

Vol 22, No 1  
March 2016



SEMINARS IN ORTHODONTICS

*Seminars in*  
**ORTHODONTICS**

Elliott M. Moskowitz, DDS, MSd  
Editor-in-Chief

**Interactions Between Orthodontics  
and Oral and Maxillofacial Surgery**

Jae Hyun Park, DMD, MSD, MS, PhD  
Guest Editor

Interactions Between Orthodontics and Oral and Maxillofacial Surgery

22:1 March 2016, 1-84

Elsevier

[www.semortho.com](http://www.semortho.com)

# Seminars in Orthodontics

*EDITOR-IN-CHIEF*

**Elliott M. Moskowitz, DDS, MSd**

Clinical Professor

Department of Orthodontics

NYU College of Dentistry

11 Fifth Avenue

New York, NY 10003

Email: [typodont@aol.com](mailto:typodont@aol.com)

Fax: (212) 674-7308

**Publication information:** *Seminars in Orthodontics* (ISSN 1073-8746) is published quarterly by Elsevier, 360 Park Avenue South, New York, NY 10010-1710. Periodicals postage paid at New York, NY and additional mailing offices. USA POSTMASTER: Send address changes to *Seminars in Orthodontics*, Elsevier Customer Service Department, 3251 Riverport Lane, Maryland Heights, MO 63043, USA.

Editorial correspondence should be addressed to: Elliott M. Moskowitz, DDS, MSd, Editor-in-Chief, *Seminars in Orthodontics*, Clinical Professor, Department of Orthodontics, NYU College of Dentistry, 11 Fifth Avenue, New York, NY 10003; email: [typodont@aol.com](mailto:typodont@aol.com); fax: (212) 674-7308.

**Orders, Claims, and Journal Inquiries:** Please contact the Elsevier Customer Service Department nearest you:

**St. Louis:** Elsevier Customer Service Department, 3251 Riverport Lane, Maryland Heights, MO 63043, USA; phone: (800) 654-2452 [toll free within the USA]; (+1) (314) 447-8871 [outside the USA]; fax: (+1) (314) 447-8029; e-mail: [JournalCustomerService-usa@elsevier.com](mailto:JournalCustomerService-usa@elsevier.com).

**Oxford:** Elsevier Customer Service Department, The Boulevard, Langford Lane, Kidlington, Oxford OX5 1GB, UK; phone: (+44) (1865) 843434; fax: (+44) (1865) 843970; e-mail: [JournalsCustomerServiceEMEA@elsevier.com](mailto:JournalsCustomerServiceEMEA@elsevier.com).

**Tokyo:** Elsevier Customer Service Department, 4F Higashi-Azabu, 1-Chome Bldg, 1-9-15 Higashi-Azabu, Minato-ku, Tokyo 106-0044, Japan; phone: (+81) (3) 5561 5037; fax: (+81) (3) 5561 5047; e-mail: [JournalsCustomerServiceJapan@elsevier.com](mailto:JournalsCustomerServiceJapan@elsevier.com).

**Singapore:** Elsevier Customer Service Department, 3 Killiney Road, #08-01 Winsland House I, Singapore 239519; phone: (+65) 63490222; fax: (+65) 67331510; e-mail: [JournalsCustomerServiceAPAC@elsevier.com](mailto:JournalsCustomerServiceAPAC@elsevier.com).

Yearly subscription rates: United States and possessions: individual, \$310.00; student and resident, \$142.00; single issue, \$105.00. All other countries: individual \$386.00; student and resident, \$193.00; single issue, \$105.00. For all areas outside the United States and possessions, there is no additional charge for surface delivery. For air mail delivery, add \$16.00. To receive student/resident rate, orders must be accompanied by name of affiliated institution, date of term, and the signature of program/residency coordinator on institution letterhead. Orders will be billed at individual rate until proof of status is received.

Prices are subject to change without notice. Current prices are in effect for back volumes and back issues. Single issues, both current and back, exist in limited quantities and are offered for sale subject to availability. Back issues sold in conjunction with a subscription are on a prorated basis.

**Author Inquiries:** For inquiries relating to the submission of articles (including electronic submission) please visit this journal's homepage at [www.elsevier.com/wps/locate/issn/1073-8746](http://www.elsevier.com/wps/locate/issn/1073-8746). Contact details for questions arising after acceptance of an article, especially those relating to proofs, will be provided by the publisher. You can track accepted articles at <http://www.elsevier.com/trackarticle>. You can also check our Author FAQs at <http://www.elsevier.com/authorFAQ> and/or contact Customer Support via <http://support.elsevier.com>.

**Funding Body Agreements and Policies:** Elsevier has established agreements and developed policies to allow authors whose articles appear in journals published by Elsevier, to comply with potential manuscript archiving requirements as specified as conditions of their grant awards. To learn more about existing agreements and policies please visit <http://www.elsevier.com/fundingbodies>.

© 2016 Elsevier Inc. All rights reserved. This journal and the individual contributions contained in it are protected under copyright by Elsevier Inc. and the following terms and conditions apply to their use:

**Photocopying:** Single photocopies of single articles may be made for personal use as allowed by national copyright laws. Permission of the Publisher and payment of a fee is required for all other photocopying, including multiple or systematic copying, copying for advertising or promotional purposes, resale, and all forms of document delivery. Special rates are available for educational institutions that wish to make photocopies for non-profit educational classroom use. For information

on how to seek permission visit [www.elsevier.com/permissions](http://www.elsevier.com/permissions) or call: (+44) 1865 843830 (UK)/(+1) 215 239 3804 (USA).

**Derivative Works:** Subscribers may reproduce tables of contents or prepare lists of articles including abstracts for internal circulation within their institutions. Permission of the Publisher is required for resale or distribution outside the institution. Permission of the Publisher is required for all other derivative works, including compilations and translations (please consult [www.elsevier.com/permissions](http://www.elsevier.com/permissions)).

**Electronic Storage or Usage:** Permission of the Publisher is required to store or use electronically any material contained in this journal, including any article or part of an article (please consult [www.elsevier.com/permissions](http://www.elsevier.com/permissions)). Except as outlined above, no part of this publication may be reproduced, stored in a retrieval system or transmitted in any form or by any means, electronic, mechanical, photocopying, recording or otherwise, without prior written permission of the Publisher.

**Notice:** No responsibility is assumed by the Publisher for any injury and/or damage to persons or property as a matter of products liability, negligence or otherwise, or from any use or operation of any methods, products, instructions or ideas contained in the material herein. Because of rapid advances in the medical sciences, in particular, independent verification of diagnoses and drug dosages should be made.

Although all advertising material is expected to conform to ethical (medical) standards, inclusion in this publication does not constitute a guarantee or endorsement of the quality or value of such product or of the claims made of it by its manufacturer.

**Reprints:** To order 100 or more reprints for educational, commercial, or promotional use, contact the Commercial Reprints Department, Elsevier Inc., 360 Park Avenue South, New York, NY 10010-1710; e-mail: [reprints@elsevier.com](mailto:reprints@elsevier.com).

**Advertising Information:** Advertising orders and inquiries can be sent to: USA, Canada and South America: James Nagle, Breuning Nagle Associates, 59 Grove St., Suite 1-D, New Canaan, CT 06840; phone: (+1) (203) 801-0055; e-mail: [jimn@bna1.com](mailto:jimn@bna1.com)

Publication of an advertisement in *Seminars in Orthodontics* does not imply endorsement of its claims by the Editor-in-Chief, Guest Editors, nor Publisher of the journal.

The contributors have checked generic and trade names and verified drug doses for accuracy according to the standards accepted at the time of publication. The ultimate responsibility, however, lies with the prescribing physician. Please convey any errors to the Editor-in-Chief.

The ideas and opinions expressed in *Seminars in Orthodontics* do not necessarily reflect those of the Editor-in-Chief, Guest Editors, nor the Publisher. Publication of an advertisement or other product mentioned in *Seminars in Orthodontics* should not be construed as an endorsement of the product or the manufacturer's claims. Readers are encouraged to contact the manufacturer with any questions about the features or limitations of the products mentioned. Neither the Editor-in-Chief, Guest Editors, nor Publisher assume any responsibility for any injury and/or damage to persons or property arising out of or related to any use of the material contained in this periodical. The reader is advised to check the appropriate medical literature and the product information currently provided by the manufacturer of each drug to be administered to verify the dosage, the method and duration of administration or contraindications. It is the responsibility of the treating orthodontist, dentist, physician or other health care professional, relying on independent experience and knowledge of the patient, to determine drug dosages and the best treatment for the patient.

*Seminars in Orthodontics* is indexed in the Cumulative Index to Nursing and Allied Health Literature® print index and the Cinahl® database.

© The paper used in this publication meets the requirements of ANSI/NISO Z39.48-1992 (Permanence of Paper).

# Seminars in Orthodontics

---

## *EDITOR-IN-CHIEF*

Elliott M. Moskowitz, DDS, MSd

## EDITORIAL BOARD

### EDITOR-IN-CHIEF EMERITUS

P. Lionel Sadowsky, DMD, BDS, DipOrth, MDent

- |                                                     |                                                           |
|-----------------------------------------------------|-----------------------------------------------------------|
| Mani Alikhani, <i>New York, NY</i> (2017)           | Peter Ngan, <i>Morgantown, WV</i> (2015)                  |
| Rolf G. Behrents, <i>St. Louis, MO</i> (2017)       | Perry M. Opin, <i>Milford, CT</i> (2017)                  |
| S. Jay Bowman, <i>Portage, MI</i> (2017)            | Jae Hyun Park, <i>Mesa, AZ</i> (2017)                     |
| James Caveney, <i>Wheeling, WV</i> (2015)           | Sheldon Peck, <i>Newton, MA</i> (2014)                    |
| John Grubb, <i>Chula Vista, CA</i> (2015)           | William R. Proffit, <i>Chapel Hill, NC</i> (2015)         |
| Greg Huang, <i>Seattle, WA</i> (2014)               | Eugene Roberts, <i>Indianapolis, IN</i> (2015)            |
| Robert J. Isaacson, <i>Edina, MN</i> (2015)         | Emile Rossouw, <i>Rochester, NY</i> (2017)                |
| Laurance Jerrold, <i>Brooklyn, NY</i> (2017)        | David L. Turpin, <i>Federal Way, WA</i> (2017)            |
| Lysle E. Johnston, Jr., <i>Eastport, MI</i> (2015)  | James L. Vaden, <i>Cookeville, TN</i> (2015)              |
| Donald R. Joondeph, <i>Bellevue, WA</i> (2015)      | Robert L. Vanarsdall, Jr., <i>Philadelphia, PA</i> (2015) |
| Robert G. Keim, <i>Los Angeles, CA</i> (2017)       | Katherine Vig, <i>Columbus, OH</i> (2017)                 |
| Richard Kleefeld, <i>Norwalk, CT</i> (2015)         | Christos Vlachos, <i>Homewood, AL</i> (2014)              |
| Steven J. Lindauer, <i>Richmond, VA</i> (2015)      | Timothy T. Wheeler, <i>Gainesville, FL</i> (2015)         |
| James A. McNamara, Jr., <i>Ann Arbor, MI</i> (2017) | Leslie A. Will, <i>Boston, MA</i> (2017)                  |

## *INTERNATIONAL*

- |                                                              |                                                        |
|--------------------------------------------------------------|--------------------------------------------------------|
| Adrian Becker, <i>Jerusalem, Israel</i> (2017)               | Rakesh Koul, <i>Lucknow, India</i> (2017)              |
| José Alexandre Bottrel, <i>Rio de Janeiro, Brazil</i> (2015) | Birte Melsen, <i>Aarhus, Denmark</i> (2017)            |
| Theodore Eliades, <i>Nea Ionia, Greece</i> (2014)            | Antony McCollum, <i>Bryanston, South Africa</i> (2015) |
| W.G. Evans, <i>Johannesburg, South Africa</i> (2017)         | Eliakim Mizarahi, <i>Ilford, England</i> (2015)        |
| Jorge Faber, <i>Brasilia, Brazil</i> (2017)                  | Bjørn Øgaard, <i>Oslo, Norway</i> (2017)               |
| Joseph Ghafari, <i>Beirut, Lebanon</i> (2017)                | Nikolaos Pandis, <i>Corfu, Greece</i> (2017)           |
| Vicente Hernandez, <i>Alicante, Spain</i> (2017)             | Pratik K. Sharma, <i>London, UK</i> (2017)             |
| Nigel Hunt, <i>London, England</i> (2015)                    | George Skinazi, <i>Paris, France</i> (2015)            |
| Haluk Iseri, <i>Ankara, Turkey</i> (2017)                    | John C. Voudouris, <i>Toronto, Canada</i> (2017)       |
| Roberto Justus, <i>Mexico City, Mexico</i> (2015)            | William A. Wiltshire, <i>Winnipeg, Canada</i> (2015)   |
| Sanjivan Kandasamy, <i>Midland, WA, Australia</i> (2017)     | Björn U. Zachrisson, <i>Oslo, Norway</i> (2015)        |

# Seminars in Orthodontics

---

VOL 22, NO 1

MARCH 2016

Interactions Between Orthodontics and Oral and Maxillofacial Surgery

Jae Hyun Park, DMD, MSD, MS, PhD

Guest Editor

---

<b>Introduction</b>	<b>1</b>
Jae Hyun Park	
<hr/>	
<b>Orthodontic considerations in orthognathic surgery: Who does what, when, where and how?</b>	<b>2</b>
Jae Hyun Park, Michael Papademetriou, and Yong-Dae Kwon	
<hr/>	
<b>Psychological considerations in orthognathic surgery and orthodontics</b>	<b>12</b>
Won Moon and Jone Kim	
<hr/>	
<b>The airway implications in treatment planning two-jaw orthognathic surgery: The impact on minimum cross-sectional area</b>	<b>18</b>
Jarom E. Maurer, Steven M. Sullivan, G. Frans Currier, Onur Kadioglu, and Ji Li	
<hr/>	
<b>Surgical exposure of impacted canines: Open or closed surgery?</b>	<b>27</b>
Adrian Becker, Ioannis Zogakis, Ionut Luchian, and Stella Chaushu	
<hr/>	
<b>Primary failure of eruption and other eruption disorders—Considerations for management by the orthodontist and oral surgeon</b>	<b>34</b>
Sylvia A. Frazier-Bowers, Sonny Long, and Myron Tucker	
<hr/>	
<b>Update on treatment of patients with cleft—Timing of orthodontics and surgery</b>	<b>45</b>
Pradip R. Shetye	
<hr/>	
<b>3D guided comprehensive approach to mucogingival problems in orthodontics</b>	<b>52</b>
Marianna Evans, Nipul K. Tanna, and Chun-Hsi Chung	
<hr/>	
<b>Implants for orthodontic patients with missing anterior teeth: Placement in growing patients—Immediate loading</b>	<b>64</b>
Mohamed Bayome, Yoon-Ah Kook, Yoonji Kim, Cheol Won Lee, and Jae Hyun Park	
<hr/>	
<b>Surgical removal of asymptomatic impacted third molars: Considerations for orthodontists and oral surgeons</b>	<b>75</b>
Sung-Jin Kim, Chung-Ju Hwang, Jung-Hyun Park, Hyung-Jun Kim, and Hyung-Seog Yu	

---

---

# Seminars in Orthodontics

---

VOL 22, NO 1

MARCH 2016

## *Introduction*

To maximize success with orthodontic treatment, cooperation between the orthodontist and other specialties is crucial. This is especially true for patients who need orthognathic surgery, where success depends on a team that is led by the orthodontist and surgeon, and supported by other specialties such as general dentists, prosthodontists, and periodontists. This issue of *Seminars in Orthodontics* addresses various interactions between oral surgeons and orthodontists, and it addresses some special challenges that orthodontists might face.

There are nine articles in this issue. The first three are related to orthognathic surgery and orthodontics. In the first one, we discuss the interaction between orthodontists and surgeons with respect to orthognathic surgical patients; our aim is to improve communication between the specialties. Recent advancements in surgical orthodontics make cooperation between the orthodontist, surgeon, and rest of the interdisciplinary team more important than ever. Orthognathic surgery is truly an interdisciplinary challenge, and lack of coordination among the team will lead to compromised results.

Beyond the mechanics of orthognathic surgery, clinicians should be aware that patients experience various psychological and emotional challenges in the course of the presurgical, surgical, and postsurgical stages of treatment. Many factors can influence the patient's level of anxiety, emotional instability, and postoperative satisfaction, so an understanding of the patient's state of mind during each stage of treatment is important. Drs. Moon and Kim from UCLA discuss psychological considerations of orthognathic surgery and orthodontics. Dr. Maurer and colleagues from the University of Oklahoma report on airway implications in orthognathic surgery treatment planning. In this study, they

focused on an evaluation of the minimum cross-sectional area of airway passages.

The next three articles discuss the interaction between the surgeon and orthodontist to treat unique problems in children and adolescents. Dr. Becker and his colleagues from Israel describe a closed versus open surgical procedure for exposing impacted canines. Dr. Frazier-Bowers and her colleagues from University of North Carolina deal with primary failure of eruption and other eruption disorder management by the orthodontist and oral surgeon. Dr. Shetye from New York University describes an update on the timing of orthodontics and surgery in treating cleft patients.

The last three articles look at challenges and critical issues in orthodontic treatment. Dr. Evans from the University of Pennsylvania describes a three-dimensional evaluation of the dentoalveolar anatomy which provides more predictable treatment outcomes for orthodontists and surgeons. I summarize some work done with my colleagues at the Catholic University of Korea dealing with the potential of implants to restore missing anterior teeth in growing patients and the effect of the immediate application of orthodontic forces on newly placed implants. Finally, Dr. Kim and his colleagues from Yonsei University in Korea review the potential risks associated with the retention and extraction of asymptomatic impacted third molars and discuss the orthodontic indications and considerations for their extraction.

It is my hope that this issue will provide the reader with useful clinical information that will enable them to increase efficiency in their personal practices. It is my further desire to encourage interdisciplinary communication that is so critical to success in our work, both among dental professionals and our patients. I deeply appreciate the opportunity to serve as the guest editor for this issue and wish to thank the editor-in-chief and Elsevier for their trust in allowing me to do this.

---

# Orthodontic considerations in orthognathic surgery: Who does what, when, where and how?

*Jae Hyun Park, Michael Papademetriou, and Yong-Dae Kwon*

**Surgical orthodontics to correct severe malocclusions and skeletal deformities involves a considerable amount of treatment planning and coordination with a multidisciplinary team. The success of the surgery requires an excellent collaboration between the orthodontist and the surgeon primarily, and secondarily with other specialties that may be involved during the diagnostic, treatment, and posttreatment phases. There is a recent movement into the “surgery-first” approach, which eliminates esthetically undesirable facial changes due to decompensation of the teeth from the presurgical orthodontic preparation. For both the conventional and “surgery-first” approaches, careful and detailed creation of a treatment plan is crucial to produce the most accurate, esthetic, and functional results. Advanced development and application of cone-beam computed tomography with three-dimensional models, craniofacial morphology and growth studies, and virtual orthodontic and surgical treatment planning are changing the traditional way that orthognathic surgery is being performed. This article discusses the interaction between orthodontists and surgeons concerning orthognathic surgical patients to improve communication between both the specialties. (Semin Orthod 2016; 22:2–11.) © 2016 Elsevier Inc. All rights reserved.**

## Introduction

**E**arly communication and coordination between the orthodontist and the surgeon to correct severe malocclusions and skeletal deformities are essential to the success of surgical treatment and to ensure patient satisfaction. The patient is the primary member of the team and should be involved in all discussions, noting his or her expectations and concerns.<sup>1</sup> The success of a surgery is directly related to the competency and consistency of the surgical team to achieve predictable, stable, and esthetic results.

Before the 1960s, most orthognathic surgeries were performed either without orthodontic treatment, or before any orthodontic treatment. Later, a three-stage approach to conventional

surgical-orthodontic treatment (presurgical orthodontics, surgery, and postsurgical orthodontics) became popular because of stability and satisfaction with posttreatment outcomes. This success was the product of the development of new surgical techniques, orthodontic materials, and rigid fixation. However, longer treatment times and transitional detriment to the facial profile has led to a new approach called “surgery-first,” which eliminates the presurgical orthodontic phase.<sup>2</sup> The “surgery-first” approach was first introduced by Nagasaka et al.<sup>3</sup> in 2009. Over time, this approach has gained in popularity among orthodontists and surgeons for several reasons.<sup>4</sup> First, the esthetic concern for the patient is addressed from the beginning.<sup>5,6</sup> Second, the length of the orthodontic treatment, which ultimately affects the total treatment time, is significantly reduced. This is probably related to the regional acceleratory phenomenon (RAP)<sup>5,7–9</sup> and a more efficient skeletal position in which soft tissue imbalances that can interfere with orthodontic movements have been suppressed. Third, when compared to the conventional three-stage surgical-orthodontic approach, a “surgery-first” approach does not seem to impair the final occlusion.<sup>7</sup> However, there has

---

*Arizona School of Dentistry & Oral Health, A.T. Still University, Mesa, AZ; Graduate School of Dentistry, Kyung Hee University, Seoul, South Korea; Department of Oral and Maxillofacial Surgery, School of Dentistry, Kyung Hee University, Seoul, South Korea.*


*Address correspondence to Jae Hyun Park, DMD, MSD, MS, PhD, Arizona School of Dentistry & Oral Health, A.T. Still University, 5835 East Still Circle, Mesa, AZ 85206. E-mail: JPark@atsu.edu*

© 2016 Elsevier Inc. All rights reserved.

1073-8746/12/1801-\$30.00/0

<http://dx.doi.org/10.1053/j.sodo.2015.10.002>



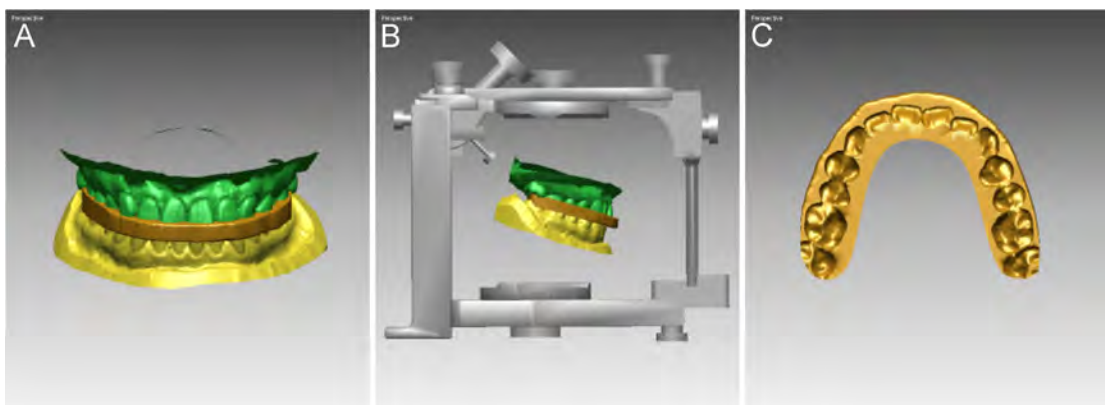


**Figure 1.** Mandibular surgical simulation movement using Morpheus3D CT software (Seoul, Korea).

been more instability and the outcome has been unpredictable.<sup>8,10</sup> Therefore, in order to reduce the uncertainty of postsurgical occlusion and increase the predictability of the results, the use of minimal presurgical orthodontics has been proposed.<sup>11–13</sup> Joh et al.<sup>13</sup> concluded that after treatment, there was no significant difference in hard and soft tissue measurements between the minimal presurgical orthodontic group and the conventional presurgical orthodontic group, but the total treatment time was significantly shorter in the minimal presurgical orthodontic group due to the shorter presurgical orthodontic treatment time.

Another advancement in jaw surgery is the utilization of three-dimensional (3D) imaging technology such as cone-beam computed tomography (CBCT). The shift from a two-dimensional (2D) to 3D imaging expands the possibilities for better diagnosis, surgical simulation, and surgical splint construction. This virtual planning allows for a more thorough analysis and surgical planning, especially in patients with facial asymmetries.<sup>2</sup> With

3D virtual technology, we have a tremendously helpful tool that allows us to more closely replicate the actual patient (Fig. 1). Incorporating 3D cephalometry is essential, but it is still in the early stages of development. Even though we have the ability to measure the right side and the left side separately, a potentially valuable benefit when treating asymmetries,<sup>14</sup> we still apply it as we do in 2D, by using the average measurements of the two sides.<sup>15</sup> Different software programs are available for 3D planning and fabrication of splints using CAD/CAM (computer-aided design/computer-aided manufacturing) technology.<sup>16</sup> The fabrication of CAD/CAM surgical wafers has introduced a working methodology which is different from conventional clinical practice. Being able to use computer-aided surgical simulation (CASS), a 3D virtual environment for planning and simulating surgery, provides surgeons with the best possible scenario for preoperative treatment planning (Fig. 2).<sup>16</sup> Although CBCT scans significantly reduced the radiation exposure compared with the multi-slice CT scans,<sup>17</sup> there are concerns



**Figure 2.** (A and B) 3D virtual models were constructed and mounted into the virtual articulator. They were repositioned according to the STO using the 3D Virtual Model Surgery program (Orapix, Seoul, Korea). (C) A 3D virtual wafer (3D-VIW) was constructed using a stereolithographic technique (Viper2; 3D Systems, Rock Hill, SC).

about the 3D virtual surgical planning in that there is an increase in radiation exposure due to the need for pre- and postsurgical CBCT scans. Fortunately, by adjusting the operating parameters, including exposure factors and reducing the field of view to the actual region of interest, we can now significantly reduce the radiation exposure.<sup>18,19</sup>

Recent advancements in surgical orthodontics make the cooperation between the orthodontist, the surgeon, and the whole interdisciplinary team crucial. A successful outcome is derived from teamwork, which is primarily guided by the orthodontist and the surgeon, and could include other specialties such as general dentists, prosthodontists, periodontists, radiologists, psychologists, anesthesiologists, and nutritionists. Orthognathic surgery is truly an interdisciplinary challenge, and lack of coordination among the orthodontist, the surgeon, and the rest of the team will lead to a compromised result.<sup>20,21</sup> Therefore, this article, explores the phases that are associated with orthognathic surgery, and the roles and collaborative efforts of the members of the surgical team.

### Initial evaluation

The initial orthodontic evaluation should involve diagnostic records such as those from a thorough clinical exam, temporomandibular joint (TMJ) evaluation, the patient's medical forms, and chief complaint, plus photographs, radiographs, articulated study models, and bite registration in centric relation. All photographs and radiographs should be taken in the natural head position. Additional records that could provide more precise details are 3D photographic images, CBCT, and video images of the patient.<sup>22,23</sup> When taking these records, it is crucial that they are precise and consistent. They can easily be shared with the surgical team in order to minimize the patient's exposure to further radiation. When establishing an initial diagnosis and treatment plan, a surgical option should be presented, without giving specific surgical details at this point. It is very important that the patient understands that presurgical orthodontics will make the problem worse and facial changes may become more pronounced temporarily until they are corrected by the surgery.

It is essential that the orthodontist and the surgeon have a clear understanding of the path they are going to follow with the case before the surgical consultation. Issues like third molar extractions, one or two-jaw surgery, genioplasty, or other facial plastic surgery should be addressed in order to avoid patient confusion. Also, the orthodontist should review the patient's chief complaint, concerns, family situation, and insurance and monetary issues with the surgeon. The patient should understand that whatever is not covered by the insurance company will be their responsibility for both the orthodontic and surgical treatments. The surgeon should discuss hospitalization details and possible options for outpatient procedures. Surgical details, including risks, complications, diet, and eating difficulties should be presented to help the patient make an educated decision. Medical history and risk assessment need to be completed early to allow proper workup.

The orthodontist should explain to the patient the difference between camouflage treatment and surgery. A nonsurgical treatment plan may provide satisfactory occlusal results, but compromised esthetics. A 2D or 3D surgical treatment objective (STO) may help the patient in making a decision. Once the patient understands and agrees with what was discussed at the surgical consultation, the orthodontist is ready to start presurgical orthodontic treatment.

The surgeon should send all the details of the surgery and treatment requests in writing, and the orthodontist must document them in the patient's chart. Complications such as third molar extractions prior to surgery, particularly in the mandible, must be completed at least six months prior to mandibular surgery. Any other proposed surgical treatment such as other extractions, surgical expansion, segmented maxilla, genioplasty, or other esthetic augmentations need to be discussed and documented. Orthodontic considerations such as whether or not to level the occlusal plane, overcorrections, types of splint and how long they will be used, type of fixation, space opening or root divergence to facilitate cuts and follow-up appointments must be discussed from the beginning. Any restorative work, permanent or provisional, must be discussed with the general dentist or prosthodontist and completed, if necessary, before presurgical orthodontics. Periodontal and



temporomandibular disorder (TMD) concerns must also be addressed before the orthodontic treatment starts. All these will help the orthodontist work his treatment plan and minimize presurgical questions and delays.

### Presurgical orthodontics

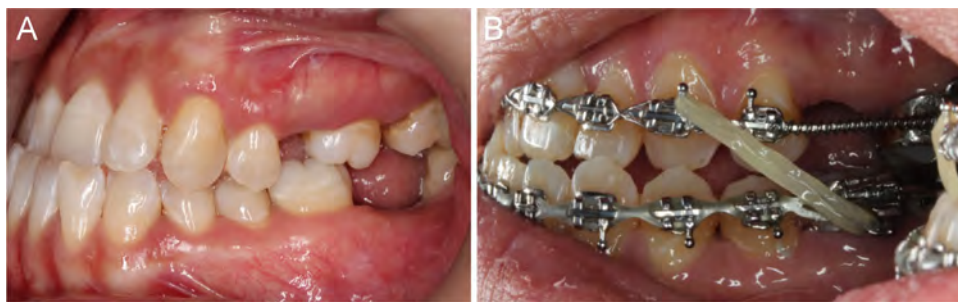
The presurgical phase involves alignment and leveling of the arches, unless there is a two-plane occlusion, in which case the treatment goal becomes maintaining the two-planes and decompensating the teeth to an ideal position within the arches and coordinating the arches. If extractions are necessary to alleviate crowding, to decompensate the teeth, to reduce protrusion or to help maximize the surgical movements before surgery, the extraction spaces should be closed. On the other hand, there are situations such as anterior segmental osteotomy where extraction spaces are closed during surgery to help decompensate the incisors or correct anterior cross bite. If mandibular surgery is planned, mandibular third molars should be extracted at least six months prior to surgery to allow healing and bone filling of the extraction site to reduce the risk of a bad split and to facilitate fixation. The maxillary third molars can be extracted during surgery if necessary. If segmental Le Fort I osteotomy is planned, any necessary expansion should be done surgically and not orthodontically. To increase stability of the expansion, clinicians could consider two-stage surgery [first, surgically assisted rapid palatal expansion (SARPE), and then Le Fort I surgery].<sup>24</sup> If a two- or three-piece Le Fort I osteotomy is being considered, it is critical to verify with the surgeon where the cuts are going to be and how much

space or root divergence is needed. It is important that there be no compensations on the teeth during the presurgical orthodontic treatment, whether it be expansion of the arches, extrusion of anterior teeth to close open bite or leveling of a two-plane occlusion. If a patient has a two-plane occlusion, it should be maintained that way and be corrected during surgery.

In Class III cases, Class II elastics are recommended to help decompensate the retroclined mandibular incisors and proclined maxillary incisors. This will also help to build over correction for Class III relapse (Fig. 3). The opposite should take place in Class II cases with the use of Class III elastics.

Occasional study models can be very helpful for evaluation of arch coordination, leveling, any torque issues (especially on the second molars), and any Bolton discrepancy. This will also help in a determination of the time for surgery. A total of six months prior to surgery, the orthodontist should evaluate alignment of teeth, torque of both anterior and posterior teeth, arch coordination using stone models, communicate with the surgeon to make sure that insurance and financial arrangements are in order and send the patient to the surgeon for an evaluation. After that appointment, the surgeon and orthodontist should discuss any necessary changes or adjustments.

Approximately 2–3 months before surgery, a presurgical workup appointment should be scheduled with the surgeon. This is an important appointment to review all surgical details, confirm that the patient is ready for surgery and request any minor adjustments such as any necessary spaces or root angulations, equilibrate any interfering contacts, review the hospitalization or outpatient process, and reconfirm insurance matters.



**Figure 3.** (A) Typical compensations of anterior teeth in Class III patients. Proclined maxillary incisors and retroclined mandibular incisors. (B) The use of Class II elastics in Class III cases helps decompensate the anterior teeth.

Before the final surgical workup and at least 4–6 weeks before surgery, the orthodontist should place the final wires to allow any tooth movement to take place and the wires to become passive before taking impressions or 3D virtual images for the construction of the surgical splints. The wires should be stiff enough to resist any unfavorable tooth movements during fixation. For 0.022 slot, a  $0.19 \times 0.25$  in stainless steel wire is preferable; for 0.018 slot, a  $0.16 \times 0.22$  in or  $0.17 \times 0.25$  in stainless steel wire is sufficient. At this time, the orthodontist should also check for any loose bands or brackets. Immediately before the final surgical appointment with the surgeon, the orthodontist should place surgical hooks on the arch wires according to the surgeon's specifications.

At the final surgical appointment 2–3 weeks prior to surgery, the surgeon should take presurgical records including photos, radiographs (panorex, cephalograms, and tomograms), impressions, bite registration in centric relation, face-bow transfer for surgical planning and splint construction. If 3D virtual technology is used instead, then a CBCT scan is necessary instead of the 2D radiographs mentioned above. Medical imaging, virtual treatment planning, and virtual splint construction could bring an end to impressions and face-bow transfers.<sup>3</sup> All records should be taken in the natural head position.<sup>25,26</sup>

If 3D treatment planning is to be used, the surgeon and the orthodontist should get together, either in person or by other means of communication, and finalize the details of the surgical movements. At the same time, they should communicate with the 3D virtual planning company they use to work up the details of the surgery, finalize the STO and construct the splint. Before surgery, the surgeon should have the patient come to the office for a final visit to try in the splints on each arch individually and make sure that there are no interferences with the brackets or wires and that they are not warped and fit well. Model surgery and surgical splint construction are traditionally done by the surgeon, but there are some orthodontists who prefer to do it themselves. This should be communicated and worked out between the orthodontist and surgeon.

### **Surgical phase**

An agreement as to the guidelines should be made between the surgeon and the orthodontist

in order to take the appropriate radiographs at the optimal times. The dataset guidelines from the British Association of Oral and Maxillofacial Surgeons (BAOMS) and British Orthodontic Society (BOS) recommend lateral cephalograms preoperatively, at the end of presurgical orthodontics, postoperatively 1–3 weeks after surgery, the prebonding stage, and two years post-retention. Panoramic radiographs are required before the initial orthodontic treatment, and immediately postoperatively.<sup>27</sup>

The BAOMS guideline enables clinicians to minimize unnecessary radiation exposure for the patient while still providing adequate data. Panorex should be initiated immediately postoperatively to confirm the position of the condyles. Not only the surgeons, but also the orthodontists should meticulously review the radiographs before starting treatment.

### **Surgery**

Optimal facial harmony and proportions may be viewed differently by patients, surgeons, and orthodontists. Therefore, open discussion should be mandatory between the treatment team members going over the patient's records including 3D computed tomography (CT) dataset. Understanding the patient's desires and expectations are very important in creating the surgical plan, but care should be taken with patients who have unrealistic expectations; the presurgical consultation with the patient and his/her guardian is quite important to make sure they understand what is possible and what is not with the surgery.

Surgery can control all of the dental and skeletal components supporting the facial profile; therefore, any major discrepancy should be corrected by surgery. With the advancement of surgical skills, various surgical options are available for the patients. Orthodontists should also know the possible surgical options available for their patients and be actively involved in surgical planning. Having understood surgical options, orthodontists can carry out presurgical orthodontics more efficiently because predicted results can be stimulated beforehand.

A combination of Le Fort I osteotomy and mandibular surgery is the basic option for orthognathic patients. For maxillary surgery, Le Fort I is the most commonly used method for

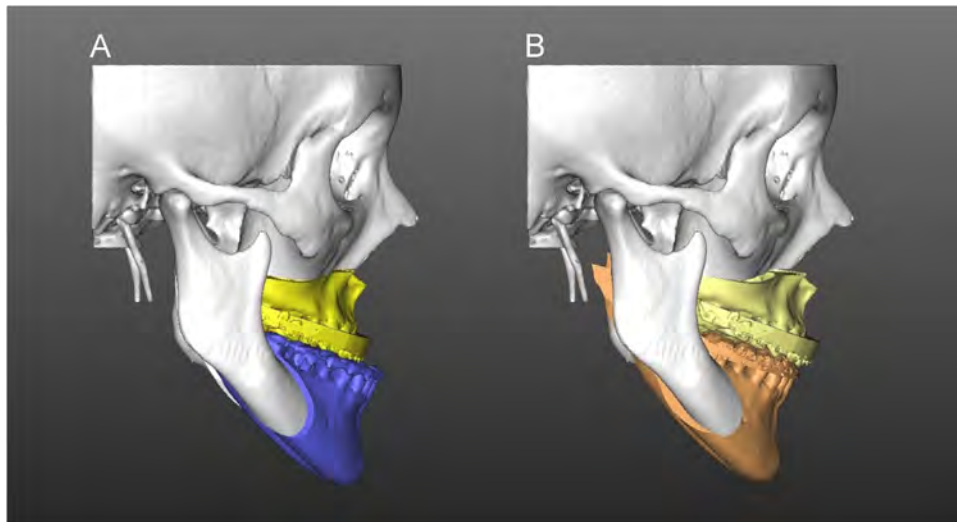
most dentofacial deformities. Depending on the nasomaxillary soft tissue profile, the osteotomy line can be modified accordingly, so a deficient soft tissue profile can be improved with Le Fort I advancement. Rotation of the maxillomandibular complex can manipulate the occlusal plane and control the incisal axis.<sup>28</sup> In patients with prognathic mandibles, maxillary retrusion is often noticed and clockwise rotation of the maxillomandibular complex can improve depressed paranasal contour and can allow for more mandibular setback.<sup>29</sup>

Alar base widening, which is considered to be an undesirable side effect of Le Fort I advancement, can be minimized by using alar cinch suture techniques. Segmental surgery has many clinical applications and can decrease the duration of presurgical orthodontics if the surgical plan has been set up at the initial treatment planning. In transverse deficiency cases, putting parasagittal osteotomy lines in conjunction with Le Fort I osteotomy can widen the maxilla. In most adult orthognathic surgery patients, maxillary expansion during presurgical orthodontics may lead to dental tipping rather than true expansion.<sup>30</sup> Two-segment and three-segment maxillary osteotomy are available options, but H-shape osteotomy is the preferred method. Bimolar width can be expanded to about 5 mm, and SARPE can be carried out for larger expansion.<sup>31,32</sup> Anterior segmental osteotomy is occasionally useful to

control bimaxillary protrusion although orthodontic miniscrews are widely used for this purpose.

For mandibular surgery, bilateral sagittal split osteotomy (BSSO) is the most popular among oral surgeons although other ramus surgeries such as intraoral vertical ramus osteotomy (IVRO) can still be used. BSSO, combined with Le Fort I osteotomy, is proven to show excellent long-term postoperative stability in literatures.<sup>29,33,34</sup> Some studies showed that IVRO may be useful for patients with temporomandibular disorder.<sup>35,36</sup> Depending on the wishes of patients or orthodontists, additional adjunct surgery can be planned. Surgeons may also recommend some adjunct surgical options such as genioplasty, mandibular contouring surgery, or other augmentation techniques. These adjunct surgical options can help the treatment team meet the patients' expectations.

Virtual surgical planning and 3D surgical planning software are becoming popular and are very useful tools in surgeons' armamentarium to help motivate patients and give them a better understanding of the surgical procedure. While setting up the surgical plan, the surgeon and the orthodontist can confirm the detailed movement of the jaws by means of surgical simulation (Fig. 4). The postoperative occlusion, set by the orthodontist from the patient's cast models, may be optimal from a dental aspect, but the overall skeletal harmony of the mandible may not have



**Figure 4.** (A) Segmentation of CT dataset was done and scanned images of the dental cast were transferred and merged to the CT images. (B) Virtual surgery was performed in a software and the final position of the maxilla and mandible was confirmed (Simplant O&O, Materialise, Leuven, Belgium).

been taken into consideration. Sometimes the postoperative mandibular position may be unpredictable in the context of 3D spatial facial harmony.

A surgeon can perform simulation surgery before he/she goes into the operating room. During a simulation surgery with segmented CT dataset, the surgeon can easily recognize the yaw of the maxilla and the mandible and also can add yaw correction in the surgical plan. The surgeon also can detect possible interference between the proximal and distal segment of the mandible, allowing for a modified plan to be created to minimize undesirable interference during BSSO. Three-dimensional superimposition is also possible and simulation surgery can be validated by the superimposition of pre- and postoperative 3D CT scan images (Fig. 5).<sup>37</sup> Long-term stability can also be evaluated with this technique.

## Fixation

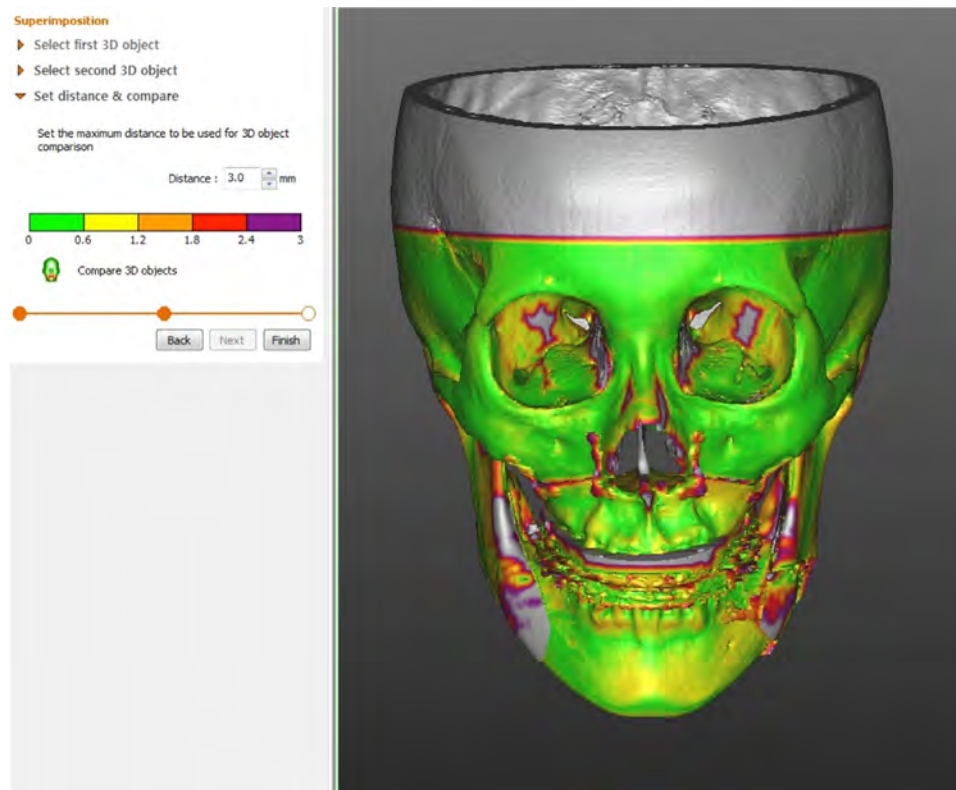
Rigid fixation, using titanium plates and screws, has enabled us to fix the osteotomized bone

segments. It has enabled patients to begin oral functions such as speaking and eating in the early postoperative period.

In the mandible, bicortical screws can be applied, but plates and screws are more popular methods for mandibular fixation. Although bicortical screw fixation seemed stable, fixation with miniplates and screws can be assumed to exert less stress on the temporomandibular joint and a lower incidence of inferior alveolar nerve injury.<sup>38,39</sup> Resorbable fixation plates and screws have been introduced by several companies. They are getting popular but their stability is still under clinical validation.<sup>40–42</sup> Some researchers have shown that conventional fixation with titanium miniplates may be more stable in maxillary elongation and mandibular setback.<sup>40</sup>

## Splint

The surgical splint is the most important appliance during the intraoperative period. Intraoperative maxillary position is significantly dependent on the intermediate or final splints;



**Figure 5.** Superimposition of the 3D image of the virtual surgery and immediate postoperative image. The real outcome was able to be validated (Simplant O&O, Materialise, Leuven, Belgium).



accurate model surgery cannot be over-emphasized in every case. In order to check the vertical position of the osteotomized maxilla, K-wire or a miniscrew can be placed at the nasion point of the patient. Currently, splint fabrication is possible using 3D technology. Surgical splints should be thin and durable since they are usually maintained in the maxillary arch during a post-operative period lasting from a few days to several weeks.

### Postoperative course; elastic wear and exercise

Swelling and bleeding are the most common postoperative events. Icepacks and elastic facial bandages are applied for 48 hours starting immediately after surgery. Steroids are commonly prescribed postoperatively to reduce swelling and bruising may sometimes occur. Neurosensory disturbance (NSD) in the chin and the lower lip area is quite a common post-operative complication so the patient should be specifically advised of it. NSD in the paranasal area and upper lip area, although uncommon, may also be observed when Le Fort I osteotomy is done. NSD after orthognathic surgery is mostly

self-limiting over time but sometimes hypoesthesia may persist.<sup>43</sup> Supportive measures for NSD such as vitamin B12 administration and neurosensory training might be beneficial.<sup>44</sup>

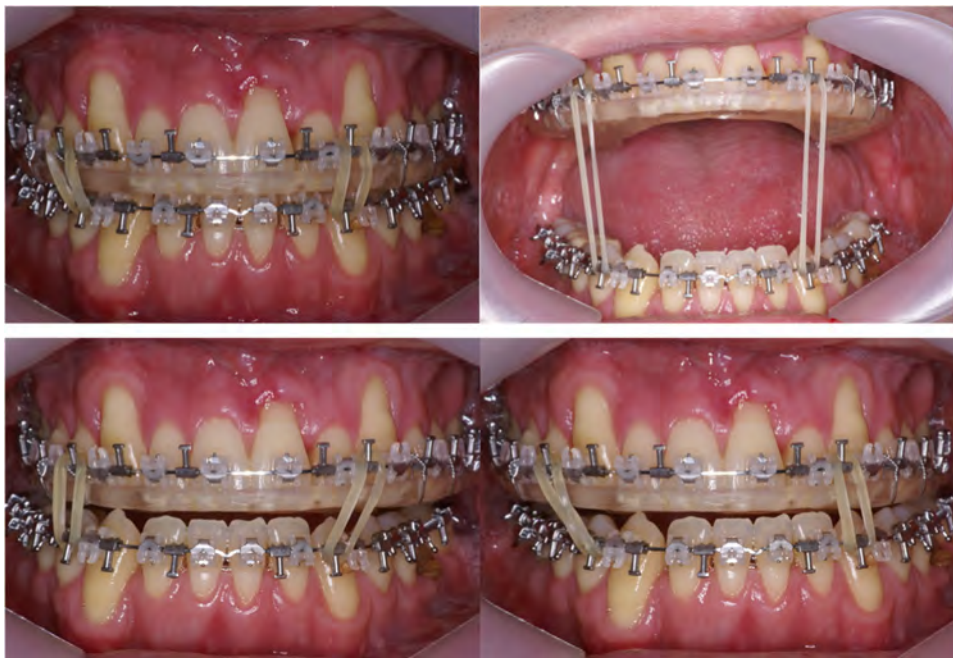The surgical splint is fixed with wires in the maxillary arch and a couple of elastics can be applied for physiotherapy. The mandible is guided into the bite indentations on the splint by the elastics (Fig. 6). The surgeon should educate the patient how to perform mouth opening exercises. They are especially important when IVRO is carried out because rigid fixation is not being used.

Before the patients are sent back to the orthodontist, mouth opening should be achieved to recover normal function for postsurgical orthodontic treatment.

The orthodontist, following the surgeon's instructions, can also remove the surgical splint when changing the surgical arch wire.

### Diet

Immediate postoperative, parenteral nutritional support is beneficial. In the early postoperative period, a liquid diet is usually provided and some commercial liquid nutritional supplements are also available. Nasogastric tubes are rarely used.



**Figure 6.** Surgical splint in maxillary arch. Mouth opening exercise should be taught for oral function rehabilitation using some elastics. Mouth opening enough for functional recovery and forthcoming orthodontic treatment should be obtained.

Soft diet is usually recommended during the healing phase. Tough and hard food should be avoided throughout the surgical-orthodontic treatment period.

### Postsurgical orthodontics

Right after the surgery, the surgeon should monitor the patient closely and have the patient come in for weekly visits. Within a week after surgery, a panoramic radiograph and cephalograms, or CBCT are taken to evaluate the surgical cuts and to make sure the condyles are seated. It is essential that the surgeon and the orthodontist communicate continuously throughout the entire process, and any problems should be addressed immediately. The orthodontist can usually resume the treatment about 2–6 weeks after the surgery upon the advice of the surgeon. At this time, the wires with surgical hooks are removed, any broken brackets are rebonded and new wires are placed to continue the finishing stage of the orthodontic treatment. The earlier the surgical splint is removed (ideally within 2 weeks), the faster the occlusion will settle because of the RAP, activated by the osteotomies.

The postsurgical orthodontic phase lasts about 6–8 months on average. This also applies to the “minimal presurgical orthodontics” approach.<sup>13</sup> During this time, the final detailing and finishing take place. After debonding, final records are taken and retainers are delivered. The retention phase is usually similar to that of conventional orthodontics, but it varies from practitioner to practitioner.

### Conclusion

Every member of the surgical team should know when, where, and how they are involved in a surgical case and should be in constant communication with the orthodontist and surgeon. An excellent coordination and interaction between the orthodontist, the surgeon, and the rest of the surgical team will lead to a successful surgery and a desirable outcome.

### References

1. Venugoplan SR, Nanda V, Turkistani K, et al. Discharge patterns of orthognathic surgeries in the United States. *J Oral Maxillofac Surg.* 2012;70:e77–e86.
2. Uribe F, Janakiraman N, Shafer D, et al. Three-dimensional cone-beam computed tomography-based virtual treatment planning and fabrication of surgical splints for asymmetric patients: surgery first approach. *Am J Orthod Dentofacial Orthop.* 2013;144:748–756.
3. Nagasaka H, Sugawara J, Kawamura H, et al. “Surgery first” skeletal Class III correction using the skeletal anchorage system. *J Clin Orthod.* 2009;43:97–105.
4. Quevado LA, Ruiz JV, Quevedo CA. Using a clinical protocol for orthognathic surgery and assessing a 3-dimensional virtual approach: current therapy. *J Oral Maxillofac Surg.* 2011;3:623–637.
5. Hernandez-Alfaro F, Guijarro-Martinez R, Molina-Coral A, et al. “Surgery first” in bimaxillary orthognathic surgery. *J Oral Maxillofac Surg.* 2011;69:e201–e207.
6. Villegas C, Janakiraman N, Uribe F, et al. Rotation of the maxillomandibular complex to enhance esthetics using a “surgery first” approach. *J Clin Orthod.* 2012;46:85–91.
7. Hernandez-Alfaro F, Guijarro-Martinez R. On a definition of the appropriate timing for surgical intervention in orthognathic surgery. *Int J Oral Maxillofac Surg.* 2014;43:846–855.
8. Villegas C, Uribe F, Sugawara J, et al. Expedited correction of significant dentofacial asymmetry using a “surgery first” approach. *J Clin Orthod.* 2010;44:97–103.
9. Wilcko MT, Wilcko WM, Pulver JJ, et al. Accelerated osteogenic orthodontic technique: a 1-stage surgically facilitated rapid orthodontic technique with alveolar augmentation. *J Oral Maxillofac Surg.* 2009;67:2149–2159.
10. Hong K, Lee J. 2-Phase treatment without preoperative orthodontics in skeletal Class III malocclusion. *Korean J Oral Maxillofac Surg.* 1999;25:25–48.
11. Ko EW, Hsu SS, Hsieh HY, et al. Comparison of progressive cephalometric changes and post-surgical stability of skeletal Class III correction with and without presurgical orthodontic treatment. *J Oral Maxillofac Surg.* 2011;69:1469–1477.
12. Wang YC, Ko EW, Huang CS, et al. Comparison of transverse dimensional changes in surgical skeletal Class III patients with and without presurgical orthodontics. *J Oral Maxillofac Surg.* 2010;68:1807–1812.
13. Joh B, Bayome M, Park JH, et al. Evaluation of minimal versus conventional presurgical orthodontics in skeletal Class III patients treated with two-jaw surgery. *J Oral Maxillofac Surg.* 2013;71:1733–1741.
14. Tai K, Park JH, Ikeda K, et al. Severe facial asymmetry and unilateral lingual crossbite treated with orthodontics and 2-jaw surgery: 5-year follow-up. *Am J Orthod Dentofacial Orthop.* 2012;142:509–523.
15. Olszewsk R, Zech F, Cosnard G, et al. Three dimensional cephalometric craniofacial analysis: experimental validation in vitro. *Int J Oral Maxillofac Surg.* 2007;36:828–833.
16. Aboul-Hosn CS, Hernandez-Alfaro F. 3D planning in orthognathic surgery: CAD/CAM surgical splints and prediction of the soft and hard tissues results—our experience in 16 cases. *J Craniomaxillofac Surg.* 2012;40:162–168.
17. Stokbro K, Aagaard E, Torkov P, et al. Systematic review: virtual planning in orthognathic surgery. *Int J Oral Maxillofac Surg.* 2014;43:957–965.
18. Bornstein MM, Scarfe WC, Vaughn VM, et al. Cone-beam computed tomography in implant dentistry: a systematic



- review focusing on guidelines, indications, and radiation dose risks. *Int J Oral Maxillofac Impl.* 2014;29:55–77.
19. Lundlow JB, Walker C. Assessment of phantom dosimetry and image quality of i-CAT FLX cone-beam computed tomography. *Am J Orthod Dentofacial Orthop.* 2013;144:802–817.
  20. Wirthlin JO, Shetye PR. Orthodontist's role in orthognathic surgery. *Semin Plast Surg.* 2013;27:137–144.
  21. Proffit WR, White RP, Combining surgery and orthodontics: who does what, when? In: Proffit WR, White RP, Sarver DM, eds *Contemporary Treatment of Dentofacial Deformity*. St. Louis: Mosby; 2003:245–268.
  22. Lubberts HT, Medinger L, Kruse A, et al. Precision and accuracy of the 3dMD photogrammetric system in cranio-maxillofacial application. *J Craniofac Surg.* 2010;21:763–767.
  23. Arnett GW, McLaughlin RP. *Facial and Dental Planning for Orthodontists and Oral Surgeons*. St. Louis: Mosby; 93–133.
  24. Phillips C, Medland WH, Fields HW, et al. Stability of surgical maxillary expansion. *Int J Adult Orthodon Orthognath Surg.* 1992;7:139–146.
  25. Lundstrom F, Lundstrom A. Natural head position as a basis for cephalometric analysis. *Am J Orthod Dentofacial Orthop.* 1992;101:244–247.
  26. Halazonitis DJ. Estimated natural head position and facial morphology. *Am J Orthod Dentofacial Orthop.* 2002;121:364–368.
  27. Dewi F, Jones SD, Ghaly GA, et al. Compliance with the minimum dataset of the British Orthodontic Society/British Association of Oral and Maxillofacial Surgeons for record keeping for orthognathic patients: retrospective comparative multicentre audit. *Br J Oral Maxillofac Surg.* 2013;51:639–643.
  28. Reyneke JP, Bryant RS, Suuronen R, et al. Postoperative skeletal stability following clockwise and counter-clockwise rotation of the maxillomandibular complex compared to conventional orthognathic treatment. *Br J Oral Maxillofac Surg.* 2007;45:56–64.
  29. Bang SM, Kwon YD, Kim SJ, et al. Postoperative stability of 2-jaw surgery with clockwise rotation of the occlusal plane. *J Craniofac Surg.* 2012;23:486–490.
  30. Kretschmer WB, Baciut G, Baciut M, et al. Transverse stability of 3-piece Le Fort I osteotomies. *J Oral Maxillofac Surg.* 2011;69:861–869.
  31. Vandersea BA, Ruvo AT, Frost DE. Maxillary transverse deficiency—surgical alternatives to management. *Oral Maxillofac Surg Clin North Am.* 2007;19:351–368.
  32. Betts NJ, Vanarsdall RL, Barber HD, et al. Diagnosis and treatment of transverse maxillary deficiency. *Int J Adult Orthodon Orthognath Surg.* 1995;10:75–96.
  33. Ueki K, Marukawa K, Shimada M, et al. Maxillary stability following Le Fort I osteotomy in combination with sagittal split ramus osteotomy and intraoral vertical ramus osteotomy: a comparative study between titanium miniplate and poly-L-lactic acid plate. *J Oral Maxillofac Surg.* 2006;64:74–80.
  34. Hoffman GR, Brennan PA. The skeletal stability of one-piece Le Fort I osteotomy to advance the maxilla; Part I. Stability resulting from non-bone grafted rigid fixation. *Br J Oral Maxillofac Surg.* 2004;42:221–225.
  35. Fujimura K, Segami N, Sato J, et al. Comparison of the clinical outcomes of patients having sounds in the temporomandibular joint with skeletal mandibular deformities treated by vertico-sagittal ramus osteotomy or vertical ramus osteotomy. *Oral Surg Oral Med Oral Pathol Oral Radiol Endo.* 2005;99:24–29.
  36. Park KR, Kim SY, Park HS, et al. Surgery-first approach on patients with temporomandibular joint disease by intraoral vertical ramus osteotomy. *Oral Surg Oral Med Oral Pathol Oral Radiol.* 2013;116:e429–e436.
  37. Park JH, Tai K, Owtad P. 3-Dimensional cone-beam computed tomography superimposition: a review. *Semin Orthod.* 2015;21:263–273. <http://dx.doi.org/10.1053/j.sodo.2015.07.007>.
  38. Ochs MW. Bicortical screw stabilization of sagittal split osteotomies. *J Oral Maxillofac Surg.* 2003;61:1477–1484.
  39. Yamashita Y, Otsuka T, Shigematsu M, et al. A long-term comparative study of two rigid internal fixation techniques in terms of masticatory function and neurosensory disturbance after mandibular correction by bilateral sagittal split ramus osteotomy. *Int J Oral Maxillofac Surg.* 2011;40:360–365.
  40. Ballon A, Laudemann K, Sader R, et al. Segmental stability of resorbable P(L/DL)LA-TMC osteosynthesis versus titanium miniplates in orthognathic surgery. *J Craniofac Surg.* 2012;40:e408–e414.
  41. Moure C, Qassemayr Q, Dunaud O. Skeletal stability and morbidity with self-reinforced P (L/DL) LA resorbable osteosynthesis in bimaxillary orthognathic surgery. *J Craniofac Surg.* 2012;40:55–60.
  42. Ahn YS, Kim SG, Baik SM, et al. Comparative study between resorbable and nonresorbable plates in orthognathic surgery. *J Oral Maxillofac Surg.* 2010;68:287–292.
  43. Colella G, Cannavale R, Vicidomini A, et al. Neurosensory disturbance of the inferior alveolar nerve after bilateral sagittal split osteotomy: a systematic review. *J Oral Maxillofac Surg.* 2007;65:1707–1715.
  44. Phillips C, Essick GK, Chung Y, et al. Non-invasive therapy for altered facial sensation following orthognathic surgery: an exploratory randomized clinical trial of intranasal vitamin B12 spray. *J Maxillofac Trauma.* 2012;1:20–29.

---

# Psychological considerations in orthognathic surgery and orthodontics

*Won Moon and Jone Kim*

**The perceived needs and self-image of patients often differ from those of the orthodontists and oral surgeons who are treating them. Unfortunately, some patients may have unreasonable expectations of the treatment outcomes, so a thorough assessment of patient perception is an important initial step during the treatment planning stage in order to ensure patient satisfaction. Clinicians should also be aware that patients experience various psychological and emotional challenges during the course of the pre-surgical, surgical, and postsurgical stages of treatment. Many factors can influence the patient's level of anxiety, emotional instability, and postoperative satisfaction, so understanding the patient's state of mind during each stage of treatment is essential. Numerous studies have suggested ways to minimize negative feelings and the relationship between surgeon and orthodontist plays an important role in building patient confidence and trust in the entire process. The mutual respect and close collaboration between them can prevent undesirable psychological distress. (Semin Orthod 2016; 22:12–17.) © 2016 Elsevier Inc. All rights reserved.**

## Introduction

Various aspects of psychology relative to orthognathic surgical procedures have already been studied and are well documented. It takes a considerable level of commitment and trust for a patient to accept these surgical procedures, which can significantly alter masticatory functions and facial appearance. Recently, Miguel et al.<sup>1</sup> suggested that the current objective of orthodontic treatment associated with orthognathic surgery consists of not only treating the esthetic and functional components of dentofacial deformities but also of considering the patients' psychological factors. Often, while the main focus of the care providers is in providing functional and esthetic improvement objectively, the patient is focused on subjective expectations of treatment outcome that can be difficult to assess.<sup>2</sup> The patient's perception of skeletal

disharmony and associated functional problems can be quite different from the parameters that the health professionals use to evaluate the patient's skeletal and facial structure. Subsequently, the patient's expectations of the surgical outcome may be significantly different from that of the providers and are sometimes unrealistic. It is imperative to thoroughly understand the patient's perceptions and expectations regarding treatment success. In this article, patient psychology through the course of orthognathic surgery will be examined and critical considerations will be discussed, and psychological factors related to interaction between surgeons and orthodontists will be explored.

## Perception

Self-perception and an awareness of the need for functional or esthetic improvement are important factors in a patient's willingness to seek treatment. This is especially true when an invasive and costly procedure is involved.<sup>3</sup> The desire for improvement may arise from a patient's awareness of existing problems, but not all patients may be initially aware of their problems, so orthodontists or oral surgeons can play a significant role in awakening them to the existing problems and potential solutions. Orthognathic surgery

---

*Section of Orthodontics, UCLA School of Dentistry, Los Angeles, CA; Section of Oral and Maxillofacial Surgery, UCLA School of Dentistry, Los Angeles, CA.*

*Address correspondence to Won Moon, DMD, MS, Section of Orthodontics, UCLA School of Dentistry, Los Angeles, CA 90095-1668. E-mail: wmoon@dentistry.ucla.edu*

© 2016 Elsevier Inc. All rights reserved.

1073-8746/12/1801-\$30.00/0

<http://dx.doi.org/10.1053/j.sodo.2015.10.003>

requires close collaboration between the maxillo-facial surgeon and orthodontist, plus a mutual agreement between the patient and the two professionals as to the diagnosis and treatment plan. Proper objective assessments should be thoroughly communicated to the patient who is contemplating orthognathic surgical procedures; their understanding of the need for treatment is imperative. Certain treatments are likely to be more readily accepted than others.

When comparing Class II and Class III patients, the desire for functional and esthetic improvement is stronger with Class III patients. Class II occlusion is often functional, and patients rarely feel an urgent need for improvements. Patients can chew with posterior dentition in Class II occlusal relationship, and they can function with anterior dentition by simply positioning their mandibles anteriorly unless there are other compounding problems such as an anterior open bite, deep bite with gingival impingement on palatal tissue, etc. Malocclusions are often unnoticed by patients until their dentists inform them of the problem. Even then, patients may reject treatment, especially when surgical treatment is the only option. It is especially difficult for patients to accept invasive surgical treatment when they do not perceive the need for correction. However, there are circumstances where patients may be aware of an existing problem. One reason for Class II patients to seek treatment may be an excessively traumatic over-bite as with a Class II Division 2 occlusal relationship. Excessive wear and chipping of incisors may alert the patient to the need for treatment. These patients may also experience painful palatal tissue damage caused by gingival impingement from extruded lower incisors. Visual damage to anterior dentition and pain can motivate patients to accept the surgical treatment if this is the only possible option. Machado et al.<sup>4-6</sup> illustrated that the esthetic zone is focused in the area of maxillary central incisors, and they play a major role in smile esthetics. Excessive overjet in the case of Class II Division 1 can be another reason for a patient to seek treatment. In this case, the patients may have esthetic concerns or they may have had traumatic experiences with flared incisors. Unsatisfactory self-image and damage to anterior dentition can be potent motivators for patients to seek orthognathic treatment.

In either of the Class II cases, the main reason for seeking orthognathic surgical treatment may be an unsatisfactory facial profile with a severe retrognathic mandible. However, the majority of less severe Class II patients are considered to have acceptable appearance. Despite the fact that surgical treatment may be recommended by dental specialists and indicated by cephalometric measurements, the patient's self-perception of their profile are more important factors in their decision regarding surgical correction.<sup>3</sup>

On the other hand, Class III patients may have functional difficulties when anterior crossbite exists, and patients may experience excessive wear and chipping of the incisors when they are in an edge-to-edge relationship. Class III patients generally are well aware of their facial disharmony, and socially they are considered to be unattractive. Epidemiological analysis of orthognathic surgery in a hospital in Curitiba, Brazil, reviewed 195 cases, and mandibular setback was the intervention most frequently performed.<sup>7</sup> Johnston et al.<sup>8</sup> explored the self-perception of dentofacial attractiveness among patients requiring orthognathic surgery, and reported that concerns and awareness about facial profile were more pronounced among Class III patients while severe Class II patients exhibited lower levels of happiness with their dental appearance. It is more likely for Class III patients to pursue surgical treatment than Class II patients. Even in these Class III patients, laypersons are less critical in their evaluation of their profiles than were orthodontists according to Fabré et al.<sup>9</sup> Surgical treatment for Class III requires careful persuasion from the orthodontist and surgeon.

Vertical problems can coexist in both Class II and Class III patients, and high angles combined with facial concavity are negatively perceived by laypersons.<sup>9</sup> A "long face" or "short faced" is often considered unattractive. Regardless of the true severity of existing functional problems, the patient's perception is the main factor in accepting orthognathic surgical treatment. Unsatisfactory self-image, pain, and damage to teeth within the esthetic zone often have more impact in decision-making than the actual malocclusion.

### **Pre-surgical orthodontics**

This phase of the treatment can often be difficult for the patient to endure both functionally and

esthetically. In preparation for surgery, decompensation of the dentition is a necessary step in order to ensure that an adequate amount of surgical movement is possible. This procedure helps in producing a precisely desired final outcome. However, this process almost always produces a more severe malocclusion and worsening of facial esthetics. The patient's occlusion often becomes gradually worse as dentition moves to a more optimal position within each jaw, not necessary coordinating well with opposing counterparts. The treatment can take more than one year, and orthodontic movement can be difficult when battling an adverse functional environment. Psychologically preparing the patient for these negative changes prior to orthodontic decompensation can help in reducing anxiety and uncertainty the patient may have to endure during the decompensatory period. Even with this prior knowledge, these changes can adversely affect daily functions and cause significant distress.

In order to avoid the negative impact associated with this part of the treatment, some have promoted a surgery-first procedure in recent years.<sup>10,11</sup> The obvious advantages are a short preparation period and a subsequently shorter total treatment duration, rapid creation of a favorable functional environment for orthodontic movement, and psycho-social benefits. This procedure provides a decisive advantage over the traditional approach for the patient's psychology. Unlike conventional pre-surgical orthodontic preparation where the patient's facial appearance often suffers negative changes, this procedure instantly improves facial esthetics. It also reduces the pre-surgical anticipation period during which time patients often experience increasing anxiety due to a worsening of myofascial functions and facial esthetics. These advantages have made the surgery-first approach increasingly popular, and this new technique is being accepted by mainstream orthodontic disciplines.

However, there are some inherent disadvantages with this approach. Without proper orthodontic decompensation prior to surgery, it is challenging to match dentition during surgery, especially when dental alignment does not coordinate well between two arches. Since dental decompensation must be carried out after surgery, an accurate wafer fabrication based on a precise prediction of postsurgical orthodontic

movement is critical for a successful result. The magnitude of surgery required for the best skeletal harmony can be easily underestimated, because the position where teeth fit best generally does not produce an optimal jaw position without pre-surgical orthodontic decompensation. Careful surgical planning for a proper jaw position that allows for adequate postoperative orthodontic decompensation is crucial for the success of this approach.

This technique is favorable for cases requiring a mild to moderate amount of dental decompensation, but it is not as good for cases requiring major postoperative orthodontic movement.<sup>12,13</sup> More precise estimation of the jaw position and postoperative dental decompensations are necessary for these cases, and the results are not as predictable. Although this technique has significant advantage in pre-surgical management of patient psychology, it can lead to patient dissatisfaction after the surgery when an optimal result is not achieved. Communicating the limitations and setting a realistic treatment goal with the patient at this stage is critically important for achieving patient's satisfaction after the surgical procedure. Although it is difficult, accurate prediction of surgical outcome can aid in ensuring patient satisfaction.

### **Orthognathic surgery**

Any surgical experience can be nerve-racking, and some patients can experience significantly increased anxiety as the surgery date approaches. After a long drawn-out preoperative orthodontic treatment, patients may have mixed emotions: a desire to complete the surgery promptly but fear of postoperative morbidity. As the oral surgeon prepares the patient for surgery, the potential surgical complications should be thoroughly discussed days before the operation. At this time the patient must sign an informed consent form which describes the risks related to orthognathic surgery. The consent form is designed to not only inform patients but also to relieve the potential liability for surgeons should they fail to inform patients of the risk. At this point, some patients may have such heightened anxiety that they get "cold feet" and postpone the scheduled procedure. Bertolini et al.<sup>14</sup> measured the level of pre-surgical anxiety by self-administered questionnaires and reported that all patients experience a medium-to-high level of pre-surgical anxiety. This is generally a temporary

emotional turmoil, and any long-term impact after surgery is uncommon.

Additional assurance and support from the surgeon and orthodontist can significantly alleviate this anxiety. The preoperative explanation of surgical steps in detail is of paramount importance in strengthening the patient's faith in the surgical team and subsequently reducing anxiety and distress.<sup>15</sup> Open communication with the patient can build trust and rapport between them and the two professionals. Besides a technical explanation of the procedures, a discussion of emotional experience dealing with the facial and functional changes and postoperative recovery is recommended. Additional support from family members, friends, and other patients can also help, especially from those who have undergone similar experiences. In the study conducted by Türker et al.,<sup>15</sup> patients who talked to other patients who had previously been through surgery were better prepared for it. Patients who have experienced surgery are generally enthusiastic about sharing their experiences, so creating a patient support group may be valuable in assisting patients to overcome preoperative fear.

### Postsurgical orthodontics

Although the vast majority of patients are satisfied with surgical results, dissatisfaction, when it does occur, is largely associated with unanticipated postsurgical events.<sup>16</sup> Leading the list of contributing factors would be unrealistic expectations, lack of emotional preparation, insufficient explanation of the surgical experience, poor mechanisms for coping with stress, significant pain, and inadequate support from others.<sup>17-19</sup> The importance of effective preoperative communication and preparation of patients cannot be over emphasized. When patients and families are better informed, postsurgical adjustment becomes easier and they are more likely to have a realistic expectation of the surgical outcome. Visual aids and honest communication can be helpful in establishing realistic goals and reducing false expectations. Türker et al.<sup>15</sup> reported that an explanation of the treatment steps and postoperative consequences prepares patients for surgery and increases their satisfaction with the surgical outcome. During the recovery period, assurance, and support from family and friends

are also valuable, especially when patients experience unusual levels of distress or have difficulty accepting the postsurgical changes.

Drastic facial changes can be alarming to the patient and family if potential changes were not relayed adequately, or if the results did not meet the patient's expectations. Properly executed treatment prediction has to be communicated prior to surgery in order to avoid this complication. The postoperative adaptation of patients to the changes in facial morphology and function takes time, even after the predicted outcome has been achieved. Psychological preparation minimizes this difficulty in coping with the postoperative body image and surgical distress during the recovery period. As postsurgical facial swelling and other morbidities dissipate over time, most patients become acclimated with the changes and generally become satisfied with the results.

Postsurgical discomfort, pain, paresthesia plus interpersonal, and oral function problems were correlated with the patient's postsurgery emotional state. Postoperative pain can increase the dissatisfaction and anxiety level of patients.<sup>20</sup> Generally, two-jaw operations precipitate more pain complaints than single-arch procedures. Maxillary surgical procedures may produce fewer complaints of severe pain than mandibular procedures, but this advantage can be off-set by complaints of breathing difficulty and sinus problems.<sup>21</sup> The common complications or problems in the sequence of postoperative healing such as facial edema, pain, and paresthesia should be discussed preoperatively in order to prepare the patients to handle such events without distress. Postoperative distress disappears gradually with the onset of successful healing, and patients tend to forget postoperative pain over time.<sup>15</sup> As patients recover from surgical trauma, enhancement in self-image is common, reflected by improvement in psychological status, body, and facial images, self-confidence, and interpersonal relationships. These positive changes eventually lead to remarkable satisfaction with the surgical outcome through enhancing social adjustment, self-confidence, and social life.

### Interaction between surgeons and orthodontists

It is known that psychological factors between the orthodontist and surgeon come into play during



planning stages of surgical treatment, but the actual impact of this relationship has not been closely studied. While it seems logical to assume that both parties would participate equally in treatment planning and patient follow up, this may not be the case in reality. One party may be more dominant in various aspects of patient care so the decision-making process can be rather lopsided. Other than clinical skills, the personality traits of providers may play a significant role in choosing a partner. Generally, the orthodontist spends significantly more time with the patient throughout the treatment and therefore has opportunity to form a close, trusting relationship. Communicating the orthodontist's full confidence in the surgeon to patients can greatly help establishing a similar trusting relationship between patient and surgeon. However, there may be disagreements between the two doctors regarding the treatment approach, and these issues need to be carefully sorted out. In case an agreement cannot be reached, it may be best to find another provider who might have a more comparable treatment philosophy. It is imperative for the two providers to be in sync with both their personal relationship and treatment approach. This intricate balance and teamwork are essential parts in achieving success. Establishing a good network of providers who are mutually comfortable in their working relationship is important. According to El Deeb et al.,<sup>22</sup> one of the most important factors in achieving success in orthognathic surgery is good communication between the oral/maxillofacial surgeon, orthodontist, and patient. A close trusting relationship between all parties is essential for proper patient care.

## Conclusion

The treatment plan should align with the patient's perception and expectations. If there is a significant difference, it should be resolved before proceeding further. The patient's pre-surgical anxiety can be reduced significantly by thoroughly explaining the surgical process with additional assurance, utilizing a patient support group and, where appropriate, adopting the surgery-first approach. Adaptation of facial changes after surgery may take time, and additional support can play a major role in eventual emotional recovery. Postsurgical morbidity can

also cause initial dissatisfaction but will be largely forgotten as the patient recovers.

The relationship between surgeon and orthodontist can be tricky. Since any friction or disharmony would be detrimental to the patient's confidence and trust, there must be mutual respect and a good working relationship with close collaboration between them. This is critical to a successful outcome.

## References

1. Miguel JA, Palomares NB, Feu D. Life-quality of orthognathic surgery patients: the search for an integral diagnosis. *Dental Press J Orthod.* 2014;19:123–137.
2. Ryan FS, Barnard M, Cunningham SJ. What are orthognathic patients' expectations of treatment outcome—a qualitative study. *J Oral Maxillofac Surg.* 2012;70:2648–2655.
3. Bell R, Kiyak HA, Joondeph DR, et al. Perceptions of facial profile and their influence on the decision to undergo orthognathic surgery. *Am J Orthod.* 1985;88:323–332.
4. Machado AW. 10 commandments of smile esthetics. *Dental Press J Orthod.* 2014;19:136–157.
5. Machado AW, Moon W, Gandini LG Jr. Influence of maxillary incisor edge asymmetries on the perception of smile esthetics among orthodontists and laypersons. *Am J Orthod Dentofacial Orthop.* 2013;143:658–664.
6. Machado AW, McComb RW, Moon W, et al. Influence of the vertical position of maxillary central incisors on the perception of smile esthetics among orthodontists and laypersons. *J Esthet Restor Dent.* 2013;25:392–401.
7. Scariot R, João da Costa D, Rebellato NLB, et al. Epidemiological analysis of orthognathic surgery in a hospital in Curitiba, Brazil: review of 195 cases. *Revista Española Cirugía Oral Maxilofac.* 2010;32:147–151.
8. Johnston C, Hunt O, Burden D, et al. Self-perception of dentofacial attractiveness among patients requiring orthognathic surgery. *Angle Orthod.* 2010;80:361–366.
9. Fabr e M, Mossaz C, Christou P, et al. Orthodontists' and laypersons' aesthetic assessment of Class III subjects referred for orthognathic surgery. *Eur J Orthod.* 2009;31:443–448.
10. Liou EJ, Chen PH, Wang YC, et al. Surgery-first accelerated orthognathic surgery: orthodontic guidelines and setup for model surgery. *J Oral Maxillofac Surg.* 2011;69:771–780.
11. Sharma VK, Yadav K, Tandon P. An overview of surgery-first approach: recent advances in orthognathic surgery. *J Orthod Sci.* 2015;4:9–12.
12. Hern andez-Alfaro F, Guijarro-Mart nez R, Peir o-Guijarro MA. Surgery first in orthognathic surgery: what have we learned? A comprehensive workflow based on 45 consecutive cases *J Oral Maxillofac Surg.* 2014;72:376–390.
13. Leelasinjaroen P, Godfrey K, Manosudprasit M, et al. Surgery first orthognathic approach for skeletal Class III malocclusion corrections—a literature review. *J Med Assoc Thai.* 2012;95:172–180.



14. Bertolini F, Russo V, Sansebastiano G. Pre- and postsurgical psycho-emotional aspects of the orthognathic surgical patients. *Int J Adult Orthodon Orthognath Surg.* 2000;15:16–23.
15. Türker N, Varol A, Ögel K, et al. Perceptions of preoperative expectations and postoperative outcomes from orthognathic surgery: Part I: Turkish female patients. *Int J Oral Maxillofac Surg.* 2008;31:710–715.
16. Lazaridou-Terzoudi T, Kiyak HA, Moore R, et al. Long-term assessment of psychologic outcomes of orthognathic surgery. *J Oral Maxillofac Surg.* 2003;61:545–552.
17. Cunningham SJ, Hunt NP. A comparison of health state utilities for dentofacial deformity as derived from patients and members of the general public. *Eur J Orthod.* 2000;22:335–342.
18. Kiyak HA, McNeill RW, West RA, et al. Personality characteristics as predictors and sequelae of surgical and conventional orthodontics. *Am J Orthod.* 1986;89:383–392.
19. Maslach C, Jackson SE, Leiter MP. *Maslach Burnout Inventory.* (3rd ed.). Consulting Psychologists Press, Palo Alto, CA, 1996.
20. Kiyak HA, McNeill RW, West RA. The emotional impact of orthognathic surgery and conventional orthodontics. *Am J Orthod.* 1985;88:224–234.
21. Flanary CM, Barnwell GM, Alexander FJM. Patient perceptions of orthognathic surgery. *Am J Orthod.* 1985;88:137–145.
22. El Deeb M, Wolford L, Bevis R. Complications of orthognathic surgery. *Clin Plast Surg.* 1989;16:825–840.

---

# The airway implications in treatment planning two-jaw orthognathic surgery: The impact on minimum cross-sectional area

Jarom E. Maurer, Steven M. Sullivan, G. Frans Currier, Onur Kadioglu, and Ji Li

**The impact of orthognathic surgery on the pharyngeal airway supported by cone-beam computed tomography (CBCT) technology has been the topic of many recent studies. The minimum cross-sectional area (MCA) has also been evaluated but not with respect to vertical position changes of the MCA with movement of the facial skeleton. Vertical position changes and shape changes of 71 patients after orthognathic treatment of Class II and Class III malocclusions were evaluated with CBCT images and Invivo5 software. The vertical changes were found not to be significant for Class II and Class III patients (5.0 mm and 0.2 mm respectively,  $p = 0.31$ ). In addition, the vertical changes of the MCA with individual skeletal movement were also not significant. The shape changes were not consistent relative to individual Angle classification. Vertical changes of the MCA after orthognathic surgery could not be associated with Angle's classification or skeletal movement while shape changes were not predictable. Orthognathic surgical planning is a complex process in which the patient's occlusion, facial balance, and harmony are considered. The purpose of this article is to provide surgical insight into obtaining the best possible results when considering the multifactorial nature of orthognathic surgical treatment planning. Original research on the changes in MCA will be presented. (Semin Orthod 2016; 22:18–26.) © 2016 Elsevier Inc. All rights reserved.**

## Introduction

Advances and availability of cone-beam computed tomography (CBCT) imaging and related software have allowed for the pharyngeal airway to be accurately evaluated. Several software programs are capable of measuring both volume and minimum cross-sectional area (MCA). In addition, several studies<sup>1–3</sup> have shown the accuracy of the volumetric airway measurements as well as the accuracy of the software in evaluating the MCA. It has been shown that changes in the pharyngeal airways are

difficult to quantify using conventional two- and three-dimensional images. Lateral cephalograms do not capture the changes in the lateral airway that can be seen with CBCT imaging.<sup>4</sup> Gonçalves et al.<sup>5</sup> demonstrated an increase in the lateral dimension of the airway at three separate vertical points with maxillary advancement, mandibular advancement, and maxillomandibular advancement. Interestingly, the maxillary advancement group with mandibular setback also demonstrated an increase in the lateral dimensions of the airway at the vertical position of the posterior nasal spine and vellicula with a small decrease in lateral dimension at the uvula.

Other studies<sup>2,4,6–8</sup> have looked at the volumetric changes associated with orthognathic surgery utilizing existing software programs and have found that there are predictable volumetric increases or decreases of the pharyngeal airway, depending upon the type of movement that was performed surgically. A more recent study<sup>9</sup> has evaluated the changes in airway volume after orthognathic surgery as it relates to specific

---

*Private Practice, 835 3rd Ave SE, Cedar Rapids, IA; Department of Oral and Maxillofacial Surgery, University of Oklahoma, Oklahoma City, OK; Department of Orthodontics, University of Oklahoma, Oklahoma City, OK; Department of Biostatistics and Epidemiology, University of Oklahoma, Oklahoma City, OK.*

*Address correspondence to Jarom Maurer, DMD, Private Practice, 835 3rd Ave SE, Cedar Rapids, IA 52403. E-mail: jarom@eiofs.com*

© 2016 Elsevier Inc. All rights reserved.

1073-8746/12/1801-\$30.00/0

<http://dx.doi.org/10.1053/j.sodo.2015.10.004>

skeletal movement, with certain movement in the horizontal mandible and vertical position of the posterior nasal spine (PNS) causing significant differences in airway volume and MCA.

Similarly, there have been numerous publications<sup>10–13</sup> concerning both the position of the MCA and the changes in area following orthognathic surgery. However, the vertical position of the MCA has not been evaluated with respect to the millimetric skeletal changes with orthognathic surgery. Such evaluation is important because airway obstruction tends to occur at two vertical areas, either at the level of the soft palate or at the tongue base.<sup>13,14</sup> If specific skeletal movement changes are found to predict the vertical position of the MCA, the orthodontic setup and surgical movement can be planned to improve upon or at least minimize negative effects on the airway.

## Materials and methods

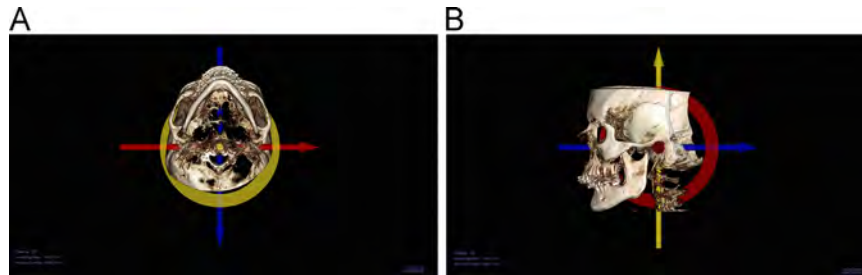
IRB approval was obtained from the University of Oklahoma (OU). The patient pool obtained from the OU Oral and Maxillofacial Surgery Department used in this study was also used in a recently published article on the pharyngeal airway and orthognathic surgery.<sup>9</sup> This retrospective study included 71 total subjects that met the inclusion criteria of 35 Class II patients and 36 Class III patients as determined cephalometrically. The patients' preoperative lateral cephalograms were used for classification. Class II patients had positive overjet and ANB and Class II posterior buccal segments. Class III patients had negative overjet and ANB and Class III posterior buccal segments. Positive overjet was defined as the anterior maxillary dentition anterior to the mandibular anterior dentition and negative overjet defined as the mandibular anterior dentition anterior to the maxillary anterior dentition. Class II buccal segments were defined as any maxillary molar position anterior to a Class I designation. Class III buccal segments were defined as the maxillary molar position posterior to a Class I designation. The average age of the 31 male and 40 female patients was 18 years 8 months. Preoperative and postoperative CBCT scans were taken on them after two-jaw orthognathic surgery using either an Iluma Ultra Cone Beam CT scanner (IMTEC, Ardmore, OK) with a  $19 \times 22 \text{ cm}^2$  field of view

and voxel size of 0.3 mm or a ProMax 3D CT scanner (Planmeca, Roselle, IL) with a field of view of  $17 \times 20 \text{ cm}^2$  and a voxel size of 0.2 mm. The images included the entire oropharynx, extending at least to the inferior border of C3. Exclusion factors included those without sufficient preoperative or postoperative records, open bites, craniofacial anomalies, and patients not in intercuspation at either time when the scans were made. The same surgeon performed the orthognathic surgery for all patients.

The postsurgical CBCT images were taken from 4 to 14 months postsurgery to allow for decrease of soft tissue inflammation. All scans were performed at 3.8 mA for 40 s at 120 kV (Iluma), or a variable 1–14 mA for 27 s at 90 kV (Planmeca). The patients were instructed to breathe lightly without swallowing while in maximum intercuspation with their head positions standardized (held in the Frankfort Horizontal (FH) plane, parallel to the floor) while they either sat (Iluma) or stood (Planmeca). The scans were reconstructed at 0.3 mm and exported in the Digital Imaging and Communications in Medicine (DICOM) format.

The DICOM files were then loaded into Invivo 5 software for evaluation. The same examiner performed all CBCT data analysis for bony measurements pre- and postoperatively,<sup>9</sup> and a second examiner performed the data analyses for measurement of MCA and vertical position of the MCA as well as changes in its shape. The patient's 3D images were oriented to FH utilizing the software's orientation widget. This served as a reference plane as previously described (Fig. 1).<sup>9</sup> Once oriented, skeletal measurements were performed. For the maxilla, Point A was measured vertically and horizontally. The transverse maxilla was measured from the inner most curvature as well as the vertical position of the PNS. The mandible included both horizontal and vertical measurements at Point D, which is the midpoint of the mandibular symphysis. Point D more accurately represents the vertical and sagittal movement of the bony chin than does Point B, which may not change with rotational movement of the mandible. For the nine patients that underwent genioplasty, Point B was used due to the difficulty in determining Point D after this procedure.

The airway volume measurement option in the Invivo software was used to calculate the MCA



**Figure 1.** (A) Submental view showing orientation through right and left porion and orbitale. (B) Left lateral view showing orientation through right and left porion and orbitale. (For interpretation of the references to color in this figure legend, the reader is referred to the web version of this article.)

(Fig. 2A). Vertical measurements from FH to the most superior limits of the MCA were then measured (Fig. 2B and C). A vertical reference plane perpendicular to FH at porion was used for anterior or posterior measurements. A positive value was assigned to any skeletal movement that was anterior or inferior while a negative value was assigned to skeletal movements posterior or superior. The superimposition option in the software provides simultaneous views of the axial, sagittal, and coronal sections of the CBCT as well as the three-dimensional skeleton and three-dimensional airway. It was used to scroll through the axial sections of the CBCT until the level of the MCA was reached in order to record the shape of the axial section of the airway (Fig. 3).

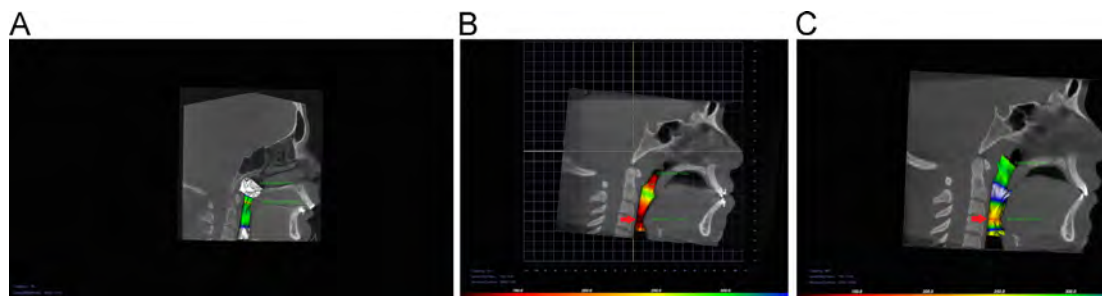
In order to evaluate potential error in the measurements of MCA and vertical position, 17 of the 71 patients were randomly selected and re-measured by the same examiner. The Dahlberg formula was used to obtain an intra-rater correlation of 0.97 for the initial vertical position measurements from FH to the MCA and 0.99 for

the final vertical position of MCA to FH (Table 1).

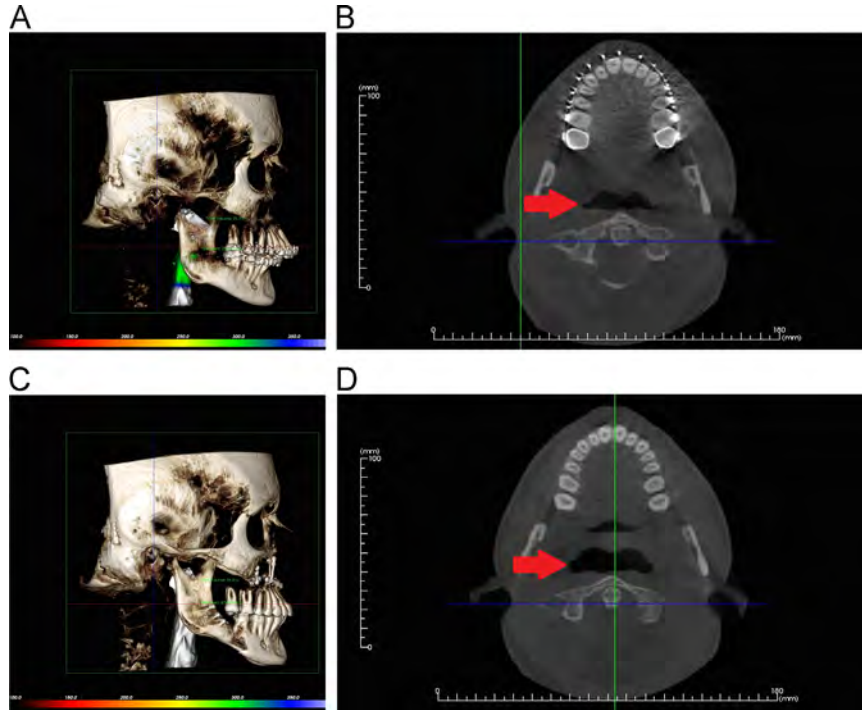
## Results

The MCA vertical position changes were not found to be statistically significant in pre- and postoperative pooled data (Table 2). Similarly, there were no statistically significant differences in the MCA vertical positions when the Class II and Class III patients were separated (Table 3). Also, there were no significant changes in vertical position of the MCA as related to changes in bony skeletal position pre- and postoperatively (Table 4).

The vertical position changed in 68 of the 71 subjects postoperatively, but none of the evaluated data showed statistical significance. A wide range was noted in the vertical position from FH of the MCA from 16.2 mm to 87.0 mm with a mean of 58.6 mm in the postsurgical sample (Table 2). This was expected considering the anatomical differences in male and female patients, their skeletal classification, and their



**Figure 2.** (A) Generated lateral cephalogram from 3D CBCT with airway volume and minimum cross-sectional area defined. (B) Vertical measurement from Frankfort Horizontal to the most superior aspect of the minimum cross-sectional area (MCA—red arrow). (C) Class III patient showing an increase in the MCA (red arrow) after two-jaw orthognathic surgery. (For interpretation of the references to color in this figure legend, the reader is referred to the web version of this article.)



**Figure 3.** (A) The superimposition tab of Invivo5 software was used to locate the minimum cross-sectional area. (B) Axial view of the MCA (red arrow). (C) Class II patient after counterclockwise rotation with mandibular advancement. (D) Axial view showing MCA (red arrow) change compared to (B). (For interpretation of the references to color in this figure legend, the reader is referred to the web version of this article.)

ages. The mean change for the entire sample was 2.6 mm with a large standard deviation of 17.1 mm. There was no statistical significance associated with any skeletal movement in the vertical position of the MCA which is consistent with the findings of other authors<sup>8,10</sup> (Table 4).

The shapes were also evaluated. For orientation, the shape of the MCA in the axial section was termed either circular or ovoid lateral. A total of 20 of the 71 patients had a clearly visible shape change postoperatively (Fig. 4); 14 of the 20 had a preoperative ovoid lateral shape

that became more circular in appearance while six changed from more circular to more ovoid lateral. Of all, nine of the patients exhibiting shape changes were Class II while the remaining patients were Class III.

**Discussion**

The Class II patients had an average vertical change of 5.0 mm in the MCA position while the Class III patients exhibited an average change of only 0.2 mm (Table 3). Although these values were not statistically significant, it did show that

**Table 1.** Measurement error.

Measurement time	N	Dahlberg's measurement error	Intra-rater correlation
Vertical MCA initial	17	2.291	0.97
Vertical MCA final	17	0.998	0.99

Dahlberg's formula,  $S = \sqrt{\sum \frac{d^2}{2n}}$  was used to calculate the error of measurement with  $d$  as the difference between the first and the second measures. Intra-rater correlation was also calculated.

**Table 2.** Summary statistics for MCA-pooled groups (units: mm).

Variable	N	Minimum	Maximum	Mean	Median	SD
Vertical MCA initial	71	16.22	83.46	56.03	59.03	16.82
Vertical MCA final	71	16.16	87.04	58.59	63.22	17.09
Vertical MCA change	71	-61.72	48.10	2.56	1.92	20.13

Negative value denotes superior change while positive an inferior change.

**Table 3.** ANOVA analysis to compare the means between Class II and Class III (units: mm).

<i>Variable</i>	<i>Class</i>	<i>N</i>	<i>Minimum</i>	<i>Maximum</i>	<i>Mean</i>	<i>Median</i>	<i>SD</i>	<i>p Value</i>
Vertical MCA initial	II	35	20.51	83.46	53.80	53.36	14.18	0.2740
	III	36	16.22	83.18	58.20	64.69	18.99	
Vertical MCA final	II	35	16.16	80.17	58.80	65.00	16.87	0.9201
	III	36	18.77	87.04	58.39	63.05	17.54	
Vertical MCA change	II	35	-51.17	48.10	5.00	3.50	20.57	0.3179
	III	36	-61.72	47.17	0.19	0.80	19.69	

There were no significant differences between Class II and Class III patterns relative to mean initial, final, and changes in the vertical position of the MCA.

the vertical position was more variable with Class II patients after surgery. The MCA in Class III patients tended to basically remain in the same position despite a mandibular setback, which conceptually could cause dorsal repositioning of the tongue base, leading to obstruction.<sup>15</sup> The surgical movement of Class III patients was done with the airway in mind, which may account for the relatively unchanged position of their MCA.

With regard to shape, one might expect changes from ovoid lateral to more circular with Class II mandibular advancements and vice versa for a Class III mandibular setback as the lateral soft tissues of the pharyngeal airway are advanced or allowed to relax. In fact, the opposite was found in this study where improvement was seen in the lateral dimension of the airway in some Class II patients, which is similar to finding by Gonçalves et al.<sup>5</sup> who showed increases in the lateral dimension of the airway in mandibular and maxillary advancements (Fig. 3B and D). This finding emphasizes that the collapsing and dilating forces of the airway are complex dynamic forces that are not yet fully understood. In this study, we did visualize changes in the lateral and anterior posterior dimension, but the shapes did not transition from ovoid lateral to round or vice versa in most cases. These shape changes at the

same vertical position as measured from FH pre- and postoperatively were not evaluated as our interest was in evaluating the changes in shape of the MCA, regardless of the vertical position.

Further studies are needed to evaluate the airflow dynamics of these patients in order to determine if there is a clinical significance associated with the vertical position of the MCA. The information provided here, as well as the recent emphasis on the evaluation of airways, should guide both the orthodontist and the surgeon when planning orthognathic cases.

One limitation of this study, as well as all other airway studies based on CBCT scans, is the potential for normal day-to-day variations in soft tissue. Also due to the wide spread in the gathered data, a larger patient pool is necessary to detect significant findings in vertical position.

### Surgical planning considerations

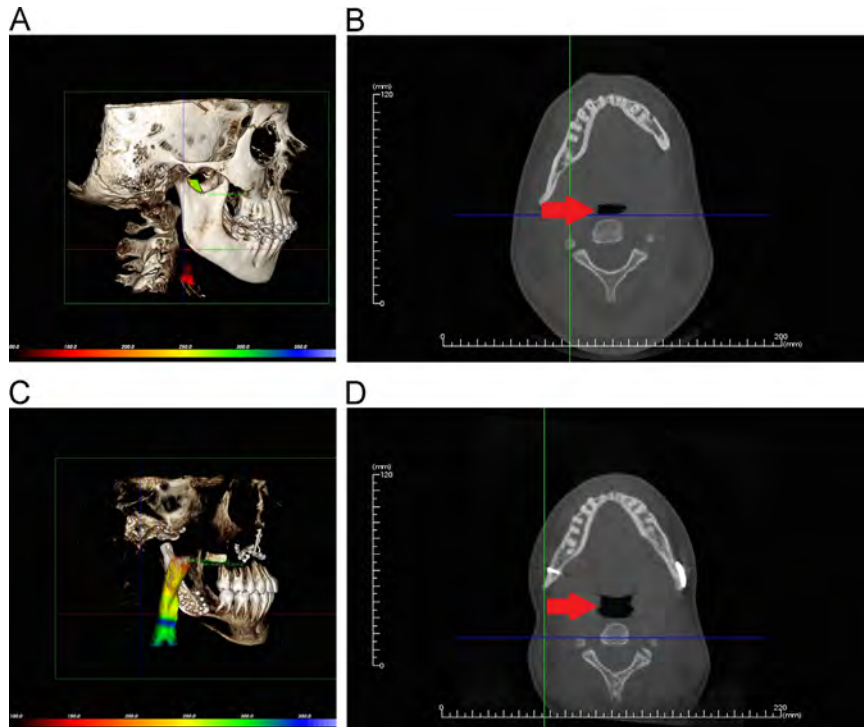
Research has shown that anterior movement with orthognathic surgery produces an improvement in the pharyngeal airway volume while posterior movement generally results in a negative effect on the airway.<sup>5,9</sup> Surgical design should incorporate an airway evaluation to mitigate or reduce any negative impact on the pharyngeal airway in

**Table 4.** Univariate analysis for pooled sample on MCA changes (units: mm).

<i>Dependent</i>	<i>Parameter</i>		<i>Estimate</i>	<i>Standard error</i>	<i>p Value</i>
Vertical MCA change	Vertical	A Point change	-0.42	1.25	0.7372
		D Point change	-0.53	0.83	0.5303
		PNS change	1.28	0.88	0.1509
	Sagittal	A Point change	-0.17	0.93	0.8513
		D Point change	0.32	0.44	0.4614
	Transverse	Maxillary change	-1.51	1.09	0.1695

For pooled data (Class II and Class III), there were no associations among any of the parameters. Negative value denotes superior change while positive an inferior change.





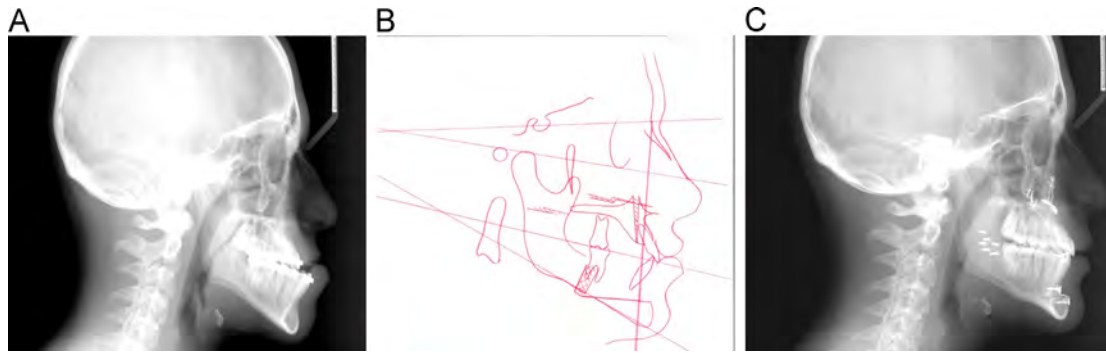**Figure 4.** (A) Preoperative airway. (B) Axial view highlighting the shape of the MCA (red arrow). (C) Post-operative airway. (D) Axial view highlighting the shape change of the MCA (red arrow) compared to (B). (For interpretation of the references to color in this figure legend, the reader is referred to the web version of this article.)

mandibular setback and improve the volume and MCA in advancement cases. The airway evaluation is vital in the planning phase as it can loosely be described as a cylinder with collapsing and dilating forces acting on it at all times.<sup>14</sup> A smaller diameter airway predisposes collapse more so than with a larger diameter airway.

Many anatomic features impact the pharyngeal airway such as angle orthodontic classification, tongue size, mandibular plane angle, elongation of the soft palate, and inferior hyoid position. They should be considered during the preoperative airway evaluation.<sup>8,11,16</sup> Conditions relative to the existing skeletal classification can also contribute to a patient's airway dimensions as shown by Muto et al.,<sup>13</sup> who concluded that the tongue base and uvula as measured to posterior pharyngeal wall vary in the different classification of patients depending on their posture.

Several authors<sup>12,15,17</sup> have evaluated the changes in skeletal position of the mandible and maxilla and their impact on the airway utilizing sleep studies. Sittitavornwong et al.<sup>17</sup> provided

data showing that increased airway cross-sectional area has a significant improvement in apnea hypopnea index (AHI) correlating the data with a decreased laminar and turbulent flow. Foltan et al.<sup>15</sup> reported improvements in obstructive apnea, respiratory disturbance index and oxygen desaturation index with mandibular advancement. Mandibular setback coupled with maxillary advancement had a negative effect in these same areas. The authors concluded that dorsal positioning of the tongue base was the likely cause of the negative impact on the evaluated sleep study parameters. Van Holsbeke et al.<sup>12</sup> studied patients with sleep apnea pre- and postmandibular advancement via an anterior positioning appliance and concluded the increases in MCA were the best predictor of decreases in resistance of the airway. Furthermore, they stated that patients without baseline obstruction of the airway responded better to mandibular advancement than those with baseline airway obstruction. Lastly, when the MCA was near the tongue base, there was an increased chance of obstruction.



**Figure 5.** (A) Preoperative lateral cephalogram of Class III patient. (B) Surgical treatment objective tracing showing counterclockwise rotation with limited mandibular setback. (C) Postoperative lateral cephalogram of the same patient with counterclockwise rotation.

### Considerations in Class II patients

In treatment planning for Class II patients, one can expect that there will be an increase in the volumetric dimensions of the pharyngeal airway as well as the MCA. However, it is not possible to predict the change in vertical position. In order to amplify the mandibular move, a counterclockwise rotation should be planned. This counterclockwise, maxillary movement will produce a far more accentuated mandibular movement along with proper correction of the occlusal plane than with traditional, linear orthognathic movement and thus have a greater effect on the airway.<sup>9</sup> The anterior mandibular move could be further increased by increasing the overjet through removal of permanent teeth in the mandible during presurgical orthodontic treatment. For anterior maxillary impaction cases, the rotation point may be placed around the anterior nasal spine (ANS), maxillary incisal edge, or between the posterior nasal spine (PNS) and ANS. Stability of orthognathic movement has greatly increased with the use of rigid fixation although some relapse can be expected.<sup>18</sup> Goncalves et al.<sup>19</sup> showed that an increase in pharyngeal volume produced after counterclockwise rotation and maxillomandibular advancement was stable long term in their study of 56 cases. Reyneke et al.<sup>20</sup> demonstrated that the stability of the mandible in counterclockwise movement is similar to stability in conventional linear movement long term (6–60 months) with the differences in relapse between the counterclockwise group and the conventional movements being insignificant.

Maxillary orthognathic movement also affects the airway. Several studies<sup>6,9,21</sup> evaluated the vertical position of PNS or uvula and found that as nasopharynx volume increased, it did so at the expense of the total and oropharyngeal volume. Hart et al.<sup>9</sup> found for every one millimeter of inferior movement of PNS, the total airway decreased by 459.2 mm<sup>3</sup> regardless of classification and it produced a 10.6 mm<sup>2</sup> decrease of the MCA. With this in mind, when planning the limits of maxillary movement, one needs to evaluate the airway and determine if the counterclockwise rotation will benefit the patient as with Class II patients or have a deleterious effect on the airway as with some Class III patients.

### Considerations in Class III patients

With regards to the pharyngeal airway, Class III patients also benefit from two-jaw orthognathic surgery with counterclockwise rotation. As Hart et al.<sup>9</sup> demonstrated, one should expect a specific volumetric change with every one millimeter of posterior movement of Point D. Their study also showed that the MCA decreased by 15.45 units for every one millimeter of inferior vertical change at D. The current study showed that the vertical position of the MCA from FH did not significantly change in Class III patients (Table 3) because changes in vertical position were only 0.2 mm in this group. This showed that the positions of the mandible and maxilla changed in such a way as to keep the tissues adjacent to the MCA in essentially the same place. In planning for Class III patients, the goal is to avoid decreases in the pharyngeal airway which may

lead to problems with collapse of the airway and sleep apnea.<sup>22,23</sup> The counterclockwise rotation of the maxilla coupled with a maxillary advancement can help to maintain the anterior and vertical positions of pogonion, even with a mandibular setback, thus eliminating significant decreases in the airway (Fig. 5).

In the Hart et al. study,<sup>9</sup> the mean changes of the MCA for the Class III patients showed a mean decrease of only 10.6 mm<sup>2</sup> (209.2 preoperatively, 198.6 postoperatively) which was not found to be statistically significant. There was also an increase of MCA in 19 of the 36 Class III patients (Fig. 2C) while the same patient pool showed a total increase in the pharyngeal airway in only 14 of the 36 patients. This showed that although the total pharyngeal volume may decrease, the MCA will not in Class III patients.<sup>9</sup>

Keep in mind that all patients in the current study and in Hart et al.<sup>9</sup> underwent two-jaw surgery for correction of the dentoskeletal relationships. Hong et al.<sup>15</sup> showed that the decreases in pharyngeal volume and MCA with mandibular setback surgery were greater when treating only the mandible. When treating both jaws in Class III patients, as outlined, some of the decreases in the airway volume and MCA are negated.

## Summary

The MCA undoubtedly changes with orthognathic movement. The Class II and Class III patients did not show any significant changes in vertical position of the MCA when comparing pre- and postoperative images, and the changes in vertical position did not significantly reflect any specific skeletal movement. The large variability in the data likely accounted for the lack of statistical significance. Although the shape of the airway at the MCA did change with surgical movement, it did not do so consistently in the Class II or Class III patients and changes in shape could not be predicted based on the surgical movement. It is the orthodontist and surgeon's responsibility to achieve the best dental and skeletal results while preventing, or minimizing, any iatrogenic effects on the airway. This study provides some insight into the effects of surgical movement on the MCA and the role the MCA plays on the patient's ventilation.

## References

1. Weissheimer A, Macedo de Menezes L, Smashima GT, et al. Imaging software accuracy for 3-dimensional analysis of the upper airway. *Am J Orthod Dentofacial Orthop.* 2012;142:801–813.
2. Ghoneima A, Kula K. Accuracy and reliability of cone-beam computed tomography for airway volume analysis. *Eur J Orthod.* 2011;35:256–261.
3. Guijarro-Mantinez R, Swennen GRJ. Cone-beam computerized tomography imaging and analysis of the upper airway: a systematic review of the literature. *Int J Oral Maxillofac Surg.* 2011;40:1227–1237.
4. Sears C, Miller AJ, Chang MK, et al. Comparison of pharyngeal airway changes on plain radiography and cone-beam computed tomography after orthognathic surgery. *J Oral Maxillofac Surg.* 2011;69:385–394.
5. Conçales ES, Duarte MAH, Palmieri C Jr, et al. Retrospective analysis of the effects of orthognathic surgery on the pharyngeal airway space. *J Oral Maxillofac Surg.* 2014;72:2227–2240.
6. Hatab NA, Konstantinovic VS, Mudrak JKH. Pharyngeal airway changes after mono-and bimaxillary surgery in skeletal Class III patients: cone-beam computed tomography evaluation. *J Craniomaxillofac Surg.* 2015;43:491–496.
7. Brunetto DP, Velasco L, Koerich L, et al. Prediction of 3-dimensional pharyngeal airway changes after orthognathic surgery: a preliminary study. *Am J Orthod Dentofacial Orthop.* 2014;146:299–309.
8. Valladares-Neto J, Silva MAG, Bumann A, et al. Effects of mandibular advancement surgery combined with minimal maxillary displacement on the volume and most restricted cross-sectional area of the pharyngeal airway. *Int J Oral Maxillofac Surg.* 2013;42:1437–1445.
9. Hart PS, McIntyre BP, Kadioglu O, et al. Postsurgical volumetric airway changes in 2-jaw orthognathic surgery patients. *Am J Orthod Dentofacial Orthop.* 2015;147:536–546.
10. Hong J, Oh K, Kim B, et al. Three-dimensional analysis of pharyngeal airway volume in adults with anterior position of the mandible. *Am J Orthod Dentofacial Orthop.* 2011;140:e161–e169.
11. Lenza MG, Lenza de O MM, Dalstra M, et al. An analysis of different approaches to the assessment of upper airway morphology: a CBCT study. *Orthod Craniofac Res.* 2010;13:96–105.
12. Van Holsbeke C, De Backer J, Vos W, et al. Anatomical and functional changes in the upper airways of sleep apnea patients due to mandibular repositioning: a large scale study. *J Biomech.* 2011;44:442–449.
13. Muto T, Yamazaki A, Takeda S. A cephalometric evaluation of the pharyngeal airway space in patients with mandibular retrognathia and prognathia, and normal subjects. *Int J Oral Maxillofac Surg.* 2008;37:228–231.
14. Susaria SM, Thomas RJ, Abramson ZR, et al. Biomechanics of the upper airway: changing concepts in the pathogenesis of obstructive sleep apnea. *Int J Oral Maxillofac Surg.* 2010;39:1149–1159.
15. Hong JS, Park YH, Kim YJ, et al. Three-dimensional changes in pharyngeal airway in skeletal class III patients undergoing orthognathic surgery. *J Oral Maxillofac Surg.* 2011;69:e401–e408.

16. Schendel SA, Jacobson R, Khalessi S. Airway growth and development: a computerized 3-dimensional analysis. *J Oral Maxillofac Surg.* 2012;70:2174–2183.
17. Sittitavornwong S, Waite PD, Shih AM, et al. Computational fluid dynamic analysis of the posterior airway space after maxillomandibular advancement for obstructive sleep apnea syndrome. *J Oral Maxillofac Surg.* 2013;71:1397–1405.
18. Proffit WR, Turvey TA, Phillips C. The hierarchy of stability and predictability in orthognathic surgery with rigid fixation: an update and extension. *Head Face Med.* 2007;3:21.
19. Goncalves JR, Buschang PH, Goncalves DG, et al. Post-surgical stability of oropharyngeal airway changes following counter-clockwise maxillo-mandibular advancement surgery. *J Oral Maxillofac Surg.* 2006;64:755–762.
20. Reyneke JP, Bryant RS, Suuronen R, et al. Postoperative skeletal stability following clockwise and counter-clockwise rotation of the maxillomandibular complex compared to conventional orthognathic treatment. *Br Oral Max Surg.* 2007;45:56–64.
21. Lee Y, Chun Y, Kang N, et al. Volumetric changes in the upper airway after bimaxillary surgery for skeletal Class III malocclusions: a case series study using 3-dimensional cone-beam computed tomography. *J Oral Maxillofac Surg.* 2012;70:2867–2875.
22. Mattos CT, Vilani GNL, Sant’Anna EF, et al. Effects of orthognathic surgery on oropharyngeal airway: a meta-analysis. *Int J Oral Maxillofac Surg.* 2011;40:1347–1356.
23. Foltan R, Hoffmannova J, Pavlikova G, et al. The influence of orthognathic surgery on ventilation during sleep. *Int J Oral Maxillofac Surg.* 2011;40:146–149.

---

# Surgical exposure of impacted canines: Open or closed surgery?

*Adrian Becker, Ioannis Zogakis, Ionut Luchian, and Stella Chaushu*

**The methods for exposing impacted canines are outlined and the relative merits of using a closed versus open surgical procedure are discussed in relation to the projected long-term prognosis and appearance of the treated outcome. These surgical modalities have a wide range of variations designed for individual circumstances, each of which has advantages in specific cases. Similarly, orthodontic biomechanic protocols vary depending on the 3-dimensional location of the impacted tooth in the maxilla. Each of these factors has an influence on the final outcome. Attempts to provide answers showing a preference for one surgical technique over another using a prospective randomized clinical trial would be difficult in the face of such a wide spectrum of factors. (Semin Orthod 2016; 22:27–33.) © 2016 Elsevier Inc. All rights reserved.**

## Introduction

When an oral surgeon and orthodontist are willing to work together as a team, impacted teeth may be successfully brought into ideal alignment and made completely indistinguishable from other, normally erupted teeth in the dentition.

Standard procedure today dictates that treatment of such cases begins with the orthodontist, and the initial goal is orthodontic alignment and leveling of the teeth in the dentition, followed by the creation of space in the dental arch to accommodate the impacted tooth. The orthodontist then consolidates and stabilizes the teeth in that jaw by placing a full thickness passive archwire in all the brackets, with the intent to create an anchorage unit including all the teeth. It is against this unit that the forces designed to reduce the impaction of the tooth will be pitted, and where necessary, the unit may be further buttressed with the addition of other anchor

elements such as intermaxillary elastic forces, extra-oral forces and temporary anchorage devices. At this point, the surgeon needs to be brought into the scene to provide unobstructed access to the impacted tooth.

Differences of opinion have arisen within the 2 specialties regarding the best method of surgical exposure to produce an overall favorable condition and prognosis at the completion of treatment.<sup>1,2</sup> Opinions are based on a prediction of the expected periodontal status of the outcome, the esthetics of gingival form and post-treatment orthodontic relapse of the achieved alignment.

The aims of the surgical phase of the orthodontic/surgical modality of treatment are:

- (1) to eliminate hard or soft tissue pathologic/obstructive entities,
- (2) to provide the orthodontist with access to the impacted tooth, including the creation of a suitably isolated micro-environment for the bonding of an attachment, and
- (3) to perform these tasks with minimum tissue damage, while avoiding exposure and instrumentation of the cemento-enamel junction (CEJ) and cervical portion of the root surface.

The most frequently impacted tooth considered for treatment with this conservative modality is the maxillary permanent canine and

---

*Department of Orthodontics, Hadassah Faculty of Dental Medicine, Hebrew University, Jerusalem, Israel; Department of Periodontology, Faculty of Dental Medicine, Grigore T. Popa University of Medicine and Pharmacy, Iasi, Romania.*

*Address correspondence to Adrian Becker, BDS, LDS, DDO, Department of Orthodontics, Hebrew University-Hadassah Faculty of Dental Medicine, P.O.B. 12272, Jerusalem 91120, Israel. E-mail: adrian.becker@mail.huji.ac.il*

© 2016 Elsevier Inc. All rights reserved.

1073-8746/12/1801-\$30.00/0

<http://dx.doi.org/10.1053/j.sodo.2015.10.005>



the ensuing discussion will largely be described in this context.

## Open-eruption techniques

The open-eruption technique is not limited to a single option, but includes 3 principal alternatives, each incorporating minor variants: (1) window technique, (2) full flap open procedure, and (3) Apically repositioned flap technique.

### *Window technique*

This represents the simplest form of open exposure. It entails the surgical removal of the mucosa and bone immediately overlying the impacted tooth.<sup>3,4</sup> It is the most direct way of exposing an impacted canine that is located and usually palpable immediately under the surface. With a very superficially located labial tooth, this procedure can sometimes be accomplished by using only topical anesthesia in the form of anesthetic spray.

In contrast, the usually palpable, palatally impacted canine is covered by thick mucosa, bone, and follicle. As such, it is at least 5–7 mm beneath the surface and considerably more when there is follicular enlargement or when the tooth is more grossly displaced. The surgical removal of a circular area of tissue will provide exposure through a deep, raw and bleeding access channel, which will make attachment bonding highly risky. In such cases, the surgeon often prefers to place a surgical pack to prevent healing over of the tissues. Sometimes the orthodontist may be rewarded with renewed eruptive activity of the canine and the possibility of autonomous eruption.<sup>5,6</sup>

### *Full flap open procedure*

An alternative is to reflect a full palatal flap to reveal the crypt of the canine, expose the tooth to its maximum circumference and then re-suture the flap back to its former place, after having first excised a circular portion of the mucosa immediately overlying the tooth.<sup>7,8</sup>

### *Apically repositioned flap*

The main indication for this procedure is when a labially impacted tooth is situated above the level of the mucogingival junction, but not displaced

mesially or distally.<sup>3,9</sup> It involves raising a labial attached mucogingival flap from the crest of the ridge and re-suturing it at the cervical level, leaving the crown exposed.

## Closed-eruption technique

There are also 3 main approaches to the closed exposure—all incorporating minor intra-technique variations:

### *Minimal exposure technique*

In a closed procedure, a full and wide flap is reflected in the thick keratinized palatal mucosa overlying the palpable bulge and retracted to reveal the bony surface beneath.<sup>10</sup> A small area of the thin shell of bone covering the tooth is pared away to disclose the follicle. A window is cut into the follicle to expose the surface of the tooth, sufficient to provide a minimum attachment bonding area of tooth enamel, while permitting the maintenance of hemostasis. The majority of the follicle is left intact; no attempt is made to remove more bone than is necessary for access to the tooth and the CEJ area is left undisturbed. A small eyelet attachment, threaded with a ligature or chain, is bonded, followed by the complete replacement of the surgical flap to its former place, leaving only the ligature or chain exiting through its sutured edge. Ideally, orthodontic traction should start immediately.

### *Maximal exposure technique*

In an effort to standardize the procedure in a multicenter controlled study to examine periodontal outcome, the participating surgeons adopted a significantly more radical exposure than the one just mentioned, by the removal of bone and, presumably, complete enucleation of the follicle covering the tooth in its crypt, in order to achieve exposure of the tooth to its maximum circumference.<sup>7</sup>

### *Tunnel approach*

An interesting variant of the closed technique was introduced by Crescini et al.<sup>11</sup> The impacted canine is drawn downwards through the evacuated socket of the simultaneously extracted deciduous canine. This modification is aimed at ensuring the preservation of the

buccal plate of the alveolar bone and the principal indication of this technique is for impacted canines that are located high in the maxilla and in close proximity to the line of the arch.

### **The choice of surgical procedure in relation to 3D location of the impacted tooth**

Teeth generally erupt through the attached gingiva, but those which are more buccally displaced have a tendency to erupt higher up above the attached gingival band and through the oral mucosa. A closed surgical exposure or apically repositioned flap procedure in these cases is indicated. The only justification for the simpler window procedure exposure here is when there is a wide band of attached gingiva overlying the impacted tooth.<sup>3</sup> When the tissue is removed in this situation, there must be a millimeter or more of attached gingiva, apical to the cut edge.

According to Ericson and Kurol<sup>12</sup> and Walker et al.,<sup>13</sup> between 48% and 67% of impacted canines are associated with resorption of the adjacent incisors. It has also been shown that resorption ceases when the offending canine is distanced from the immediate vicinity.<sup>14</sup> In order to move the canine, it must first be exposed and an attachment placed on it. Since the crown of the canine is located at least partially within the resorption crater, leaving the tooth open to the oral environment post-surgery endangers the vitality of the incisor—clearly not an option. Thus, the alternatives are either to extract 1 or other of the 2 involved teeth or to leave the canine to continue on its destructive eruption path until it resorbs its way through the incisor root and out the other side. The third alternative is to perform a closed procedure in which only a small opening into the follicle is made at the most distant part of the crown of the canine from the resorption front. A minimal amount of enamel is exposed, sufficient only to accept the attachment to be bonded to it.

What of the unerupted central incisor, impacted by the presence of a supernumerary tooth or 2? The incisor is often very high up, labially displaced and at the level of the reflection of the oral mucosa in the summit of the labial sulcus. Some orthodontists prefer to have the surgeon remove the supernumerary teeth and

then wait for the incisor to erupt or, at least improve its position, before exposing it in a second surgical episode. Alternatively and assuming that it is desirable to avoid 2 surgical procedures, performing an open procedure on this tooth runs the almost impossible task of maintaining clinical access to the tooth, when the highly mobile mucosa is desperately trying to heal the wound over. Furthermore, modifying the technique by apically repositioning a partial thickness, keratinized, gingival flap, results in the denudation of the entire labial mucosal cover of the ridge.

Attempting an open procedure risks leave a large defect in the soft tissues and bone. This would not be appropriate in many instances, even if a surgical pack is used, because of the depth of the tooth within the maxilla, as reported recently.<sup>15</sup> Other contraindications to an open procedure include exposure of adjacent tooth roots to the oral environment, exposure of resorbing root apices, and loss of access due to healing of the mucosal tissues over the surgical site. Furthermore, a closed procedure provides better access to a buried tooth by reflecting a wide mucosal covering of the area as a first step, making for better vision and better hemostasis, particularly in the palatal area.

No 2 oral and maxillofacial surgeons expose teeth in the same way. There is a wide range of preferred clinical protocols regarding the width and depth of open exposure and to a varying extent the surgical flaps in closed procedures. There is a broad spectrum of opinion and practice among oral and maxillofacial surgeons in regard to the elimination of the tissues around the impacted tooth, ranging from those who expose just a small area of crown enamel, to those who bare the tooth well down to the CEJ and beyond.

Many orthodontists prefer the services of a periodontist.<sup>1,3</sup> The rationale for this is the belief that the skills of a periodontist are more suited to the finer nature of this particular procedure, including greater care in the manipulation of the soft tissues. This is indicative of different surgical strategies or protocols within these 2 related specialties, with a corresponding variation in the periodontal outcome.

It becomes evident that there are very many objective factors to consider when selecting a surgical method and planning for the surgical

exposure of an impacted tooth, many of which are dictated by the individual preference of the surgeon. The range of treatable impacted teeth that can be salvaged is wider if we are prepared to use a closed procedure than an open one. Thus, a technical bias creeps into the selection of cases that comprise the investigative sample. While the indications and contraindications for the performance of one method versus another need to be evaluated on a patient-by-patient basis, there is a fairly wide range of situations in which either an open or closed method would be equally suitable. These are likely to be the more straightforward and simpler ones and differences in periodontal and appearance-outcomes between the 2 are unlikely to be great. However, these are precisely the cases that would probably form their random investigative sample, because those with more severely displaced teeth will be eliminated as unsuitable for an open surgical approach.<sup>7,15</sup> A further methodologic flaw in that study relates to their standardized, submucous, direct, orthodontic traction of the canine to its location, emerging intraorally only in its place in the arch. For many impacted canines, the path to their destination is obstructed by the root of one or both incisors. No allowance was made for this in the study, suggesting the inclusion of only minor impaction cases and correspondingly minor periodontal outcome differences.

### Attachment bonding

With access to the tooth presented during surgery, an attachment needs to be placed in the most convenient location on the crown of the tooth, with a connector leading from the tooth to the exterior. Superficially, it would seem logical to assume that, with an open exposure technique, bonding of an attachment may be performed either at the time of surgical exposure, or at a later date. However, experience has shown that the cut and raw mucosal tissues rapidly close within the first few days and access to the tooth may be lost, even when the exposure was very wide.<sup>15</sup> Placement of a surgical pack for the first 2–3 weeks of the healing period will delay the tissue closure, but bonding an attachment deep into a surgically created cavern with an oozing periphery following pack removal, is far from reliable.

If we accept that it is preferable to place an attachment at the time of surgery and that the attachment comes into intimate contact with the healing mucosa as the tooth is erupted into the mouth, then a low profile and rounded eyelet must be the attachment of choice. Placing a bulky and sharply cornered standard bracket as a “back-pack” on the tooth will lead to impingement and consequent inflammation of the gingival tissues as it emerges. This will have a negative effect on the periodontal outcome, particularly in the closed procedure cases. No requirement was established regarding the type of attachment to be bonded in the various treatment centers, so the likelihood that a standard orthodontic bracket was used is fairly unlikely and the consequences could be quite significant.

### Efficacy of treatment

For optimum interdisciplinary cooperation, there is no substitute for the orthodontist being present at the surgical exposure to test for mobility of the tooth, to bond the attachment in the most advantageous site, to draw the connector in the calculated direction of traction, to connect up the traction mechanism and to activate it at that time. Closed surgery provides a wide surgical field, where the widely reflected flap—the main source of bleeding—can be retracted away from the bonding area. This also provides for visibility of the entire field and consequently, the surgeon can remove a minimum of bone around the tooth and expose a small area of enamel, just enough for placing a small eyelet. There is no need to expose the whole crown of the impacted tooth,<sup>15</sup> this will not speed-up the eruption rate, but will increase the risk for negative periodontal implications.<sup>16</sup> The biggest advantage is that immediate activation may be effected in the optimal direction, with the appropriate force level and range of action—something only the orthodontist knows how to do properly—and all this while the patient is still anesthetized!

### Periodontal outcome

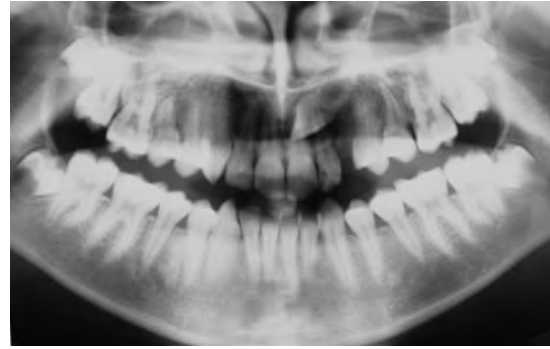
Surgical repair after a closed procedure occurs by primary intention, while open procedures heal by secondary intention around the impacted

tooth crown. Few studies clarify whether this leads to different periodontal and esthetic outcomes, while most have methodological limitations. One study included a mixed group of canines and incisors,<sup>17</sup> another did not describe the surgical procedure used,<sup>18</sup> while others<sup>11,19</sup> included both palatal and buccal canines. The results must clearly be interpreted with caution, since the periodontal outcome is not necessarily the same with different teeth and with different surgical methods.

### *Palatal canines*

A previously reported study on the periodontal outcome in groups of palatal canines treated with the same surgical procedure showed that those treated with closed procedures report very satisfactory outcomes in terms of esthetics, a minimal increase in the depth of the periodontal pockets and some loss of bone support.<sup>20</sup> In contrast, Wisth et al.<sup>21</sup> reported a significant loss of attachment associated with open procedures; however, since these groups of canines were totally different and unmatched, a meaningful comparison still cannot be made. Until recently, only one retrospective study aimed to compare closed versus open procedures in a pure group of palatal canines.<sup>22</sup> It found deeper pockets in teeth exposed by open exposures, but this study had inherent methodological limitations due to the lack of matching between the 2 surgery groups.

A Cochrane review<sup>23</sup> concluded that there is insufficient evidence to prefer one technique over the other. In all, 2 subsequent prospective studies<sup>7,8</sup> reported contradictory results with similar periodontal and esthetic results, irrespective of the type of surgery. These studies randomly allocated the cases to the 2 surgery groups, with no attempt to match them. Random allocation does not guarantee perfect matching, especially in terms of the severity of impaction. In addition, the description of the surgical technique included “surgical bone removal exposing the largest diameter of the ectopic canine crown.”<sup>15</sup> For the closed procedure, this represents a departure from good clinical practice and a radical and unnecessary removal of bony covering which would negatively influence the final periodontal and esthetic outcome.<sup>16</sup> The defined standardized criteria

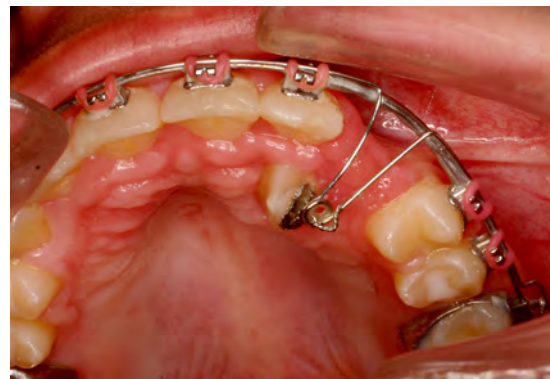

**Figure 1.** Pre-treatment panoramic radiograph shows a palatally impacted canine, with crown tip in the midline. The lateral incisor roots lies in the direct path between the canine and its final location.

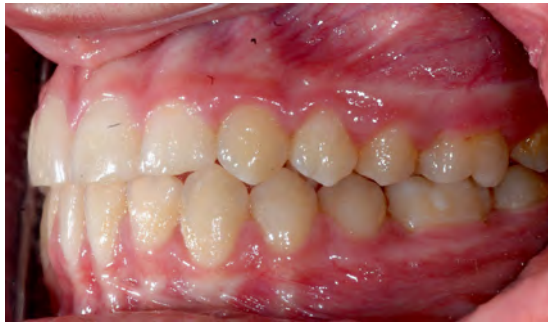for closed exposure in the Parkin series of studies carried an important rider, namely “.....the canine exposed with the closed procedure was moved beneath the mucosa.”<sup>7</sup> This automatically excludes the many cases where the lateral incisor root obstructs the direct path of the tooth to the desired location. In this common situation, a 2-stage resolution of the impaction is necessary to overcome the strategic obstruction. The impacted tooth has to be initially erupted vertically into the mid-palate, from where it gains a new and direct path to its place (Figs. 1–3).

### *Buccal canines*

Studies reporting the periodontal condition of buccally impacted canines after closed-eruption exposure found excellent appearance but a



**Figure 2.** The same case, following a closed surgical exposure, the initial movement vertically erupted the tooth into the palatal area, in order to circumvent the lateral incisor root, before drawing it to the line of the arch.



**Figure 3.** The same case at the completion of treatment with the canine in its place.

decrease in the width of attached gingiva.<sup>24</sup> No studies have directly compared open versus closed surgical outcomes in buccal canines alone, although mixed groups of palatal and buccal canines have been investigated.<sup>19,25,26</sup>

### **Incisors**

Our group has reported on the periodontal and esthetic outcome in a group of unilaterally impacted incisors. The incisors treated by closed surgery resulted in a very satisfactory appearance in general but with a slight, occasional gingival irregularity.<sup>27</sup> Those treated by open exposures showed an inferior periodontal result including a decrease in the width of attached gingiva, an increased crown length, a high frequency of gingival irregularity and a significant reduction in the mesial bone support.<sup>28</sup> The only article in the literature which compared closed versus open was the study of a group of matched (in terms of age, position and severity of impaction) impacted incisors found statistically significant differences in 2 parameters: teeth in the open-eruption group had considerably longer crowns and decreased mesial bone support than those in the closed-eruption group.<sup>29</sup> A special case has to be made in the surgical protocol for treatment of severely dilacerate incisors, whose incisal tip is high in the labial sulcus, adjacent to the anterior nasal spine. These teeth require 2 separate and contrasting surgical procedures. Initially, a closed procedure is performed in the summit of the labial sulcus to place the attachment. As the tooth moves down toward the crest of the ridge, its incisal edge bulges the labial side and is danger of erupting through the free oral mucosa. At this point, an apically repositioned flap of gustatory

mucosa is sutured over its labially exposed aspect. A third procedure may later be prescribed for the purpose of apicectomizing the labially prominent root apex.<sup>30</sup>

### **Post-treatment quality of life**

Our group reported on postoperative recovery following surgical exposure of impacted teeth treated with closed-eruption and an open-eruption surgical-orthodontic technique.<sup>31-33</sup> Again, results must be interpreted in relation to the initial location of the impacted tooth. Buccal exposures, either closed or open, showed prolonged recovery in comparison to palatal exposures. The buccal approach is probably more traumatic in either the open or closed approaches than in the palatal approach because of the need to sever paranasal/oral musculature and to locate the surgical flap in highly mobile oral mucosa.<sup>33</sup> In contrast, for palatal exposures, recovery was longer (5 days) after open eruption than after closed-eruption exposures (3 days), especially with regard to pain, analgesic intake, difficulty in eating and swallowing. The discomfort was greater if bone removal was needed. In our studies, questionnaires were answered on a daily basis from day 1 and the results indicated recovery in 3-5 days after surgery. Significantly, at the extreme ends of the spectrum, 6 patients who still reported pain at 10 days were from the open surgery group and 3 of 4 patients who reported no pain, were from the closed surgery group.

In a similar study, the authors found no post-surgical differences in discomfort following the various procedures.<sup>15</sup> However, in that study the patients completed the questionnaires on a single occasion 10 days after the surgery, which would appear to be excessively taxing on the memory for an accurate and critical assessment of post-surgery discomfort.

### **Conclusion**

In conclusion, it must be recognized that there are far too many variable factors involved in the surgical and the orthodontic procedures in the treatment of impacted canines and that any attempt to standardize the clinical approach to either of these 2 specialties in a randomized clinical trial can, at best, only provide answers to the "sterile" conditions of those treated within



that study. At worst, it ignores the individual treatment needs and special operative requirements that are determined by the clinical features and characteristics of many in the broad spectrum of patients whom we treat.

## References

- Mathews DP, Kokich VG. Palatally impacted canines: the case for preorthodontic uncovering and autonomous eruption. *Am J Orthod Dentofacial Orthop.* 2013;143:450–458.
- Becker A, Chaushu S. Palatally impacted canines: the case for closed surgical exposure and immediate orthodontic traction. *Am J Orthod Dentofacial Orthop.* 2013;143:451–459.
- Kokich VG, Mathews DP. Surgical and orthodontic management of impacted teeth. *Dent Clin North Am.* 1993;37:181–204.
- Becker A. *The Orthodontic treatment of Impacted Teeth*. 3rd ed., Oxford: Wiley Blackwell; 2012.
- Schmidt AD, Kokich VG. Periodontal response to early uncovering, autonomous eruption, and orthodontic alignment of palatally impacted maxillary canines. *Am J Orthod Dentofacial Orthop.* 2007;131:449–455.
- Kokich VG. Preorthodontic uncovering and autonomous eruption of palatally impacted maxillary canines. *Semin Orthod.* 2010;16:205–211.
- Parkin NA, Milner RS, Deery C, et al. Periodontal health of palatally displaced canines treated with open or closed surgical technique: a multicenter, randomized controlled trial. *Am J Orthod Dentofacial Orthop.* 2013;144:176–184.
- Parkin NA, Freeman JV, Deery C, Benson PE. Esthetic judgments of palatally displaced canines 3 months postdebond after surgical exposure with either a closed or an open technique. *Am J Orthod Dentofacial Orthop.* 2015;147:173–181.
- Vanarsdall RL, Corn H. Soft-tissue management of labially positioned unerupted teeth. *Am J Orthod.* 1977;72:53–64.
- Lewis PD. Preorthodontic surgery in the treatment of impacted canines. *Am J Orthod.* 1971;60:382–397.
- Crescini A, Clauser C, Giorgetti R, Cortellini P, Pini Prato GP. Tunnel traction of infraosseous impacted maxillary canines. A three-year periodontal follow-up. *Am J Orthod Dentofacial Orthop.* 1994;105:61–72.
- Ericson S, Kurol PJ. Resorption of incisors after ectopic eruption of maxillary canines: a CT study. *Angle Orthod.* 2000;70:415–423.
- Walker L, Enciso R, Mah J. Three-dimensional localization of maxillary canines with cone-beam computed tomography. *Am J Orthod Dentofacial Orthop.* 2005;128:418–423.
- Becker A, Chaushu S. Long-term follow-up of severely resorbed maxillary incisors after resolution of an etiologically associated impacted canine. *Am J Orthod Dentofacial Orthop.* 2005;127:650–654[quiz 754].
- Parkin NA, Deery C, Smith AM, et al. No difference in surgical outcomes between open and closed exposure of palatally displaced maxillary canines. *J Oral Maxillofac Surg.* 2012;70:2026–2034.
- Kohavi D, Becker A, Zilberman Y. Surgical exposure, orthodontic movement, and final tooth position as factors in periodontal breakdown of treated palatally impacted canines. *Am J Orthod.* 1984;85:72–77.
- Vermette ME, Kokich VG, Kennedy DB. Uncovering labially impacted teeth: apically positioned flap and closed-eruption techniques. *Angle Orthod.* 1995;65:23–32 [discussion 33].
- Woloshyn H, Artun J, Kennedy DB, Joondeph DR. Pulpal and periodontal reactions to orthodontic alignment of palatally impacted canines. *Angle Orthod.* 1994;64:257–264.
- McDonald F, Yap WL. The surgical exposure and application of direct traction of unerupted teeth. *Am J Orthod.* 1986;89:331–340.
- Becker A, Kohavi D, Zilberman Y. Periodontal status following the alignment of palatally impacted canine teeth. *Am J Orthod.* 1983;84:332–336.
- Wisth PJ, Norderval K, Boe OE. Periodontal status of orthodontically treated impacted maxillary canines. *Angle Orthod.* 1976;46:69–76.
- Wisth PJ, Norderval K, Boe OE. Comparison of two surgical methods in combined surgical-orthodontic correction of impacted maxillary canines. *Acta Odontol Scand.* 1976;34:53–57.
- Parkin N, Benson PE, Thind B, Shah A. Open versus closed surgical exposure of canine teeth that are displaced in the roof of the mouth. *Cochrane Database Syst Rev.* 2008;4:CD006966.
- Kohavi D, Zilberman Y, Becker A. Periodontal status following the alignment of buccally ectopic maxillary canine teeth. *Am J Orthod.* 1984;85:78–82.
- Crescini A, Nieri M, Buti J, Baccetti T, Pini Prato GP. Orthodontic and periodontal outcomes of treated impacted maxillary canines. *Angle Orthod.* 2007;77:571–577.
- Crescini A, Nieri M, Buti J, et al. Short- and long-term periodontal evaluation of impacted canines treated with a closed surgical-orthodontic approach. *J Clin Periodontol.* 2007;34:232–242.
- Becker A, Brin I, Ben-Bassat Y, Zilberman Y, Chaushu S. Closed-eruption surgical technique for impacted maxillary incisors: a postorthodontic periodontal evaluation. *Am J Orthod Dentofacial Orthop.* 2002;122:9–14.
- Chaushu S, Brin I, Ben-Bassat Y, Zilberman Y, Becker A. Periodontal status following surgical-orthodontic alignment of impacted central incisors with an open-eruption technique. *Eur J Orthod.* 2003;25:579–584.
- Chaushu S, Dykstein N, Ben-Bassat Y, Becker A. Periodontal status of impacted maxillary incisors uncovered by 2 different surgical techniques. *J Oral Maxillofac Surg.* 2009;67:120–124.
- Becker A. Extreme tooth impaction and its resolution. *Semin Orthod.* 2010;16:222–233.
- Chaushu S, Becker A, Zeltser R, Vasker N, Chaushu G. Patients' perceptions of recovery after surgical exposure of impacted maxillary teeth treated with an open-eruption surgical-orthodontic technique. *Eur J Orthod.* 2004;26:591–596.
- Chaushu G, Becker A, Zeltser R, Branski S, Chaushu S. Patients' perceptions of recovery after exposure of impacted teeth with a closed-eruption technique. *Am J Orthod Dentofacial Orthop.* 2004;125:690–696.
- Chaushu S, Becker A, Zeltser R, et al. Patients perception of recovery after exposure of impacted teeth: a comparison of closed- versus open-eruption techniques. *J Oral Maxillofac Surg.* 2005;63:323–329.

---

# Primary failure of eruption and other eruption disorders—Considerations for management by the orthodontist and oral surgeon

Sylvia A. Frazier-Bowers, Sonny Long, and Myron Tucker

**Tooth eruption is a highly variable process, and the disorders that stem from a defective eruption process are often difficult to diagnose. The eruption process can range from normally timed and sequenced events to one characterized by eruption delays or a primary failure of eruption (PFE, OMIM 125350)—with partially or completely unerupted teeth in the absence of a mechanical obstruction. Our understanding of the molecular basis of tooth eruption was drastically strengthened when one gene, parathyroid hormone receptor 1 (PTH1R), was found to be causative for familial cases of PFE. Although PFE is a relatively rare condition, knowledge of a biological mechanism underlying the development of PFE illuminates: (1) the influence of genetics on orthodontic tooth movement in general; (2) the differential diagnosis of clinical eruption disorders; and (3) the correlation of a biologic basis with the clinical management of eruption failure. In this article, we consider the best clinical management of eruption disorders from the standpoint of what is known from a biological perspective about normal tooth eruption and therefore eruption disorders. Specifically, how the diagnosis influences the clinical management of eruption disorders using biologic versus clinical factors is considered. These advances in our understanding of normal and abnormal tooth eruption now allow for a systematic clinical diagnostic regime that may include a surgical approach or simply the elimination of treatment with a continuous archwire. (Semin Orthod 2016; 22:34–44.) © 2016 Elsevier Inc. All rights reserved.**

## Introduction

**D**iagnosis and clinical management of eruption disorders can be quite challenging. The critical features of diagnosis can be broken into several major categories, including syndromic versus isolated, genetic versus

environmental, and of course idiopathic. Primary failure of eruption (PFE, OMIM #125350), originally described by Proffit and Vig,<sup>1</sup> is characterized by eruption failure of permanent teeth in the absence of mechanical obstruction or syndrome. The hallmark features of this condition are:

1. Infraocclusion of affected teeth.
2. Significant posterior openbite malocclusion accompanying normal vertical facial growth.
3. The inability to move affected teeth orthodontically.

Many historic studies have noted the heritable basis of infraoccluded teeth or eruption disorders.<sup>2–7</sup> Until the reports of mutations in the parathyroid hormone receptor 1 gene (*PTH1R*), non-syndromic eruption disturbances (i.e., ankylosis, secondary retention, primary retention, and PFE) were difficult to distinguish from one

---

*Department of Orthodontics, University of North Carolina, School of Dentistry, Chapel Hill, NC; Department of Pediatric Dentistry, University of North Carolina, School of Dentistry, Chapel Hill, NC and Private Practice in Orthodontics and Pediatric dentistry, Charlotte, NC; Department of Oral and Maxillofacial Surgery, Louisiana State University School of Dentistry, Oral and Maxillofacial Surgery Educations Services Consultant, Isle of Palms, SC.*

*Address correspondence to Sylvia A. Frazier-Bowers, DDS, PhD, Department of Orthodontics, University of North Carolina, School of Dentistry, Chapel Hill, NC 27599. E-mail: sylvia\_frazier-bowers@unc.edu*

*We gratefully acknowledge the past support of the AAOF, SAO, and NIH grants 1K23RR17442 and M01RR-00046.*

© 2016 Elsevier Inc. All rights reserved.

1073-8746/12/1801-\$30.00/0

<http://dx.doi.org/10.1053/j.sodo.2015.10.006>

another.<sup>8,9</sup> Moreover, it became apparent that the orthodontic management of mechanical failure of eruption (MFE)<sup>6</sup> is different from that of PFE, therefore critically important to distinguish between eruption failure due to local or mechanical causes (e.g., cysts, interference of adjacent tooth, lateral pressure from tongue, and secondary to syndrome such as cleidocranial dysplasia, OMIM #199600) versus a failure of the eruption mechanism completely.

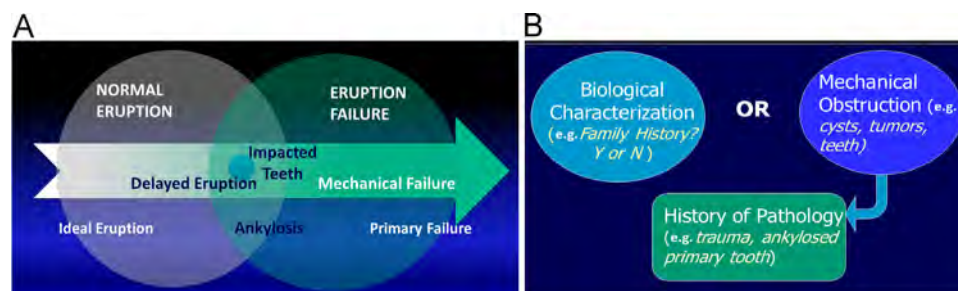
Although PFE was previously thought to be an isolated event, the identification of *PTH1R* mutations associated with PFE provides confirmation of a genetic etiology for eruption failure. It may also be reasonable to suspect a genetic etiology for other eruption disturbances (i.e., delayed eruption, impaction) that do not involve a mechanical barrier. This shifts the focus from a purely clinical description to one that represents a combination of clinical and biologic factors.<sup>10</sup> Accordingly, eruption disturbances should be thought of in broad etiologic categories rather than narrowly defined morphological characteristics.<sup>11,12</sup> The major categories include biologic dysfunction (e.g., primary failure of eruption) and physical obstruction (e.g., mechanical failure, cysts, and lateral tongue pressure; Fig. 1A and B). Impacted teeth may fit into either category, depending upon the location of the impacted tooth (i.e., palatal or buccal canine impaction). Palatally impacted canines are hypothesized to be both multifactorial and genetic in origin.<sup>13–16</sup> Also, permanent teeth can become impacted secondary to an

obstruction of the eruption pathway, such as crowded dental arches.

In this report, we examine the relationship between the clinical eruption disorder, its etiology and hence the best management using a rubric created from a study of eruption disorders and genetic etiology.<sup>10</sup> For the clinical orthodontist, the utilization of biologic information facilitates the accurate and timely diagnosis of an eruption disorder and therefore appropriate management of the orthodontic problem.<sup>17,18</sup>

### The biology of tooth eruption

The key to understanding abnormal tooth eruption should start with a complete understanding of normal eruption. Briefly, human dental eruption is defined as the axial movement of a tooth from its non-functional, developmental position in alveolar bone to a functional position of occlusion.<sup>19</sup> It is also known that normal tooth eruption relies on a tightly coordinated process including a series of signaling events between the dental follicle and the osteoblast and osteoclast cells found in the alveolar bone.<sup>20</sup> Several studies confirm the role of the dental follicle as a central mediator of tooth eruption<sup>21–23</sup>; the dental follicle provides the environment and chemo-attractants for monocytes to differentiate into osteoclasts, facilitating the bone resorption necessary for normal tooth eruption. Historical experiments by Cahill and Marks<sup>21</sup> demonstrated the critical role of the follicle in experiments



**Figure 1.** (A) Diagrammatic representation of the spectrum of tooth eruption, ranging from normal eruption to mechanical or primary failure of eruption. Delayed eruption is at the far end of the normal eruption sequence. Mechanical failure of eruption can be due, for instance, to local causes such as a cyst, supernumerary teeth, and lateral pressure from the tongue. On the other hand, impactions (especially canine), and ankylosis represent either a defect in the primary eruption mechanism or a mechanical obstruction. PFE is, by definition, “primary” failure of eruption due to a defect in the molecular eruption mechanism. (B) Diagrammatic representation of a rubric that initially distinguishes from a mechanical versus biologic etiology is a key step in treatment planning decisions.

where a metal object was substituted for a tooth in the dental follicle. Evidenced by the successful eruption of the follicle containing a metal object, it was concluded that the follicle was necessary and sufficient for eruption.

Furthermore, the importance of key cytokines and diffusible growth factors in tooth eruption was nicely illustrated using rodent molars by Yao et al.<sup>24</sup> Their studies suggested that specific growth factors and cytokines and the following chain of events provides the mechanism that facilitates eruption into the oral cavity:

1. Stellate reticulum cells found in the dental follicle are observed to secrete parathyroid hormone related peptide (PTHrP).
2. PTHrP induces expression of colony stimulating factor-1 (CSF1) and receptor activator of NF-kappa B ligand (RANKL), which are primary factors involved in osteoclastogenesis.<sup>24</sup>
3. At the apical end of the dental follicle, concomitant expression of bone morphogenic protein (BMP) promotes osteogenesis in a temporally and spatially coordinated fashion.<sup>25</sup>

These experiments in rats reveal that specific factors are necessary and sufficient to facilitate eruption of the tooth into the oral cavity.<sup>26</sup> Additionally, we know that genes involved in mineralization, for example, amelogenin (*AMELX*) and ameloblastin (*AMBN*) may act in concert with those involved in osteoclastogenesis, such as *RANKL*, *CSF1* and *C-Fos*.<sup>27</sup> These and other findings enhance our understanding of the specific biologic mechanism underlying tooth eruption. The apparent connection between *PTHIR* and *PTHrP*, which is secreted in the stellate reticulum and responsible for the induction of *CSF1* and *RANKL*, was confirmed in a simple network pathway analysis.<sup>12</sup> The established link between *PTHIR* and *PTHrP* provides significant evidence of the relationship between PFE, *PTHrP* signaling and the mediators of eruption necessary for normal bone remodeling.

Consequently, one might hypothesize that some variants in one of these two focal genes (e.g., *PTHIR*) could disrupt the balance between bone resorption, necessary to establish the passageway for an erupting tooth, and bone formation, necessary to rebuild bone through which

the tooth has transited, thus contributing to PFE. This relationship of PFE with *PTHIR* and *PTHrP* therefore provides clues to the possible mechanism of tooth eruption and may be important deducing an appropriate treatment modality. Because *PTHIR* and *PTHrP* act in the vitamin D receptor—retinoid X receptor (VDR/RXR) activation pathway—it is plausible that a critical target of the genetic defect in PFE is the alveolar bone. The VDR/RXR pathway primarily affects cell signaling, molecular transport, and vitamin and mineral metabolism.<sup>28,29</sup> Yet VDR/RXR signaling also plays a key role in balancing bone formation with bone resorption such as that seen in bone remodeling.<sup>30,31</sup> In addition to influencing calcium homeostasis in general, the focal genes, *PTHIR* and *PTHrP*, and the pathway in which they belong, have been shown to affect the number, quality and function both of osteoclasts and osteoblasts<sup>32,33</sup> as well as the volume, thickness and density of trabecular bone.<sup>34,35</sup> Consideration of these biologic relationships helps to form the basis for treatment options in the management of PFE versus other eruption disorders discussed below.

### Diagnosis and management of tooth eruption problems

The identification of mutations in the *PTHIR* gene as the cause of PFE and the connection between osteoclasts and osteoblast cells as discussed above also provides the basis for potential clinical management approaches. We already know that individuals affected with PFE do not respond to orthodontic forces and can be easily confused with ankylosis.<sup>1,6,9</sup> However, clinical cases in question now can be evaluated for a link to a specific biologic cause (i.e., *PTHIR* mutation) and therefore rule out MFE or ankylosis. Although PFE is relatively rare (estimated incidence of 0.6%), the occurrence of eruption problems in the dental/orthodontic setting is not uncommon.

A significant challenge in the accurate diagnoses of PFE is the high degree of clinical variability observed in familial and isolated cases.<sup>6,11</sup> For example, our phenotypic evaluation of eruption failure in a large cohort revealed that there are distinguishable types of PFE related to the extent of eruption potential in the anteroposterior and vertical gradient. With respect to

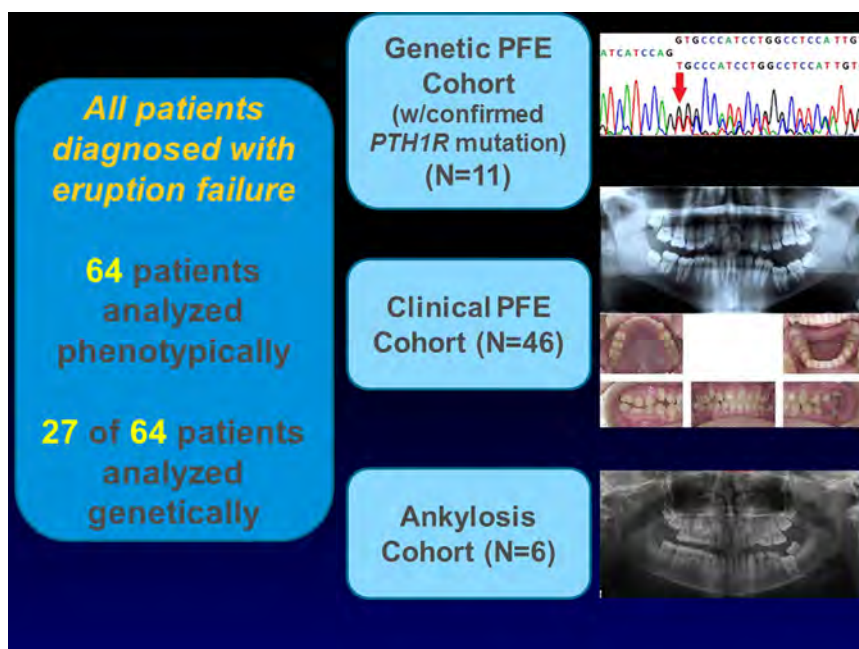


the pattern viewed from an anteroposterior gradient two types of PFE have been previously described.<sup>6,11</sup> Type I is marked by a progressive openbite from the anterior to the posterior of the dental arches. Type II presents as a progressive openbite from the anterior to the posterior; however, there also is a more varied expression of eruption failure in more than one quadrant and greater although inadequate eruption of a second molar. Type II is even more challenging to recognize than Type I because the second molar may appear erupted but upon careful examination will lack the ideal interdigitation with the opposing tooth. While the exact reason for this clinical variation is unknown, in light of the recent *PTH1R* finding, we speculate that the predominant affection of molar teeth may be the result of a coordinated series of molecular events that act in a temporally and spatially specific manner such that posterior rather than anterior alveolar bone is affected.

Despite the gap of knowledge that remains in our understanding of how a significant problem, such as eruption failure arises, we have gained

quite useful knowledge from viewing the disorders in a systematic fashion in a study that compares PFE with other eruption failure (Fig. 2).<sup>10</sup> Evaluation and comparison of three cohorts (PFE with *PTH1R* mutation, ankylosis, and PFE w/o mutation) with varying forms of eruption disorders revealed that those who had a mutation in the *PTH1R* gene (and a certain diagnosis of PFE) shared common phenotypic characteristics with one another. Specifically, 100% of the 11 cases evaluated had at least one affected first molar and 93% of all eruption failure cases ( $N = 64$ ) had at least one affected first molar; all of the cases revealed a clear eruption pathway radiographically. These findings were used to create a rubric that provides a systematic diagnosis, but also that guides clinical management. Using the diagnostic criteria defined in this study we may also be able to elucidate the most efficient management sequence.

Ankylosis, strictly defined as the fusion of cementum to alveolar bone, represents an eruption defect most easily confused with PFE.

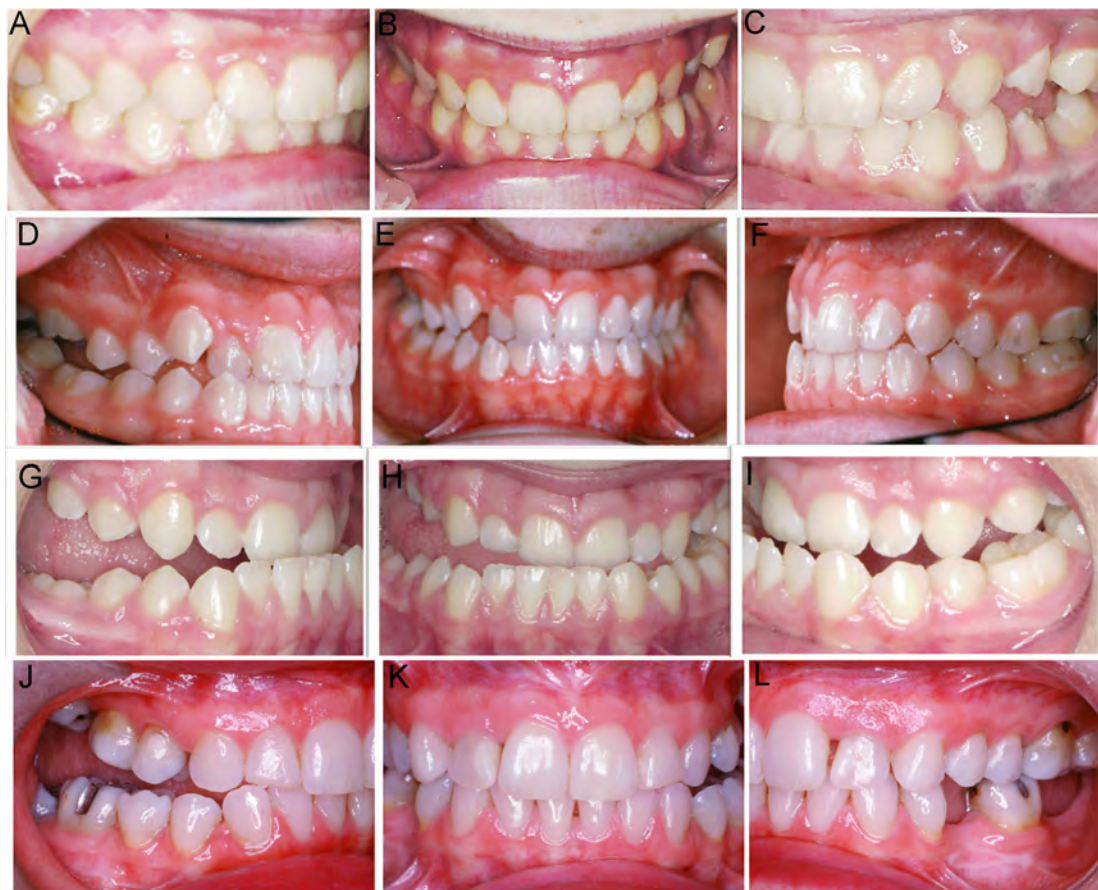

**Figure 2.** A systematic study of eruption disorders to establish a diagnostic rubric determined the diagnostic features of PFE based on those who carried a mutation in the *PTH1R* gene since this is a most objective criterion. Three cohorts were evaluated for phenotypic and genetic characteristics: cohort (1) PFE—genetic (those that harbor a mutation in *PTH1R*), cohort(2) PFE—clinical (those that are phenotypically identical to PFE genetic without the mutation in *PTH1R*, and cohort (3) ankylosis. The results of this study formed the basis for a diagnostic rubric to distinguish eruption disorders, revealing the hallmark features of PFE based on those with *PTH1R* mutations and at least one infraoccluded molar that had a clear eruption pathway.



The diagnosis of ankylosis relies largely on the clinical appearance of infraocclusion and radiographically by the absence of a periodontal ligament space, however, the determination of an absent periodontal ligament space often can be misinterpreted on a radiograph. The absence of physiologic mobility and the sharp solid sound on percussion of the tooth have also been suggested as diagnostic approaches but show great variation based on the operator.<sup>36,37</sup> In this case, ankylosis can be difficult to distinguish from PFE. This scenario is exemplified in one family in which five members carried the same mutation in *PTHIR* (Fig. 3A–L). Two affected individuals were diagnosed previously with ankylosis as determined by bone sounding (Fig. 3A–F). The fact that all family members carried the same mutation causative for PFE, but only two

were diagnosed with PFE, reveals a need to establish better diagnostic tools to distinguish between ankylosis and PFE. The consequence of the misdiagnosis in this family led to unsuccessful attempts to correct the malocclusion orthodontically that instead worsened the severity of the posterior openbite and intruded teeth anterior to affected teeth.<sup>9</sup> A positive family history of PFE and/or positive identification of a mutation in the *PTHIR* gene should alert the clinician that affected teeth would be unresponsive to orthodontic treatment. However, if a diagnosis of ankylosis is accurate then the affected tooth is the only tooth that will be unresponsive; the remaining teeth will be responsive to orthodontic treatment. Given the difficulty in diagnosing ankylosis accurately, if a physical or mechanical cause cannot be documented and



**Figure 3.** (A–C and D–F) represents Type II PFE observed in pretreatment photographs of two siblings. This mild presentation of a unilateral openbite initially was mistaken for isolated ankylosis. Both siblings have a unilateral pattern of PFE with a Class I relationship on the unaffected side. Another affected sibling (G–I) and the mother of all three children (J–L) show Type I PFE, with the distal most teeth affected more severely. Despite disparate diagnoses, all of the family members carried the same mutation in the *PTHIR* gene.

a genetic etiology is discovered, then PFE more likely is the diagnosis. The diagnostic approach above will allow the clinician to follow two different treatment courses including:

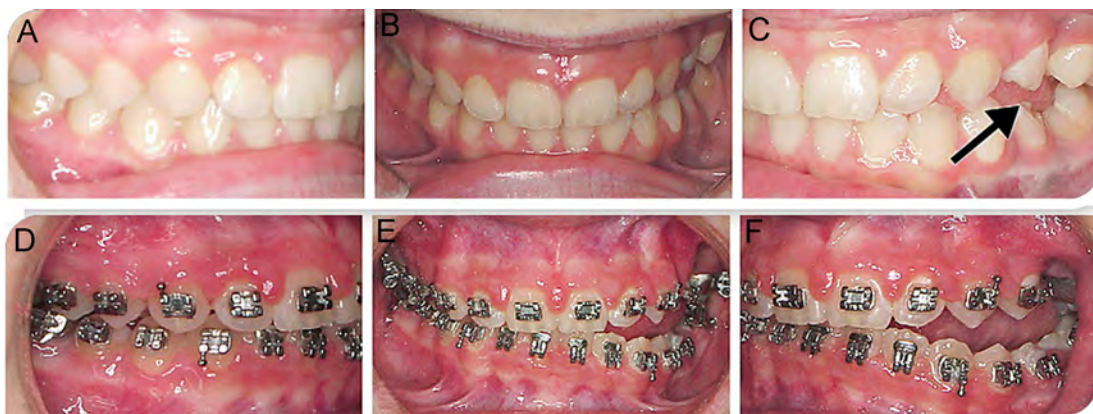
1. If PFE can be confirmed, traditional orthodontic treatment with a continuous archwire should be avoided. An accurate diagnosis of PFE prevents a futile effort by doctor and patient because the teeth will not respond.
2. If a first molar fails to erupt, early extraction of the first molar will allow the second molar to drift mesially if the second molar is normal and does no harm if the second molar exhibits abnormal eruption.

### Clinical approaches to manage eruption failure

A systematic clinical approach based on biologic data was described previously in three cohorts of eruption failure and can be applied as follows: (1) first determine if the eruption defect has an apparent mechanical obstruction (e.g., cysts, tumors, or supernumerary teeth) or biologic etiology (i.e., family history, developmental pathology; Fig. 1B).<sup>10</sup> (2) Then the determination of whether a lower first molar is involved must be made. If the answer to these two questions is yes, then the diagnosis may be PFE. Although a genetic analysis of the *PTHIR* gene would be an ideal approach to confirm a diagnosis of PFE, this is not yet routinely available in most practices as it does not represent a standard genetic test.<sup>9</sup> Nonetheless,

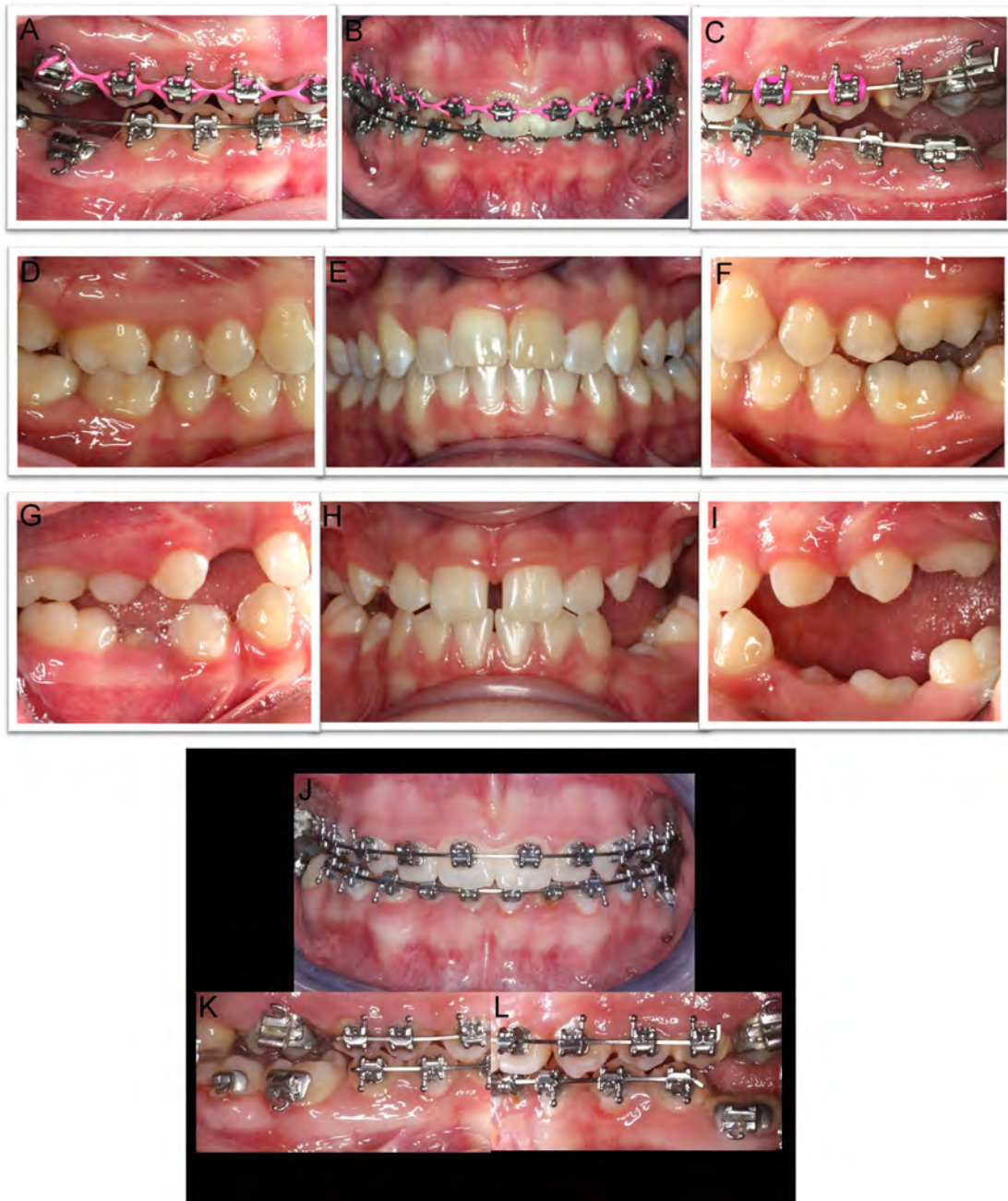this diagnostic distinction informs the clinical management. For instance, in one family, the apparent biologic etiology was only determined after the infraocclusion was misdiagnosed as ankylosis and the occlusal relationships worsened by treating the entire dentition with a continuous archwire (Fig. 4A–F).<sup>9</sup> In this clinical scenario, the analysis of the *PTHIR* gene was not available at the time of their initial diagnosis but the apparent familial segregation was remarkable and forms the basis of the systematic approach in diagnosis of eruption failures (Fig. 3A–L). In another family, an eruption defect that aligns with PFE was found in a mother and two daughters (Fig. 5A–I). The only approach that would result in closure of the posterior openbite and occlusal interdigitation is single tooth osteotomies (corticotomies) with immediate elastic traction taking advantage of Regional Acceleratory Phenomenon (RAP). Corticotomies followed by immediate elastic traction is perhaps the most logical approach to achieve a significant occlusal improvement but the key to such intervention is immediate traction following the surgery (Fig. 6A–D) as shown in another individual affected with PFE. The surgical approach will likely be used for the younger untreated daughter as well (Fig. 5G–I). The alternative treatment approach is always to avoid treatment with a continuous archwire and employing a segmented approach from premolar to premolar and leaving the infraocclusion in the molar region uncorrected.

The management of PFE described above is quite distinct from other forms of eruption



**Figure 4.** (A–C) The same patient shown in Fig. 3(A–C) before treatment with a continuous archwire and (D–F) after treatment. The outcome of orthodontic treatment with a continuous archwire in confirmed cases of PFE is intrusion of the adjacent teeth.

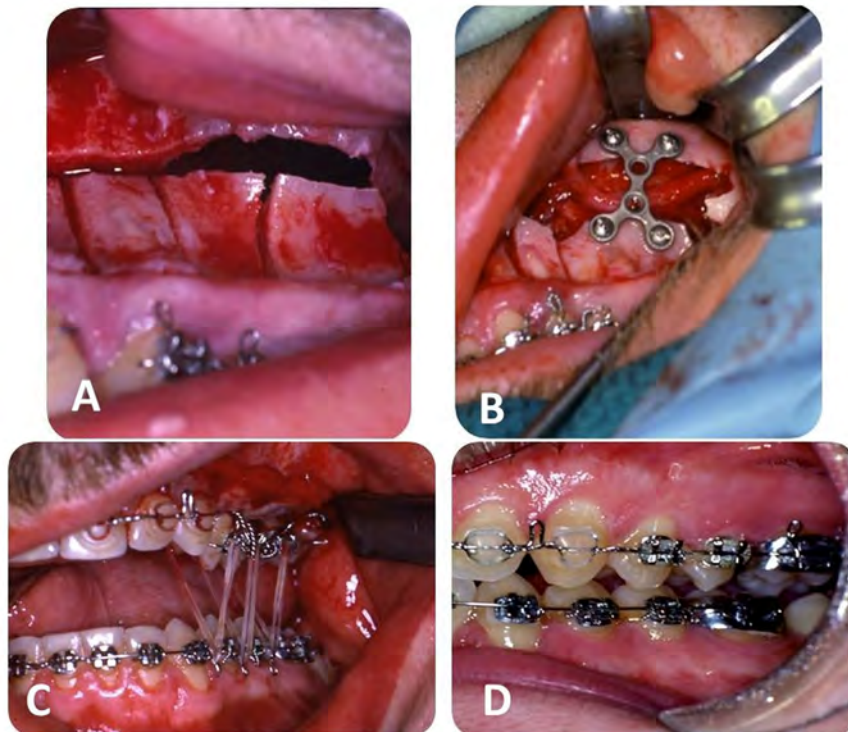




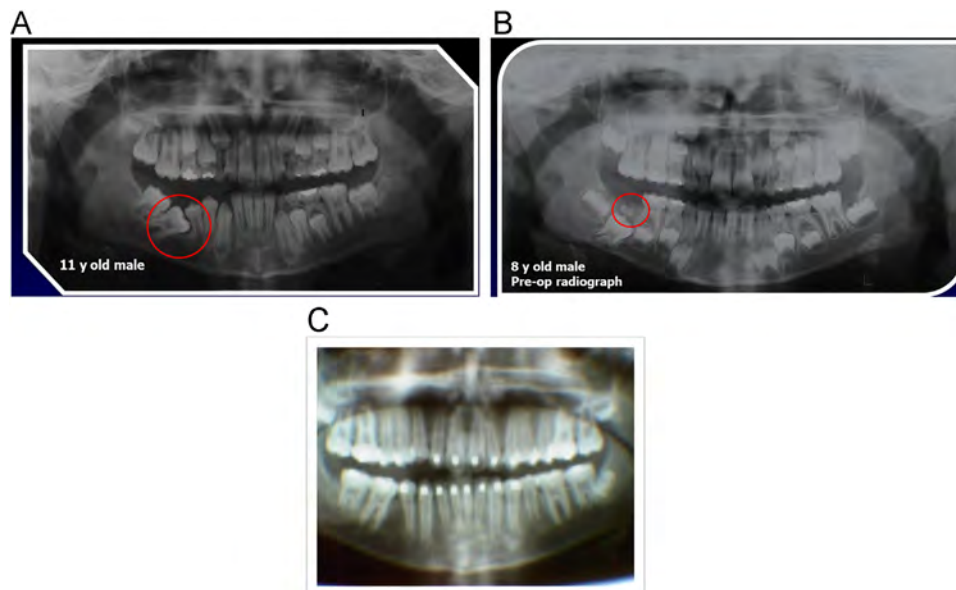
**Figure 5.** An important aspect of the diagnostic rubric (Fig. 1A and B) is to determine if a biologic cause is present for the eruption disorder. Application of this rubric can be illustrated in one family with an affected daughter who manifests the posterior lateral openbite after orthodontic treatment (A–C). Re-evaluation of her mother, who was treated in the distant past, and her younger sister revealed a milder (D–F) and more severe (G–I) case of PFE with at least one affected molar (G–I). A genetic evaluation of *PTH1R* would be ideal to confirm the diagnosis, but can be concluded using the information available. In this case treatment included corticotomies followed by elastic traction (J–L).

failure that should be managed quite differently (Fig. 7A–C). An 11-year-old male reported to an orthodontic clinic with an apparent first molar eruption failure that can be initially confused

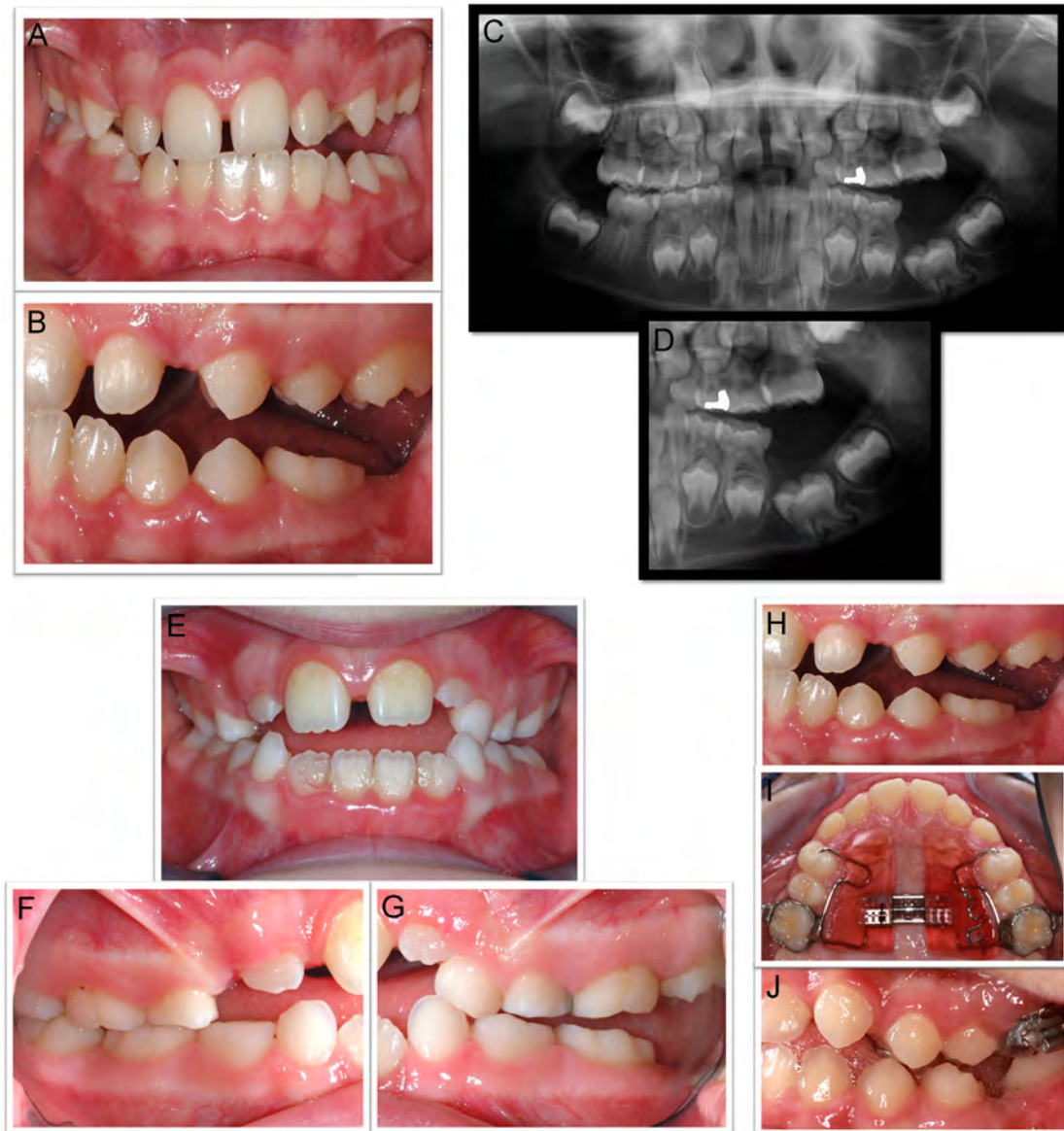with PFE (Fig. 7A). The absence of a family history and a systematic collection of historical information revealed a complex odontoma in his past that caused the initial impaction (Fig. 7B).



**Figure 6.** Example of adult male patient affected with PFE. Treatment included segmental osteotomy in the maxillary arch (A and B) with immediate elastic traction (C and D).



**Figure 7.** (A) Panoramic film illustrating an unerupted lower first molar that may initially appear to fit the diagnostic rubric of PFE. (B) Assessment of an earlier panoramic film reveals the cause of eruption failure is a complex odontoma. (C) This illustrates a good example of how identification of the etiology provides the appropriate management and successful resolution of eruption failure.



**Figure 8.** Clinical photographs of 8-year-old male with an apparent lateral open bite (A) and an unerupted lower left first molar (B). After extraction of tooth 19, which subsequently revealed a developmental pathology and not PFE, the lower left second molar erupted normally (C–E). Eventual use of a vertical crib to discourage the tongue from occupying the edentulous space resulted in a reasonable resolution of the open bite (E–J).

Removal of the adjacent second premolar and surgical exposure of the impacted lower first molar was selected to eliminate the mechanical obstruction and allow resolution of the occlusion. This case nicely illustrates the importance of determining mechanical obstruction versus family history. The management was clearly different than if the diagnosis was mistaken for PFE, given the affected first molar. In this case, obtaining an appropriate natural history of the

dentition was critical to point to MFE as the cause of the eruption failure. The resultant occlusion was restored with surgical extraction of the premolar and orthodontics (Fig. 7C).

After the determination of an affected first molar is made, a critical step is to determine whether a biologic versus mechanical cause is known. This can be narrowed down by determining if a family history exists. Fig. 8A–D nicely illustrates a different scenario of eruption failure



in the absence of a family history. This fact alone does not eliminate the diagnosis of PFE, but upon further inspection, radiographically, a developmental pathology of the tooth can be observed along with an incompletely cleared bony pathway. Surgical extraction was recommended at the age of 8.7 years for the lower left unerupted molar (#19) with an apparent developmental pathology (Fig. 8E–G). Subsequent eruption of the developing 7 (#18) was eventual and caused a short-term posterior lateral openbite that was likely due to the tongue filling the edentulous area. A HAAS type appliance with a vertical tongue crib was employed and the posterior openbite was corrected (Fig. 8H–J). The cause in this patient was a pathological and unerupted isolated tooth (#19). Comprehensive orthodontics to correct the remaining occlusal discrepancies should be successful with a continuous archwire.

## Conclusion

The therapeutic approach for MFE/ankylosis versus PFE is vastly different. A misdiagnosis and attempt at early orthodontic intervention for PFE patients is futile and the surgical intervention, specifically corticotomies can achieve greater results. It is less clear but speculated that distraction osteogenesis also may provide a reasonable alternative to orthodontic tooth movement, but this approach first must be tested for its clinical effectiveness in modifying PFE-affected teeth. The advantage of making the correct diagnosis is that the proper mechanotherapy will provide reassurance for the patient and efficiency for the orthodontist.

## References

1. Proffit WR, Vig KW. Primary failure of eruption: a possible cause of posterior open-bite. *Am J Orthod.* 1981;80:173–190.
2. Bosker H, ten Kate LP, Nijenhuis LE. Familial reinclusion of permanent molars. *Clin Genet.* 1978;13:314–320.
3. Brady J. Familial primary failure of eruption of permanent teeth. *Br J Orthod.* 1990;17:109–113.
4. Ireland AJ. Familial posterior open bite: a primary failure of eruption. *Br J Orthod.* 1991;18:233–237.
5. DiBiase AT, Leggat TG. Primary failure of eruption in the permanent dentition of siblings. *Int J Paediatr Dent.* 2000;10:153–157.
6. Frazier-Bowers SA, Koehler KE, Ackerman JL, Proffit WR. Primary failure of eruption: further characterization of a rare eruption disorder. *Am J Orthod Dentofacial Orthop.* 2007;131(578):e1–e11.
7. Frazier-Bowers SA, Simmons D, Koehler K, Zhou J. Genetic analysis of familial non-syndromic primary failure of eruption. *Orthod Craniofac Res.* 2009;12:74–81.
8. Decker E, Stellzig-Eisenhauer A, Fiebig BS, et al. PTHR1 loss-of-function mutations in familial, nonsyndromic primary failure of tooth eruption. *Am J Hum Genet.* 2008;83:781–786.
9. Frazier-Bowers SA, Simmons D, Wright JT, Proffit WR, Ackerman JL. Primary eruption failure and PTHIR: the importance of a genetic diagnosis for orthodontic treatment planning. *Am J Orthod Dentofacial Orthop.* 2010;137(160):e1–e7.
10. Rhoads SG, Hendricks HM, Frazier-Bowers SA. Establishing the diagnostic criteria for eruption disorders based on genetic and clinical data. *Am J Orthod Dentofacial Orthop.* 2013;144:194–202.
11. Proffit WR, Frazier-Bowers SA. Mechanism and control of tooth eruption: overview and clinical implications. *Orthod Craniofac Res.* 2009;12:59–66.
12. Frazier-Bowers SA, Puranik CP, Mahaney MC. The etiology of eruption disorders: further evidence of a 'genetic paradigm.'. *Semin Orthod.* 2010;16:180–185.
13. Baccetti T. A controlled study of associated dental anomalies. *Angle Orthod.* 1998;68:267–274.
14. Peck S, Peck L, Kataja M. The palatally displaced canine as a dental anomaly of genetic origin. *Angle Orthod.* 1994;64:249–256.
15. Pirinen S, Arte S, Apajalahti S. Palatal displacement of canine is genetic and related to congenital absence of teeth. *J Dent Res.* 1996;75:1742–1746.
16. Zilberman Y, Cohen B, Becker A. Familial trends in palatal canines, anomalous lateral incisors, and related phenomena. *Eur J Orthod.* 1990;12:135–139.
17. Kuroi J. Impacted and ankylosed teeth: why, when, and how to intervene. *Am J Orthod Dentofacial Orthop.* 2006;129: S86–S90.
18. Loria LB, Machado AW, Souki BQ, Pereira TJ. Late diagnosis of dentoalveolar ankylosis: impact on effectiveness and efficiency of orthodontic treatment. *Am J Orthod Dentofacial Orthop.* 2009;135:799–808.
19. Ten Cate AR, Nanci A. Physiologic tooth movement: eruption and shedding. In: Nanci A, ed. *Oral Histology: Development, Structure and Function.* 6th ed. Toronto: Mosby; 2003:279–280.
20. Wise GE, King GJ. Mechanisms of tooth eruption and orthodontic tooth movement. *J Dent Res.* 2008;87: 414–434.
21. Cahill DR, Marks SC Jr. Tooth eruption: evidence for the central role of the dental follicle. *J Oral Pathol.* 1980;9:189–200.
22. Marks SC Jr, Cahill DR. Regional control by the dental follicle of alterations in alveolar bone metabolism during tooth eruption. *J Oral Pathol.* 1987;16:164–169.
23. Wise GE, Frazier-Bowers S, D'Souza RN. Cellular, molecular and genetic determinants of tooth eruption. *Crit Rev Oral Biol Med.* 2002;13:323–334.
24. Yao S, Pan F, Wise GE. Chronological gene expression of parathyroid hormone-related protein (PTHrP) in the stellate reticulum of the rat: implications for tooth eruption. *Arch Oral Biol.* 2007;52:228–232.

25. Wise GE. Cellular and molecular basis of tooth eruption. *Orthod Craniofac Res.* 2009;12:67–73.
26. Wise GE, Yao S, Henk WG. Bone formation as a potential motive force of tooth eruption in the rat molar. *Clin Anat.* 2007;20:632–639.
27. Hatakeyama J, Philp D, Hatakeyama Y, et al. Amelogenin-mediated regulation of osteoclastogenesis and periodontal cell proliferation and migration. *J Dent Res.* 2006;85:144–149.
28. Kim S, Shevde NK, Pike JW. 1,25 Dihydroxyvitamin D3 stimulates cyclic vitamin D receptor/retinoid X receptor DNA-binding, co-activator recruitment, and histone acetylation in intact osteoblasts. *J Bone Miner Res.* 2005;20:305–317.
29. Christakos S, Raval-Pandya M, Wernyj RP, Yang W. Genomic mechanisms involved in the pleiotropic actions of 1,25-dihydroxyvitamin D3. *Biochem J.* 1996;1:361–371.
30. Lanske B, Amling M, Neff L, Guiducci J, Baron R, Kronenberg HM. Ablation of the PTHrP gene or the PTH/PTHrP receptor gene leads to distinct abnormalities in bone development. *J Clin Invest.* 1999;104:399–407.
31. Lanske B, Divieti P, Kovacs CS, et al. The parathyroid hormone (PTH)/ PTH-related peptide receptor mediates actions of both ligands in murine bone. *Endocrinology.* 1998;139:5194–5204.
32. Yoneda T, Niewolna M, Lowe C, Izbicka E, Mundy GR. Hormonal regulation of pp60c-src expression during osteoclast formation *in vitro*. *Mol Endocrinol.* 1993;7:1313–1318.
33. Chiusaroli R, Maier A, Knight MC, et al. Collagenase cleavage of type I collagen is essential for both basal and parathyroid hormone (PTH)/PTH-related peptide receptor-induced osteoclast activation and has differential effects on discrete bone compartments. *Endocrinology.* 2003;144:4106–4116.
34. Miao D, He B, Karaplis AC, Goltzman D. Parathyroid hormone is essential for normal fetal bone formation. *J Clin Invest.* 2002;109:1173–1182.
35. Miao D, Li J, Xue Y, Su H, Karaplis AC, Goltzman D. Parathyroid hormone-related peptide is required for increased trabecular bone volume in parathyroid hormone-null mice. *Endocrinology.* 2004;145:3552–3562.
36. Biederman W. Etiology and treatment of tooth ankylosis. *Am J Orthod.* 1962;48:670–684.
37. Andersson I, Blomlof L, Lindskog S, Feiglin B, Hammarstrom L. Tooth ankylosis: clinical, radiographic and histological assessments. *Int J Oral Surg.* 1984;13:423–431.

---

# Update on treatment of patients with cleft—Timing of orthodontics and surgery

*Pradip R. Shetye*

**The management of patients with cleft lip and cleft palate requires prolonged orthodontic and surgical treatment and an interdisciplinary approach in providing them with optimal esthetics, function, and stability. This article describes an update on the current concepts and principles in the treatment of patients with cleft lip and palate. Sequencing and timing of orthodontic/orthopedic and surgical treatment in infancy, early mixed dentition, early permanent dentition, and after the completion of facial growth will be discussed. (Semin Orthod 2016; 22:45–51.) © 2016 Elsevier Inc. All rights reserved.**

## Introduction

Cleft lip and palate is the most frequently occurring congenital anomaly. Depending on the extent of the cleft defect, patients may have complex problems dealing with facial appearance, feeding, airway, hearing, and speech. Patients with cleft lip and palate are ideally treated in a multidisciplinary team setting involving specialties from the following disciplines: pediatrics, plastic and reconstructive surgery, maxillofacial surgery, otolaryngology, orthodontics, genetics, social work, nursing, speech therapy, pediatric dentistry, prosthetic dentistry, and psychology. The orthodontic and surgical treatment of patients with clefts is extensive, initiating at birth and continuing into adulthood when craniofacial skeletal growth is finished. The role of the orthodontist in timing and sequence of treatment is important in terms of overall team management. The goal for complete rehabilitation of patients with clefts is to maximize treatment outcome with minimal interventions.

In a patient with cleft lip and palate, the orthodontic malocclusion can be related to soft tissue, skeletal, or dental defects. Some cleft orthodontic problems are directly related to the

cleft deformity itself, such as discontinuity of the alveolar process, and missing or malformed teeth, whereas other aspects of the malocclusion are secondary to the surgical intervention performed to repair the lip, nose, alveolar, and palatal defects. A malocclusion may exist in all the three planes of space; anteroposterior, transverse, and vertical. The malocclusion may reflect the severity of the initial cleft deformity and the growth response to the primary surgery. As malocclusion in patients with clefts is often a growth-related problem, the effect of the cleft deformity and primary surgery will be observed throughout the growth of the child until skeletal maturity. The orthodontist must make critical decisions for orthodontic intervention at the appropriate time and prioritize treatment goals for each intervention. For the purpose of organization, the orthodontic treatment of patients with clefts will be presented in four distinct treatment phases: infancy, primary dentition, mixed dentition, and permanent dentition.

## Treatment during infancy

Pre-surgical infant orthopedics has been used in the treatment of cleft lip and palate patients for centuries. In 1993, Grayson et al.<sup>1</sup> described a new technique, nasoalveolar molding (NAM), to presurgically mold the alveolus, lip, and nose in infants born with cleft lip and palate.

The initial impression of the infant with cleft lip and palate is obtained within the first week after birth using a heavy body silicon impression material and the NAM appliance is inserted within the first 2 weeks. The NAM appliance has

---

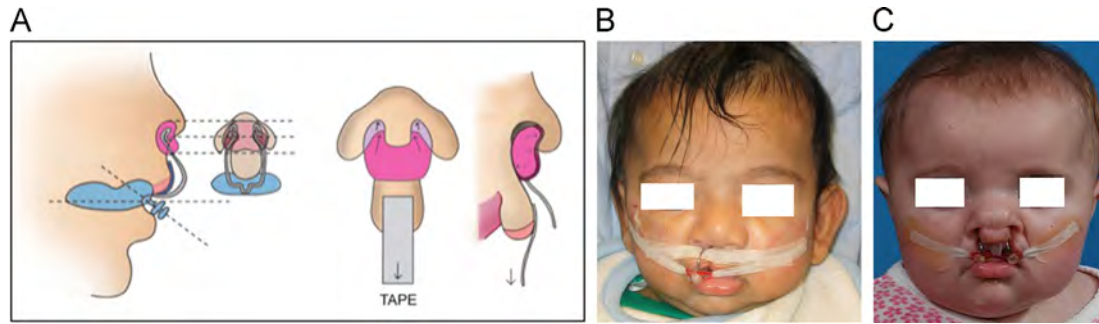
Wyss Department of Plastic Surgery, New York University, Langone Medical Center, New York, NY.

Address correspondence to Pradip R. Shetye, DDS, BDS, MDS, Wyss Department of Plastic Surgery, New York University, Langone Medical Center, 307 East 33rd St, New York, NY 10016. E-mail: [pradip.shetye@nyumc.org](mailto:pradip.shetye@nyumc.org)

© 2016 Elsevier Inc. All rights reserved.

1073-8746/12/1801-\$30.00/0

<http://dx.doi.org/10.1053/j.sodo.2015.10.007>



**Figure 1.** (A) Unilateral NAM plate with nasal stent showing lip taping. (B) The bilateral NAM plate in position showing the tape adhered to the prolabium, stretched to the plate, and attached to the plate.

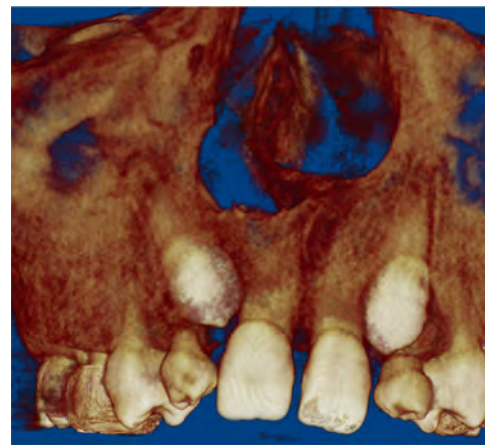
two components—the oral (molding plate) and the nasal (nasal stents). The oral component molds the clefted alveoli to allow them to approximate each other. The nasal components mold the distorted nasal cartilage on the clefted nose, making it more symmetrical (Fig. 1). Nasal molding helps expand the tissue of the mucosal lining of the nose. In unilateral cleft patients, the nasal stent straightens the deviated columella towards the non-cleft side. In patients with bilateral cleft lip and palate, the nasal stent elongates the deficient columella by gradually stretching the columella tissue. With the help of tape, the lips are also molded to reduce the size of the cleft. This process is done over a 3–4-month period and with active involvement by the family in the nasoalveolar molding process. A recent study of caregivers demonstrated that nasoalveolar molding was often associated with positive factors for parents such as increased empowerment, self-esteem, and bonding with their infant.<sup>2</sup> After completion of nasoalveolar molding treatment, the infant is then referred to the surgeon for primary closure of lip, nose, and the alveolus.

There are several benefits with the nasoalveolar molding technique in the treatment of cleft lip and palate deformity. Proper alignment of the alveolus, lip, and nose helps the surgeon achieve a better and more predictable surgical result.<sup>3</sup> Long-term studies of NAM therapy indicate that the change in nasal shape is stable.<sup>4</sup> The improved quality of primary surgical repair reduces the number of surgical revisions, oronasal fistulas, and secondary nasal and labial deformities.<sup>4–8</sup> If the alveolar segments are in the correct position and a gingivoperiosteoplasty is performed, the resulting bone

bridge across the former cleft site improves the conditions for eruption of the permanent teeth and provides them with better periodontal support. Studies have also demonstrated that 60% of patients who underwent NAM and gingivoperiosteoplasty did not require secondary bone grafting<sup>9</sup> (Fig. 2). The remaining 40% who did need bone grafts showed more bone remaining in the graft site compared to patients who had not had gingivoperiosteoplasty.<sup>10</sup>

### Treatment during the primary dentition

The treatment goals during the primary dentition stage of development focus on the acquisition of normal speech function, which is



**Figure 2.** Sectional CBCT of a patient who underwent nasoalveolar molding and gingivoperiosteoplasty surgery to repair the alveolus at the time of primary lip closure. Note good bone formation on the right former cleft side. This patient did not need secondary alveolar bone graft surgery. CBCT, cone beam-computed tomography.



managed by a speech therapist or pathologist and the surgeon. During this phase, the patient is closely monitored by the speech and language therapists. Patients may or may not need speech therapy depending on the diagnosis of speech issues. If the child has been diagnosed with velopharyngeal insufficiency (VPI), then the surgeon may perform a pharyngeal flap. This surgery is typically performed around the age of 2 years.

Another important component of care for a patient during this time period includes routine follow-up with a pediatric dentist. Regular visits to the pediatric dentist every 6 months are strongly recommended to prevent dental caries.

### Treatment during mixed dentition

The treatment objectives for a child as he/she enters mixed dentition are directed toward preparing the patient for secondary alveolar bone graft (SABG) surgery. The alveolar bone graft surgery is typically performed at around 8–9 years of age. A limited volume CBCT performed at this age is invaluable to identify the cleft defect and the position of the permanent teeth adjoining the cleft defect. The principal benefits of alveolar bone grafting are: (1) to provide sufficient bone for the eruption of either the maxillary lateral incisor or canine, (2) to provide adequate bone and soft tissue coverage around teeth adjacent to the cleft site, (3) to close the oronasal fistulae to prevent nasal air escape and fluid or food leakage, (4) to provide additional support and elevation to nasal structures, (5) to restore the alveolar ridge in the area of the cleft, thereby allowing orthodontic tooth movement and future placement of dental implants, and (6)

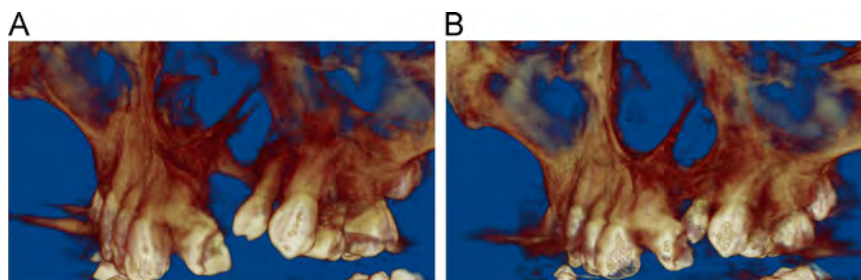
to stabilize pre-maxillary segments in patients with bilateral clefts.

Discrepancies in maxillary arch form or transverse width should be improved before the secondary alveolar bone graft. It is of note that the surgeon and orthodontist must work in tandem to determine the anatomical limits of pre-surgical maxillary expansion. This is imperative, as overexpansion may create an oronasal fistula or a defect that is beyond the limits of surgical closure (Fig. 3).

To provide the most stable environment for integration of the alveolar bone graft and the maintenance of palatal expansion, we routinely place an occlusally-bonded acrylic or removable tritain type splint at the time of surgery. The splint serves to immobilize the alveolar segments, as well as to prevent relapse of pre-surgical maxillary expansion. The splint remains in place for 6–8 weeks after surgery.

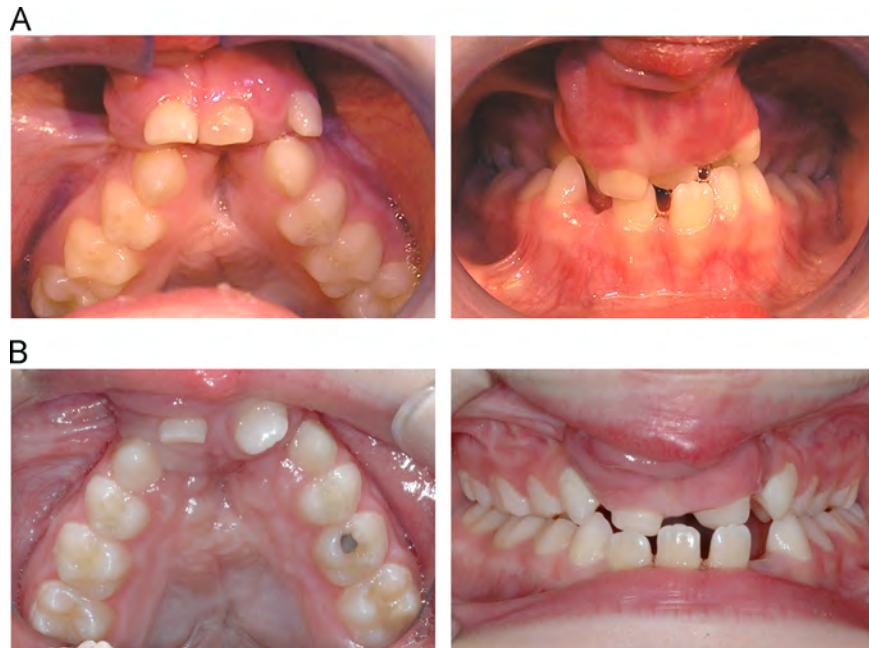The management of a bilateral cleft lip and palate patient may pose a unique challenge with respect to the position of the premaxilla before bilateral alveolar bone grafts. However, if the premaxilla is ectopically positioned, the patient may need pre-maxillary repositioning surgery. Pre-surgical expansion is performed to improve the arch form before surgery. A bonded occlusal splint is constructed after model surgery. In the operating room, the surgeon uses the splint to reposition the premaxilla and perform the secondary alveolar bone graft surgery.

After 6 months of secondary alveolar bone graft surgery, a post-op CBCT must be obtained to confirm the outcome of SABG surgery (Fig. 4). After successful repair of the cleft defect, the patient can then start Phase I fixed appliance treatment to correct malpositioned anterior teeth. If a patient shows a skeletal crossbite,



**Figure 3.** Sectional CBCT of pre- and post-alveolar bone graft sites. (A) Note the large alveolar defect on the lateral wall of the maxillary left central incisor. (B) The post-alveolar bone graft sectional CBCT shows good bone formation of the alveolar cleft site 6 months post iliac bone graft. CBCT, cone beam-computed tomography.





**Figure 4.** Occlusal (A) and frontal (B) views of a patient with bilateral cleft lip and palate who underwent rapid maxillary expansion with a bonded acrylic fan expander. Following transverse expansion, patient had bilateral alveolar bone grafts and pre-maxillary repositioning.

manifested as negative overjet at this stage, protraction headgear treatment can be initiated for about 9 months to correct the skeletal crossbite.

### Treatment during permanent dentition

Lateral cephalometric growth studies have shown that the maxilla in treated patients with cleft lip and palate show variable degrees of maxillary hypoplasia. The reasons for abnormal facial morphology in treated cleft patients may involve intrinsic skeletal and soft tissue deficiencies, iatrogenic factors introduced by treatment, or a combination of both. At birth, cleft lip and palate deformities vary greatly in severity. In some patients, there may be adequate tissue volume but the cleft segments have failed to fuse together due to inadequate cell migration. In others there may be varying amounts of missing tissue (bone, soft tissue, and teeth) associated with non-fusion of the cleft segments. Both groups of patients may respond differently to surgical treatment.

Clinically, patients with clefts may present with a concave profile, midface deficiency, and a Class III skeletal pattern. The maxilla may also be deficient in transverse and vertical planes,

contributing to posterior skeletal crossbite and reduced midface height. Dentally, there may be lingually inclined incisors and constricted maxillary posterior arch width, causing anterior or posterior crossbite. The extent of abnormal midface growth may vary from mild to severe. The severity distribution of abnormal midfacial growth is concentrated in the center of the bell curve, whereas patients with good growth and severe growth disturbances are dispersed on either side of the curve.<sup>11</sup> Depending on the severity of the malocclusion presented by the cleft patient, the management can be categorized into three types. In the first category, the patients have no skeletal discrepancy and orthodontic correction is limited to tooth movement only. In the second category, there is a mild skeletal discrepancy and the patients will benefit from camouflaging the malocclusion by orthodontic tooth movement alone. In the last category of patients, there is moderate to severe skeletal deformity and optimal results can only be obtained by combined surgical/orthodontic intervention. It is important to establish as early as possible if the patient will be treated with orthodontics alone, or orthodontics in conjunction with surgery. The direction of

orthodontic tooth movement to camouflage a very mild midface deficiency is opposite to that of tooth movement required to prepare a patient for midface advancement surgery.

### ***Patients with no skeletal deformity***

If a cleft patient in permanent dentition presents with no skeletal deformity (AP transverse or vertical), then the management of the dental malocclusion does not differ very much from that of the non-cleft patient. Patients with isolated clefts of the lip and alveolus or clefts of the soft palate may fall into this group and will benefit from fixed orthodontic treatment alone. The dental malocclusion may be limited to mild dental anterior or posterior crossbites, rotated and malposed teeth, and missing the lateral incisor in the cleft area. Mild anterior crossbites can be corrected with an advancing arch wire and posterior crossbite with arch wire expansion or with a removable quad helix.

There are two options regarding management of a missing lateral incisor: either maintenance of the space for a dental implant, or movement of the canine into the lateral incisor space, recontouring it to resemble a lateral incisor. If the decision is made to maintain space for a dental implant, optimal space must be made available for the implant to replace the missing lateral incisor. During active orthodontic treatment, this space can be maintained with the use of a pontic tooth that contains a bracket and is ligated to the orthodontic arch wire. At the conclusion of treatment, a cosmetic removable prosthesis should be fabricated to maintain the space. Once craniofacial skeletal growth is complete, a single tooth implant can be placed.

If canine substitution is planned for replacement of the missing lateral incisor, then several canine crown modifications are needed to achieve optimal esthetics. The permanent canine will need re-countering on incisal, labial, mesial, distal, and lingual surfaces. Recontouring can be done progressively during active orthodontic treatment. When bonding this tooth, a lateral incisor bracket will be placed more gingivally, to bring its gingival margin down to the level of the adjacent central incisor. The first bicuspid will then take the canine position and will also need reshaping to resemble a permanent canine. The second premolar and first and second

molars are moved mesially. The patient's orthodontic treatment is completed with a Class II occlusal relationship on the side of the missing lateral incisor. With successful esthetic bonding, excellent results can be achieved with this option.

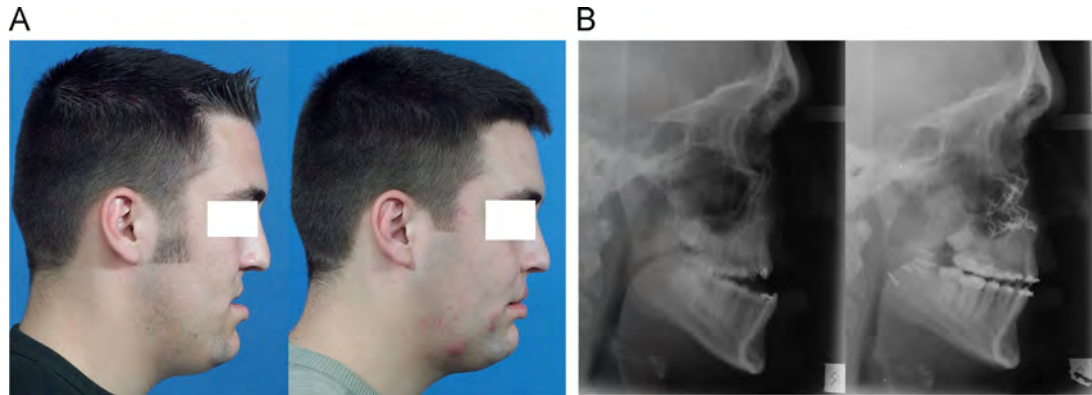
### ***Patients with mild skeletal discrepancy***

In patients presenting with mild skeletal discrepancy and minimal esthetic concern, orthodontic dental compensation may be recommended. A thorough clinical exam, growth status and stature, hand wrist films, and serial cephalometric assessments need to be performed before suggesting this option. However, the patient and the family should be cautioned that the outcome can be compromised if the patient outgrows the dental compensation and ultimately may need extended orthodontic treatment to remove the compensations and prepare for orthognathic surgery. Proclination of the maxillary incisors and lingual inclination of the lower incisor can adequately camouflage a mild skeletal discrepancy.

### ***Patients with moderate to severe skeletal discrepancy***

Patients presenting with moderate to severe skeletal discrepancy may achieve the best esthetic and functional results through a combination of orthodontic treatment that is carefully coordinated with orthognathic surgery. Depending on the severity of the skeletal discrepancy, the patient may require only maxillary advancement or a combination of maxillary advancement and mandibular setback. If the surgical/orthodontic option is elected, timing of the orthodontic and surgical treatment becomes critical (Fig. 5).

Under optimal conditions, it is recommended to remove all dental compensations and to align the teeth in an optimal position relative to the skeletal base and alveolar processes. The orthodontist will plan the coordination of maxillary and mandibular arch widths by hand articulating the progressing dental study models into the predicted postsurgical occlusion. Once the pre-surgical orthodontic treatment goals are achieved (coordinated maxillomandibular arch width, compatibility of occlusal plans, and satisfactory intercuspation), the patient may be debonded and placed on removable retainers



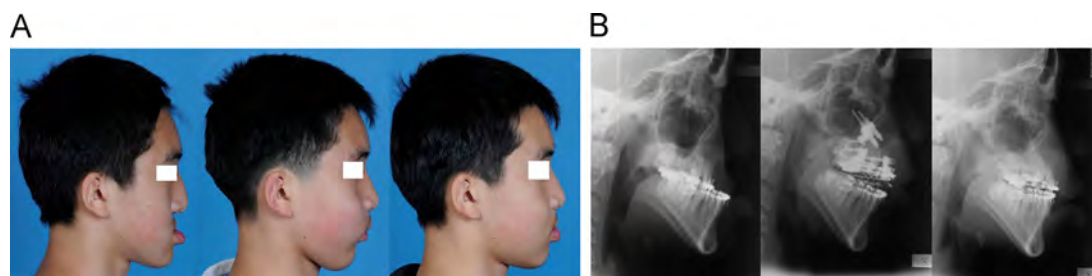
**Figure 5.** Bilateral cleft patient with two jaw surgery. (A) Pre- and post-lateral profile photographs show significant improvement after maxillary advancement and BSSO. (B) Lateral cephalogram pre- and post-surgery. BSSO, bilateral sagittal split osteotomy.

until craniofacial skeletal growth is complete. This assessment is made by observation of the closing sutures in the hand wrist radiographs, by measurements of mandibular body length in serial lateral cephalograms and measurements of change in stature or height. The patient is placed on fixed orthodontic appliances for a short, pre-surgical orthodontic treatment phase before orthognathic surgery. The combined surgical and orthodontic treatment goals are planned in close coordination with the surgeon. After surgical correction is completed, a 12-month post-surgical orthodontic phase of treatment begins. The objectives of postsurgical orthodontics are to balance the forces of skeletal relapse with intermaxillary elastics, to observe the skeletal stability of the surgical correction, and to detail the postsurgical occlusion.

Sometimes a maxillomandibular skeletal discrepancy is severe, and for psychosocial reasons, early surgery during the mixed or permanent dentition is indicated. However, the patient and

their family must be cautioned that the patient may outgrow the surgical orthodontic correction and may need another corrective surgery upon the completion of skeletal growth. In these cases, distraction osteogenesis may be considered as an alternative. The advantages of distraction osteogenesis in a growing patient with cleft lip and palate include the generation of new bone at the site of the osteotomy, large advancement without the need for a bone graft, and gradual stretching of the scarred soft tissue. Since distraction osteogenesis and midface advancement are performed at the rate of 1 mm per day, changes in velopharyngeal competency can be monitored during the advancement. For the skeletally mature cleft patient who shows severe maxillary deficiency, advancement of the midface with distraction osteogenesis is also a good treatment option (Fig. 6).

Distraction in the cleft patient can be achieved with external or internal distraction devices. Depending on the surgeon's preference and



**Figure 6.** Series of patients treated for LeFort I midface advancement with internal distraction: (A) Before, during and after internal midface distraction lateral profile photographs. (B) Before, during, and after internal midface distraction lateral cephalograms.

clinical presentation of deformity, either approach may be used to achieve the desired results. Internal distraction devices are more acceptable to the patient; however, they offer some clinical limitations. The external devices can be adjusted to change the vector of skeletal correction during the active phase of distraction, while the internal device cannot be adjusted in this way. After the LeFort I osteotomy and a latency period of 5–6 days, the distraction device is activated at the rate of 1 mm per day until the desired advancement is achieved. Interarch elastics may be used during the active phase of distraction osteogenesis to guide the maxilla to its optimal position and the teeth to optimal occlusion. On completion of the advancement, there is a 8-week period of bone consolidation during which time the distraction devices serve as skeletal fixation appliances. Following this period of bone healing, the distraction devices are removed and post-distraction orthodontics begins. The objective of post-distraction orthodontics is to retain the position of the advanced midfacial skeleton and to fine tune the occlusion.

## Conclusion

The successful management of a patient with cleft lip and palate requires careful coordination of all members of the Cleft Palate Team. Introduction of nasolabial molding has significantly changed the outcome of cleft treatment. The shape, form, and nasal esthetics of patients with clefts are significantly better in those who have had the benefits of NAM. Clinical techniques constantly will be improved to enable the clinician to provide the best possible care while striving to reach the goal of excellent facial esthetics in patients born with clefts.

## References

1. Grayson BH, Cutting C, Wood R. Preoperative columella lengthening in bilateral cleft lip and palate. *Plast Reconstr Surg*. 1993;7:1422–1423.
2. Sischo L, Broder HL, Phillips C. Coping with cleft: a conceptual framework of caregiver responses to nasolabial molding. *Cleft Palate Craniofac J* 2014 [Epub ahead of print].
3. Rubin MS, Clouston S, Ahmed MM, Lowe KM, Shetye PR, Broder HL, Warren SM, Grayson BH. Assessment of presurgical clefts and predicted surgical outcome in patients treated with and without nasolabial molding. *J Craniofac Surg*. 2015;1:71–75.
4. Maull DJ, Grayson BH, Cutting CB, Brecht LL, Bookstein FL, Khorrambadi D, et al. Long-term effects of nasolabial molding on three-dimensional nasal shape in unilateral clefts. *Cleft Palate Craniofac J*. 1999;5:391–397.
5. Cutting C, Grayson B, Brecht L, Santiago P, Wood R, Kwon S. Presurgical columellar elongation and primary retrograde nasal reconstruction in one-stage bilateral cleft lip and nose repair. *Plast Reconstr Surg*. 1998;3: 630–639.
6. Pfeifer TM, Grayson BH, Cutting CB. Nasolabial molding and gingivoperiosteoplasty versus alveolar bone graft: an outcome analysis of costs in the treatment of unilateral cleft alveolus. *Cleft Palate Craniofac J*. 2002;1: 26–29.
7. Patel PA, Rubin MS, Clouston S, Lalezaradeh F, Brecht LE, Cutting CB, Shetye PR, Warren SM, Grayson BH. Comparative study of early secondary nasal revisions and costs in patients with clefts treated with and without nasolabial molding. *J Craniofac Surg*. 2015;4:1229–1233.
8. Lee CT, Grayson BH, Cutting CB, Brecht LE, Lin WY. Prepubertal midface growth in unilateral cleft lip and palate following alveolar molding and gingivoperiosteoplasty. *Cleft Palate Craniofac J*. 2004;44:375–380.
9. Santiago PE, Grayson BH, Cutting CB, Gianoutsos MP, Brecht LE, Kwon SM. Reduced need for alveolar bone grafting by presurgical orthopedics and primary gingivoperiosteoplasty. *Cleft Palate Craniofac J*. 1998;1:77–80.
10. Sato Y, Grayson BH, Garfinkle JS, Barillas I, Maki K, Cutting CB. Success rate of gingivoperiosteoplasty with and without secondary bone grafts compared with secondary alveolar bone grafts alone. *Plast Reconstr Surg*. 2008;4:1356–1367.
11. Ross RB. Treatment variables affecting facial growth in complete unilateral cleft lip and palate. *Cleft Palate J*. 1987;1:5–77.



---

# 3D guided comprehensive approach to mucogingival problems in orthodontics

Marianna Evans, Nipul K. Tanna, and Chun-Hsi Chung

**Advances in technology have enabled the clinician to use a 3-dimensional (3D) guided approach to orthodontic diagnosis and treatment planning, leading to a more predictable treatment sequence and outcome for orthodontists and surgeons. Important factors must be taken into consideration when planning orthodontic treatment such as the existing and projected tooth position as well as the periodontal soft and hard tissue phenotype. 3D anatomic analysis of the dentoalveolar complex may provide more information than what can be derived from 2-dimensional radiographs and the clinical examination. It can help identify patients at risk for the development of mucogingival problems during or after orthodontic treatment and can guide the clinician in determining the appropriate intervention to minimize the risks of an unfavorable outcome. (Semin Orthod 2016; 22:52–63.) © 2016 Elsevier Inc. All rights reserved.**

## Introduction

**E**stablishing periodontal health in conjunction with the existence of a biologically and anatomically acceptable environment that allows for the proper function and maintenance of that health is critical for the longevity of the dentition. This requires teeth to be positioned in the center of the alveolar housing with adequate buccolingual bone support, an adequate inflammation-free keratinized gingival seal and the presence of an occlusal scheme that allows for even force dissipation in an axial direction, free of interferences.

Patients with a malocclusion may present with pre-existing mucogingival problems or fragile periodontal support that is susceptible to attachment loss during or after orthodontic treatment. The American Academy of Periodontology (AAP) defines mucogingival conditions as deviations from the normal anatomic relationship between the gingival margin and the mucogingival junction (MGJ).<sup>1</sup> Common muco-

gingival conditions include gingival recession, absence or reduction of keratinized tissue and probing depth extending beyond the MGJ. For the purpose of this article, attachment loss due to periodontitis will not be discussed.

Gingival recession is defined as an apical shift of the marginal gingiva from its normal position on the crown of the tooth to levels on the root surface apical to the cemento-enamel junction (CEJ). Once developed, this condition is irreversible without surgical intervention. It is critical to note that gingival recession is simply a clinical manifestation of an underlying alveolar bone problem. It is always accompanied by alveolar bone dehiscences of varying degrees. Löst,<sup>2</sup> in a human study on correlation between gingival recession and alveolar bone dehiscences, found a minimal distance of around 3 mm between the vestibular gingival margin and the alveolar bone margin of teeth affected by gingival recession. Alveolar bone dehiscence may be present without manifestation of gingival recession, but gingival recession cannot develop without simultaneously manifesting or pre-existing bone loss.<sup>2</sup>

According to Loe et al.,<sup>3</sup> gingival recession begins early in life and is found primarily on the labial root surfaces. Prevalence varies from 3% to 100% depending on the population and the methods of analysis, and appears to be lower in younger groups, where the incidence increases with age.<sup>4</sup> If left untreated, it may result in the

---

*Department of Orthodontics, School of Dental Medicine, University of Pennsylvania, Pennsylvania, PA.*

*Address correspondence to Marianna Evans, DMD, Department of Orthodontics, School of Dental Medicine, University of Pennsylvania, Philadelphia, PA. E-mail: mevans@infinityorthoperio.com*

© 2016 Elsevier Inc. All rights reserved.

1073-8746/12/1801-\$30.00/0

<http://dx.doi.org/10.1053/j.sodo.2015.10.008>



loss of the tooth, followed by further resorption of the underlying bone.

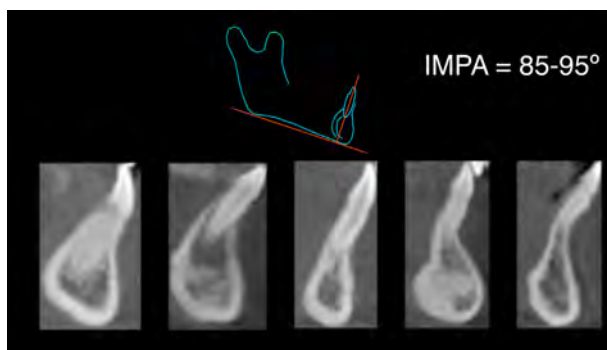
The etiology of recession is multi-factorial<sup>5</sup> and may include bacterial plaque, tooth brush and toothpaste abrasion, occlusal trauma, oral piercing, iatrogenic factors related to restorative and periodontal therapy, tooth position/tooth size in relation to the surrounding bone volume, orthodontic malocclusion, gingival biotype and high frenum attachment.

Gingival recession may develop or progress before, during or after orthodontic treatment. The correlation between orthodontic tooth movement and attachment loss remains controversial due to the lack of randomized controlled studies.<sup>6,7</sup> In spite of that, it has been reported that the buccolingual tooth position and movement will affect the thickness and width of keratinized gingiva.<sup>8,9</sup> Teeth positioned more lingually will often have a wider band of keratinized gingiva than those positioned more labially. This phenomenon may be explained by spatial redistribution of the gingival tissue in a buccolingual dimension during tooth movement. Multiple studies also confirm that thin gingival biotype and the presence of alveolar bone dehiscences predispose patients to gingival recession with or without orthodontic tooth movement.<sup>10–12</sup> Wennstrom et al.<sup>13</sup> evaluated the periodontal reaction to orthodontic movement in monkeys and reported that plaque-induced inflammation and the thickness (volume) of the marginal soft tissue, rather than the apico-coronal width of the keratinized and attached gingiva, are determining factors for the development of gingival recession and attachment loss during orthodontic tooth movement.

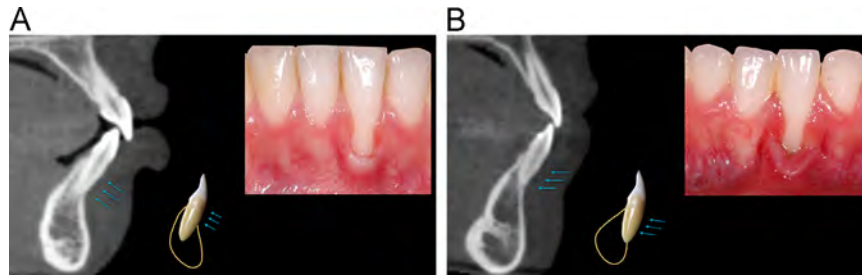
To prevent or address gingival recession in susceptible patients, predictable soft tissue grafting procedures such as the subepithelial connective tissue graft (SCTG) and the free gingival graft (FGG) may be performed prior to or after tooth movement.<sup>14,15</sup> Since gingival recession is also a bone problem, hard tissue grafting procedures to thicken the buccolingual alveolar bone dimension may be beneficial in selected cases.

Alveolar bone deficiency is a common finding in the general population.<sup>16</sup> Before cone-beam computed tomography (CBCT) technology, the alternative to diagnosing buccolingual alveolar bone dimension without flap reflection was to use costly, medical CT scans that were associated with much higher radiation. Traditionally, 2-dimensional images such as lateral cephalograms have been used to evaluate changes in the incisor inclination. These images are limited to evaluation of the average buccolingual incisor position in relationship to large anatomic landmarks such as mandibular plane or the A-Pog line and lack precise visibility of the anatomy of the symphysis and position in the bone of each individual tooth.<sup>17</sup> Often, mandibular incisors that are positioned within the normal range of 85°–95° to the mandibular plane present with significant variations with respect to their position within the symphysis and with different amounts of supporting bone. This variation can only be identified with 3D images (Fig. 1).

CBCT imaging allows for an additional perspective into understanding how mucogingival problems relate to orthodontic tooth movement by allowing us to differentiate whether the problem lies in the tooth position, the anatomy of the surrounding bone, or both (Fig. 2). A weak



**Figure 1.** CBCT images of lower incisors (from different patients) positioned within 85°–95° to the mandibular plane but with a diverse positioning within the symphysis and with differing amounts of alveolar bone support.



**Figure 2.** CBCT images of mandibular incisors with recession (tooth 24) from 2 different patients. (A) The lower incisor is centered in the symphysis but presents with an alveolar bone deficiency on the labial. (B) The mandibular incisor is positioned labial in relationship to the symphysis.

correlation has been reported between gingival thickness and underlying bone thickness, although a positive correlation has been identified between crestal alveolar bone thickness and width of the gingiva.<sup>18</sup> Cook et al.<sup>19</sup> reported that thin gingival biotype was associated with thinner labial plate thickness. It should be noted that patients with a thick, wide band of keratinized gingiva may present with deficient alveolar bone. Mandelaris et al.<sup>20</sup> suggested that when studying alveolar bone with CBCT, one must differentiate between the crestal and radicular zones of alveolar bone. The dentoalveolar crestal zone is defined as the region from the CEJ to a point 4-mm apically and the dentoalveolar radicular zone is dependent upon the individual root length and is that area extending below the 4-mm line for the remaining root length. Both crestal and radicular bone can be identified as thick (>1 mm) or thin (<1 mm). Patients also may present with different combinations of alveolar bone thickness in both zones.<sup>20</sup>

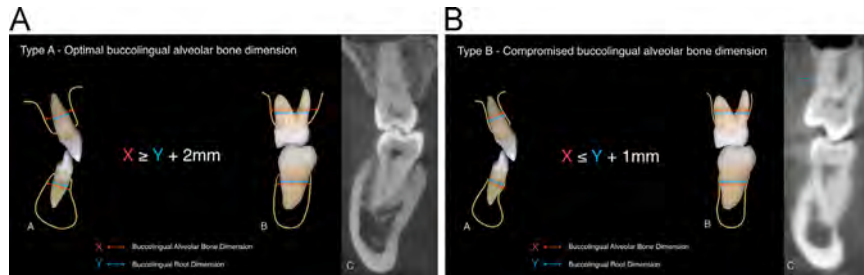
### 3D guided evaluation of the dentoalveolar complex

Advances in CBCT imaging technology and developments in 3D simulation software allow us to evaluate not only pretreatment dentoalveolar anatomy but also the projected tooth movement and its relationship relative to the alveolar bone. While the additional information gained provides a new perspective, it also brings with it many unanswered questions which will require ongoing research with randomized controlled studies. Many factors such as variations in equipment, settings, field of view, voxel size etc., play a critical role in the accuracy of the images. Thin labial plates, for example, may or may not be evident on

a scan based on these factors. According to Patcas et al.,<sup>21</sup> even the 0.125-mm voxel protocol does not depict the thin buccal alveolar bone covering reliably, and there is a risk of overestimating fenestrations and dehiscences. In a recent study by Sun et al.<sup>22</sup> similar findings were reported with CBCT images having some diagnostic value for detecting bony dehiscences and fenestrations; however, this method might overestimate the actual measurements.

### *Buccolingual alveolar bone dimension*

In the ideal situation, the tooth is positioned in the center of the alveolus, to receive axial loading with bone covering the root circumferentially 1–2 mm below the CEJ with at least 1 mm of bone thickness on the labial and lingual surfaces of the root. We suggest evaluating the buccolingual (BL) alveolar and basal bone dimension in relationship to individual buccolingual root dimension. In the optimal environment, when the tooth is centered in alveolar bone, the BL bone dimension should be at minimum 2-mm wider than the root dimension at any given root cross-section (Type A) to allow minimal root coverage within alveolar bone of 1 mm in thickness on both labial and lingual surfaces of the root (Fig. 3A). Anything less should be considered as compromised (Type B) and will present a risk for the development of gingival recession (Fig. 3B). Type B alveolar bone may be subdivided into Type B-1 (thin alveolar plate less than 1 mm in thickness), Type B-2 (fenestration) and Type B-3 (dehiscence) and is found either on the labial, lingual or both root surfaces. Teeth with dehiscences (Type B-3) and thin overlying gingiva are the most susceptible to gingival recession.



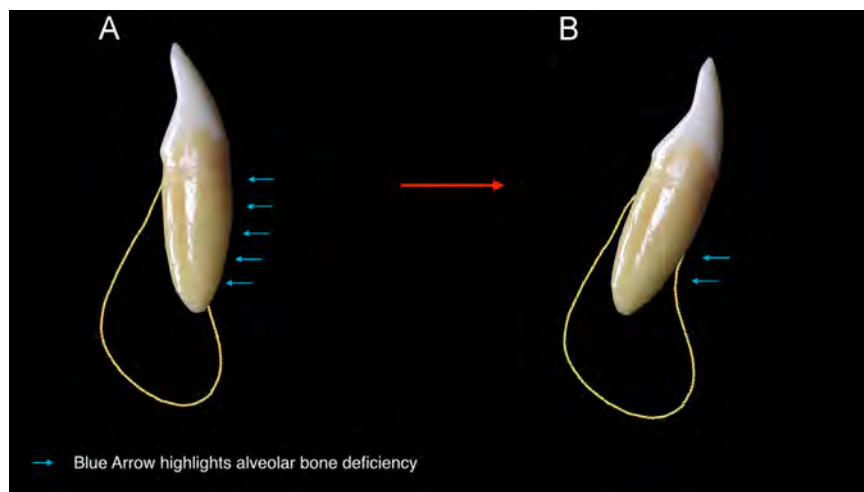
**Figure 3.** (A). Type A: A—Optimal buccolingual alveolar bone dimension of the anterior teeth. B—Posterior teeth. C—Example of Type A bone as shown on a CBCT coronal slice at the first molar. (B) Type B: A,B—Compromised buccolingual alveolar bone dimension of the anterior and posterior teeth. C—Example of Type B bone as shown on a CBCT coronal slice at the first molar.

### Tooth position

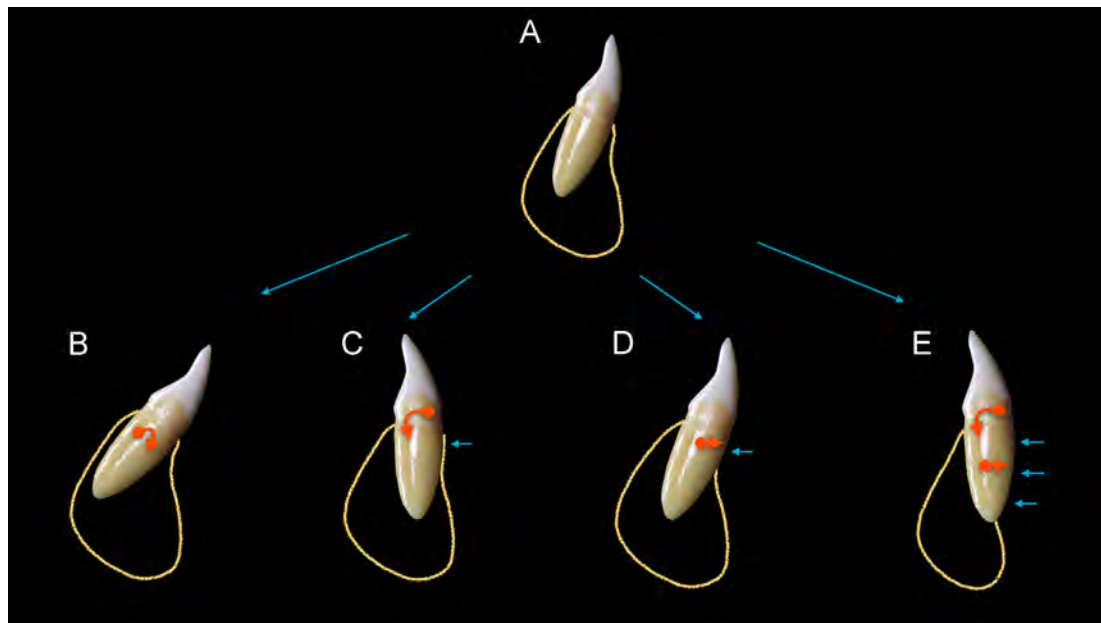
CBCT examination of the dentoalveolar complex also includes evaluation of the pretreatment and projected spatial position of the tooth within bone. In some situations, the tooth might be positioned off-axis and present radiographically with fenestrations and dehiscences with sufficient quantity of surrounding bone to support it in proper position (Fig. 4A). In these situations, the determination needs to be made whether anticipated orthodontic treatment will improve tooth position in the bone or not. In some situations, positioning the tooth in the center of the alveolar bone may improve dehiscences and fenestrations and even possibly gingival recession<sup>23</sup> (Fig. 4B). If that improvement is feasible, many mucogingival and alveolar bone deficiencies can be re-evaluated after the tooth

position has been addressed. However, in most situations this improvement is not possible with orthodontic tooth movement alone.

A more common clinical scenario is when the tooth movement may result in a situation with more compromised soft tissue and bone support.<sup>24</sup> With advances in 3D software, the majority of the tooth movement can be simulated before treatment begins. Fig 5 illustrates possible projected tipping and bodily movements of the mandibular incisor from the original optimal position (A) in the center of the ridge and the effects on the alveolar bone. Image B, for example, shows that significant labial tipping will not compromise the alveolar housing, while lingual tipping (C), labial bodily movement (D), and combination of lingual tipping and labial root movement (E), will compromise alveolar bone support.



**Figure 4.** (A) Retroclined lower incisor with severe labial dehiscence related to labial root position. (B) The same tooth after orthodontic movement into the center of the symphysis presents with improved labial alveolar bone support.



**Figure 5.** Projected tooth movement with alveolar bone implications. (A) Optimal tooth position in the symphysis with optimal labial and lingual alveolar bone support. (B) Labial tipping with no effects on the alveolar bone support. (C) Lingual tipping with thinning of the labial alveolar bone. (D) Labial bodily movement with an anticipated development of a labial dehiscence. (E) Lingual crown tipping and labial root torque outside the symphysis with the anticipated development of a severe labial dehiscence.

By studying dentoalveolar anatomy in 3D at the individual tooth level, we may be able to better identify patients at risk of developing mucogingival problems and also to understand the underlying anatomy of the existing mucogingival deformities.

#### ***Pre-orthodontic comprehensive 3D guided periodontal evaluation***

Patients with malocclusion often present for orthodontic treatment with periodontal manifestations of varying degrees, thin gingival biotype and deficient alveolar bone support.<sup>25,26</sup> A comprehensive periodontal evaluation is essential for all adult patients and when indicated, for selective adolescent patients with thin periodontium.

The presence of orthodontic appliances makes oral care challenging and may present a risk for the development of plaque-induced gingival inflammation.<sup>27</sup> Additionally, some types of orthodontic tooth movement may position the teeth outside the envelope of periodontal support. The clinical periodontal evaluation includes measurements of sulcular probing depth,

gingival bleeding index, thickness and width of the attached and keratinized gingiva and frenum anatomy. Conventional periapical radiographs reveal the interproximal bone level, presence of a lamina dura and root length, but are limited in the evaluation of the buccolingual dentoalveolar anatomy. 3D imaging provides additional information to assess the buccolingual anatomy, and when combined with the clinical exam, will serve as a guide to identify patients with anatomic risk factors for attachment loss prior to initiating tooth movement.

When identifying mucogingival problems and potential risks of developing them in orthodontic patients, 3 scenarios may be identified:

- (1) *Pre-existing mucogingival conditions.* When patients present for orthodontic treatment with gingival recession, with or without lack of attached gingiva and high frenum attachment.
- (2) *Pre-existing risks.* When patients present with Type B buccolingual alveolar bone dimension accompanied by thin or thick gingiva without clinical manifestations of mucogingival problems.

- (3) *Projected risks*: When the anticipated tooth movement is predisposed to the development of dehiscences, fenestrations and gingival recession.

First and foremost, educating patients in proper oral hygiene is fundamental to prevent attachment loss during and after orthodontic treatment.

With pre-existing mucogingival conditions, grafting should be considered when there is a risk for the progression of attachment loss during or after tooth movement. This is usually related to compromised oral hygiene, labial tooth movement and lack of attached gingiva. When the patient has a wide band of keratinized tissue, free of inflammation and the anticipated tooth movement will not exceed beyond the bone support, root coverage may be postponed until after orthodontic treatment.

When evaluating patients at risk for developing attachment loss during or after orthodontic treatment, initial identification of the tooth position is critical. Teeth positioned outside of bone support and in traumatic occlusal relationships may significantly contribute to exacerbation of mucogingival problems. Therefore, positioning them back into bone and relieving occlusal trauma should precede surgical intervention. In some instances, a mucogingival problem will improve after occlusal trauma is eliminated and surgical intervention may be avoided (Fig. 6).

#### ***Pre-orthodontic periodontal augmentation***

Once it has been determined that orthodontic tooth movement will present a risk for

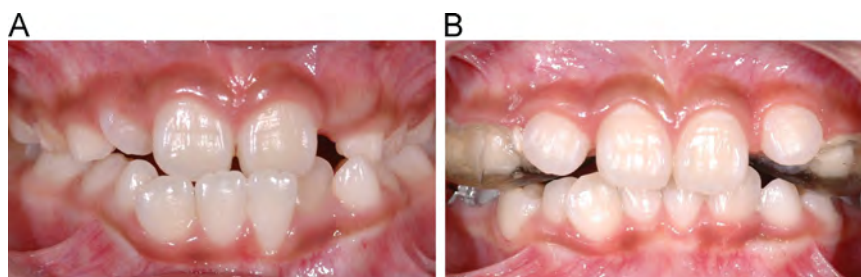
attachment loss, periodontal augmentation procedures should be considered.

Augmentation may include manipulation within the soft tissue, the hard tissue, or a combination of both based on the clinical and radiographic findings and the treatment plan. Therapeutic grafting is indicated in patients with pre-existing mucogingival conditions, while prophylactic grafting is performed in situations of pre-existing or projected risks.

When performing periodontal augmentation surgery, oral hygiene is critical to optimal healing. Gingival inflammation related to poor oral care will compromise healing and presents challenges to diagnose the true periodontal condition of the marginal gingival tissue. Placement of orthodontic appliances should be delayed until after soft tissue healing takes place (4-6 weeks post-surgery) when the patient resumes a regular oral hygiene regimen.

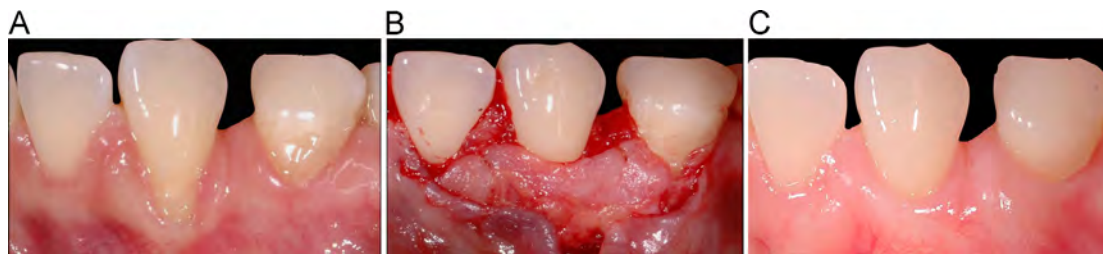#### ***Soft tissue augmentation***

Pre-orthodontic soft tissue augmentation is performed to address existing mucogingival deformities (i.e., gingival recession) (Fig. 7) as well as to convert a patient from a thin gingival biotype to a biotype less susceptible to periodontal breakdown during tooth movement (Fig. 8). Autogenous free gingival and subepithelial connective tissue grafts as well as skin allografts have been successfully used for gingival augmentation.<sup>28,29</sup> Autogenous soft tissue grafting procedures require a thorough understanding of the anatomic relationships to vital structures in recipient and donor sites. Free gingival grafts may be harvested from palatal and buccal areas, depending on the required



**Figure 6.** (A) A 7-year-old male patient presents with an anterior crossbite and crowding with lack of attached gingiva on tooth 24. (B) 6 Months after addressing the anterior crossbite and improving the lower incisor crowding, tooth 24 presents with a sufficient band of keratinized gingiva without the need for surgical intervention.





**Figure 7.** (A) Gingival recession on tooth 22 with no attached keratinized gingiva. (B) A SCTG was performed prior to tooth movement to address the recession and create keratinized attached gingiva. (C) Complete root coverage was achieved with a 2 mm band of keratinized attached gingiva at 1 month post-surgery.

graft size, thickness and quantity of available donor tissue.

A recently held AAP Regeneration Workshop (2015) concluded that in optimal plaque-control conditions, in the absence of inflammation, there is no need for a minimal width of keratinized gingiva to prevent attachment loss. However, in situations when plaque control is suboptimal as during orthodontic treatment, a minimum width of 2 mm of keratinized tissue with 1 mm of attached gingiva is required.<sup>29</sup> This workshop recommended the FGG as a standard for the gain of keratinized gingiva, although the free connective tissue graft (FCTG) may also fulfill this purpose.<sup>28</sup>

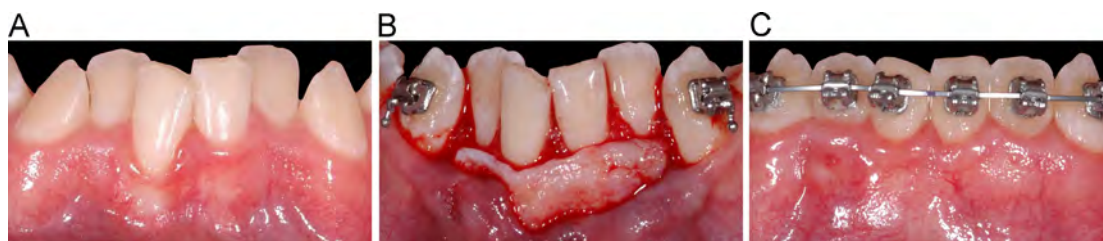Considering all treatment modalities in periodontal plastic surgery to create an adequate band of attached keratinized gingiva, the most optimal indication for the FGG procedure today in orthodontic patients is when it is performed in conjunction with a frenectomy. FGGs that are performed in conjunction with a frenectomy are usually smaller in size and almost always may be harvested from the buccal. This allows for expedited healing of the

recipient and donor sites due to thinner grafts, improves patient comfort, prevents reattachment of the frenum and allows for better graft blending with the surrounding gingiva (Fig. 9).

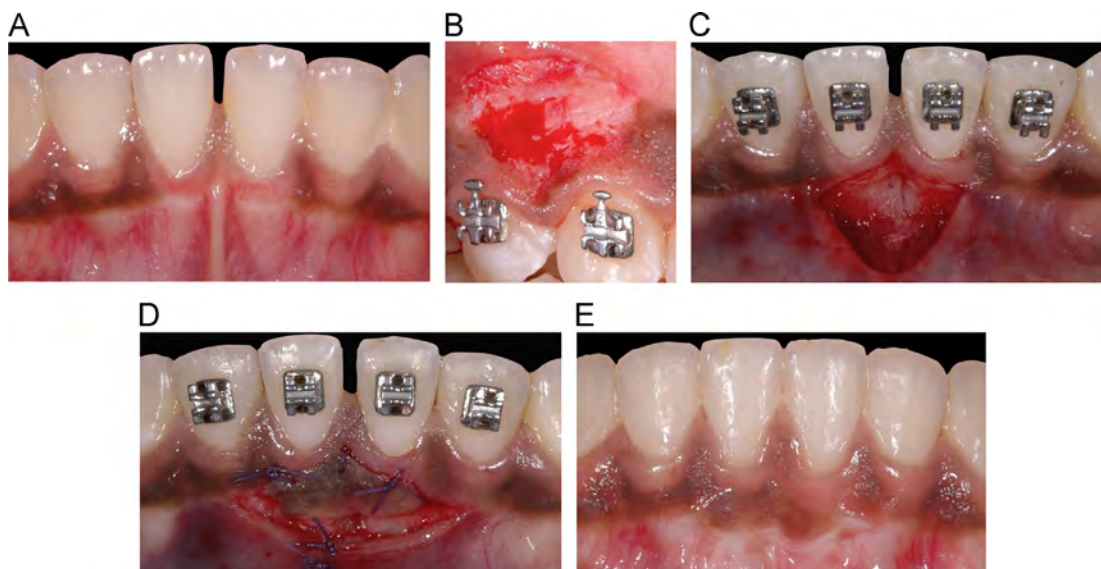
Since gingival recession is an alveolar bone problem, hard tissue grafting may also have to be considered in addition to the soft tissue augmentation. In these situations, it might be beneficial to combine a connective tissue graft with bone augmentation, which will be discussed later in this article.

#### *Hard tissue augmentation*

It is worth noting that the concept of surgical manipulation of the alveolar ridge facilitating tooth movement dates back to Kole<sup>30</sup> in 1959. Suya<sup>31</sup> specifically reported corticotomy facilitated orthodontics in 1991. Findings from this work lead Wilcko et al.<sup>32</sup> to explore the concept further. While additional randomized controlled trials are still needed to understand this process and to substantiate certain claims, initial case reports have shown stable



**Figure 8.** (A) An 11-year-old Caucasian male patient presents for orthodontic treatment with severe lower crowding, thin gingival tissue with no attached gingiva on tooth 25. (B) SCTG procedure was performed on the lower incisors to thicken the gingiva in order to prevent attachment loss during tooth movement. (C) 6 Months after grafting, lower incisors were aligned and presented with a thick band of coronally positioned keratinized gingiva.



**Figure 9.** (A) A 15-year old AA female presents for orthodontic treatment with thin labial gingiva and a high frenum attachment at the level of the mandibular central incisors. (B) Prior to orthodontic tooth movement, a FGG was harvested from the buccal gingiva between the maxillary right premolar and canine. (C and D) Transplantation to the frenectomy site with the purpose of widening the zone of keratinized gingiva and preventing re-attachment of the frenum. Buccal donor tissue was used for the sake of patient comfort. (E) 1-year post-treatment, mandibular incisors present with a healthy band of keratinized gingiva without signs of attachment loss.

results with a significant decrease in the time of treatment.<sup>32</sup> In addition to the benefit of a decrease in treatment time, the use of bone grafting materials, acting as scaffolding for additional bone formation, has been explored further to increase the envelope of tooth movement and still provide a stable periodontal outcome. Previous studies<sup>5,33,34</sup> have reported cases in which orthodontic corrections were achieved with movement into sites that would normally have been considered periodontally unhealthy if they had been completed using conventional methods without surgical intervention.

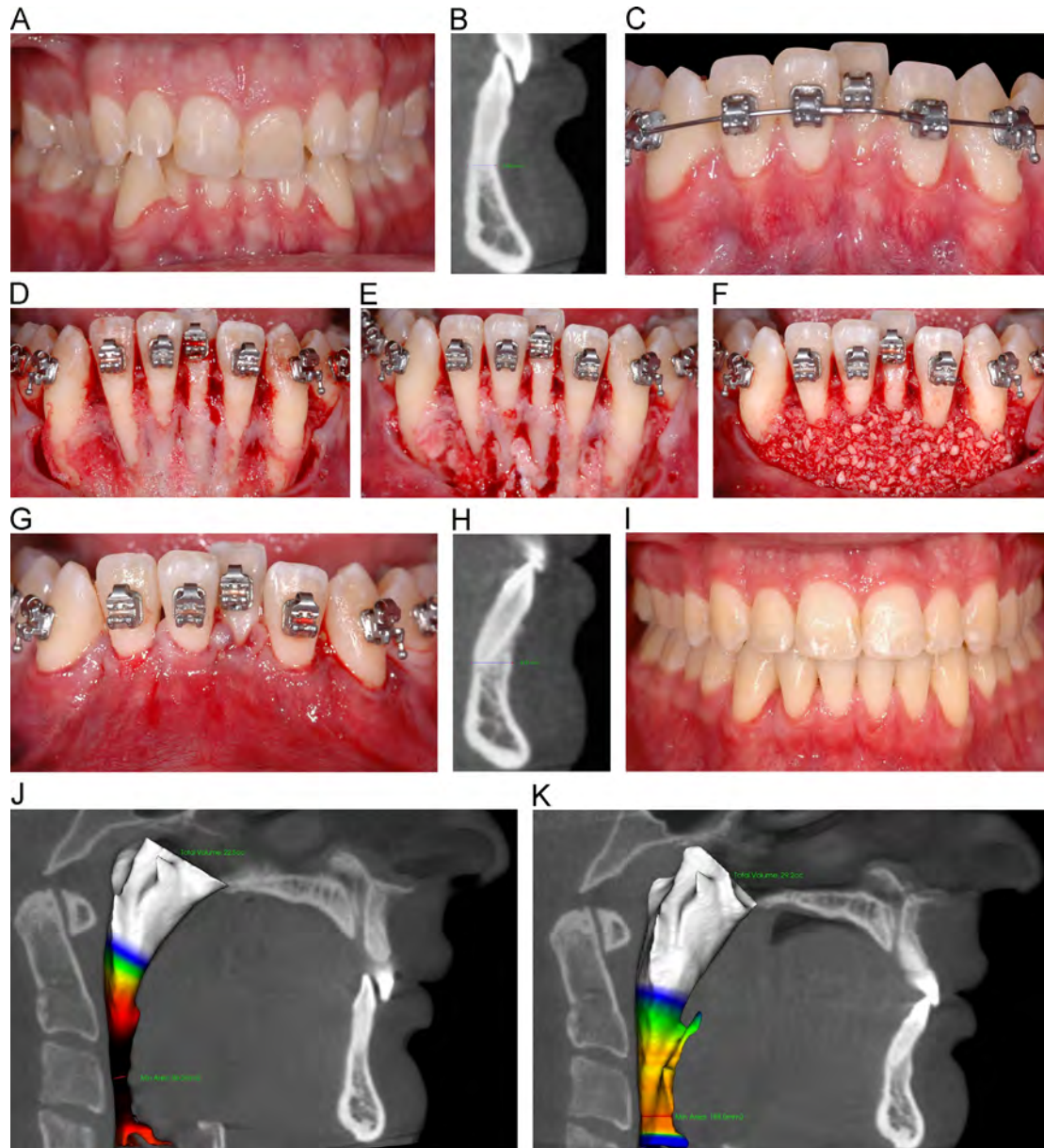
Bone augmentation is beneficial for orthodontic patients with Type B alveolar anatomy, in particular when non-extraction therapy is elected for airway and esthetic considerations (Fig. 10). Studying the pre-existing and projected dentoalveolar anatomy will aid in the decision-making of whether bone grafting can be limited to the labial area or extended to the labial and lingual root surfaces (Fig. 11). Anatomic limits also have to be considered with respect to graft containment. Augmentation of the crestal

bone may prevent gingival recession, while augmentation in the radicular zone may prevent root movement outside the alveolar bone dimension and increase stability of the achieved tooth alignment.

Although decrease in treatment time<sup>35</sup> and post-orthodontic stability<sup>36</sup> have been reported in the literature as a result of this procedure, the effectiveness of bone augmentation has yet to be investigated.

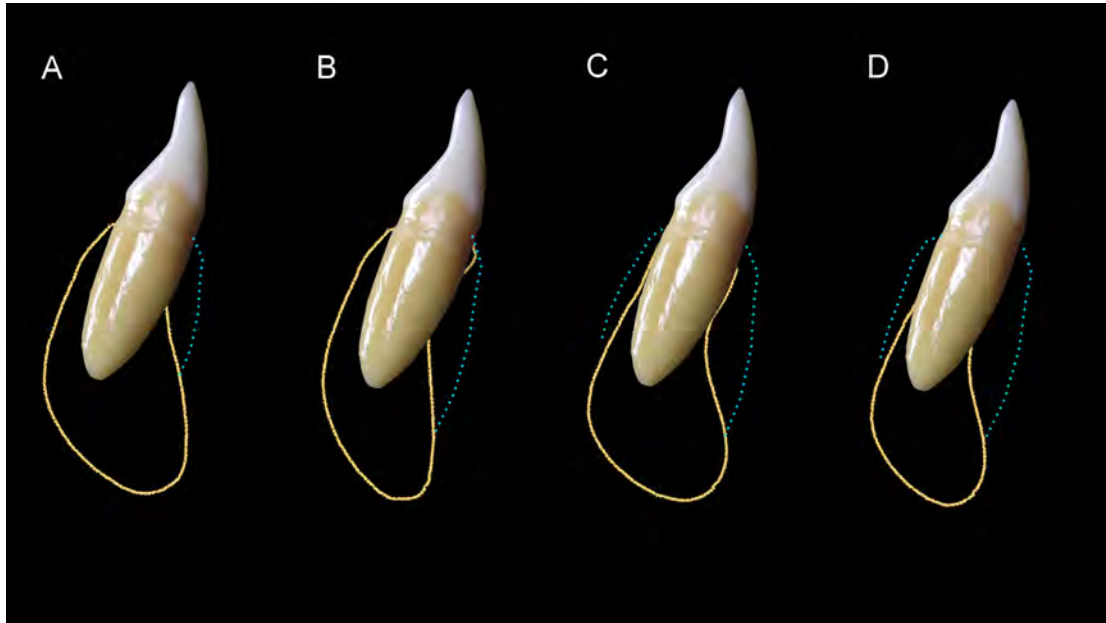
#### ***Combined hard and soft tissue augmentation***

When the clinical and radiographic exam reveals an underlying or projected soft and hard tissue deficiency as shown in Fig 12, combined soft and hard tissue augmentation may be the treatment of choice. Subepithelial connective tissue grafting may be done simultaneously with bone grafting or in a stepped approach. When soft tissue augmentation involves multiple teeth, a soft tissue allograft might be the material of choice as shown in Fig. 13.

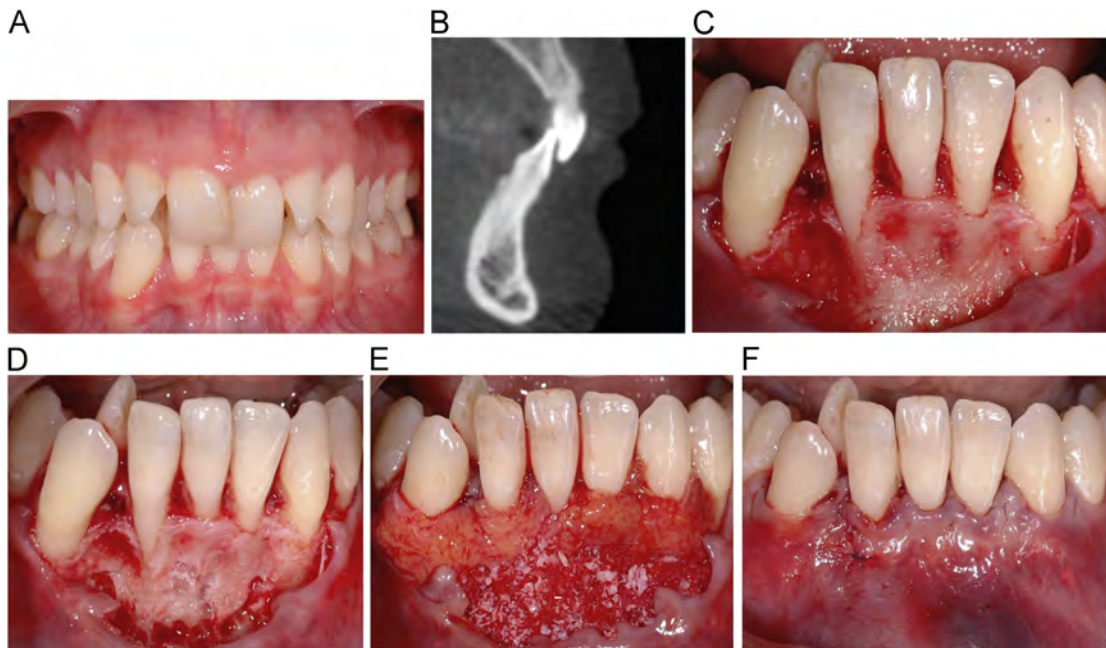


**Figure 10.** (A and B) A 21-year-old Caucasian male presents for orthodontic re-treatment with upper and lower crowding, thin gingival biotype and Type B alveolar bone on the mandibular anterior teeth. (C–G) Labial bone augmentation of the lower anterior teeth was completed with corticotomy and grafted with particulate freeze-dried bone allograft material. (H) CBCT sagittal slice of the post-treatment augmented labial alveolar bone with 3-mm increase in thickness at the level of lower incisor. (I) Final records taken 3 months after debond show thickening of the labial gingiva after orthodontic alignment in conjunction with prophylactic labial bone augmentation. (J) 3D image of the pretreatment airway with constriction in the retroglottal area of  $83.2 \text{ mm}^2$ . (K) 3D image of the post-treatment airway with increase of the airway volume in the retroglottal area to  $188 \text{ mm}^2$ .



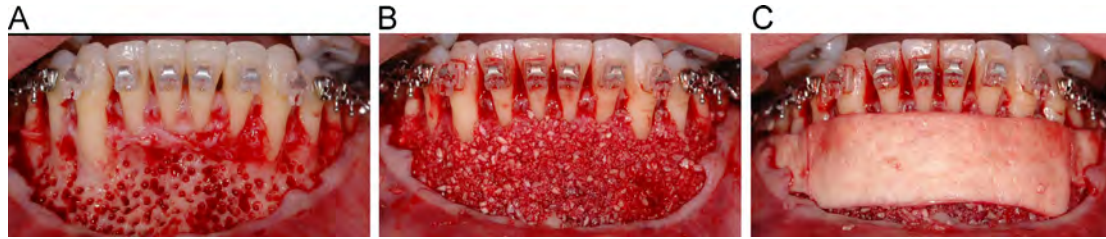

**Figure 11.** (A and B) labial, (C and D) labial and lingual bone augmentation (blue dotted line) based on CBCT findings of alveolar bone deficiency.



**Figure 12.** (A and B) A 28-year-old female patient presents for non-extraction orthodontic treatment with severe crowding, thin gingival biotype and deficient Type B bone support on the labial of lower anterior teeth. (C–F) A combination of labial soft and hard tissue augmentation was performed with subepithelial connective tissue graft in conjunction with freeze dried bone allograft and xenograft mixture prior to tooth movement.





**Figure 13.** (A–C) Combined soft tissue and hard tissue augmentation with an acellular dermal matrix and freeze-dried bone allografts performed on a 39-year-old female patient with thin gingiva and Type B alveolar bone.

## Conclusions

In conjunction with the clinical exam, a 3D evaluation of the dentoalveolar anatomy provides further insight to diagnose and treatment plan in 3 dimensions.

While the use of 3D imaging provides us with a valuable piece of additional information, some level of caution should be exercised. It is important to note that accuracy in visualizing dentoalveolar anatomy may vary based on the machine type, the resolution and individual machine settings.<sup>37</sup> The experienced diagnostician must take into consideration the volume of the scan as well as the voxel size when making a diagnosis utilizing 3D images. With full volume scans and a higher voxel size, it is possible that the diagnosis of an absence of bone may actually be made when there is a thin plate of existing bone. Alveolar bone might not be accurately identified during the state of active remodeling, as evident during orthodontic tooth movement. When CBCT images are taken, the ALARA principle should be followed.

Modalities of treatment may be in the form of soft tissue augmentation, hard tissue augmentation or a combination of both. Soft tissue procedures like the free gingival graft and the subepithelial connective tissue graft have provided predictable and stable results for many years.<sup>27,28</sup> Hard tissue grafts appear to be promising,<sup>34</sup> however, further studies are required to evaluate this methodology. Additional studies are also required to help determine the optimal timing for hard and soft tissue grafting procedures.

The ultimate goal of the clinician is to provide for a stable and healthy environment that can be adequately maintained by the patient. An accurate and thorough diagnosis will guide the clinician in choosing the appropriate augmentation methodology when necessary.<sup>37</sup>

## References

1. AAP position paper: parameter on mucogingival conditions. *J Periodontol.* 2000;71:861–862.
2. Löst C. Depth of alveolar bone dehiscences in relation to gingival recessions. *J Clin Periodontol.* 1984;11:583–589.
3. Loe H, Anerud A, Bousen H. The natural history of periodontal disease in man: prevalence, severity and extent of gingival recession. *J Periodontol.* 1992;63:489–495.
4. Slutzkey S, Levin L. Gingival recession in young adults: occurrence, severity, and relationship to past orthodontic treatment and oral piercing. *Am J Orthod Dentofacial Orthop.* 2008;134:652–656.
5. Richman C. Is gingival recession a consequence of an orthodontic tooth size and/or tooth position discrepancy? A paradigm shift *Compendium.* 2011;32:62–69.
6. Zachrisson BU, Orthodontics and Periodontics. In: Lindhe J, Lang N, Karring T, eds. *Clinical Periodontology and Implant Dentistry.* 4th ed. Oxford: Blackwell Munksgaard; 2003:744–780.
7. Kloukos D. Indication and timing of soft tissue augmentation at maxillary and mandibular incisors in orthodontic patients: a systematic review. *Eur J Orthod.* 2014;36:442–449.
8. Dorfman HS. Mucogingival changes resulting from mandibular incisor tooth movement. *Am J Orthod Dentofacial Orthop.* 1978;74:286–297.
9. Wennstrom J. Mucogingival consideration in orthodontic treatment. *Semin Orthod.* 1996;2:46–54.
10. Baker DL, Seymour GJ. The possible pathogenesis of gingival recession. *J Clin Periodontol.* 1976;3:208–219.
11. Bernimoulin JP, Curilovis Z. Gingival recession and tooth mobility. *J Clin Periodontol.* 1977;4:107–114.
12. Zachrisson BU, Clinical interrelation of orthodontics and periodontics. In: Barrer HG, ed. *Orthodontics, The State of the Art.* Philadelphia: University of Pennsylvania Press; 1981.
13. Wennstrom JL, Lindhe J, Sinclair F, et al. Some periodontal tissue reactions to orthodontic tooth movement in monkeys. *J Clin Periodontol.* 1987;14:121–129.
14. Richardson CR, Allen EP, Chambrone L, et al. Periodontal soft tissue root coverage procedures: practical applications from the AAP regeneration workshop. *Clin Adv Periodontics.* 2015;5:2–10.
15. Vanchit J, Langer L, Rasperini G, et al. Periodontal soft tissue non-root coverage procedures: Practical applications from the AAP regeneration workshop. *Clin Adv Periodontics.* 2015;5:11–20.

16. Rupprecht R, Horning G, Nicoll B, et al. Prevalence of dehiscences and fenestrations in modern american skulls. *J Periodontol.* 2001;72:722–729.
17. Nauert K, Berg R. Evaluation of labio-lingual bony support of lower incisors in orthodontically untreated adults with the help of computed tomography. *J Orofacial Orthop.* 1999;60:321–334.
18. La Rocca AP, Alemany AS, Levi P, et al. Anterior maxillary and mandibular biotype: relationship between gingival thickness and width with respect to underlying bone thickness. *Implant Dent.* 2012;21:507–515.
19. Cook R, Mealey B, Verrett R, et al. Relationship between clinical periodontal biotype and labial plate thickness: an in vivo study. *Int J Periodontics Restorative Dent.* 2011;31:345–354.
20. Mandelaris GA, Vence BS, Rosenfeld AL, et al. A classification system for crestal and radicular dentoalveolar bone phenotypes. *Int J Periodontics Restorative Dent.* 2013;33:289–296.
21. Patcas R, Muller L, Ullrich O, et al. Accuracy of cone-beam computed tomography at different resolutions assessed on the bony covering of the mandibular anterior teeth. *Am J Orthod Dentofacial Orthop.* 2012;141:41–50.
22. Sun L, Zhang L, Shen G, et al. Accuracy of cone-beam computed tomography in detecting alveolar bone dehiscences and fenestrations. *Am J Orthod Dentofacial Orthop.* 2015;147:313–323.
23. Karring T, Nyman S, Thilander B, et al. Bone regeneration in orthodontically produced alveolar bone dehiscences. *J Periodontol Res.* 1982;17:309–315.
24. Handelman C. The Anterior Alveolus: its importance in limiting orthodontic treatment and its influence on the occurrence of iatrogenic sequelae. *Angle Orthod.* 1996;66:95–110.
25. Enhos S, Uysal T, Yagci A, et al. Dehiscence and fenestration in patients with different vertical growth patterns assessed with cone-beam computed tomography. *Angle Orthod.* 2012;82:868–874.
26. Ngom P, Diagne F, Benoist H, et al. Intraarch and interarch relationships of the anterior teeth and periodontal conditions. *Angle Orthod.* 2006;76:236–242.
27. Migliorati M, Isaia L, Cassaro A, et al. Efficacy of professional hygiene and prophylaxis on preventing plaque increase in orthodontic patients with multibracket appliances: a systematic review. *Eur J Orthod* 2014;1–11.
28. Chambrone L, Tatakis D. Periodontal soft tissue root coverage procedures: a systematic review from the AAP regeneration workshop. *J Periodontol.* 2015;86:S8–S51.
29. Scheyer ET, Sanz M, Dibart S, et al. Periodontal soft tissue non-root coverage procedures: a consensus report from the AAP regeneration workshop. *J Periodontol.* 2015;86:S73–S76.
30. Kole H. Surgical operations of the alveolar ridge to correct occlusal abnormalities. *Oral Surg Oral Med Oral Pathol.* 1959;12:515–529.
31. Suya H. Corticotomy in orthodontics. In: Hosl E, Baldauf A, eds. *Mechanical and Biological Basics in Orthodontic Therapy.* Heidelberg: Huthig Buch; 1991:207–226.
32. Wilcko WM, Wilcko MT, Bouquot JE, et al. Rapid orthodontics with alveolar reshaping: two case reports of decrowding. *Int J Periodontics Restorative Dent.* 2001;21:9–19.
33. Gantes B, Rathbun E, Anholm M. Effects of the periodontium following corticotomy-facilitated orthodontics: case reports. *J Periodontol.* 1990;61:234.
34. Wilcko MT, Wilcko WM, Pulver JJ, et al. Accelerated osteogenic orthodontics technique: a 1-stage surgically facilitated rapid orthodontic technique with alveolar augmentation. *J Oral Maxillofac Surg.* 2009;67:2149–2159.
35. Shoreibah EA, Ibrahim SA, Attia MS, et al. Clinical and radiographic evaluation of bone grafting in corticotomy-facilitated orthodontics in adults. *J Int Acad Periodontol.* 2012;14:105–113.
36. Ferguson DJ, Makki L, Stapelberg R, et al. Stability of the mandibular dental arch following periodontally accelerated osteogenic orthodontics therapy: preliminary studies. *Semin Orthod.* 2014;20:239–246.
37. Molen AD. Considerations in the use of cone-beam computed tomography for buccal bone measurements. *Am J Orthod Dentofacial Orthop.* 2010;137:S130–S135.

---

# Implants for orthodontic patients with missing anterior teeth: Placement in growing patients—Immediate loading

Mohamed Bayome, Yoon-Ah Kook, Yoonji Kim, Cheol Won Lee, and Jae Hyun Park

**There is a marked increase in the importance of facial esthetics. This means that interdisciplinary treatment plans are an important strategy for achieving pleasing facial appearance with dental treatment. Over the decades, missing anterior teeth have been a challenge for clinicians and replacing them with an implant in children and adolescents was questionable. One concern was that an implant might influence the growth of the alveolar ridge, which could compromise facial esthetics in the long run since the positioning of the implant within the alveolar ridge plays a key role in the esthetic outcome. Another concern was the long-term effects of immediate loading of orthodontic force on implants. The short-term effects have been evaluated but not the long-term implications. This article summarizes a discussion about the effects of implants to restore missing anterior teeth in growing patients and the effect of the immediate application of orthodontic forces on newly placed implants. (Semin Orthod 2016; 22:64–74.) © 2016 Elsevier Inc. All rights reserved.**

## Introduction

**H**ow a person looks can be an important factor in whether or not they are successful in life and appearance affects self-esteem and social acceptance. Facial esthetics are a big part of appearance, and since teeth are a prominent facial feature, dental appearance is a key part of facial esthetics, especially if there are missing anterior teeth. In addition, they have a

significantly higher impact on the oral health-related quality of life than missing posteriors.<sup>1–4</sup>

There has always been a question whether missing teeth should be replaced with an implant or fixed prosthesis, or whether the space should be closed orthodontically. The decision depends on several factors including age, profile, space availability, condition of adjacent teeth, gingival display on smiling, type of malocclusion, overjet, and overbite.<sup>5,6</sup> Another study showed that it also depends on the skill of the orthodontist and his/her work environment.<sup>7</sup> Andrade et al.<sup>8</sup> reported the lack of scientific evidence for any type of treatment for agenesis of the maxillary lateral incisors.

Dental implants have been one of the treatments of choice for missing anterior teeth. Their success rate has been reported extensively and depends on age, gender, which side, and which jaw, among other factors. On average, implants have a survival rate better than 97% and are expected to last for decades.<sup>9</sup> However, most of the literature focuses just on adult patients.

Interestingly, children and adolescent suffer from the same conditions requiring placement of dental implants, even though the frequency is lower than that of adults. The prevalence of

---

*Department of Dentistry, College of Medicine, The Catholic University of Korea, Seoul, South Korea; Department of Postgraduate Studies, The Universidad Autónoma del Paraguay, Asunción, Paraguay; Department of Orthodontics, College of Medicine, Seoul St. Mary's Hospital, The Catholic University of Korea, Seoul, South Korea; Department of Prosthodontics, College of Medicine, Seoul St. Mary's Hospital, The Catholic University of Korea, Seoul, South Korea; Postgraduate Orthodontic Program, Arizona School of Dentistry & Oral Health, A.T. Still University, Mesa, AZ; Graduate School of Dentistry, Kyung Hee University, Seoul, South Korea.*

*Address correspondence to Jae Hyun Park, DMD, MSD, MS, PhD, Postgraduate Orthodontic Program, Arizona School of Dentistry & Oral Health, A.T. Still University, Mesa, AZ. E-mail: JPark@atsu.edu*

© 2016 Elsevier Inc. All rights reserved.

1073-8746/12/1801-\$30.00/0

<http://dx.doi.org/10.1053/j.sodo.2015.10.009>

traumatic dental injury to anterior teeth in children ranges from 9% to 35% depending on the population.<sup>10–13</sup> These injuries resulted in missing teeth in 10.9% of the cases.<sup>13</sup> In addition, congenitally missing teeth occurs in 1.6–15.7% of various modern societies.<sup>14–18</sup> However, clinicians have been reluctant to install implants in growing patients. Nevertheless, untreated dental problems have some negative impact on the quality of life of children.<sup>19</sup>

This article aims to demonstrate some orthodontic applications where implant placement can serve as an adjunctive treatment placement, especially in younger patient populations.

### ***Adjunctive orthodontic treatment prior to implantation***

When an edentulous area is left unrestored over an extended period of time, a more challenging clinical situation arises when there is an extrusion of the opposing teeth, tilting of neighboring teeth, and a vertically and horizontally resorbed ridge. Often, such deteriorated conditions will require orthodontic treatment prior to the start of any definitive restorative work.

In the anterior region, adjunctive orthodontic therapy may be necessary to address misalignment and tooth size discrepancy for better function and esthetics. Proper alignment of anterior teeth and creation of appropriate space enhances purely esthetic restorations not only by preserving restoration space but also by maintaining the desired interproximal alveolar contour and gingival embrasure form. In order to establish normal overjet and overbite, it might be necessary to position the implant labiolingually a bit beyond than the optimal position, which might in turn compromise the esthetic relationship between the gingiva and the crown by altering the ideal space required around the implant. The adjacent teeth may need to be increased in width with adhesive restoration or reduced by interproximal reduction.

Generally, there should be enough bone around an implant to prevent bone loss. When placed between two natural teeth, at least 1.0 mm of interdental space is essential. For an implant restoration, there should be 1.5 mm of bone between the implant and adjacent roots, or 3.0 mm of bone between adjacent implants to

prevent marginal bone loss and the presence of unesthetic papilla.<sup>20–22</sup> Since the standard implant diameter ranges between 3.5 and 4.2 mm, the narrowest edentulous space required is about 6.5 mm. However, when a narrow dental implant is used, the space required can be as small as 5 mm.

The proximity and inclination of adjacent teeth is important for the mesiodistal tooth position. The proximity of adjacent teeth is necessary to provide proximal support and volume of the interdental papilla. A mesially inclined tooth usually creates a more incisally located contact point and a much larger gingival embrasure, which requires more volume in order to achieve the same vertical height. However, this mesial inclination has an advantage in the case of implantation due to the thicker interproximal bone and lower risk of resorption. Hopeless teeth with diastemas have similar advantages.<sup>23</sup>

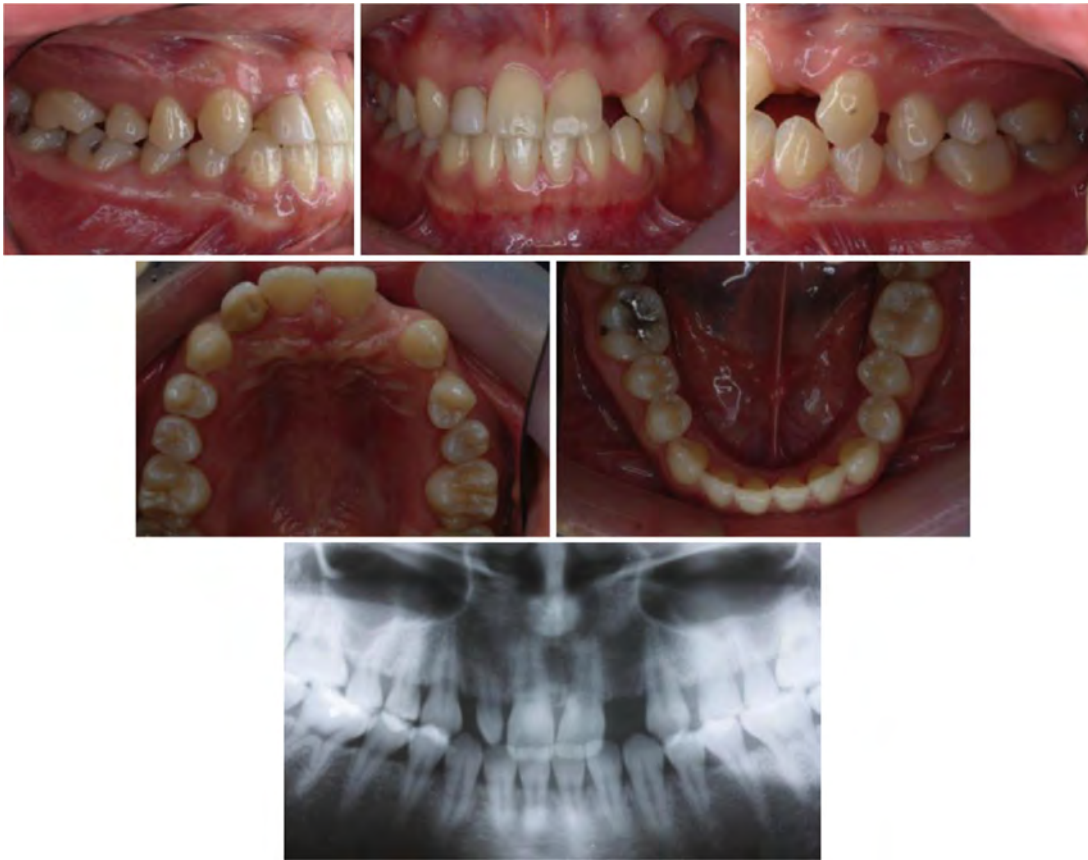### **Case 1**

A 27-year-old female was referred by a general dentist for orthodontic tooth movement before final restoration. The upper dental midline had been shifted to the left side and a missing maxillary lateral incisor caused spacing. Her peg-shaped, right lateral incisor had been previously restored as revealed in a panoramic radiograph. A bracket was bonded to the acrylic pontic in the left lateral incisor area and an arch wire was inserted to regain space to restore esthetic balance between the maxillary lateral incisors. The maxillary and mandibular dental midline coincided and adequate space was regained for the restoration. After debonding, an implant was placed in the maxillary lateral incisor area. A crown lengthening procedure was performed on the maxillary right lateral incisor to correct the gingival height (Figs. 1–4).

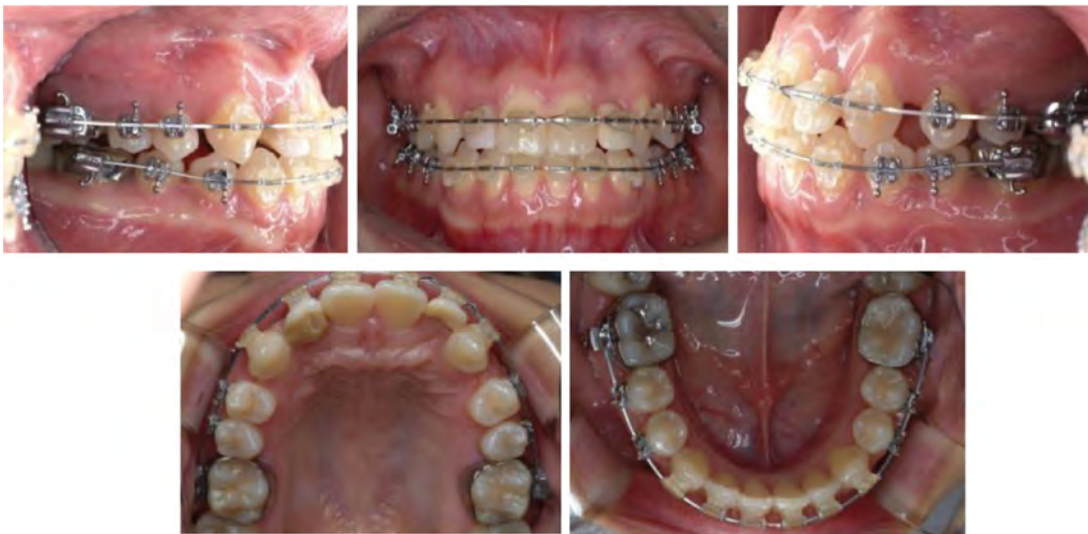### ***Temporary anchorage devices as temporary crown restoration***

There are several treatment options for a missing maxillary anterior tooth in adolescent patients including substitution, autotransplantation, and dental restoration. However, these methods each have limitations. An orthodontic miniscrew system (C-implant) may serve as an excellent treatment option to maintain edentulous space upon completion of active orthodontic

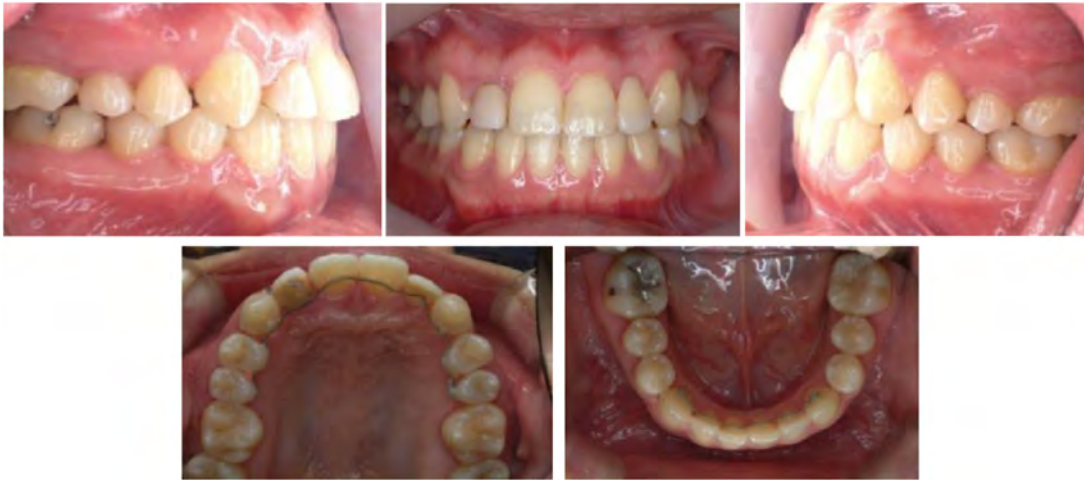



**Figure 1.** Case 1: pretreatment intraoral images and panoramic radiograph.



**Figure 2.** Case 1: treatment progress.



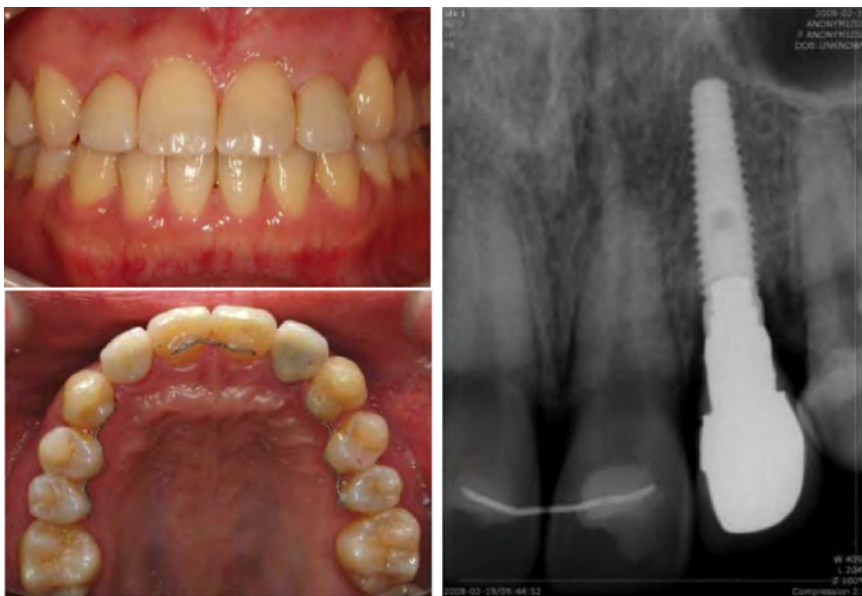**Figure 3.** Case 1: debonding intraoral images.

treatment. Temporary crown restorations are required after orthodontic treatment for young patients when implant placement needs to be delayed. An orthodontic C-implant system was placed in a 3 mm-wide edentulous space to build up a temporary crown restoration after a short period of orthodontic treatment to regain space for a missing permanent mandibular right lateral incisor (Fig. 5).<sup>24</sup> Another report replaced missing maxillary lateral incisors in growing patients with temporary crowns fixed to

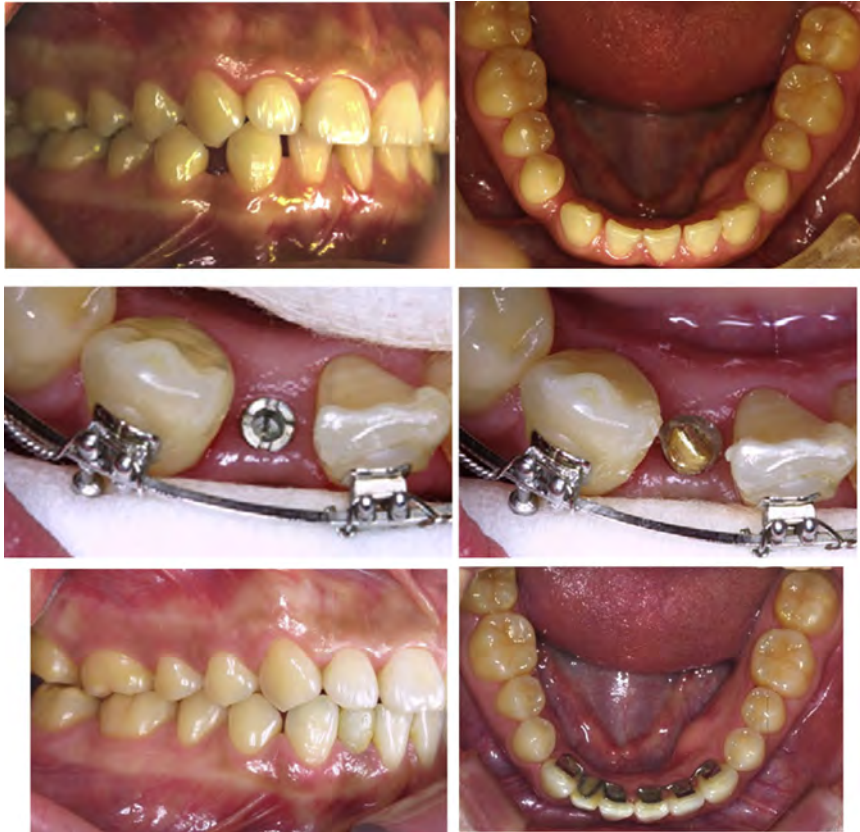miniscrews and documented with an 8-year follow-up.<sup>25</sup>

### Case 2

A C-implant was placed in the space resulting from an avulsed permanent maxillary right lateral incisor of a 14.6-year-old boy to prevent aggressive alveolar bone resorption resulting from dental trauma (Fig. 6). Location and path of the implant were verified with a cone-beam



**Figure 4.** Case 1: implant placement.



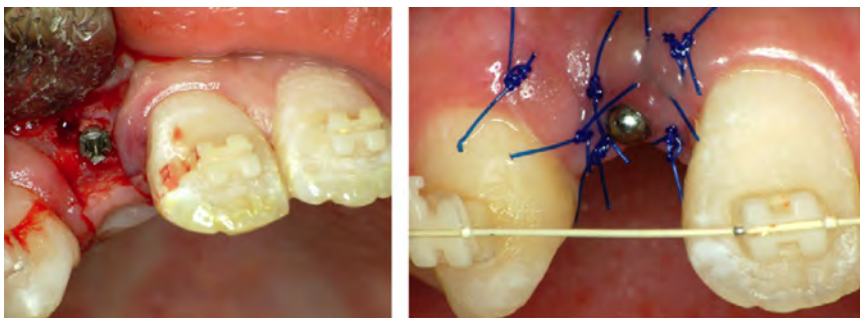
**Figure 5.** A C-implant placed in the edentulous space to support a temporary crown replacing mandibular right lateral incisor.

computed tomography (CBCT) scan. Crowns were fabricated with an indirect method of telescopic abutment casting and porcelain build-up (Fig. 7). The temporary crown restorations were retained successfully until patients were ready to proceed with a permanent restoration at a later time (Fig. 8). An orthodontic miniscrew system may serve as an excellent treatment

option to maintain edentulous space upon completion of active orthodontic treatment.<sup>24</sup>

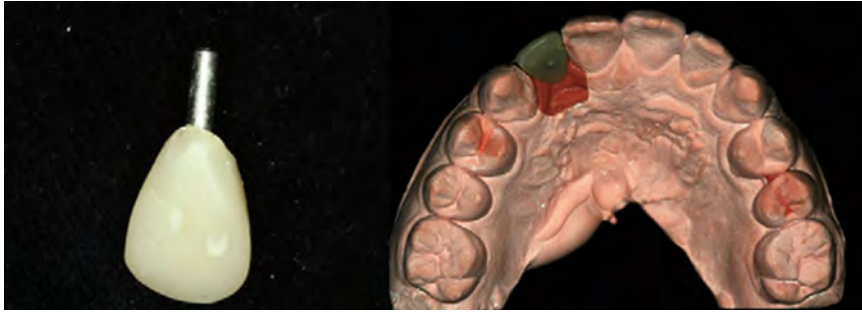
#### *Anterior teeth movement with block bone graft*

Resorption of the alveolar bone usually occurs after tooth extraction with a higher rate within the 1st year. Extraction of maxillary anterior



**Figure 6.** Case 2: a C-implant placed in the space of a missing permanent maxillary right lateral incisor of a 14.6-year-old boy.





**Figure 7.** Case 2: crown made by casting and porcelain build-up on a telescopic abutment.

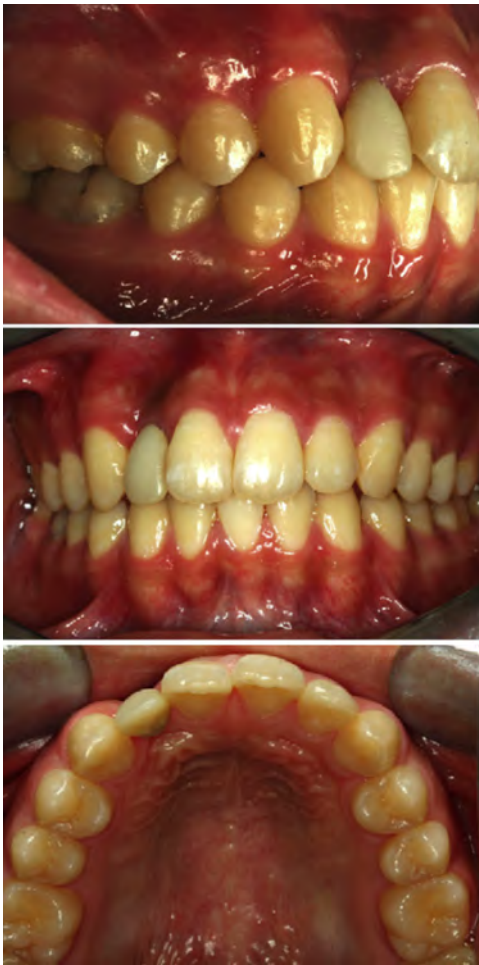teeth is associated with a progressive loss of bone, mainly from the labial side.<sup>26</sup> Several factors are claimed to be responsible for this such as disuse atrophy, decreased blood supply, and localized

inflammation.<sup>27</sup> Root replicates of polylactic acid (PLA)<sup>28</sup> or bioglass<sup>29</sup> have been produced to preserve the alveolar crest width and height after tooth loss, but their incomplete resorption may impair later implantation. Also, to prevent resorption, autogenous grafts have been used to fill the tooth socket.<sup>30,31</sup>

As people age, more of their mandibular incisors tend to be exposed, especially after their 40s. When insufficient papilla presents coupled with severe alveolar bone loss, achieving an esthetic treatment outcome becomes more challenging. One way to approach such a problem is to begin from the periodontal aspect to build up a healthier foundation for gingival architecture. In the case presented below, esthetic treatment results were enhanced by encouragement of papilla formation through movement of 2 lateral incisors into the missing central incisor position. Alternatively, a bone graft could also alleviate such conditions with insufficient alveolar ridge.

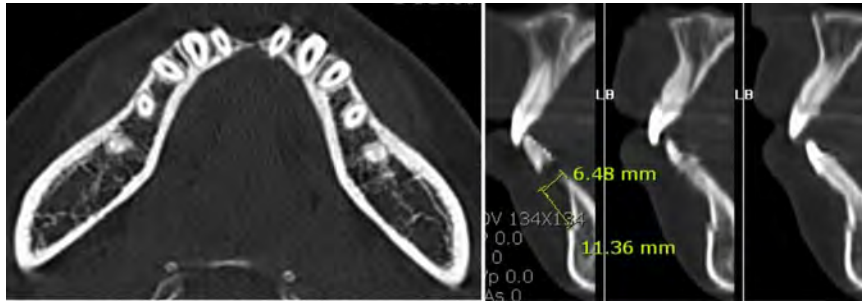### Case 3

A 20-year-old female with 2 missing mandibular central incisors that had been restored with a fixed retainer carrying 2 pontics. She requested implants rather than a fixed partial denture. Her alveolar bone thickness was too narrow to place implants (Fig. 9) based on a computed tomography (CT) image. Also, placing 2 implants next to each other in this area could produce unesthetic results. Therefore, bone graft from the mandibular symphysis was placed to augment the medial area of the alveolar bone (Fig. 10). Then, the 2 lateral incisors were moved to close the space in the midline using indirect



**Figure 8.** Case 2: 4 years retention of the temporary crown restoration.





**Figure 9.** Case 3: CT images showing that the alveolar bone thickness was too narrow to place implants.

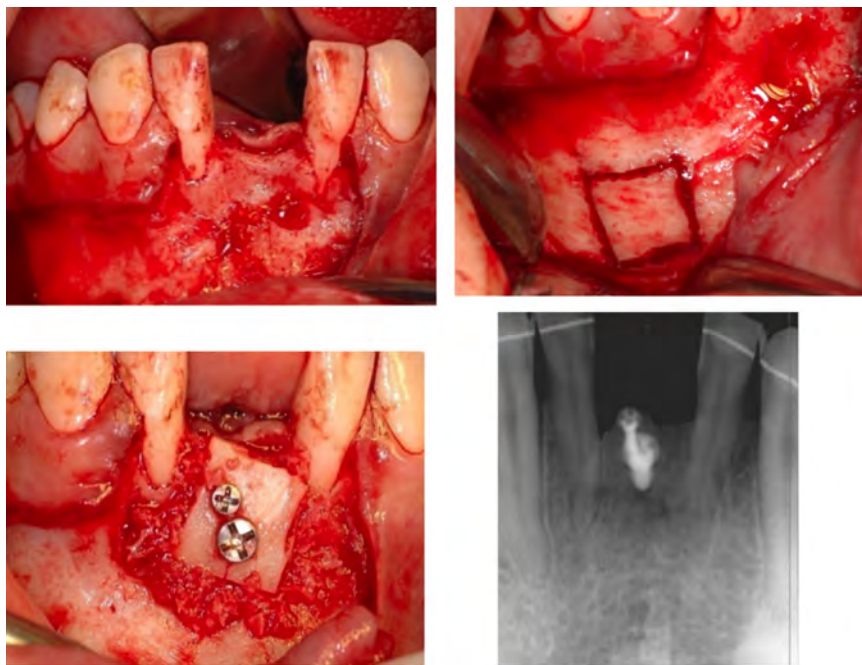
anchorage from a miniscrew (Orlus, 6 mm length, 1.6 mm in diameter). This resulted in crown tipping, so the roots were controlled by repositioning the brackets in an over corrected position and the 2 brackets were tied together. This insured sufficient inter-radicular space between the 2 lateral incisors and the canines. After 7 months of tooth movement, 2 implants were placed distal to the lateral incisors (Fig. 11).

#### ***Immediate vs. delayed loading of dental implants***

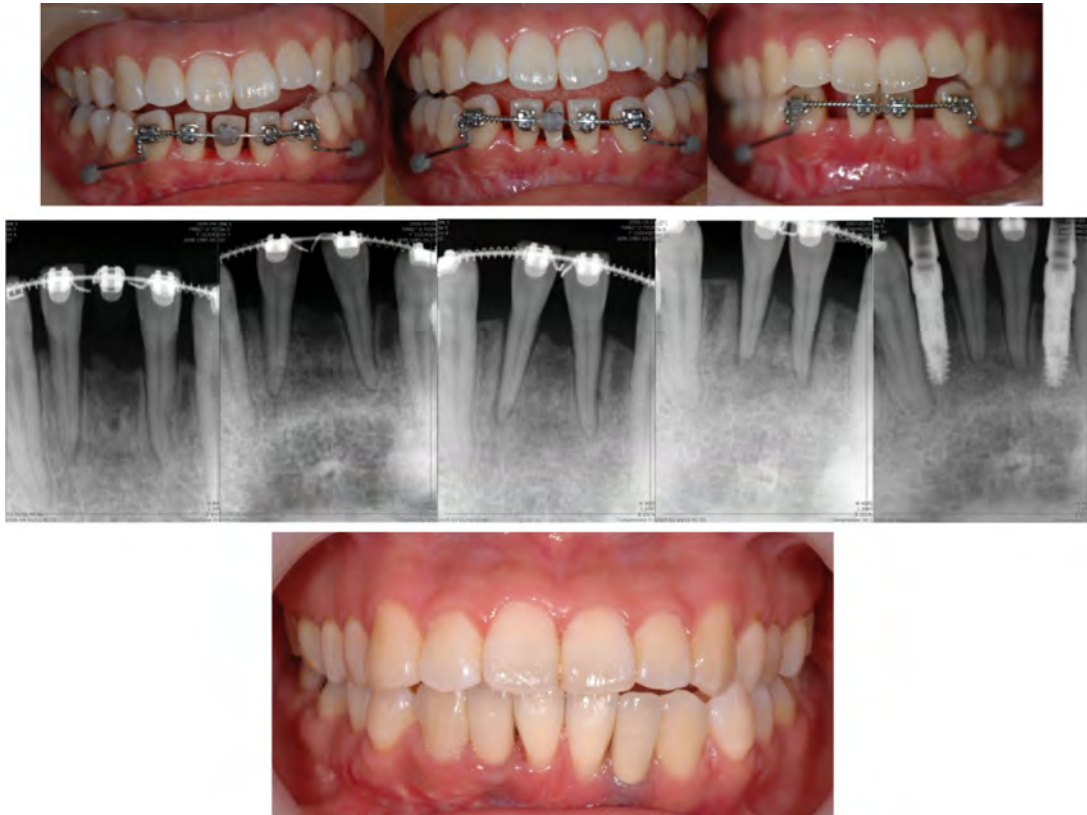The traditional protocol for implant rehabilitation requires a healing period of 12 month post-extraction and 3–6 months of undisturbed

healing following implant placement. However, the reduced treatment time and increased patient acceptance rendered the immediate loading approach more popular in implant prosthodontics.<sup>32</sup> This approach was originally applied in the anterior mandible and showed high success rates.<sup>33,34</sup> Then, it was applied in the maxillary dentition as a single implant restoration, again with a high success rate.<sup>35,36</sup> A meta-analysis study showed similar failure rates for immediately loaded and conventionally-loaded implants.<sup>37</sup>

To better understand the biologic evidence and the mechanisms of how peri-implant tissues respond to loading conditions, several studies have been conducted including animal studies



**Figure 10.** Case 3: bone grafting from the mandibular symphysis to augment the medial area of the alveolar bone.



**Figure 11.** Case 3: after 7 months of the 2 lateral incisors mesial movement, an implant was placed on each side between the lateral incisor and the canine.

and clinical trials. Bone–implant contact, bone area around implant apices, implant stability, and marginal bone loss were not significantly different between implants loaded immediately and those with delayed loading in dogs and monkeys.<sup>38–40</sup> Clinically, there were no apparent differences between soft and hard tissue responses to immediately and early loaded implants.<sup>41</sup>

Nevertheless, for immediately loaded single anterior implants, few studies reported a success rate less than 95% and the risk factors were not investigated.<sup>42,43</sup> In general, the reduced success rates were due to the bending loads of nonaxial forces on the implants. This increased the stress at the bone–implant interface, elevating the bone strain. Therefore, the probability of micromotion and fatigue failure of supporting bone was increased.<sup>44,45</sup>

Hurzeler et al.<sup>46</sup> reported no significant effect from orthodontic forces on changes in the peri-implant tissues in Monkeys. Turley et al.<sup>47</sup> showed that titanium implants remained stable

under orthodontic and orthopedic forces. Majzoub et al.<sup>48</sup> reported no adverse effect on the stability of the dental implant due to early loading of implants by orthodontic distalization forces. Palagi et al.<sup>49</sup> compared the effect of delayed versus immediate orthodontic loading on dental implants for 6 months and concluded that a reduction of the healing period prior to force application had no adverse effect on the success of osseointegrated implants. A recent study showed that immediate loading had no inhibitory effect on osseointegration of implants but may stimulate bone mineralization.<sup>50</sup>

While many studies report no adverse effects from early loading of implants, Cattaneo et al.<sup>51</sup> demonstrated through histologic and finite element analysis that the alveolar bone mechanical adaptation is complex and case-specific around implants subjected to orthodontic loading. In addition, a recent systematic review concluded that there were no reports in the literature of an adequate evaluation of the negative effects caused by excessive orthodontic

loading on implants.<sup>52</sup> Therefore, further studies might be recommended to assess the effect of immediate orthodontic loading on the osseointegration, stability, success, and survival rates of the dental implants.

Case 2 in this report shows a C-implant supporting a crown of a maxillary right lateral incisor as a temporary restoration in an adolescent patient. When orthodontic forces were applied, no adverse effects on the stability of the prosthesis were reported. The placement of the implant may reduce the marginal bone loss,<sup>53,54</sup> and thus preserve the alveolar bone height. However, with an increase in the height of the alveolar bone in growing patients, the implant can act as an ankylosed tooth and sustain an infraocclusion that results in a reduction of bone height.<sup>55,56</sup> Therefore, it is recommended to replace the implant or at least its crown after the completion of growth. In addition, if the tooth next to the infraocclusion starts tilting, it would be advisable to remove the temporary implant.<sup>57</sup>

## Conclusion

- Placement of implants in the anterior area in growing patients may become more frequent due to the high esthetic demands of today's society. However, if the implant seems to be in an infraocclusion position at the follow-up, it might be necessary to remove the implant and replace it later on, but in reality, it would be difficult to perform this procedure. The placement of temporary miniscrews instead of a dental implant to support a temporary crown offers a feasible treatment option for such patients because removal of the miniscrews is easier and results in a less bone damage.
- The application of orthodontic forces to dental implants as an anchorage has no negative effect on the osseointegration of the implant. However, the long-term effect on immediately loaded implants is still controversial.

## References

1. Tsakos G, Steele JG, Marcenes W, et al. Clinical correlates of oral health-related quality of life: evidence from a national sample of British older people. *Eur J Oral Sci.* 2006;114:391–395.
2. Pallegedara C, Ekanayake L. Effect of tooth loss and denture status on oral health-related quality of life of older individuals from Sri Lanka. *Community Dent Health.* 2008;25:196–200.
3. Tsakos G, Marcenes W, Sheiham A. The relationship between clinical dental status and oral impacts in an elderly population. *Oral Health Prev Dent.* 2004;2: 211–220.
4. Walter MH, Woronuk JI, Tan HK, et al. Oral health related quality of life and its association with sociodemographic and clinical findings in 3 northern outreach clinics. *J Can Dent Assoc.* 2007;73:153.
5. Kokich VO Jr., Kinzer GA. Managing congenitally missing lateral incisors. Part I: canine substitution. *J Esthet Restor Dent.* 2005;17:5–10.
6. Chaushu G, Chaushu S. The use of orthodontic treatment and immediate implant loading to restore the traumatic loss of a maxillary central incisor. *Int J Adult Orthodon Orthognath Surg.* 2001;16:47–53.
7. Louw JD, Smith BJ, McDonald F, et al. The management of developmentally absent maxillary lateral incisors—a survey of orthodontists in the UK. *Br Dent J.* 2007;203:E25 [discussion 654-655].
8. Andrade DC, Loureiro CA, Araujo VE, et al. Treatment for agenesis of maxillary lateral incisors: a systematic review. *Orthod Craniofac Res.* 2013;16:129–136.
9. Moraschini V, Velloso G, Luz D, et al. Implant survival rates, marginal bone level changes, and complications in full-mouth rehabilitation with flapless computer-guided surgery: a systematic review and meta-analysis. *Int J Oral Maxillofac Surg.* 2015;44:892–901.
10. Forsberg CM, Tedestam G. Traumatic injuries to teeth in Swedish children living in an urban area. *Swed Dent J.* 1990;14:115–122.
11. Garcia-Godoy F, Morban-Laucer F, Corominas LR, et al. Traumatic dental injuries in preschoolchildren from Santo Domingo. *Community Dent Oral Epidemiol.* 1983;11:127–130.
12. Soriano EP, Caldas Ade F Jr., Dimiz De Carvalho MV, et al. Prevalence and risk factors related to traumatic dental injuries in Brazilian schoolchildren. *Dent Traumatol.* 2007;23:232–240.
13. Oliveira LB, Marcenes W, Ardenghi TM, et al. Traumatic dental injuries and associated factors among Brazilian preschool children. *Dent Traumatol.* 2007;23:76–81.
14. Vahid-Dastjerdi E, Borzabadi-Farahani A, Mahdian M, et al. Non-syndromic hypodontia in an Iranian orthodontic population. *J Oral Sci.* 2010;52:455–461.
15. Topkara A, Sari Z. Prevalence and distribution of hypodontia in a Turkish orthodontic patient population: results from a large academic cohort. *Eur J Paediatr Dent.* 2011;12:123–127.
16. Matalova E, Fleischmannova J, Sharpe PT, et al. Tooth agenesis: from molecular genetics to molecular dentistry. *J Dent Res.* 2008;87:617–623.
17. Diagne F, Diop-Ba K, Yam AA, et al. Prevalence of dental agenesis: a radiologic and clinical study in Dakar. *Orthod Fr.* 2001;72:313–315.
18. Gabris K, Tarjan I, Csiki P, et al. Prevalence of congenital hypodontia in the permanent dentition and its treatment. *Fogorv Sz.* 2001;94:137–140.

19. Oziegbe EO, Esan TA, Adesina BA. Impact of oral conditions on the quality of life of secondary schoolchildren in Nigeria. *J Dent Child (Chic)*. 2012;79:159–164.
20. Buser D, Martin W, Belser UC. Optimizing esthetics for implant restorations in the anterior maxilla: anatomic and surgical considerations. *Int J Oral Maxillofac Implants*. 2004;19(suppl):43–61.
21. Tarnow DP, Cho SC, Wallace SS. The effect of inter-implant distance on the height of inter-implant bone crest. *J Periodontol*. 2000;71:546–549.
22. Tarnow DP, Magner AW, Fletcher P. The effect of the distance from the contact point to the crest of bone on the presence or absence of the interproximal dental papilla. *J Periodontol*. 1992;63:995–996.
23. Kois JC. Predictable single-tooth peri-implant esthetics: five diagnostic keys. *Compend Contin Educ Dent*. 2004;25:895–896[898, 900 passim; quiz 906-897].
24. Jeong DM, Choi B, Choo H, et al. Novel application of the 2-piece orthodontic C-implant for temporary crown restoration after orthodontic treatment. *Am J Orthod Dentofacial Orthop*. 2011;140:569–579.
25. Cope JB, McFadden D. Temporary replacement of missing maxillary lateral incisors with orthodontic miniscrew implants in growing patients: rationale, clinical technique, and long-term results. *J Orthod*. 2014;41(suppl 1):s62–s74.
26. Cawood JI, Howell RA. A classification of the edentulous jaws. *Int J Oral Maxillofac Surg*. 1988;17:232–236.
27. Ashman A. Postextraction ridge preservation using a synthetic alloplast. *Implant Dent*. 2000;9:168–176.
28. Suhonen JT, Meyer BJ. Polylactic acid (PLA) root replica in ridge maintenance after loss of a vertically fractured incisor. *Endod Dent Traumatol*. 1996;12:155–160.
29. Yilmaz S, Efeoglu E, Kilic AR. Alveolar ridge reconstruction and/or preservation using root form bioglass cones. *J Clin Periodontol*. 1998;25:832–839.
30. Wiesen M, Kitzis R. Preservation of the alveolar ridge at implant sites. *Periodontol Clin Investig*. 1998;20:17–20.
31. Lekholm U, Zarb GA. Patient selection and preparation. In: Branemark PI, Zarb GA, Albrektsson T, eds. *Tissue Integrated Prosthesis Osseointegration in Clinical Dentistry*. Chicago: Quintessence; 1985.
32. Strub JR, Jurdzik BA, Tuna T. Prognosis of immediately loaded implants and their restorations: a systematic literature review. *J Oral Rehabil*. 2012;39:704–717.
33. Schnitman PA, Wohrle PS, Rubenstein JE. Immediate fixed interim prostheses supported by two-stage threaded implants: methodology and results. *J Oral Implantol*. 1990;16:96–105.
34. Henry P, Rosenberg I. Single-stage surgery for rehabilitation of the edentulous mandible: preliminary results. *Pract Periodontics Aesthet Dent*. 1994;6:15–22[quiz 24].
35. Tarnow DP, Emtiaz S, Classi A. Immediate loading of threaded implants at stage I surgery in edentulous arches: ten consecutive case reports with 1- to 5-year data. *Int J Oral Maxillofac Implants*. 1997;12:319–324.
36. Ericsson I, Nilson H, Lindh T, et al. Immediate functional loading of Branemark single tooth implants. An 18 months' clinical pilot follow-up study. *Clin Oral Implants Res*. 2000;11:26–33.
37. Ioannidou E, Doufexi A. Does loading time affect implant survival? A meta-analysis of 1266 implants. *J Periodontol*. 2005;76:1252–1258.
38. Rismanchian M, Attar BM, Razavi SM, et al. Dental implants immediate loading versus the standard 2-staged protocol: an experimental study in dogs. *J Oral Implantol*. 2012;38:3–10.
39. Romanos G, Toh CG, Siar CH, et al. Peri-implant bone reactions to immediately loaded implants. An experimental study in monkeys. *J Periodontol*. 2001;72:506–511.
40. Romanos GE, Toh CG, Siar CH, et al. Bone-implant interface around titanium implants under different loading conditions: a histomorphometrical analysis in the Macaca fascicularis monkey. *J Periodontol*. 2003;74:1483–1490.
41. Rocci A, Martignoni M, Gottlow J. Immediate loading of Branemark System TiUnite and machined-surface implants in the posterior mandible: a randomized open-ended clinical trial. *Clin Implant Dent Relat Res*. 2003;5(suppl 1):57–63.
42. Degidi M, Piattelli A, Gehrke P, et al. Five-year outcome of 111 immediate nonfunctional single restorations. *J Oral Implantol*. 2006;32:277–285.
43. Malo P, Friberg B, Polizzi G, et al. Immediate and early function of Branemark System implants placed in the esthetic zone: a 1-year prospective clinical multicenter study. *Clin Implant Dent Relat Res*. 2003;5(suppl 1):37–46.
44. Quirynen M, Naert I, van Steenberghe D. Fixture design and overload influence marginal bone loss and fixture success in the Branemark system. *Clin Oral Implants Res*. 1992;3:104–111.
45. Mellal A, Wiskott HW, Botsis J, et al. Stimulating effect of implant loading on surrounding bone. Comparison of three numerical models and validation by in vivo data. *Clin Oral Implants Res*. 2004;15:239–248.
46. Hurzeler MB, Quinones CR, Kohal RJ, et al. Changes in peri-implant tissues subjected to orthodontic forces and ligature breakdown in monkeys. *J Periodontol*. 1998;69:396–404.
47. Turley PK, Kean C, Schur J, et al. Orthodontic force application to titanium endosseous implants. *Angle Orthod*. 1988;58:151–162.
48. Majzoub Z, Finotti M, Miotti F, et al. Bone response to orthodontic loading of endosseous implants in the rabbit calvaria: early continuous distalizing forces. *Eur J Orthod*. 1999;21:223–230.
49. Palagi LM, Sabrosa CE, Gava EC, et al. Long-term follow-up of dental single implants under immediate orthodontic load. *Angle Orthod*. 2010;80:807–811.
50. Nakagaki S, Iijima M, Handa K, et al. Micro-CT and histologic analyses of bone surrounding immediately loaded miniscrew implants: comparing compression and tension loading. *Dent Mater J*. 2014;33:196–202.
51. Cattaneo PM, Dalstra M, Melsen B. Analysis of stress and strain around orthodontically loaded implants: an animal study. *Int J Oral Maxillofac Implants*. 2007;22:213–225.
52. Rungruanganunt P, Taylor T, Eckert SE, et al. The effect of static load on dental implant survival: a systematic review. *Int J Oral Maxillofac Implants*. 2013;28:1218–1225.



53. Berberi AN, Noujeim ZN, Kanj WH, et al. Immediate placement and loading of maxillary single-tooth implants: a 3-year prospective study of marginal bone level. *J Contemp Dent Pract.* 2014;15:202–208.
54. Romanos GE, Aydin E, Locher K, et al. Immediate vs. delayed loading in the posterior mandible: a split-mouth study with up to 15 years of follow-up. *Clin Oral Implants Res* 2014[Epub ahead of print].
55. Burdi AR, Moyers RE, Development of the dentition and occlusion. In: Moyers RE, ed. *Handbook of Orthodontics.* 4th ed. Chicago: Year Book Medical Publishers; 1988: 93–94.
56. Dias C, Closs LQ, Fontanella V, et al. Vertical alveolar growth in subjects with infraoccluded mandibular deciduous molars. *Am J Orthod Dentofacial Orthop.* 2012;141: 81–86.
57. Malmgren B, Malmgren O. Rate of infraposition of reimplanted ankylosed incisors related to age and growth in children and adolescents. *Dent Traumatol.* 2002;18: 28–36.

---

# Surgical removal of asymptomatic impacted third molars: Considerations for orthodontists and oral surgeons

*Sung-Jin Kim, Chung-Ju Hwang, Jung-Hyun Park, Hyung-Jun Kim, and Hyung-Seog Yu*

**Surgical removal of impacted third molars is one of the most common surgeries in the oral and maxillofacial region. While there is a general consensus that symptomatic impacted third molars should be removed, management of asymptomatic impacted third molars remains a controversial issue. Although surgeons extract these teeth, orthodontists are often involved in the decision-making process for their management, because not only do the majority of orthodontic patients have asymptomatic impacted third molars but some of them also need an extraction for orthodontic reasons. Here we review the potential risks associated with the retention and extraction of asymptomatic impacted third molars and discuss the orthodontic indications and considerations for their extraction in terms of minimizing risks and maximizing patient benefits. (Semin Orthod 2016; 22:75–83.) © 2016 Elsevier Inc. All rights reserved.**

## Introduction

**T**hird molars generally erupt between 17 and 24 years of age, the last teeth to erupt in the oral cavity.<sup>1–3</sup> The eruption age varies depending on the racial and ethnic group.<sup>1</sup> Frequently, these teeth fail to erupt and remain impacted, primarily because of the lack of space distal to the second molars.<sup>4</sup> Among all human teeth, the third molars show the highest prevalence of impaction, with nearly two-thirds of all adults carrying at least one impacted third molar.<sup>2,5</sup>

Impacted third molars can be either symptomatic or asymptomatic. Surgical removal is the treatment of choice when impacted third molars are associated with pain or pathological changes such as pericoronitis and/or resorption of adjacent tooth roots<sup>6</sup>; however, the management of

asymptomatic impacted third molars remains controversial. Some dentists favor an early prophylactic removal of asymptomatic third molars to avoid future problems, which may be more difficult to manage in older patients,<sup>7</sup> but some risks such as nerve damage, alveolar osteitis, infection, pain, and swelling are inevitably associated with all surgical procedures.<sup>7</sup> A recent systematic review found no evidence to support or contradict the prophylactic removal of asymptomatic third molars in adults, concluding that decisions regarding these teeth should depend on clinical judgment and patient values.<sup>8</sup>

Asymptomatic impacted third molars often require extraction for orthodontic reasons. Several orthodontic indications have been proposed, such as the prevention of late mandibular incisor crowding,<sup>9</sup> molar distalization,<sup>10</sup> and preparation for orthognathic surgery.<sup>11</sup> To make the appropriate decisions with regard to the extraction of asymptomatic impacted third molars, both oral surgeons and orthodontists must know the associated risks and benefits and carefully evaluate all indications. Here we review the potential risks associated with the retention and extraction of asymptomatic impacted third molars and discuss the orthodontic indications and considerations for their extraction.

---

*Department of Orthodontics, School of Dentistry, Yonsei University, Seoul, South Korea; Department of Orthodontics, Institute of Craniofacial Deformity, School of Dentistry, Yonsei University, Seoul, South Korea; Department of Oral and Maxillofacial Surgery, School of Dentistry, Yonsei University, Seoul, South Korea.*

*Address correspondence to Hyung-Seog Yu, DDS, MS, PhD, Department of Orthodontics, Institute of Craniofacial Deformity, School of Dentistry, Yonsei University, 134 Shinchon-dong, Seodaemun-gu, Seoul 120-752, South Korea. E-mail: yumichael@yuhs.ac*

© 2016 Elsevier Inc. All rights reserved.

1073-8746/12/1801-\$30.00/0

<http://dx.doi.org/10.1053/j.sodo.2015.10.010>

## Potential risks of retained impacted third molars

### Pericoronitis

Pericoronitis refers to localized gingivitis or periodontitis around the crowns of unerupted or partially erupted third molars and is frequently associated with pain and swelling. It is the most common pathology related to third molars, followed by dental caries.<sup>12,13</sup> It has been reported that approximately 20–30% of partially erupted and 10% of completely unerupted third molars were associated with pericoronitis,<sup>12,13</sup> with risk factors including partial coverage of soft tissue and vertical or distal inclination of the tooth.<sup>12,21,22</sup> Prophylactic extraction is recommended in such cases (Table).<sup>7,12–20</sup>

### Development of cysts and tumors

There is a potential for cysts or tumors to develop in the dental follicular tissue surrounding impacted third molars.<sup>23</sup> The incidence of such cysts and tumors as detected by radiographic evaluation was reported to be 1.2–2.3%<sup>13,14,16,24</sup> and 0.5–0.8%,<sup>14,24</sup> respectively. Surprisingly, histological examination in some studies revealed that approximately 30–50% of pericoronal tissue around radiographically normal impacted third molars showed cystic changes.<sup>25–27</sup> The most frequent pathology was dentigerous cyst, followed by odontogenic keratocyst, although malignant tumors were also found.<sup>25</sup> Because these pathologies severely impair the patient's quality of life, they are considered a major reason for the prophylactic removal of impacted third molars.

### Resorption of adjacent second molar roots

Impacted third molars may cause external root resorption in adjacent second molars, although the underlying etiology is not completely understood. The incidence of this pathology reportedly varies from 0.3% to 7.5%,<sup>14,16,28</sup> primarily because of limited visibility on two-dimensional radiographs. However, a recent study reported that the proportion of patients diagnosed with external root resorption was considerably higher when they were examined with cone-beam computed tomography (CBCT; 23%) rather than with panoramic radiographs (5%), although CBCT cannot precisely distinguish root caries from root resorption.<sup>15</sup> In contrast to pericoronitis, resorption of adjacent second molar roots occurs more frequently in association with mesially or horizontally impacted mandibular third molars.<sup>15</sup>

### Mandibular angle fracture

Impacted mandibular third molars reportedly increase the incidence of mandibular angle fracture.<sup>29–32</sup> Reitzik et al.<sup>33</sup> showed that the force required for mandibular angle fracture by impacted third molars in monkeys is approximately 60% of that required for angle fracture by erupted third molars.<sup>33</sup> However, there is evidence that the incidence of condylar fracture was higher in the absence of impacted third molars, probably because of the transmission of greater forces to the condylar region,<sup>34,35</sup> and that these fractures are generally more difficult to manage than angle fractures.<sup>36</sup> Therefore, the prophylactic removal of third molars cannot be justified in terms of decreasing the risk of mandibular angle fracture.

**Table.** Risks Associated With Retention and Removal of Impacted Third Molars<sup>7,12–20</sup>

Retention	Removal
Pericoronitis (10–30%)	Postoperative discomforts (~50%): pain, swelling, trismus, and generalized malaise
Dental caries on themselves (11.5–13.6%) or adjacent second molars (2.0–7.9%)	Periodontal defect at the distal aspect of second molar (48% of healthy periodontium)
External root resorption of adjacent second molars (0.3–23%)	Minor postoperative complications: alveolar osteitis (2.7–26%), infection (0.72–4.2%), and secondary hemorrhage (0.09–5.8%)
Development of cysts (1.2–2.3%) and tumors (0.5–0.8%)	Temporary or permanent nerve injury: inferior alveolar nerve (1.3–8.4%) and, lingual nerve (0.5–5.7%)
Increased risk of bad split in BSSO and mandibular angle fracture	Injury to adjacent tooth (0.18%)
	Maxillary tuberosity or mandibular fracture (0.09–0.6%)

BSSO, bilateral sagittal split osteotomy.

## Potential risks with impacted third molar extraction

### *Periodontal defects distal to second molars*

A periodontal defect that develops distal to the second molars following the removal of impacted third molars is a challenging risk for clinicians (Table). Although a systematic review reported that the changes in attachment levels and probing depths on the distal aspect of second molars were clinically insignificant, it also revealed that 48% patients with a healthy periodontium before surgery showed worse periodontal measurements after surgery.<sup>37</sup> These periodontal defects are attributed to several factors including bone remodeling after tooth extraction, bone removal and instrumentation required during surgery, and difficulty in oral hygiene maintenance at the distal aspect of second molars.<sup>38</sup> Other studies reported that age above 25 years, pre-existing periodontal pockets, and mesial or horizontal impaction of third molars are risk factors for postoperative periodontal defects.<sup>39–41</sup> Orthodontic extraction of third molars may be indicated in patients with these risk factors; this will be discussed in a later section.

### *Nerve injury*

The inferior alveolar and lingual nerves may be injured during the surgical removal of mandibular third molars, a condition that results in sensory impairment in the ipsilateral lower lip, chin, and tongue. Patients may experience discomfort when talking, drinking, or eating in the presence of mild injury, whereas severe injury frequently leads to extreme discomfort and pain. The incidence of sensory impairment after third molar surgery was reported to be 1.3–8.4% for the inferior alveolar nerve and 0.5–5.7% for the lingual nerve.<sup>18,19</sup> This sensory impairment is mostly transient and disappears within the first 6 months, while the incidence of permanent damage is reportedly less than 1%.<sup>42</sup> In patients with persistent sensory impairment, however, nonsurgical treatments, including acupuncture and low-level laser therapy, or surgical interventions including external neurolysis, direct suturing, autogenous vein grafting, and application of a Gore-tex tube as a conduit may improve sensation, although complete recovery is rare.<sup>43</sup>

### *Alveolar osteitis (dry socket)*

Alveolar osteitis is defined as postoperative pain in and around the extraction site, which increases in severity at any time between 1 and 3 days after extraction and is accompanied by a partially or totally disintegrated blood clot within the alveolar socket, with or without halitosis.<sup>44</sup> The incidence is reportedly 25–30% after impacted mandibular third molar extraction, being 10 times higher than that at other locations.<sup>44</sup>

The etiology of and risk factors for alveolar osteitis are poorly understood. The risks suggested in the literature include surgical trauma<sup>45</sup> and bacterial infection,<sup>46</sup> whereas the risk factors are higher for females,<sup>47</sup> patients who use oral contraceptives,<sup>48</sup> smokers,<sup>49</sup> and the elderly.<sup>50</sup> Alveolar osteitis causes extreme pain; therefore, its management should focus on pain control until the commencement of normal healing.<sup>51</sup>

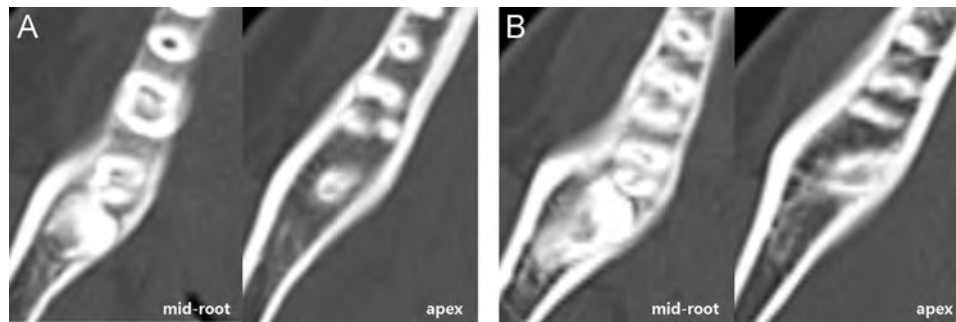
## Orthodontic indications for impacted third molar extraction

### *Molar distalization*

Molar distalization is employed to correct a Class II or Class III molar relationship and to gain space for the relief of crowding without functional premolar extraction.<sup>52,53</sup> The clinical significance of molar distalization has increased since the introduction of temporary anchorage devices (TADs) that allow predictable molar distalization with minimal patient compliance.<sup>54,55</sup> However, molar distalization is not always an efficient treatment modality; therefore, the decision to deploy this procedure should be carefully made. With regard to relief of anterior crowding, the amount of space gained after first or second premolar extraction is approximately 5.5 and 3.5 mm, respectively, because the loss of posterior anchorage without TADs is reported to be approximately 20%<sup>56</sup> and 50%<sup>57</sup> of the extraction space, respectively. Considering that the conventional amount of molar distalization is approximately 3 mm,<sup>54,55,58</sup> premolar extraction may be the treatment of choice when more than 3 mm of molar distalization is necessary.

Molar distalization requires not only adequate anchorage but also available space distal to second molars. Therefore, impacted third molars are routinely removed before molar distalization





**Figure 1.** In patient A, extraction of the mandibular left third molar will provide space for second molar distalization. However, in patient B, it is limited by root contact with the lingual cortex of the mandibular body.

in adults.<sup>10</sup> In the mandible, however, even impacted third molar extraction cannot guarantee enough space for molar distalization, because the available space distal to second molars is determined by the lingual cortex of the mandibular body and is not affected by third molar extraction.<sup>59</sup> In addition, 35.3% second molar roots were reported to be in contact with the lingual cortex in patients with skeletal Class I malocclusion and no history of orthodontic treatment.<sup>59</sup> Therefore, regardless of the presence of mandibular third molars, examination of the available space distal to second molars using computed tomography is recommended before planning molar distalization (Fig. 1).

#### ***Preparation for orthognathic surgery***

The effect of impacted mandibular third molars on unfavorable fracture or bad split during sagittal split osteotomy (SSO) has been a controversial issue. Some authors reported a slightly increased risk of a bad split in the presence of impacted third molars,<sup>11,60–62</sup> whereas others found no significant correlations.<sup>63–65</sup> Because no data from randomized clinical trials are currently available, the timing for third molar extraction depends on the surgeon's preference and orthodontic necessity. If third molar extraction is planned before SSO, it should be performed at least 6 months before SSO to allow for complete bone maturation.<sup>66</sup>

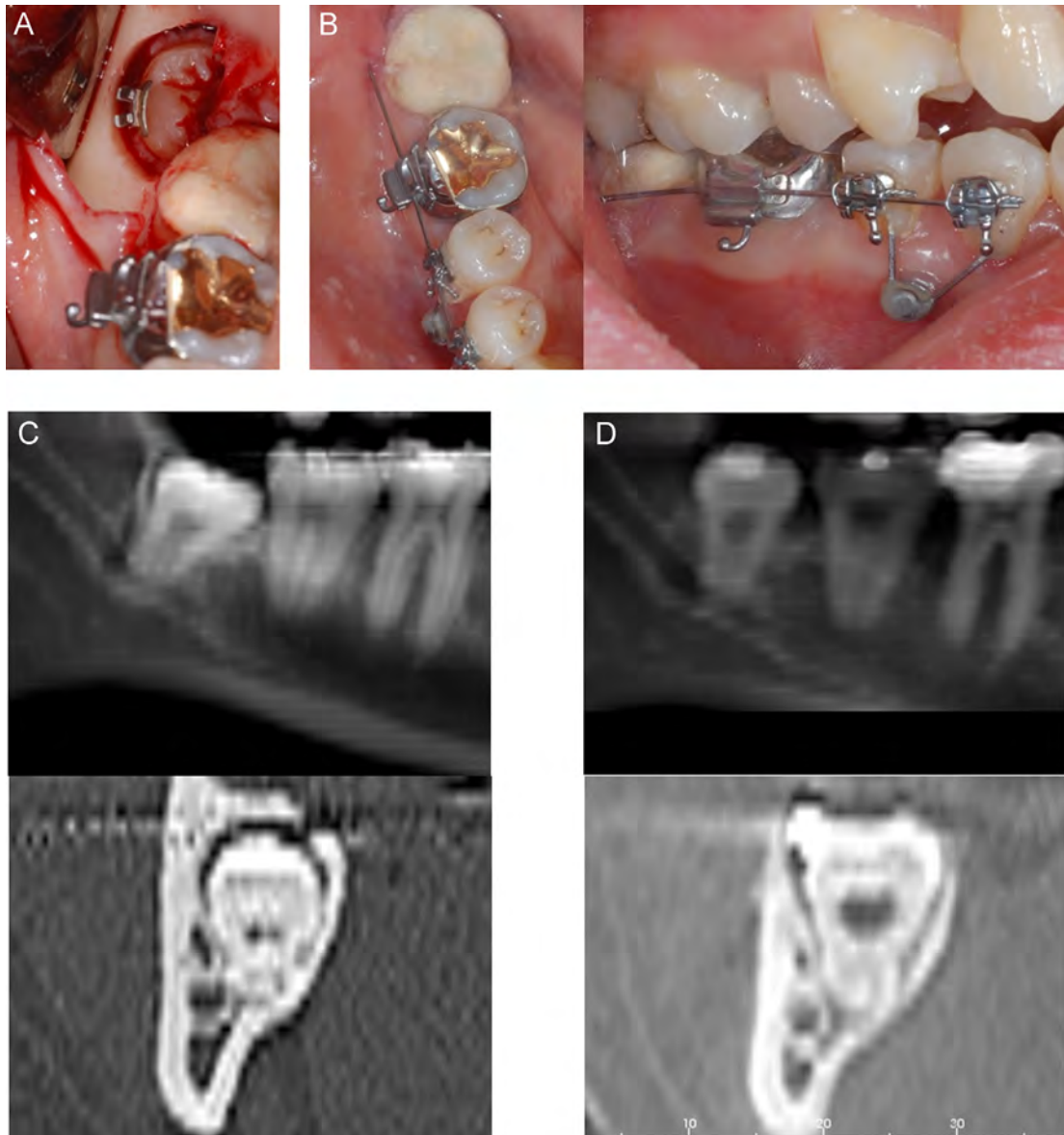
In contrast to SSO, the timing of extraction is not critical in patients requiring vertical ramus osteotomy because the osteotomy line is distant from the dentition. Maxillary impacted third molars may also disturb osteotomy, although they can be easily removed after

maxillary down-fracture without the risk of complications.

#### ***Prevention of late mandibular incisor crowding***

Late mandibular incisor crowding is a common phenomenon that generally occurs in the early 20s. Various etiological factors have been proposed including late mandibular growth,<sup>67</sup> mesial drift of posterior teeth,<sup>68</sup> an anterior occlusal force component,<sup>69</sup> and pressure from third molars.<sup>9</sup> Among these factors, much attention has been paid to pressure from third molars, probably because direct intervention is possible. However, there have been conflicting results, where some authors found third molar removal beneficial in terms of the prevention of late mandibular incisor crowding,<sup>9,70</sup> whereas others found no direct benefits.<sup>71,72</sup>

Considering the lack of knowledge about precise etiological factors, the best approach to match the extraction and retention groups and eliminate potential sources of bias is randomization. To date, only one randomized controlled trial by Harradine et al.<sup>73</sup> evaluated the influence of third molars on late mandibular incisor crowding. After an average 66 months of follow-up, there were no significant differences in Little's index of irregularity and intercanine width between the two groups, although a small but statistically significant difference (approximately 1 mm) was found in arch length. These findings imply that the presence of third molars has little influence on late mandibular incisor crowding, although impacted third molars appear to contribute to the mesial migration of posterior teeth. Therefore, considering the cost and morbidity, the surgical removal of impacted



**Figure 2.** (A) Surgical exposure of an impacted mandibular right third molar. (B) Indirect application of a mini-screw to reinforce the posterior anchorage for orthodontic extrusion of the impacted mandibular right third molar. Radiographs obtained before (C) and after (D) orthodontic extrusion that moved the roots away from the inferior alveolar nerve (Courtesy of Dr. Wonse Park).

third molars to prevent late mandibular incisor crowding cannot be justified.

### Special considerations for orthodontists

#### *Timing of extraction*

In general, increased age has been associated with increased morbidity after the surgical removal of third molars.<sup>74–76</sup> A recent review

summarized relevant studies and concluded that age 25 is a critical time after which complications such as a higher infection rate, more periodontal complications at the distal aspect of second molars, and delayed or incomplete recovery from nerve injury increase rapidly.<sup>77</sup> The higher complication rate is partially attributed to increased difficulty of third molar removal in older patients because of continuing root development, a thinner periodontal ligament,

and an increased incidence of ankylosis and hypercementosis. On the other hand, early removal of third molars by germectomy at 9–16 years of age does not decrease the complication rate compared to that at 17–24 years of age.<sup>78</sup> Therefore, the prophylactic removal of third molars can be postponed until 17–24 years of age when the patient's compliance increases.

In orthodontic patients, however, there are special considerations for the timing of extraction. First, when molar distalization is planned, third molars should be removed immediately before molar distalization in an attempt to decrease the treatment duration.<sup>55</sup> Decreased treatment time can be expected because of the regional acceleratory phenomenon<sup>79</sup> and a decrease in the amount of alveolar bone requiring removal.<sup>80</sup> Second, in patients scheduled for SSO, third molars may be removed 6–9 months before surgery to avoid unfavorable fractures.<sup>66</sup> Maxillary impacted third molars can be easily removed after LeFort I downfracture.

### ***Orthodontic extraction of impacted third molars***

Orthodontic extraction was introduced to minimize the risk of nerve damage and facilitate the extraction of impacted mandibular third molars in close anatomical proximity to the mandibular canal.<sup>81</sup> It involves the orthodontic extrusion of impacted third molars to pull their roots away from the mandibular canal. In addition to the benefit of safer and easier subsequent extraction, it provides periodontal advantages of a decreased probing pocket depth and increased clinical attachment levels at the distal aspect of adjacent second molars because new bone formation follows orthodontic extrusion, preserving more bone after extraction.<sup>38</sup> However, it inevitably increases the treatment duration and cost for the patient; therefore, it is indicated in selected patients with roots in close proximity to the mandibular nerve as confirmed by CBCT<sup>82</sup> and/or patients with a high risk of developing postoperative periodontal defects.

There are several considerations for predictable outcomes with this technique. First, a stable anchorage unit should be established before the surgical exposure of impacted third molars. Some side effects accompany third molar extrusion using conventional anchorage such as

intrusion and distal tipping of the mandibular posterior anchorage or extrusion of maxillary posterior teeth when intermaxillary elastics are used. Direct or indirect application of TADs can provide stable anchorage to prevent these side effects (Fig. 2). Second, over-extrusion of third molars is recommended to save more bone at the distal aspect of the second molars. When maxillary third molars prohibit over-eruption of mandibular third molars, they should be extracted first.<sup>83</sup> Third, a retention period of a few months is required to allow for new bone formation after extrusion.

### **Conclusions**

Most of the orthodontic patients have asymptomatic impacted third molars; however, their surgical removal remains controversial in terms of risks vs. benefits. Even though a surgeon is the one extracting these teeth, orthodontists are in an ideal position to monitor them and should participate in the decision-making process for their management. Interaction between orthodontists and surgeons with regard to extraction timing and minimization of post-operative complications by orthodontic intervention may decrease risks and maximize patient benefits.

### **References**

1. Brkic H, Vodanovic M, Dumancic J, et al. The chronology of third molar eruption in the Croatian population. *Coll Antropol.* 2011;35:353–357.
2. Hugoson A, Kugelberg CF. The prevalence of third molars in a Swedish population. An epidemiological study. *Community Dent Health.* 1988;5:121–138.
3. Odusanya SA, Abayomi IO. Third molar eruption among rural Nigerians. *Oral Surg Oral Med Oral Pathol.* 1991; 71:151–154.
4. Forsberg CM. Tooth size, spacing, and crowding in relation to eruption or impaction of third molars. *Am J Orthod Dentofacial Orthop.* 1988;94:57–62.
5. Quek SL, Tay CK, Tay KH, et al. Pattern of third molar impaction in a Singapore Chinese population: a retrospective radiographic survey. *Int J Oral Maxillofac Surg.* 2003;32:548–552.
6. NIH consensus development conference for removal of third molars. *J Oral Surg.* 1980;38:235–236.
7. Kandasamy S, Rinchuse DJ, Rinchuse DJ. The wisdom behind third molar extractions. *Aust Dent J.* 2009; 54:284–292.
8. Mettes TD, Ghaemina H, Nienhuijs ME, et al. Surgical removal versus retention for the management of

- asymptomatic impacted wisdom teeth. *Cochrane Database Syst Rev*. 2012;6:CD003879.
9. Lindqvist B, Thilander B. Extraction of third molars in cases of anticipated crowding in the lower jaw. *Am J Orthod*. 1982;81:130–139.
  10. Choi YJ, Lee JS, Cha JY, et al. Total distalization of the maxillary arch in a patient with skeletal Class II malocclusion. *Am J Orthod Dentofacial Orthop*. 2011;139:823–833.
  11. Verweij JP, Mensink G, Fiocco M, et al. Presence of mandibular third molars during bilateral sagittal split osteotomy increases the possibility of bad split but not the risk of other post-operative complications. *J Craniomaxillofac Surg*. 2014;42:e359–e363.
  12. Punwutikorn J, Waikakul A, Ochareon P. Symptoms of unerupted mandibular third molars. *Oral Surg Oral Med Oral Pathol Oral Radiol Endod*. 1999;87:305–310.
  13. Dogan N, Orhan K, Gunaydin Y, et al. Unerupted mandibular third molars: symptoms, associated pathologies, and indications for removal in a Turkish population. *Quintessence Int*. 2007;38:e497–e505.
  14. Al-Khateeb TH, Bataineh AB. Pathology associated with impacted mandibular third molars in a group of Jordanians. *J Oral Maxillofac Surg*. 2006;64:1598–1602.
  15. Oenning AC, Neves FS, Alencar PN, et al. External root resorption of the second molar associated with third molar impaction: comparison of panoramic radiography and cone beam computed tomography. *J Oral Maxillofac Surg*. 2014;72:1444–1455.
  16. Stanley HR, Alattar M, Collett WK, et al. Pathological sequelae of neglected impacted third molars. *J Oral Pathol*. 1988;17:113–117.
  17. Guven O, Keskin A, Akal UK. The incidence of cysts and tumors around impacted third molars. *Int J Oral Maxillofac Surg*. 2000;29:131–135.
  18. Lopes V, Mumenya R, Feinmann C, et al. Third molar surgery: an audit of the indications for surgery, post-operative complaints and patient satisfaction. *Br J Oral Maxillofac Surg*. 1995;33:33–35.
  19. Hu ML, Perrott DH, Greene MG, et al. Development of an oral and maxillofacial surgery outcomes system for anesthesia and third molar removal: results of alpha and beta testing. *J Oral Maxillofac Surg*. 2001;59:554–560.
  20. Daly B, Sharif MO, Newton T, et al. Local interventions for the management of alveolar osteitis (dry socket). *Cochrane Database Syst Rev*. 2012;12:CD006968.
  21. Leone SA, Edenfield MJ, Cohen ME. Correlation of acute pericoronitis and the position of the mandibular third molar. *Oral Surg Oral Med Oral Pathol*. 1986;62:245–250.
  22. Hazza'a AM, Bataineh AB, Odat AA. Angulation of mandibular third molars as a predictive factor for pericoronitis. *J Contemp Dent Pract*. 2009;10:51–58.
  23. Curran AE, Damm DD, Drummond JF. Pathologically significant pericoronitis lesions in adults: histopathologic evaluation. *J Oral Maxillofac Surg*. 2002;60:613–617.
  24. Güven O, Keskin A, Akal ÜK. The incidence of cysts and tumors around impacted third molars. *Int J Oral Maxillofac Surg*. 2000;29:131–135.
  25. Rakprasitkul S. Pathologic changes in the pericoronitis tissues of unerupted third molars. *Quintessence Int*. 2001;32:633–638.
  26. Glosser JW, Campbell JH. Pathologic change in soft tissues associated with radiographically 'normal' third molar impactions. *Br J Oral Maxillofac Surg*. 1999;37:259–260.
  27. Baykul T, Sağlam AA, Aydin U, et al. Incidence of cystic changes in radiographically normal impacted lower third molar follicles. *Oral Surg Oral Med Oral Pathol Oral Radiol Endod*. 2005;99:542–545.
  28. Nitzan D, Keren T, Marmary Y. Does an impacted tooth cause root resorption of the adjacent one. *Oral Surg Oral Med Oral Pathol*. 1981;51:221–224.
  29. Safdar N, Meechan J. Relationship between fractures of the mandibular angle and the presence and state of eruption of the lower third molar. *Oral Surg Oral Med Oral Pathol Oral Radiol Endod*. 1995;79:680–684.
  30. Tevepaugh DB, Dodson TB. Are mandibular third molars a risk factor for angle fractures?: a retrospective cohort study. *J Oral Maxillofac Surg*. 1995;53:646–649.
  31. Yamada T, Sawaki Y, Tohnoi I, et al. A study of sports-related mandibular angle fracture: relation to the position of the third molars. *Scand J Med Sci Sports*. 1998;8:116–119.
  32. Halmos DR, Ellis Iii E, Dodson TB. Mandibular third molars and angle fractures. *J Oral Maxillofac Surg*. 2004;62:1076–1081.
  33. Reitzik M, Lownie JF, Cleaton-Jones P, et al. Experimental fractures of monkey mandibles. *Int J Oral Maxillofac Surg*. 1978;7:100–103.
  34. Iida S, Nomura K, Okura M, et al. Influence of the incompletely erupted lower third molar on mandibular angle and condylar fractures. *J Trauma*. 2004;57:613–617.
  35. Zhu S-J, Choi B-H, Kim H-J, et al. Relationship between the presence of unerupted mandibular third molars and fractures of the mandibular condyle. *Int J Oral Maxillofac Surg*. 2005;34:382–385.
  36. Adeyemo WL. Do pathologies associated with impacted lower third molars justify prophylactic removal? A critical review of the literature. *Oral Surg Oral Med Oral Pathol Oral Radiol Endod*. 2006;102:448–452.
  37. Richardson DT, Dodson TB. Risk of periodontal defects after third molar surgery: an exercise in evidence-based clinical decision-making. *Oral Surg Oral Med Oral Pathol Oral Radiol Endod*. 2005;100:133–137.
  38. Montevocchi M, Incerti Parenti S, Checchi V, et al. Periodontal healing after 'orthodontic extraction' of mandibular third molars: a retrospective cohort study. *Int J Oral Maxillofac Surg*. 2014;43:1137–1141.
  39. Kugelberg CF. Periodontal healing two and four years after impacted lower third molar surgery: a comparative retrospective study. *Int J Oral Maxillofac Surg*. 1990;19:341–345.
  40. Kugelberg CF, Ahlström U, Ericson S, et al. The influence of anatomical, pathophysiological and other factors on periodontal healing after impacted lower third molar surgery: a multiple regression analysis. *J Clin Periodontol*. 1991;18:37–43.
  41. Kan KW, Liu JK, Lo EC, et al. Residual periodontal defects distal to the mandibular second molar 6-36 months after impacted third molar extraction. *J Clin Periodontol*. 2002;29:1004–1011.
  42. Güllicher D, Gerlach K. Sensory impairment of the lingual and inferior alveolar nerves following removal of



- impacted mandibular third molars. *Int J Oral Maxillofac Surg.* 2001;30:306–312.
43. Leung YY, Fung PP, Cheung LK. Treatment modalities of neurosensory deficit after lower third molar surgery: a systematic review. *J Oral Maxillofac Surg.* 2012;70:768–778.
  44. Blum IR. Contemporary views on dry socket (alveolar osteitis): a clinical appraisal of standardization, aetiopathogenesis and management: a critical review. *Int J Oral Maxillofac Surg.* 2002;31:309–317.
  45. Nusair YM, Younis MH. Prevalence, clinical picture, and risk factors of dry socket in a Jordanian dental teaching center. *J Contemp Dent Pract.* 2007;8:53–63.
  46. Penarrocha M, Sanchis JM, Saez U, et al. Oral hygiene and postoperative pain after mandibular third molar surgery. *Oral Surg Oral Med Oral Pathol Oral Radiol Endod.* 2001;92:260–264.
  47. MacGregor AJ. Aetiology of dry socket: a clinical investigation. *Br J Oral Surg.* 1968;6:49–58.
  48. Sweet JB, Butler DP. Predisposing and operative factors: effect on the incidence of localized osteitis in mandibular third-molar surgery. *Oral Surg Oral Med Oral Pathol.* 1978;46:206–215.
  49. Sweet JB, Butler DP. The relationship of smoking to localized osteitis. *J Oral Surg.* 1979;37:732–735.
  50. Alexander RE. Dental extraction wound management: a case against medicating postextraction sockets. *J Oral Maxillofac Surg.* 2000;58:538–551.
  51. Kolokythas A, Olech E, Miloro M. Alveolar osteitis: a comprehensive review of concepts and controversies. *Int J Dent.* 2010;2010.
  52. Sfondrini MF, Cacciafesta V, Sfondrini G. Upper molar distalization: a critical analysis. *Orthod Craniofac Res.* 2002;5:114–126.
  53. Rey D, Angel D, Oberti G, et al. Treatment and posttreatment effects of mandibular cervical headgear followed by fixed appliances in Class III malocclusion. *Am J Orthod Dentofacial Orthop.* 2008;133:371–378[quiz 476 e371].
  54. Yamada K, Kuroda S, Deguchi T, et al. Distal movement of maxillary molars using miniscrew anchorage in the buccal interradicular region. *Angle Orthod.* 2009;79:78–84.
  55. Oh YH, Park HS, Kwon TG. Treatment effects of microimplant-aided sliding mechanics on distal retraction of posterior teeth. *Am J Orthod Dentofacial Orthop.* 2011;139:470–481.
  56. Cho MY, Choi JH, Lee SP, et al. Three-dimensional analysis of the tooth movement and arch dimension changes in Class I malocclusions treated with first premolar extractions: a guideline for virtual treatment planning. *Am J Orthod Dentofacial Orthop.* 2010;138:747–757.
  57. Chen K, Han X, Huang L, et al. Tooth movement after orthodontic treatment with 4 second premolar extractions. *Am J Orthod Dentofacial Orthop.* 2010;138:770–777.
  58. Park Y, Kim J, Lee J. Biomechanical considerations with temporary anchorage devices. In: Graber L, Vanarsdall RL Jr, Vig K, eds. *Orthodontics: Current Principles and Techniques.* 5th ed. Philadelphia: Mosby; 2012.
  59. Kim SJ, Choi TH, Baik HS, et al. Mandibular posterior anatomic limit for molar distalization. *Am J Orthod Dentofacial Orthop.* 2014;146:190–197.
  60. Mehra P, Castro V, Freitas RZ, et al. Complications of the mandibular sagittal split ramus osteotomy associated with the presence or absence of third molars. *J Oral Maxillofac Surg.* 2001;59:854–858[discussion 859].
  61. Reyneke JP, Tsakiris P, Becker P. Age as a factor in the complication rate after removal of unerupted/impacted third molars at the time of mandibular sagittal split osteotomy. *J Oral Maxillofac Surg.* 2002;60:654–659.
  62. Mensink G, Verweij JP, Frank MD, et al. Bad split during bilateral sagittal split osteotomy of the mandible with separators: a retrospective study of 427 patients. *Br J Oral Maxillofac Surg.* 2013;51:525–529.
  63. Kriwalsky MS, Maurer P, Veras RB, et al. Risk factors for a bad split during sagittal split osteotomy. *Br J Oral Maxillofac Surg.* 2008;46:177–179.
  64. Precious DS, Lung KE, Pynn BR, et al. Presence of impacted teeth as a determining factor of unfavorable splits in 1256 sagittal-split osteotomies. *Oral Surg Oral Med Oral Pathol Oral Radiol Endod.* 1998;85:362–365.
  65. Doucet JC, Morrison AD, Davis BR, et al. The presence of mandibular third molars during sagittal split osteotomies does not increase the risk of complications. *J Oral Maxillofac Surg.* 2012;70:1935–1943.
  66. Colelia G, Giudice A. The timing of third molar removal in patients undergoing a bilateral sagittal split osteotomy. *J Oral Maxillofac Surg.* 2003;61:975.
  67. Bjork A. Variations in the growth pattern of the human mandible: longitudinal radiographic study by the implant method. *J Dent Res.* 1963;42(1):400–411 [Pt 2].
  68. Yilmaz RS, Darling AI, Levers BG. Mesial drift of human teeth assessed from ankylosed deciduous molars. *Arch Oral Biol.* 1980;25:127–131.
  69. Southard TE, Behrents RG, Tolley EA. The anterior component of occlusal force. Part 2. Relationship with dental malalignment. *Am J Orthod Dentofacial Orthop.* 1990; 97:41–44.
  70. Kahl-Nieke B, Fischbach H, Schwarze CW. Post-retention crowding and incisor irregularity: a long-term follow-up evaluation of stability and relapse. *Br J Orthod.* 1995; 22:249–257.
  71. Shanley L. Influence of mandibular third molars on mandibular anterior teeth. *Am J Orthod.* 1962;48:786–787.
  72. Kaplan R. Mandibular third molars and post retention crowding. *Am J Orthod.* 1974;66:428–430.
  73. Harradine NW, Pearson MH, Toth B. The effect of extraction of third molars on late lower incisor crowding: a randomized controlled trial. *Br J Orthod.* 1998;25: 117–122.
  74. Bruce R, Frederickson G, Small G. Age of patients and morbidity associated with mandibular third molar surgery. *J Am Dent Assoc.* 1980;101:240–245.
  75. Osborn TP, Frederickson G Jr, Small IA, et al. A prospective study of complications related to mandibular third molar surgery. *J Oral Maxillofac Surg.* 1985;43: 767–769.
  76. Chuang S-K, Perrott DH, Susarla SM, et al. Age as a risk factor for third molar surgery complications. *J Oral Maxillofac Surg.* 2007;65:1685–1692.
  77. Pogrel MA. What is the effect of timing of removal on the incidence and severity of complications. *J Oral Maxillofac Surg.* 2012;70:S37–S40.

78. Chiapasco M, Crescentini M, Romanoni G. Gernectomy or delayed removal of mandibular impacted third molars: the relationship between age and incidence of complications. *J Oral Maxillofac Surg.* 1995;53:418–422.
79. Frost HM. The regional acceleratory phenomenon: a review. *Henry Ford Hosp Med J.* 1983;31:3–9.
80. Ahn HW, Ohe JY, Lee SH, et al. Timing of force application affects the rate of tooth movement into surgical alveolar defects with grafts in beagles. *Am J Orthod Dentofacial Orthop.* 2014;145:486–495.
81. Checchi L, Alessandri Bonetti G, Pelliccioni GA. Removing high-risk impacted mandibular third molars: a surgical-orthodontic approach. *J Am Dent Assoc.* 1996;127:1214–1217.
82. Xu GZ, Yang C, Fan XD, et al. Anatomic relationship between impacted third mandibular molar and the mandibular canal as the risk factor of inferior alveolar nerve injury. *Br J Oral Maxillofac Surg.* 2013;51:e215–e219.
83. Alessandri Bonetti G, Bendandi M, Laino L, et al. Orthodontic extraction: riskless extraction of impacted lower third molars close to the mandibular canal. *J Oral Maxillofac Surg.* 2007;65:2580–2586.

# Seminars in Orthodontics

---

## *Future Issues*

---

*Vol 22 No 1 (March 2016)*

### **INTERACTIONS BETWEEN ORTHODONTICS AND ORAL MAXILLOFACIAL SURGERY**

*Jae Hyun Park, DMD, MSD, MS, PhD, Guest Editor*

## *Recent Issues*

---

*Vol 21 No 4 (December 2015)*

### **ADVANCES IN CBCT DIAGNOSTICS WITH ORTHODONTIC TREATMENT: INTERPRETATION AND MANIPULATION**

*Onur Kadioglu, DDS, MS, Guest Editor*

*Vol 21 No 3 (September 2015)*

### **ACCELERATED ORTHODONTICS**

*Mani Alikhani, DDS, MS, PhD, Guest Editor*

*Vol 21 No 2 (June 2015)*

### **JUVENILE IDIOPATHIC ARTHRITIS AND TEMPOROMANDIBULAR JOINT INVOLVEMENT: AN INTERDISCIPLINARY APPROACH**

*Bjørn Øgaard, DDS, Dr Odont, Guest Editor*

*Vol 21 No 1 (March 2015)*

### **INTERDISCIPLINARY MANAGEMENT OF THE ORTHODONTIC PATIENT**

*Pratik Kumar Sharma, BDS(Hons), MFDS, MSc, MOrth, FDSOrth, Guest Editor*

*Vol 20 No 4 (December 2014)*

### **ALL ROADS LEAD TO ROME: NEW DIRECTIONS FOR CLASS II**

*S. Jay Bowman, DMD, MSD, FACD, FICD, Guest Editor*

*Vol 20 No 3 (September 2014)*

### **PERIODONTAL-ORTHODONTIC INTERACTIONS**

*Ramzi V. Abou-Arraj, DDS, MS, Guest Editor*

*Vol 20 No 2 (June 2014)*

### **AGE-APPROPRIATE ORTHODONTIC TREATMENT, PART II**

*Gerry Samson, DDS, and Elliott M. Moskowitz, DDS, MSd, Guest Editors*

*Vol 20 No 1 (March 2014)*

### **AGE-APPROPRIATE ORTHODONTIC TREATMENT, PART I**

*Elliott M. Moskowitz, DDS, MSd, and Gerry Samson, DDS, Guest Editors*

*Vol 19 No 4 (December 2013)*

### **THE VERTICAL DIMENSION IN ORTHODONTICS**

*Nada M. Souccar, DDS, MS, Guest Editor*

*Vol 19 No 3 (September 2013)*

### **EVIDENCE-BASED ORTHODONTICS**

*Katherine Vig, BDS, MS, FDS, DOrth, and Greg Huang, DMD, MSD, MPH, Guest Editors*

*Vol 19 No 2 (June 2013)*

### **PROGRESSIVE CONDYLAR RESORPTION AND DENTOFACIAL DEFORMITIES**

*Chester S. Handelman, DMD, and Charles S. Greene, DDS, Guest Editors*

*Vol 19 No 1 (March 2013)*

### **INTERDISCIPLINARY TREATMENT OF ADOLESCENTS WITH MISSING ANTERIOR TEETH**

*Mark R. Yanosky, DMD, MS, Guest Editor*

*Vol 18 No 4 (December 2012)*

### **UPDATES ON THE BIOLOGICAL FOUNDATIONS OF ORTHODONTIC TOOTH MOVEMENT**

*Vinod Krishnan, BDS, MDS, M Orth RCS D, PhD, and Ze'ev Davidovitch, DMD, Cert Ortho, Guest Editors*

*Vol 18 No 3 (September 2012)*

### **AN OVERVIEW OF FACIAL ATTRACTIVENESS FOR ORTHODONTISTS**

*Margaret Collins, BDS, FDSRCPs, DOrth, MSc, MOrthRCS, MA, Guest Editor*

*Vol 18 No 2 (June 2012)*

### **MAXILLARY EXPANSION AND MANDIBULAR WIDENING: TREATMENT METHODS AND STABILITY**

*Haluk İ şeri, DDS, PhD, Guest Editor*