



ATSU


National Center for Osteopathic
Principles and Practice Education

Counterstrain: Anterior & Posterior Cervical Spine

Anna E. Esparham, MD, D-ABP,
D-ABMA, D-ABOIM, C-ONMM

Copyright © 2026, A.T. Still University/Kirksville College of Osteopathic Medicine.
This presentation is intended for ATSU/KCOM use only. No part of this presentation
may be distributed, reproduced or uploaded/posted on any Internet web sites
without the expressed written consent from the author or ATSU/KCOM OMM
Department Chairperson.

Anna Esparham, MD D-ABP, D-ABMA, D-ABOIM, C-ONMM



Anna Esparham, MD, is an associate professor at A.T. Still University's Kirksville College of Osteopathic Medicine (ATSU-KCOM). She is a quadruple-board certified physician in Integrative Medicine, Pediatrics, Osteopathic Neuromusculoskeletal Medicine, and Medical Acupuncture. She also has received additional training in headache and integrative pain management, and certifications in clinic hypnosis and aromatherapy. She has several investigator-initiated research publications and has been featured in The New York Times, Shape Magazine, Doctor Radio, and more.

Speaker Disclosure Statements

Dr. Anna Esparham, MD, discloses that she has no relevant financial relationships with any organization producing, marketing, reselling, or distributing healthcare goods or services consumed by, or used on, patients relative to the content of this presentation.

Planning Committee Disclosure Statement

- The Continuing Education Steering Committee (CESC), Osteopathic Principles and Practice (OPP) Committee members, and planners/reviewers of this activity disclose that they have no relevant financial relationships with any organization producing, marketing, reselling, or distributing health care goods or services consumed by, or used on, patients relative to the content of this presentation.
- The copyrighted materials available in this PowerPoint are for educational use only. Redistribution of copyrighted materials is not permitted.
- No discussion of off-label use and/or investigation used in this presentation.



Accreditation Statement

- Missouri Association of Osteopathic Physicians and Surgeons (MAOPS) is accredited by the American Osteopathic Association to provide osteopathic continuing medical education for physicians.
- MAOPS designates this program for a maximum of 2 AOA Category 1-A CME credits and will report CME and specialty credits commensurate with the extent of the physician's participation.
- MAOPS is accredited by the Accreditation Council for Continuing Medical Education (ACCME) to provide continuing medical education for physicians.
- MAOPS designates this live activity for a maximum of 2 *AMA PRA Category 1 Credits™*. Physicians should claim only the credit commensurate with the extent of their participation in the activity.
- This activity has been planned and implemented in accordance with the accreditation requirements and policies of the Accreditation Council for Continuing Medical Education (ACCME) through the joint providership of the Missouri Association of Osteopathic Physicians and Surgeons (MAOPS) and Still OPTI. MAOPS is accredited by the ACCME to provide continuing medical education for physicians.

Objectives

- Describe the anatomic landmarks associated with anterior and posterior cervical counterstrain tender points
- Identify positive cervical tender points using palpation
- Describe the initial positioning and steps involved in counterstrain treatment of cervical tender points
- Demonstrate effective treatment of cervical tender points using counterstrain technique
- Describe the alternate treatment positions that may be required for effective treatment of AC3 and PC3

Counterstrain

Counterstrain,

1. **A system of** diagnosis and treatment that considers the dysfunction to be a continuing, inappropriate strain reflex, which is inhibited by applying a position of mild strain in the direction exactly opposite to that of the reflex; this is accomplished by specific directed positioning about the point of tenderness to achieve the desired therapeutic response.
2. Australian and French use: Jones technique, (correction spontaneous by position), spontaneous release by position.
3. Developed by Lawrence Jones, DO.

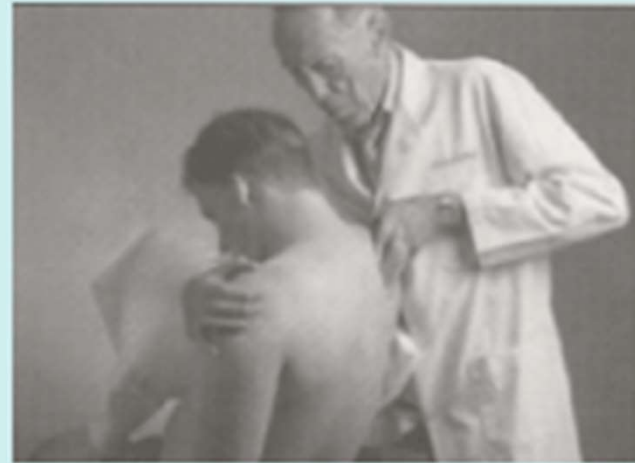Counterstrain

Dr. Jones experimented with different positions for different problems

Found that if he just positioned the affected areas of the body he only needed to maintain the position for 90 seconds

Found discrete tender points associated with different problems

Found both anterior and posterior tender points



Lawrence Jones, D.O., F.A.A.O.

Anterior Cervical Counterstrain

AC1

- 1) Posterior surface of ramus of mandible - *push posterior to anterior*
- 2) Midway between ramus and mastoid process on the transverse process of C1 - *push lateral to medial*

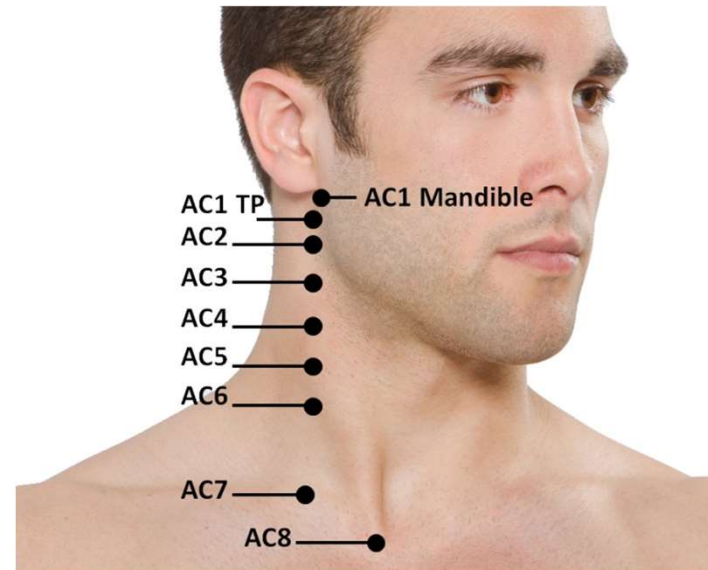
AC2-6 Anterior surface of the transverse processes

AC7

2cm lateral to the medial end of the clavicle (clavicular head of SCM)

AC8

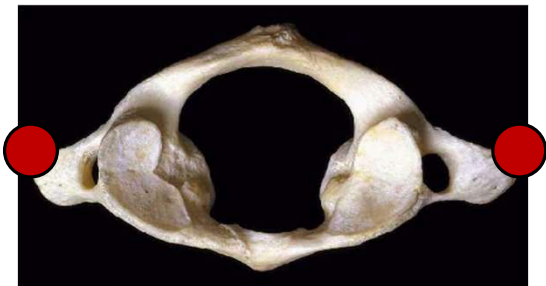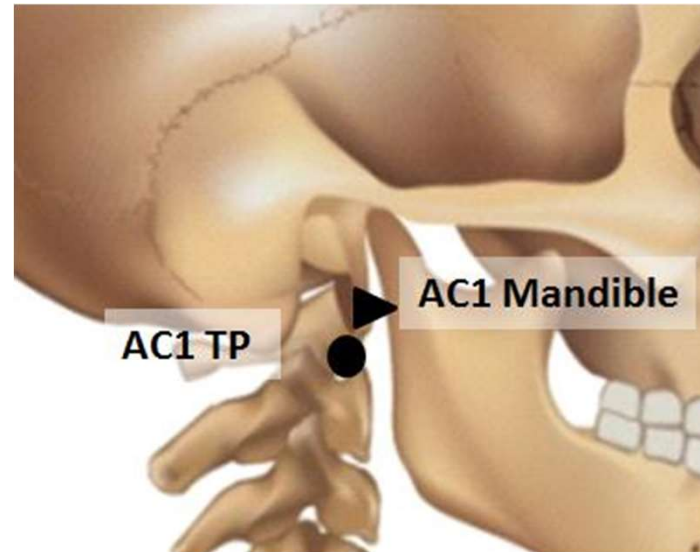
medial end of the clavicle (sternal head of the SCM at sternal notch)



Anterior Cervical Counterstrain

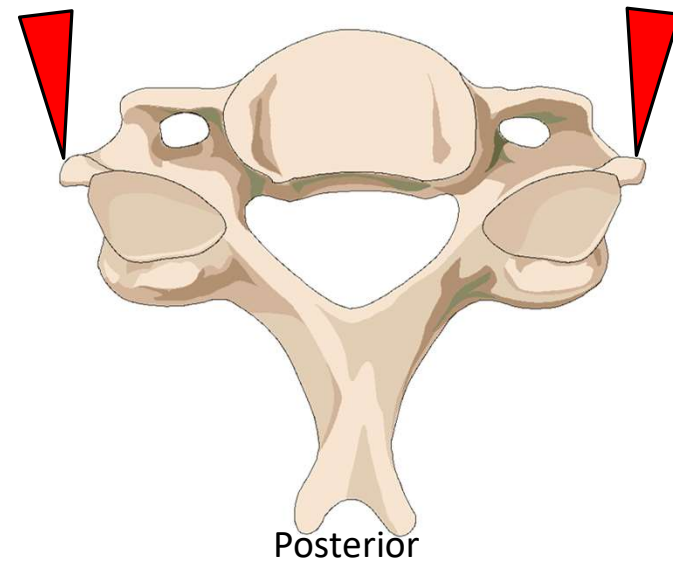
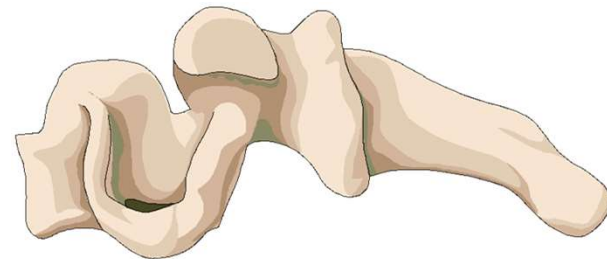AC1

- 1) **Mandible:** Posterior surface of ramus of mandible - *push posterior to anterior*
- 2) **Transverse Process:** Midway between ramus and mastoid process on the transverse process of C1 - *push lateral to medial*



Anterior Cervical Counterstrain

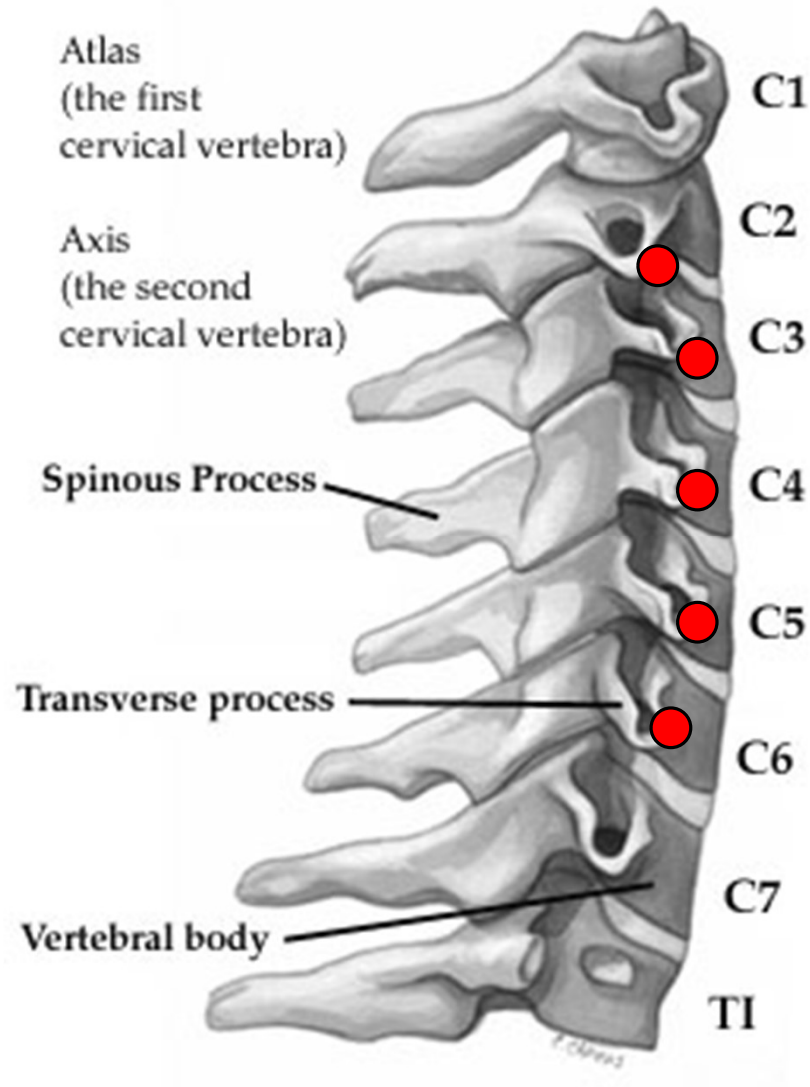
AC2-6 - Anterior surface of the transverse processes



Anterior Cervical Counterstrain

AC2-6

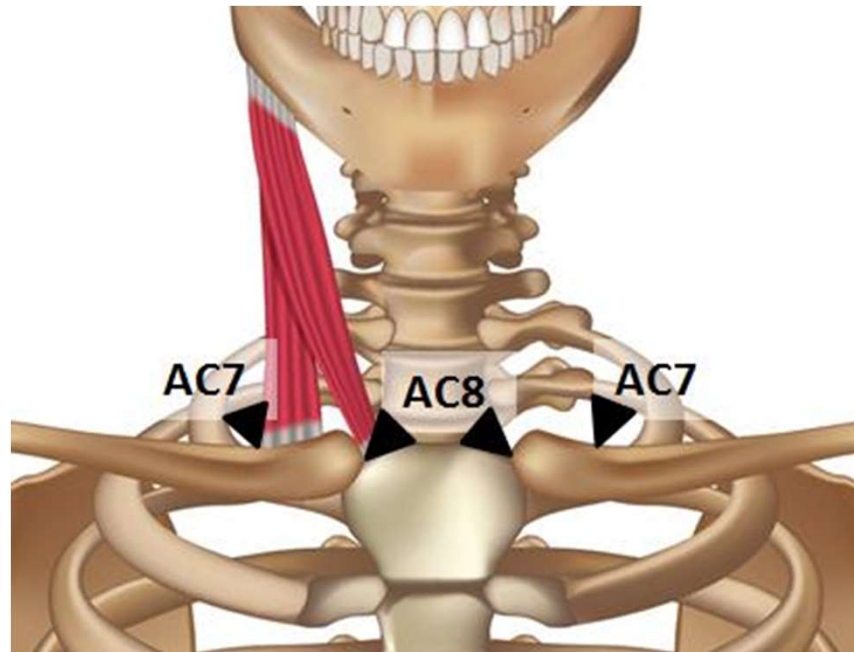
Anterior surface of the transverse processes



Anterior Cervical Counterstrain

AC7 - 2cm lateral to the
medial end of the clavicle
(clavicular head of SCM)

AC8 - medial end of the clavicle
(sternal head of the SCM at
sternal notch)



Lab Exercise

AC1

- 1) Posterior surface of ramus of mandible
- *push posterior to anterior*
- 2) Midway between ramus and mastoid process on the transverse process of C1 - *push lateral to medial*

AC2-6

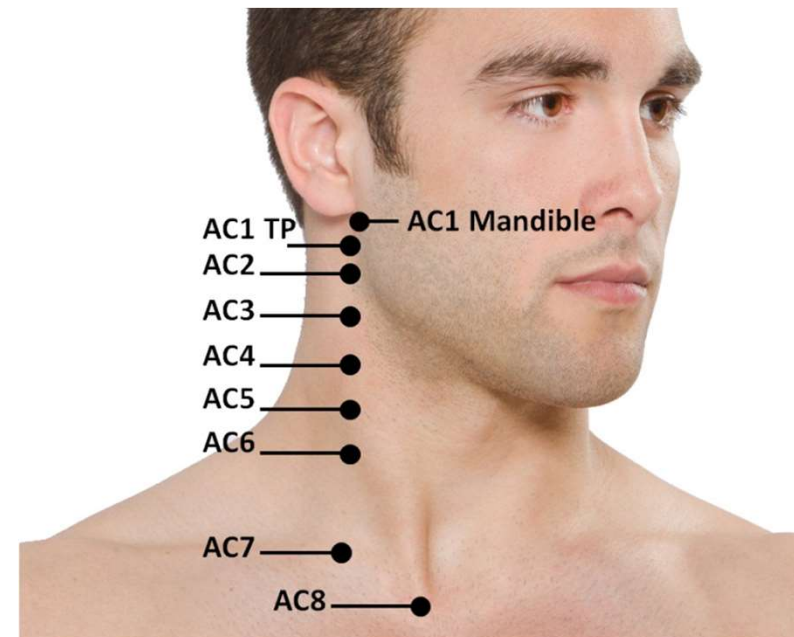
Anterior surface of the transverse processes – *push posteromedially*

AC7

2cm lateral to the medial end of the clavicle (clavicular head of SCM) – *push inferiorly on superior aspect of clavicle*

AC8

medial end of the clavicle (sternal head of the SCM at sternal notch)



Counterstrain Treatment

1. Find the tender point
2. Establish a pain scale
 - a) 10/10, \$1.00's worth of pain, 100% MAX pain
3. Position in standard treatment position
4. Recheck TP -Goal is Zero - minimum is 30% of original pain
5. Fine tune position for maximum effect
6. Monitor point and Hold treatment position for 90 seconds
7. **SLOWLY** return to neutral
8. Recheck point

TIPS

- ▶ Avoid pressure of tender point during 90 second treatment (palpate pressure should be light enough to feel pulse, blood flow, relaxation underneath finger)
- ▶ Reach for 100% resolution; don't settle for just "30%"
- ▶ TPs located more laterally require more sidebending
- ▶ With multiple TPs, treat the most severe first
- ▶ With a row of TPs, treat the middle one first
- ▶ Tell your pts they may be sore for 24-48 hrs

How to Treat AC 1-6

Anterior C1

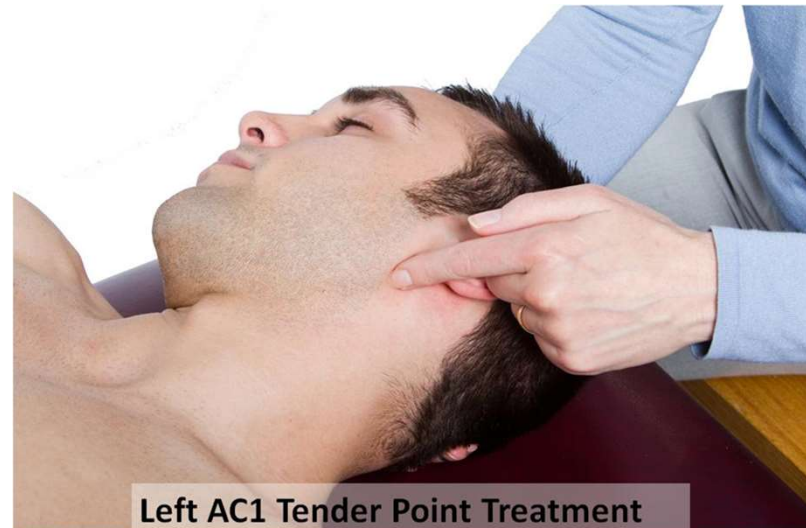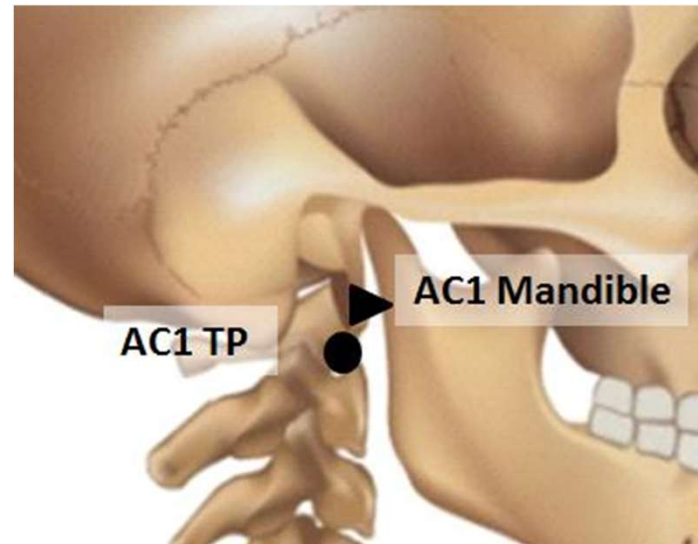
Locations:

1. AC1 TP: On C1 transverse process midway between ramus of mandible and mastoid process - *push lateral to medial*
2. AC1 Mandible: Posterior surface of ramus of mandible - *push posterior to anterior*

Position:

Sidebend and rotate head and neck away from point
(away, away)

CS iBook page 30



Anterior C2-6

Locations:

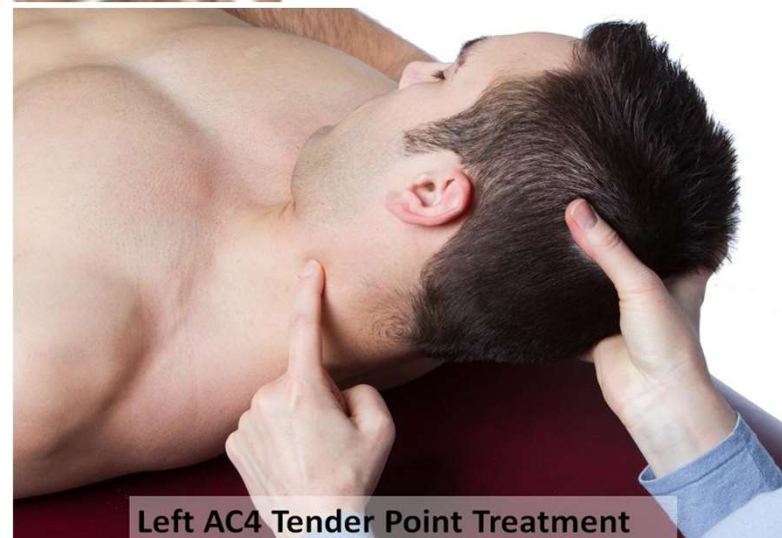
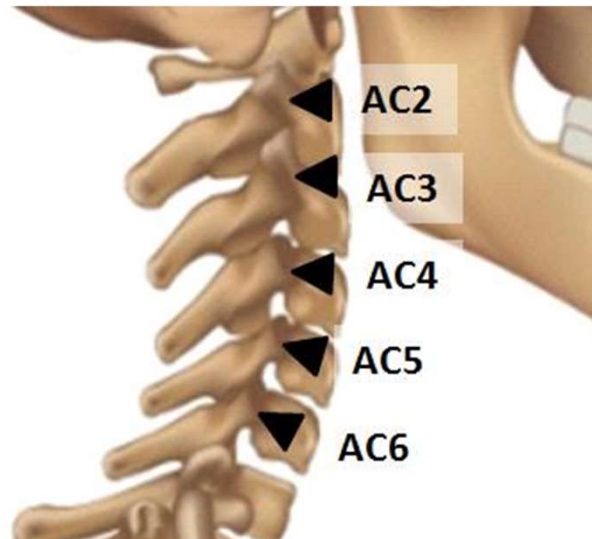
Found on anterior aspect of transverse processes of corresponding vertebra –
push anterior to posterior

Position:

Cervical flexion with sidebending and rotation of head and neck away from point
(Flex, away, away)

Note : sometimes AC3 may need - *ESaRa*

CS iBook page 31



Anterior C3

Locations:

Found on anterior aspect of transverse processes of corresponding vertebra -*push anterior to posterior*

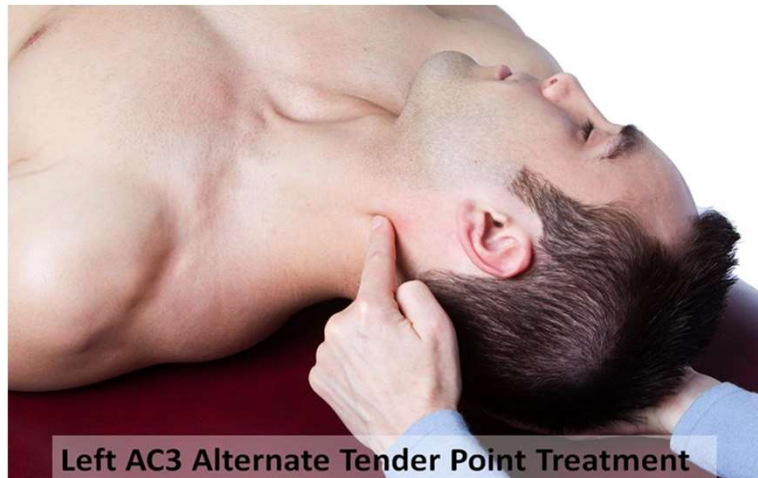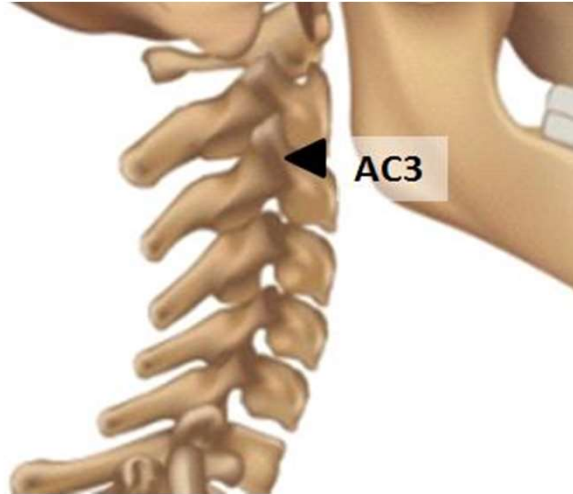
Alternate Position:

Cervical *extension* with sidebending and rotation of head and neck away from point

ESaRa

Note: AC3 may require cervical flexion

CS iBook page 32



Lab Exercise

- ▶ **Anterior C1**

- Rotate away
 - Sidebend away

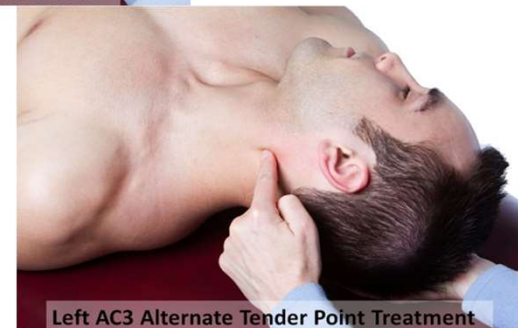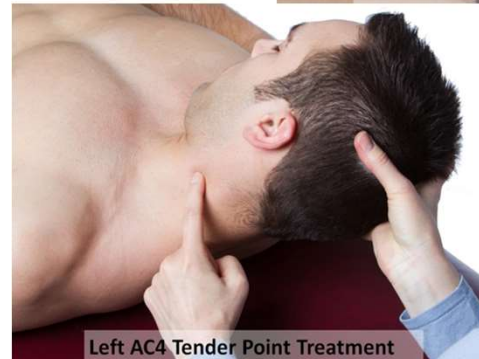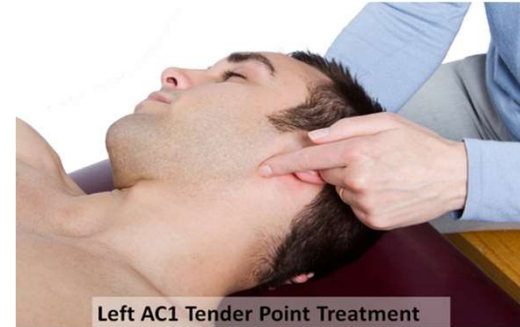- ▶ **Anterior C2-6**

- Flexion
 - Sidebend away
 - Rotate away

- Alternate AC3**

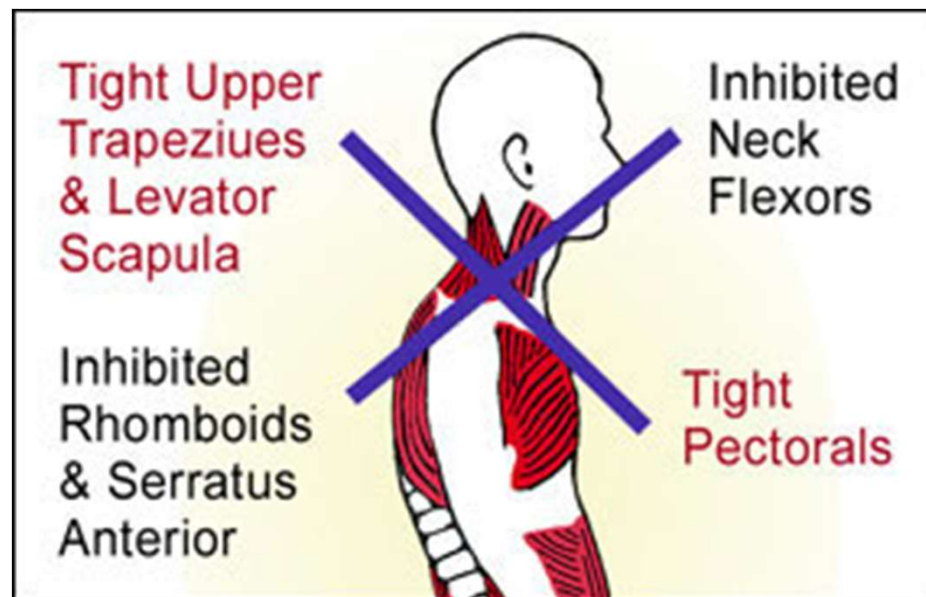
- may need - *ESaRa*

CS iBook page 30-1



Clinical Correlation

- ▶ Postural problems
 - ▶ Upper cross Syndrome
- ▶ Headaches
- ▶ TMJ



How to Treat AC 7 & 8

Anterior C7

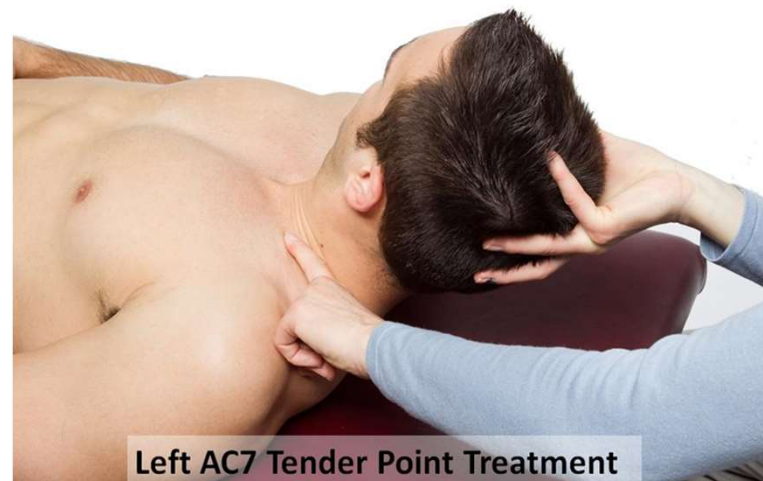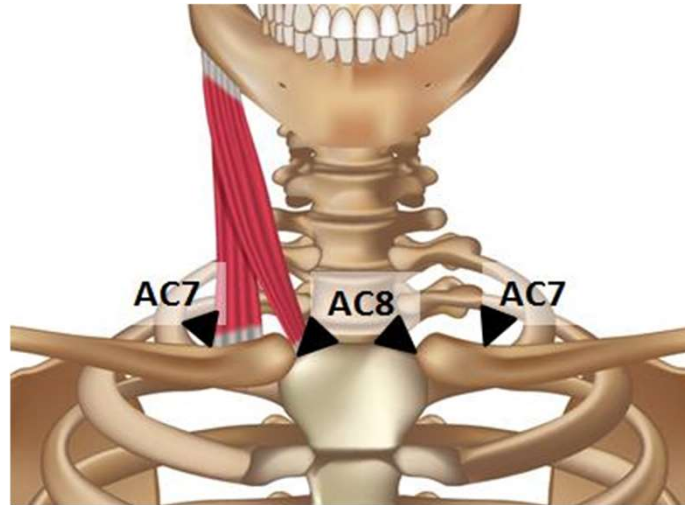
Location:

Found at clavicular insertion of sternocleidomastoid muscle, 2-3 cm lateral to proximal clavicle - *push superior to inferior*

Position:

Cervical flexion with sidebending **towards** and rotation of head and neck **away** from point

CS iBook page 33



Anterior C8

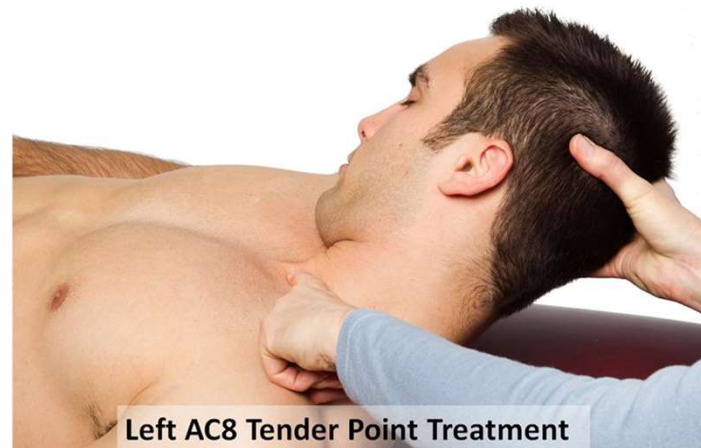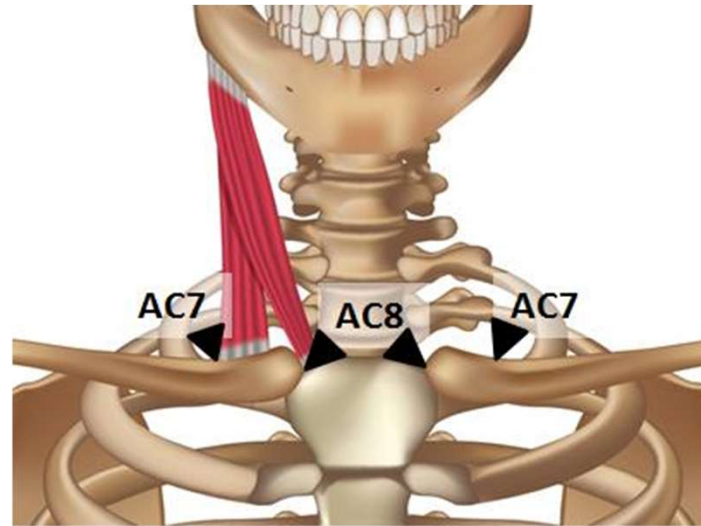
Location:

Found at sternal insertion of sternocleidomastoid muscle
-push superomedial to inferolateral

Position:

Cervical flexion with sidebending and rotation of head and neck away from point

(Flex, away, away)



Lab Exercise

- ▶ **Anterior C7**

Flexion

Rotate away

Sidebend **toward**

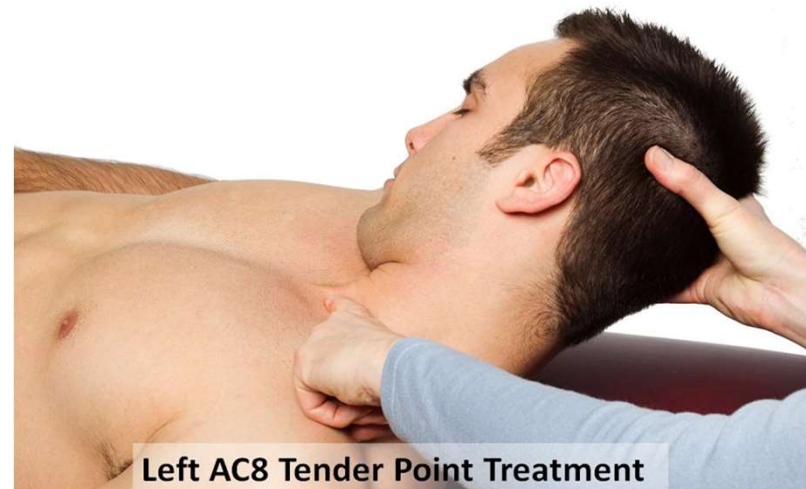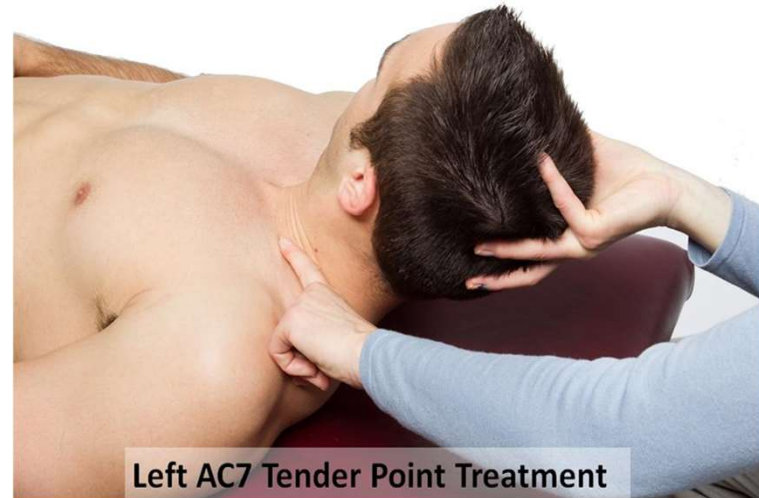- ▶ **Anterior C8**

Flexion

Rotate away

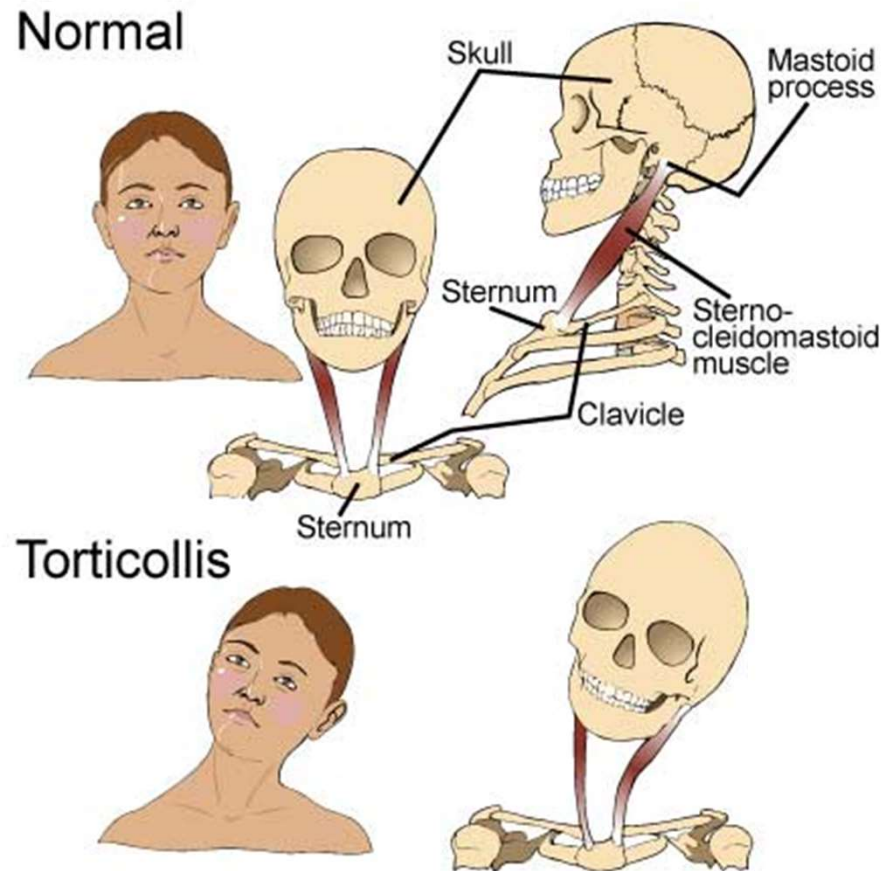
sidebend **away**

CS iBook page 33-4



Clinical Correlation

- ▶ Poor posture
- ▶ Whiplash
- ▶ Torticollis



Posterior Cervical Tender Points

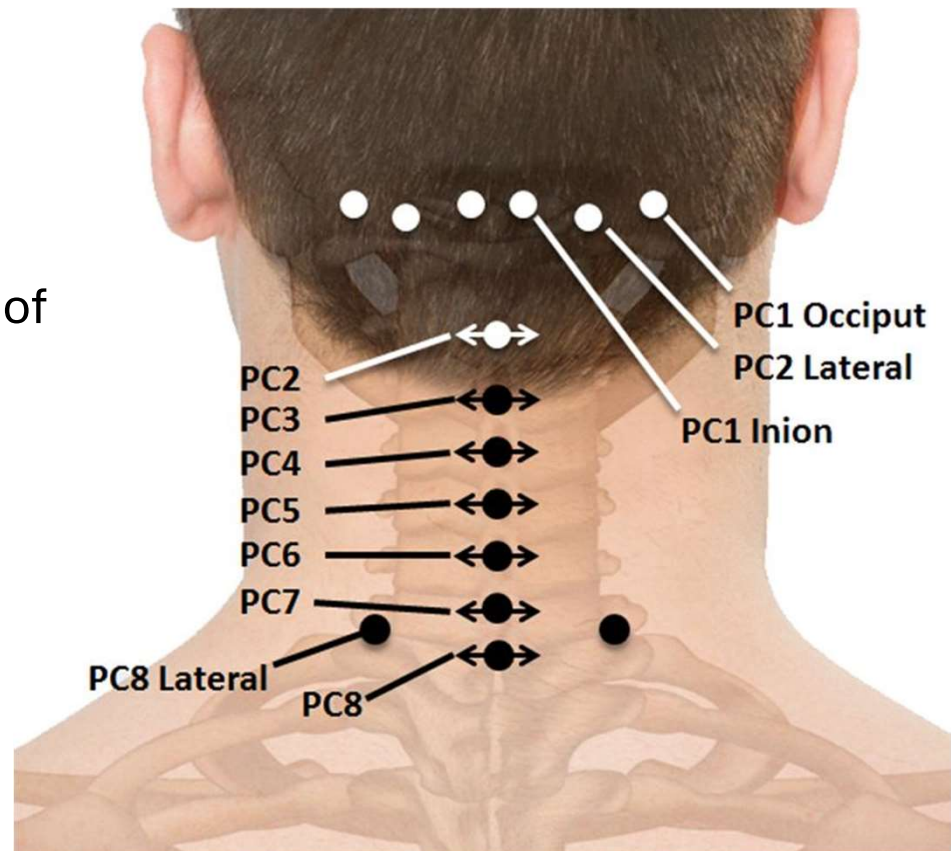
PC1 - inion

PC1 - occiput

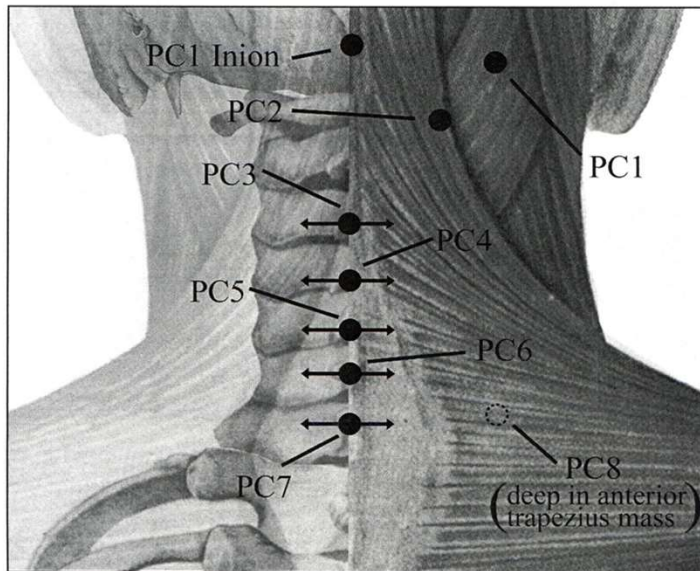
PC2 - lateral, medial

PC3-7 - spinous process of
vertebra above

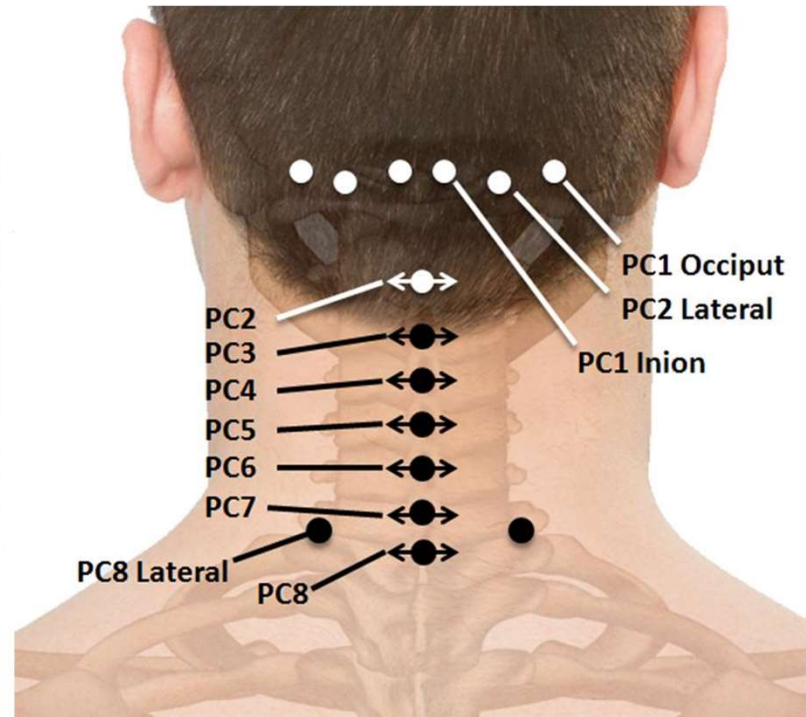
PC8 - lateral, medial



AUTHOR DISAGREEMENT



Named for vertebral level



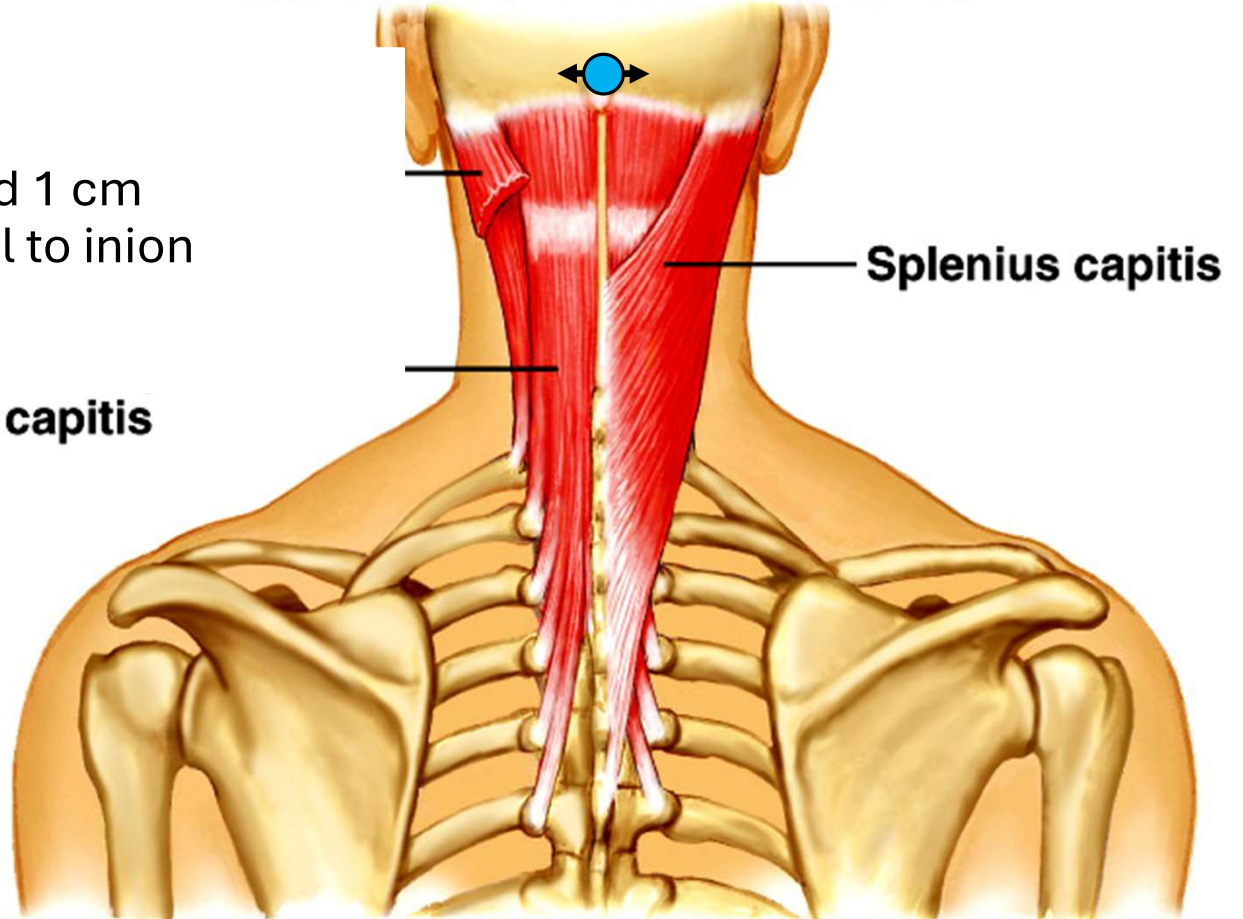
★ Named for nerve root level

Posterior Cervical Tender Points

PC1 Inion – Found 1 cm
inferior and lateral to inion

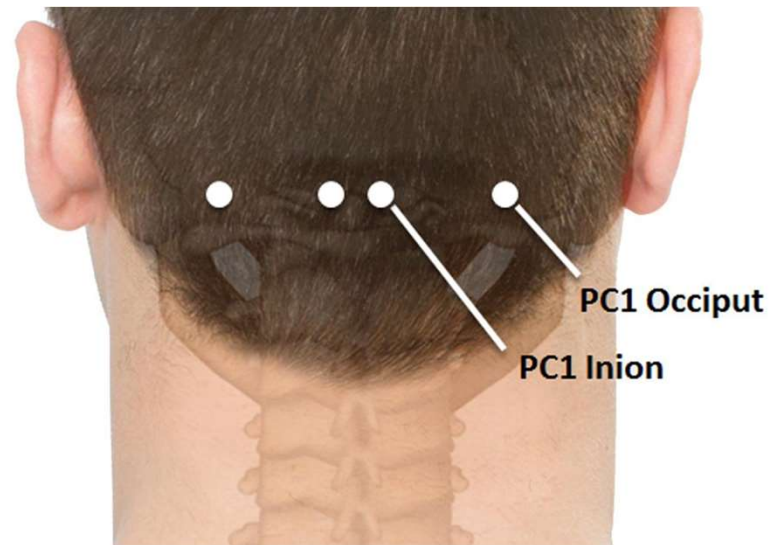
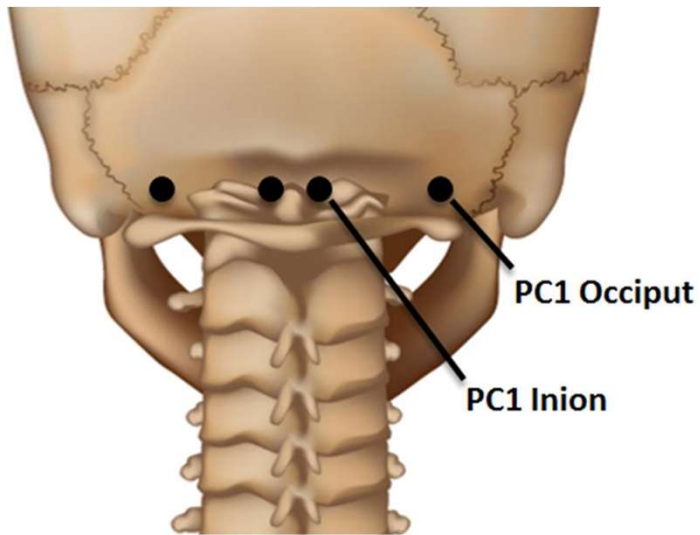
capitis

Copyright © The McGraw-Hill Companies, Inc. Permission required for reproduction or display.



Posterior Cervical Tender Points

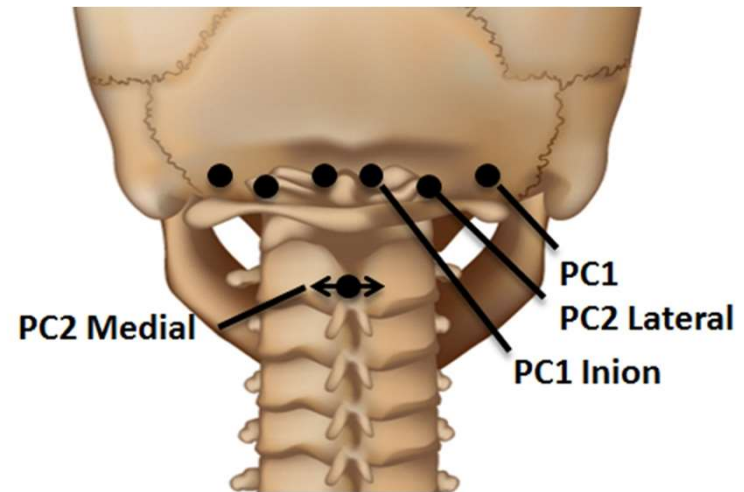
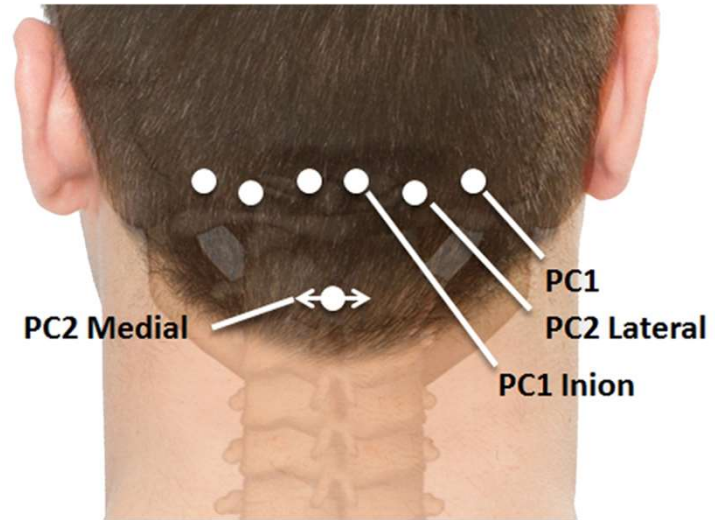
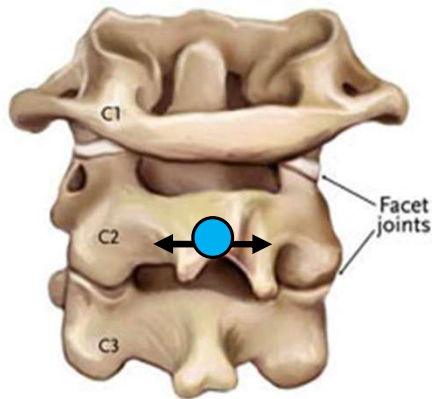
PC1 Occiput – Found on occiput 3-4 cm lateral to midline in muscle mass



Posterior Cervical Tender Points

PC2

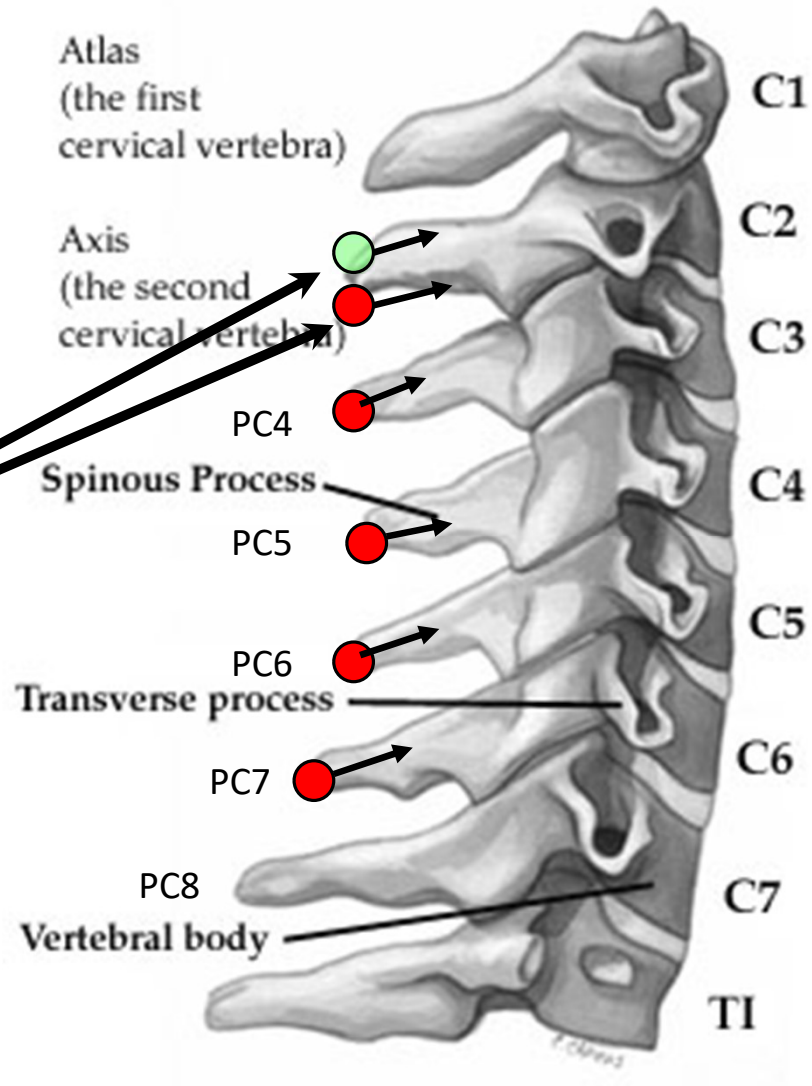
1. Medial - On C2 spinous process or just lateral
2. Lateral - 2 cm lateral to midline below occiput in muscle mass



Posterior Cervical Tender Points

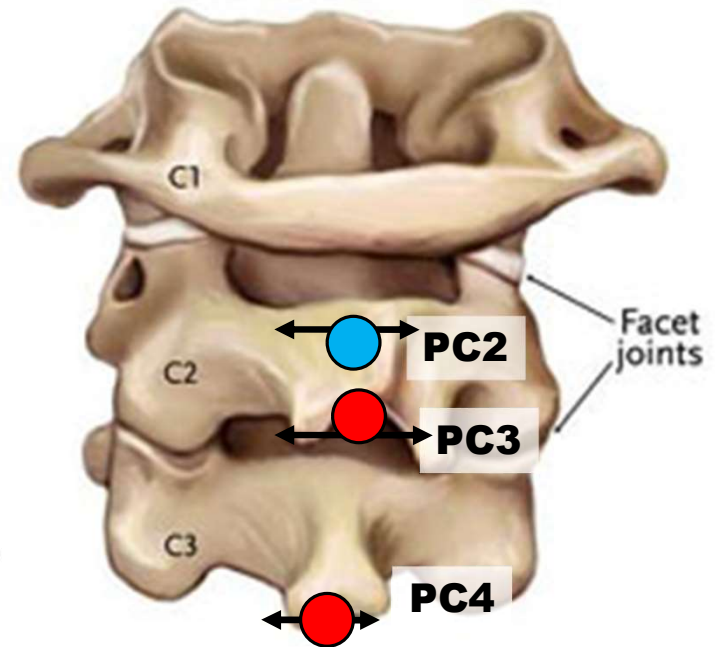
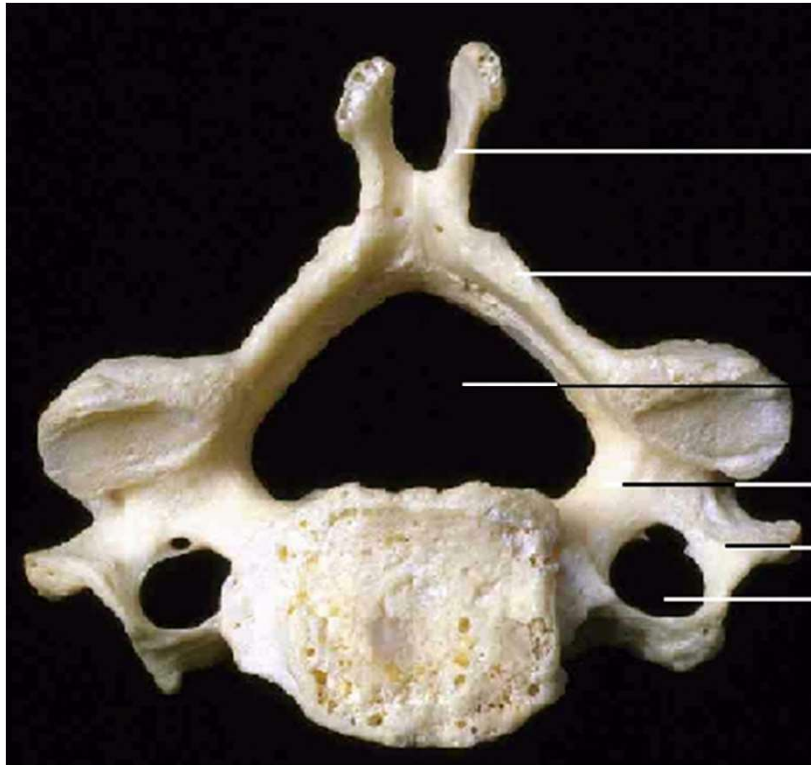
PC3-7 - Midline or slightly lateral to spinous processes of vertebra above

NOTE: PC2 and PC3 are on the same vertebra



PC3-7 - Midline or slightly lateral to spinous processes of vertebra above

Bifid Spinous Processes

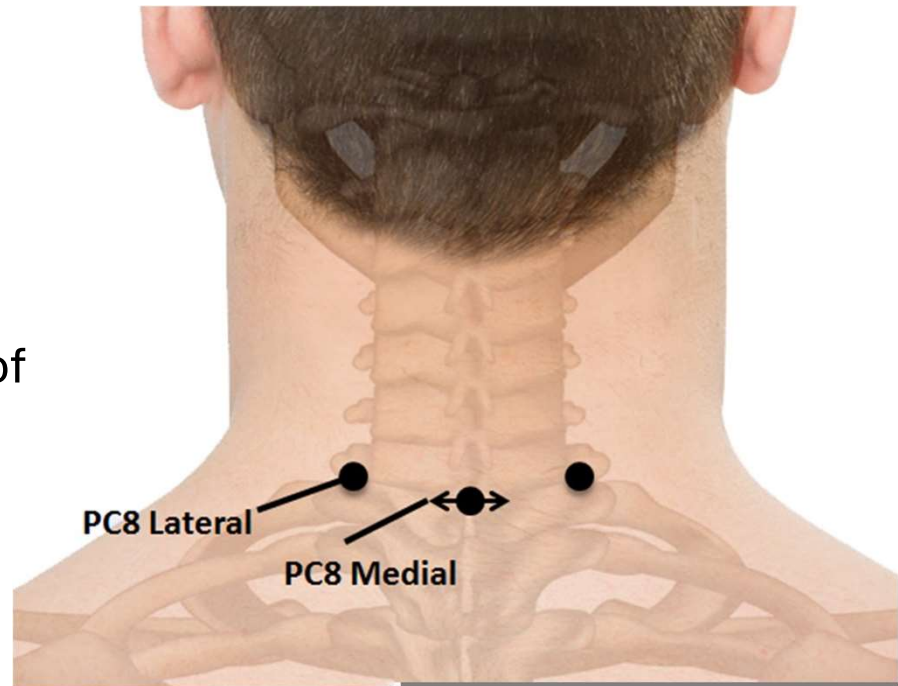


- lamina
- vertebral canal
- pedicle
- transverse process
- transverse foramen

Posterior Cervical Tender Points

PC8 Locations

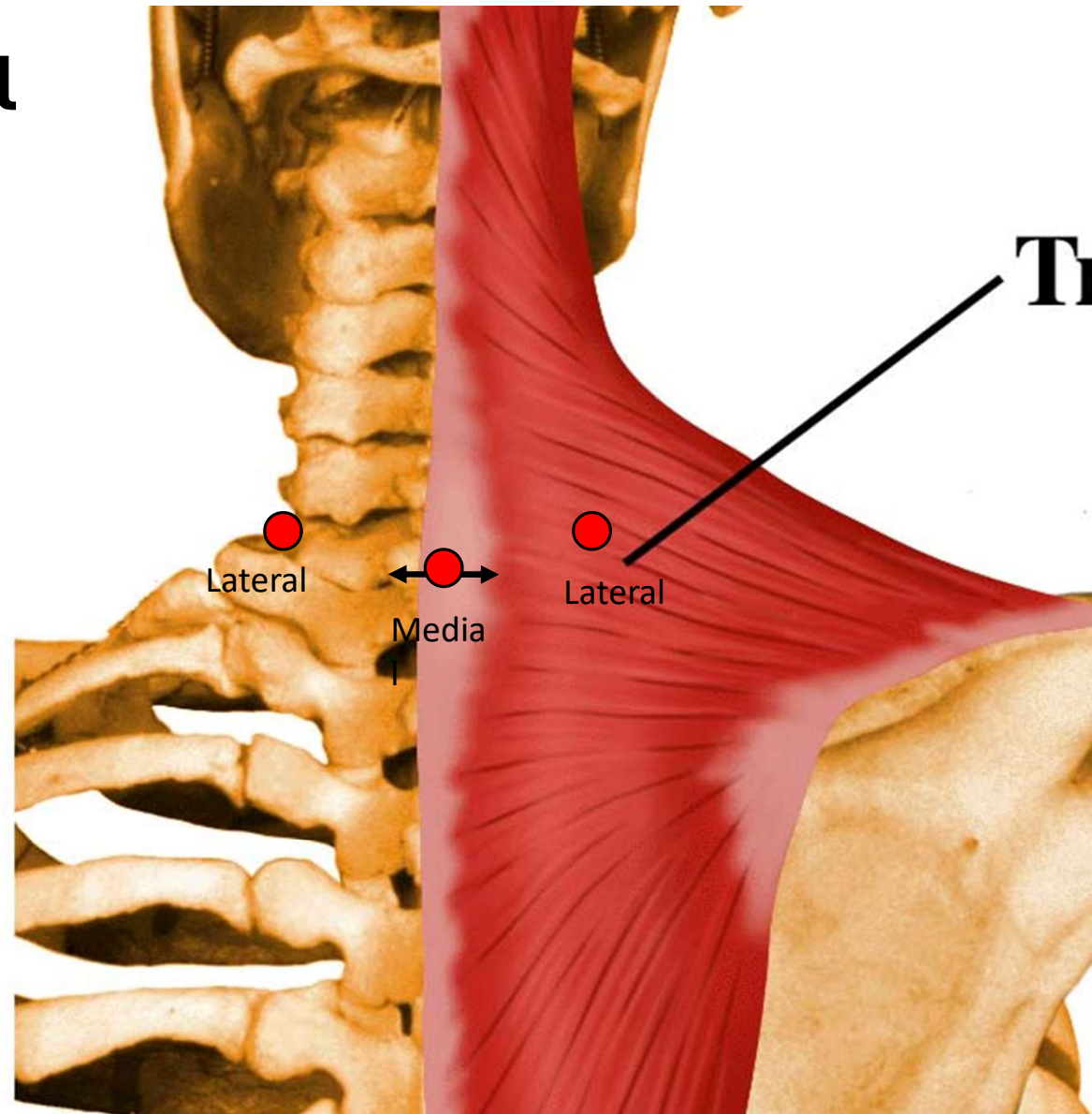
1. Medial - At midline or inferolateral aspect of C7 spinous process
1. Lateral - on posterior tip of transverse processes, anterior to trapezius muscle belly



Posterior Cervical Tender Points

PC8

1. Medial - At midline or inferolateral aspect of C7 spinous process
2. Lateral - on posterior tip of transverse processes, anterior to trapezius muscle belly



Lab Exercise

PC1 Inion

- ▶ On the inion, usually right or left side on protuberance, but occasionally midline

PC1 Occiput

- ▶ 3-4 cm lateral to midline in muscle mass

PC2

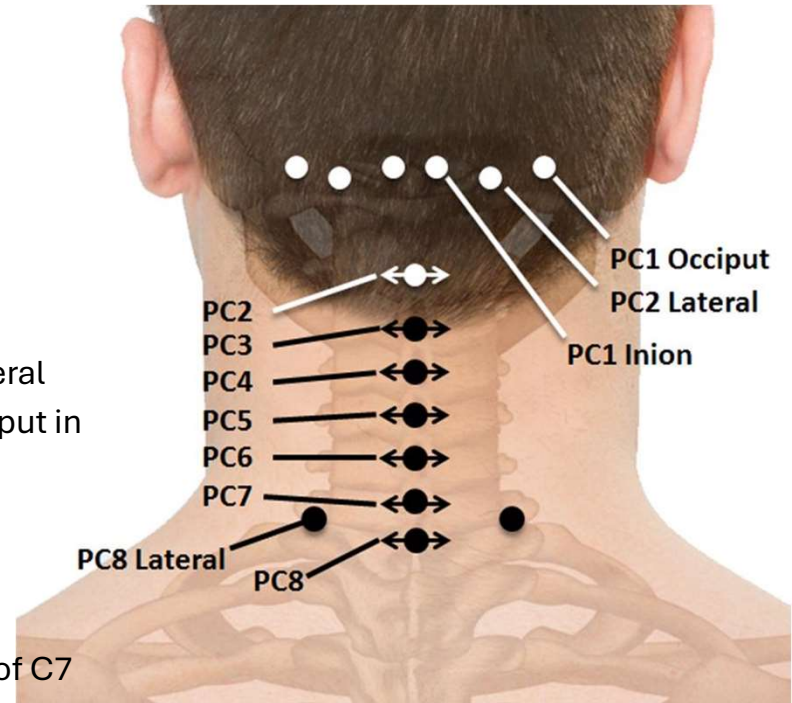
- ▶ Medial - On C2 spinous process or just lateral
- ▶ Lateral - 2 cm lateral to midline below occiput in muscle mass

PC3-7

- ▶ Spinous process of vertebra above

PC8

- ▶ Medial - At midline or inferolateral aspect of C7 spinous process
- ▶ Lateral - on posterior tip of transverse processes, anterior to trapezius muscle belly



How to Treat PC 1 & 2

PC1 Inion

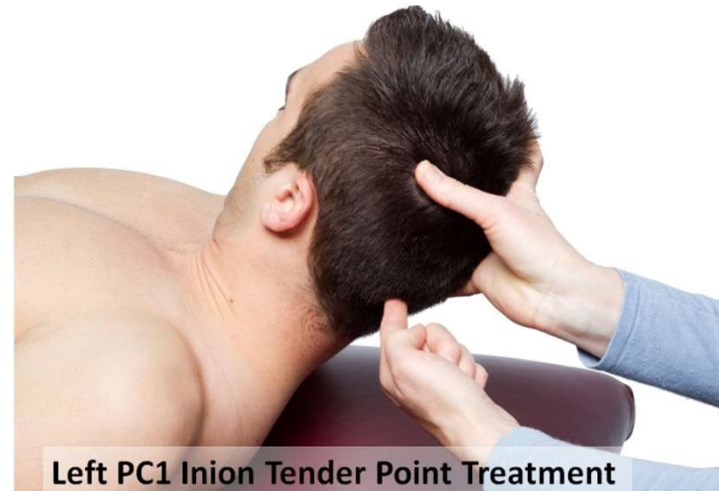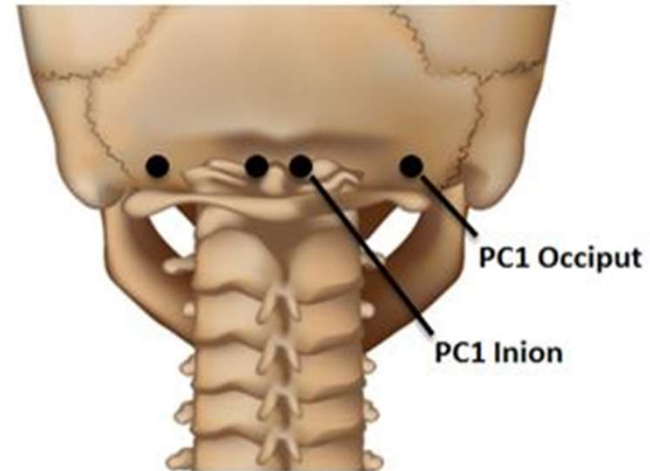
Location:

Found 1 cm inferior and lateral to inion

Position:

Cervical flexion with sidebending towards and rotation of head and neck **away** from point

Flex StRa



Left PC1 Inion Tender Point Treatment

PC1 Occiput

Location

Found on occiput 3-4 cm lateral to midline in muscle mass

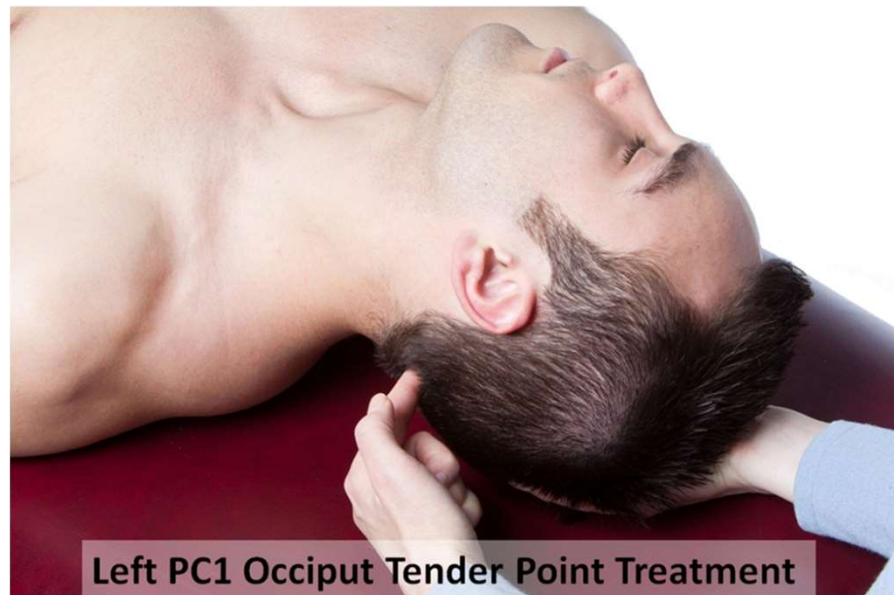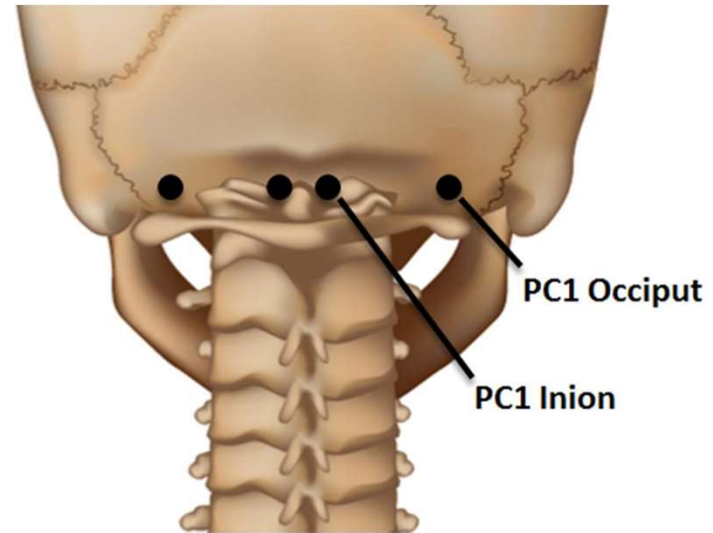
Position:

Cervical extension with sidebending and rotation of head and neck away from point as needed

(Extend, away, away)

E with SaRa as needed

CS iBook page 38



PC2

TWO Locations:

Medial: On C2 spinous process or just lateral

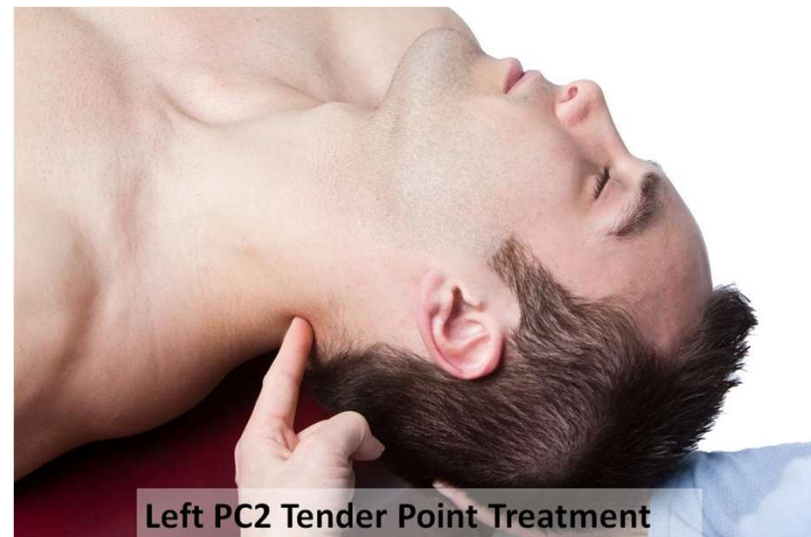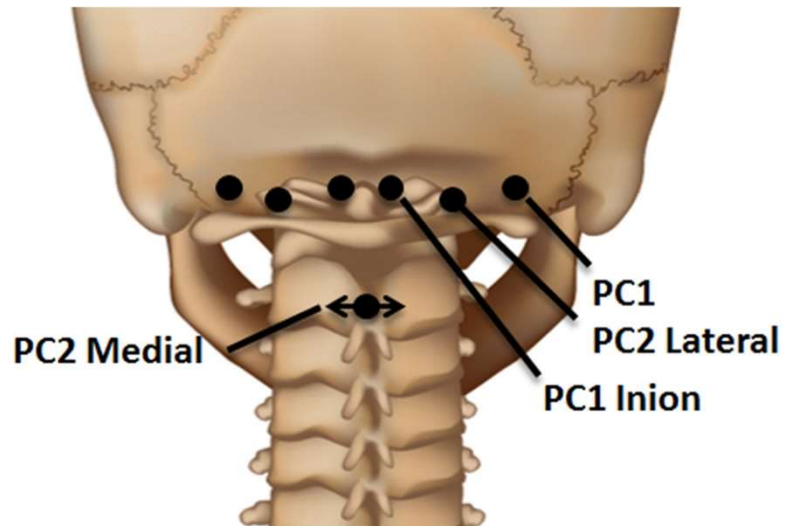
Lateral: 2 cm lateral to midline below occiput in muscle mass

Position:

Cervical extension with sidebending and rotation of head and neck away from point as needed

E with SaRa as needed

CS iBook page 39



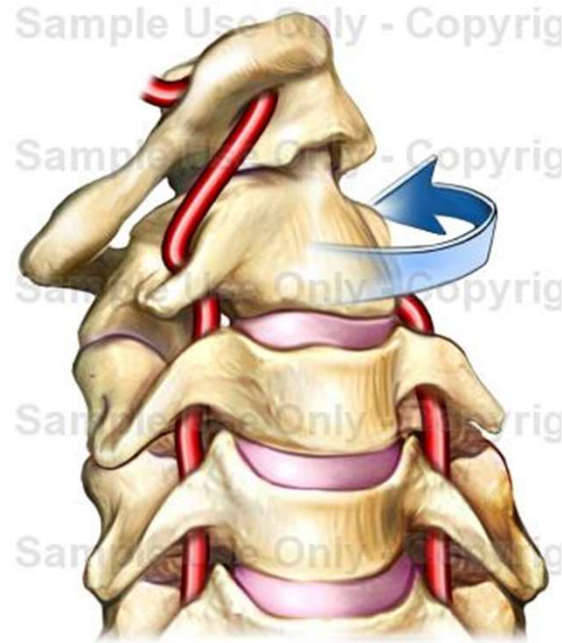
Left PC2 Tender Point Treatment

WARNING

Hyperextension and rotation results in compression of vertebral artery on contralateral side

Vertebral artery stenosis

- ▶ Disequilibrium
- ▶ Vertigo
- ▶ Diplopia
- ▶ Tinnitus
- ▶ Paresthesia
- ▶ Dysphagia
- ▶ Dysarthria
- ▶ Ataxia



Lab Exercise

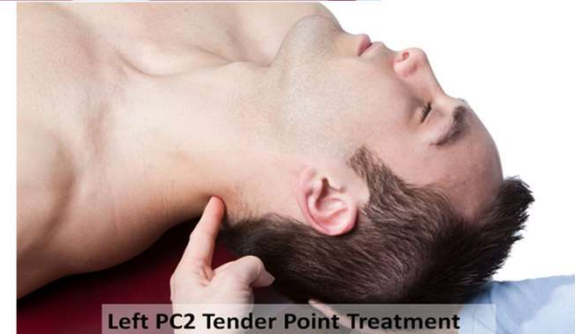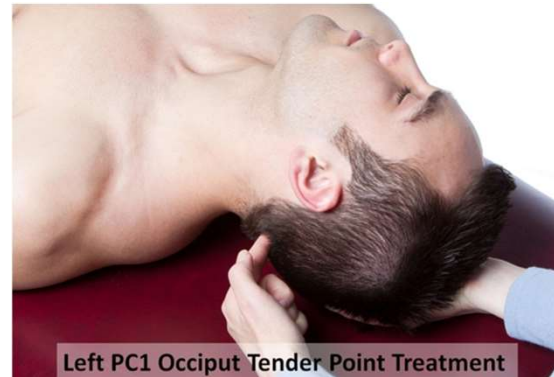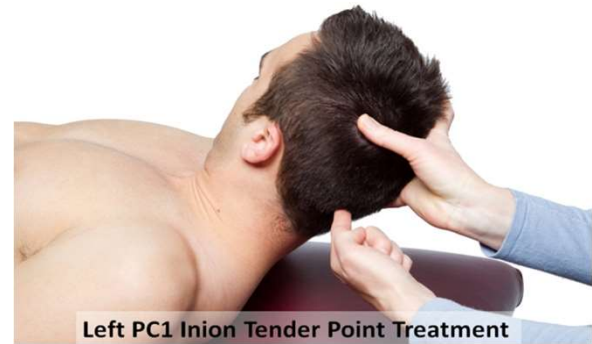**Treat Most significant
Tender Point**

PC1 Inion – *F StRa*

**PC1 Occiput - *E with SaRa as
needed***

**PC2 (TWO Locations)
*E with SaRa as needed***

CS iBook page 37-9



How to Treat PC 3 - 8

Posterior C3

Locations:

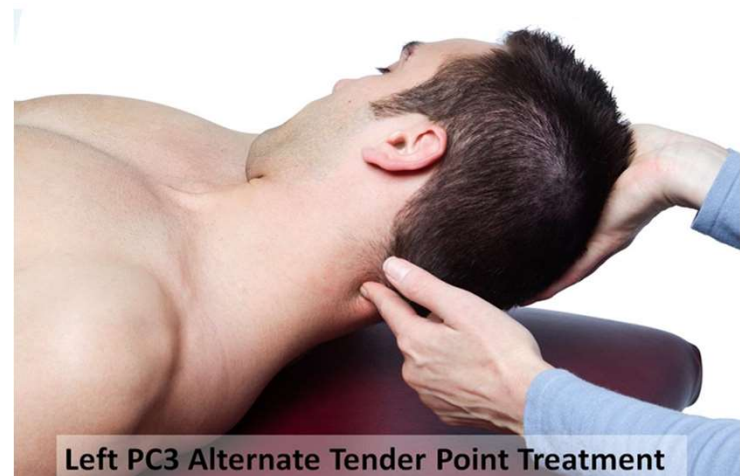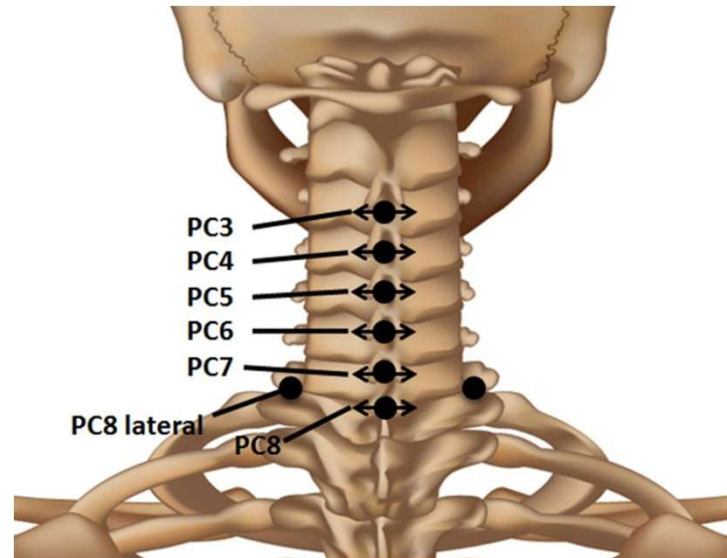
Found at midline or inferolateral aspect of C2-6 spinous processes of named vertebra above or just lateral to spinous processes

Alternate Position:

Cervical flexion with sidebending and rotation of head and neck away from point

Flex SaRa

Note: PC3 may require cervical extension



Posterior C3-7

Locations:

Found at midline or inferolateral aspect of C2-6 spinous processes of named vertebra above or just lateral to spinous processes

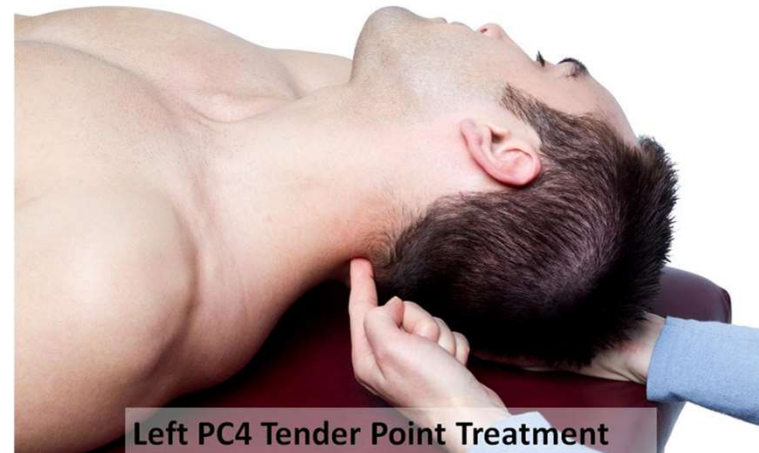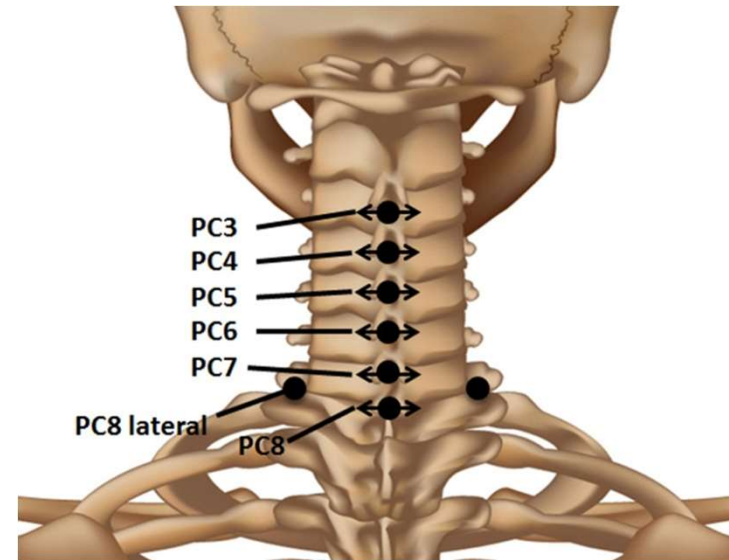
Position:

Cervical **extension** with sidebending and rotation of head and neck away from point

Extend SaRa

- ▶ Note: Midline points may require pure extension
- ▶ Note: PC3 may require cervical flexion

CS iBook page 40



PC8 Location

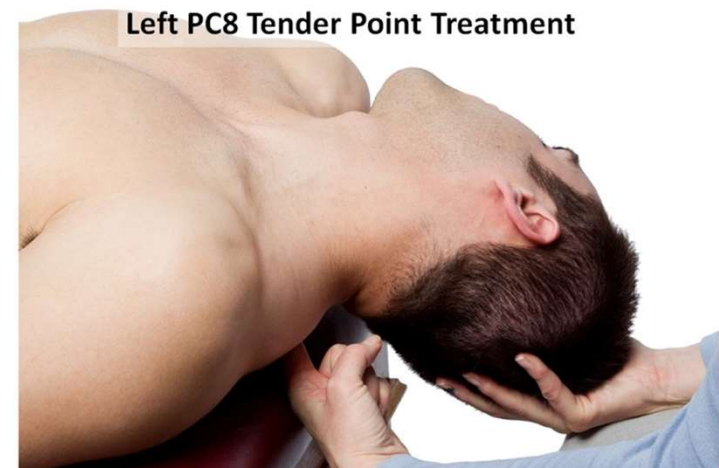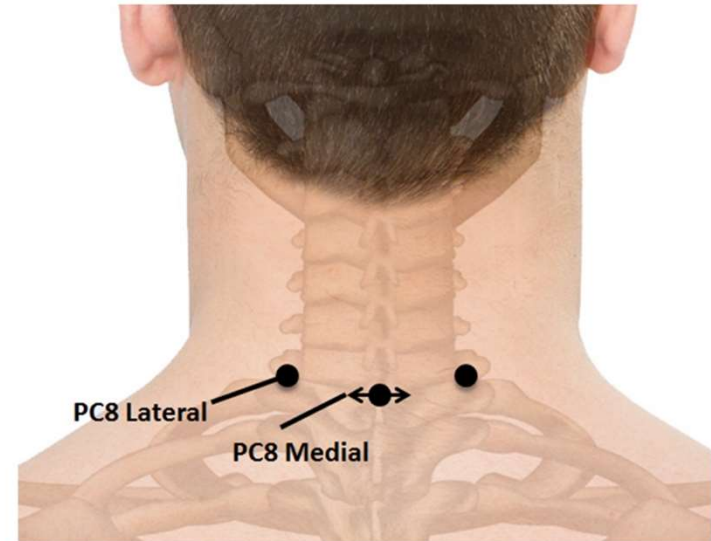
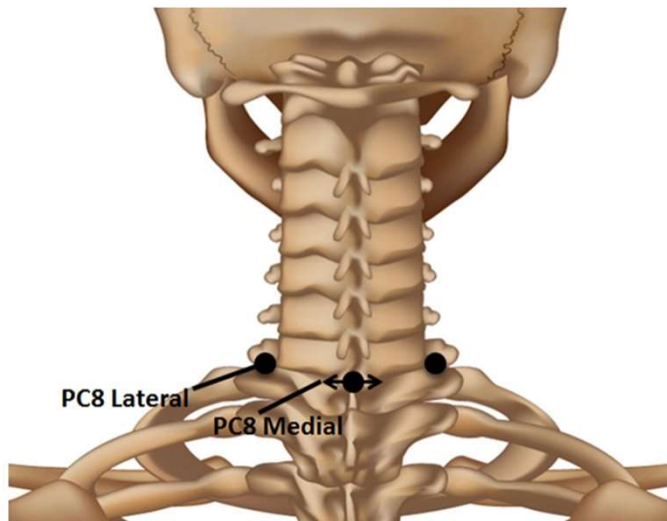
1. Medial: At midline or inferolateral aspect of C7 spinous processes
2. Lateral: On posterior tip of transverse processes, anterior to trapezius muscle belly

Treatment

1. Supine
2. Cervical extension with sidebending and rotation of head and neck away from point
3. Midline points may require pure extension

ESaRa

Anatomical Consideration



Lab Exercise

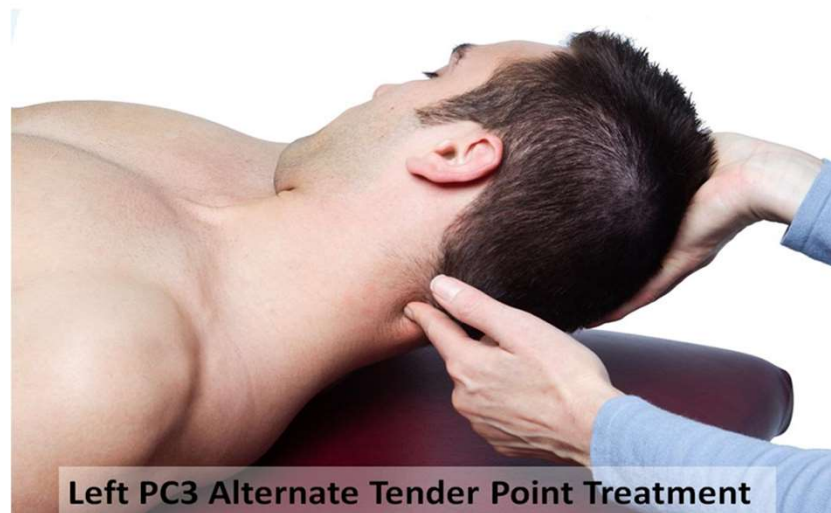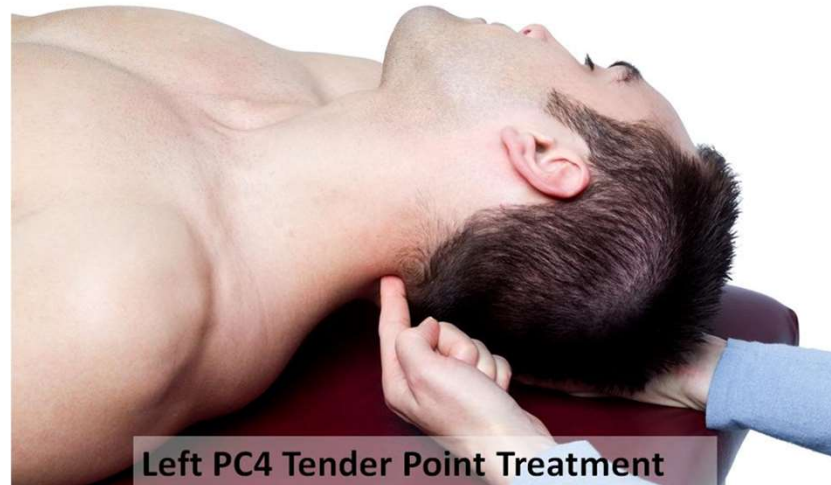Treat most significant
Tender Point

PC3-8 – *ESaRa*

Midline points may require pure
extension

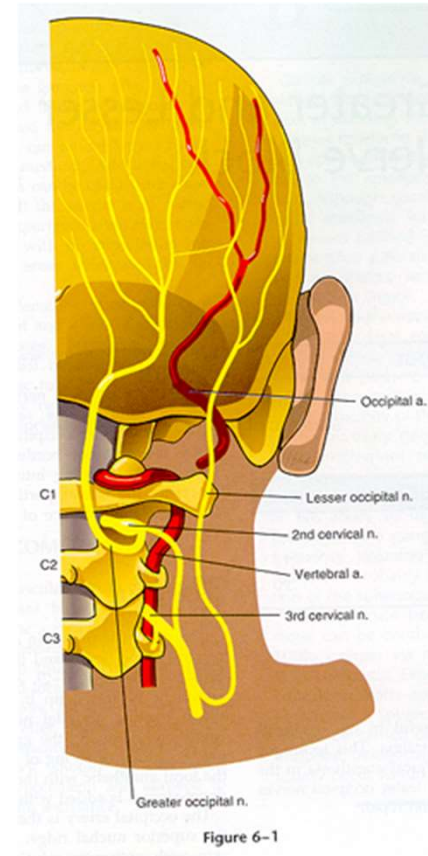

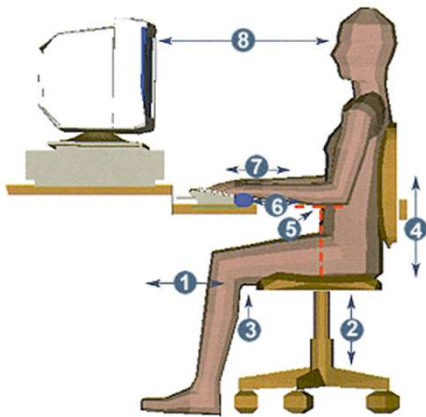
PC3 may require cervical **flexion**

CS iBook page 40



Clinical Correlation

- ▶ Tension headaches
- ▶ Migraine Headaches
- ▶ Occipital neuralgia
- ▶ Poor Posture
- ▶ Crick in the neck



Questions?

annaesparham@atsu.edu

Grievance Policy

All grievances should be in writing and should specify the nature of the grievance. Initially, all grievances should be directed to MAOPS Executive Director, who will then forward said grievance to the Education & Convention Committee. All grievances will receive an initial response in writing within 30 days of receipt. If the participant does not receive a satisfactory response, then they can then submit a complaint in writing to the Bureau of Osteopathic Education of the AOA at 142 East Ontario Street, Chicago, IL 60611.