Notes on Anatomy

By William Smith, D.O.
Copyrighted by publishers
William Smith and C. L. Rider
1898

©Museum of Osteopathic Medicine, Kirksville, MO [RZ 342.S6]

May not be reproduced without permission of the Museum of Osteopathic Medicine

2220

NOTES ON ANATOMY

BY Wm. Smith. D.O.

Copyrighted by the publishers
Wm. SMITH & C. L. RIDER.
1898

MUSEUM OF OSTEOPATHIC MEDICINE, KIRKSVILLE, MO [RZ342.S6]

N O T E S ON A N A T O M Y.

****
****
****
****
**

PREFACE.

These Notes on Anatomy have been prepared expressly for the students in my classes, at the request of many, in order to lessen the vast amount of study required by existing text-books in obtaining an understanding of the more important facts of this branch of study. These notes are not original, they are a compilation from various authorities.

It will be noticed that only the more important relations of structures are given, that only important facts are mentioned, that as far as possible undue prolixity has been avoided.

The work of reproduction has been executed on the Edison Mimeograph; it must be understood that that method does not permit of "proof-revision", what is written by the typewriter has to remain as written, hence it may seem that there is an excess of clerical errors. As far as was possible these have been avoided, but unless one is a positive expert on the typewriter some are sure to occur.

In the Index all strumtures appear under their proper headings, all Muscles are named only once under the heading of "Muscles", all Nerves under the heading of "Nerves", Arteries under "Arteries" and Articulations, Veins etc. in the same manner.

That these Notes may fulfil the purpose for which they were written and that all who use them may find them of service is my cordial wish.

William Smith, M.D., D.O.
L.R.C.P. & S., Edin. L.F.P. & S., Glas., L.M.
Kirksville, Mo.
February, 1898.


THE ARM

The body lying on its anterior aspect an incision is made from the external occipital protuberance to the sacrum in the middle line, another from the 7th. cervical spine to the acromion process and a third along the crest of the ilium meeting the first incision. The skin is then reflected as follows, the portion bounded by incisions 1 and 2 upward and outward, that by incisions 1, 2 and 3 outward. Then is exposed the superficial fascia with its vessels and nerves. The nerves are derived from the posterior divisions of the spinal nerves and are mostly of small size, the upper dorsal reaching the shoulder the lumbar passing as far as the buttock. The cervical and upper dorsal nerves (3) pirce the trapezius close to the spine, the lower 3 dorsal and the 3 upper lumbar appear neah the angles of the ribs and pierce the latissimus dorsi along the oblique line at which the muscular fibres commence, the sacral nerves usually give two small branches through the tendinous expansion near the spine.

The first layer of the muscles of the back, as well as the second, belong to the region of the arm, the first layer consists of the trapezius and latissimus dorsi..

TRAPEZIUS, Origin, Superior curved line of occipital, 7th. cervical spine, ligamentum nuchae, dorsal spines with their supraspinous ligaments. Insertion, Outer third upper surface of clavicle, posteriorly to the origin of the deltoid, inner border of acromion and upper edge of posterior third of spine of scapula. Nerve, Spinal accessory and branches from the cervical plexus. One trapezius in outline is roughly triangular, the two together form the trapezoid from which the muscle gets its name. The ligamentum nuchae in man is composed of white fibrous tissue to a great extent.

LATISSIMUS DORSI,--- Origin, crest of ilium, lumbar fascia, lower 3 dorsal spines, last 3 ribs. Insertion, bottom of bicipital groove. Nerve, Long subscapular.

The Trapezius is now to be divided by a vertical incision near the spine, and the second layer of muscles will be, in part exposed. In reflecting the muscle note the triangular surface at the inner end of the spine of the scapula over which it glides in action. The second layer of muscles consists of the levator anguli scapulae and the rhomboidei.

LEVATOR ANGULI SCAPULAE. Origin, posterior tubercles on transverse processes of the upper three or four cervical vertebrae. Insertion, vertebral border of scapula between spine and superior angle. Nerve, 5th. cervical and deep branches of the cervical plexus. The surface of this muscle covers the splenius colli and will be again seen in the posterior triangle of the neck.

RHOMBOIDEUS MINOR.-- Origin, ligamentum nuchae and spines of C7 and D1, a narrow muscle, Insertion, vertebral border of scapula opposite spine. Nerve, nerve to the rhomboids (supra-clavicular branch of brachial plexus).

RHOMBOIDEUS MAJOR.--Origin, Spines of upper three, four or five dorsal vertebrae with their ligaments, missing the first. Insertion, vertebral border of scapula opposite the infra-spinous fossa, middle fibres connected to a fibrous arch which is unconnected with the bone. Nerve, nerve to the rhomboids.

The superficial cervical artery passes over the outer surface of the lev. ang. scap., and the posterior scapular artery runs beneath this muscle to reach the hinder end of the scapula, (or vertebral border) between the attachments of the rhomboids and the serratus magnus.

DISSECTION TO EXPOSE THE POSTERIOR SCAPULAR ARTERY, lay the body face down-.

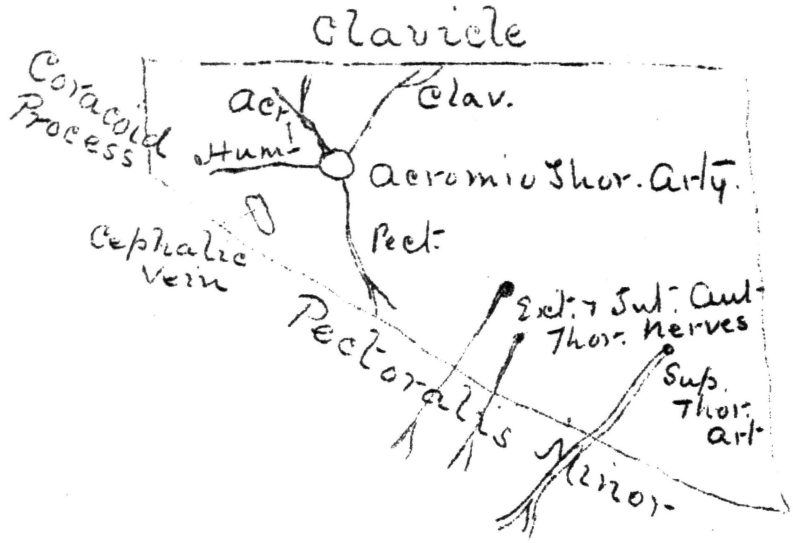
Clavicle
Coracoid Process
Acr.
Clav.
Hum.
Acromio Thor. Artery
Cephalic Vein
Pect.
Pectoralis
Ext. & Sup. Anal Thor. Nerves
Sup. Thor. art.
Minor

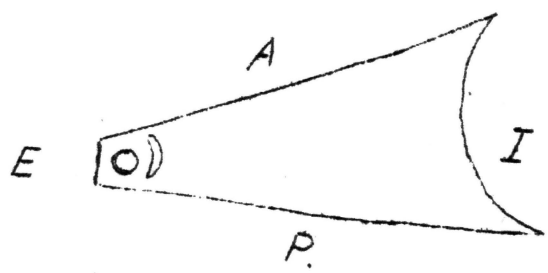
A
E
I
P

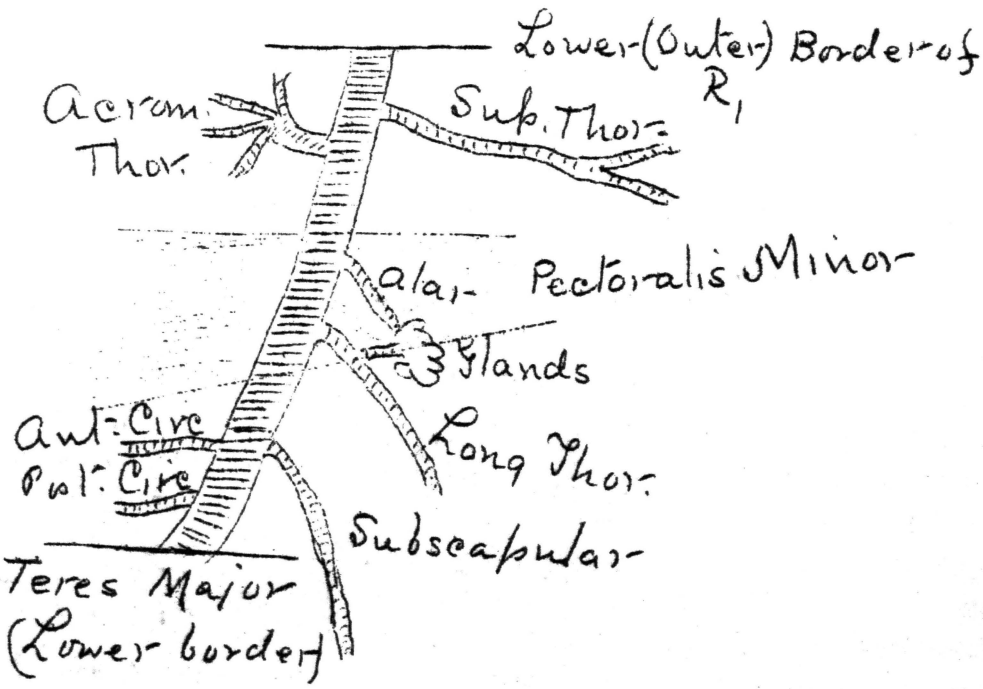
Lower (Outer) Border of R1
Acrom. Thor.
Sup. Thor.
Pectoralis Minor
Glands
Long Thor.
Ant. Circ
Post. Circ
Subscapular
Teres Major
(Lower border)

ward, reflect the skin, superficial fascia, fascia lata, the trapezius, the two rhomboids, pull outward the levator anguli scapulae and the artery is exposed. It is a branch of the transversalis colli.

The body is now turned upon its back and the dissector devotes his attention to the pectoral and axillary regions. The arm being drawn away from the side an incision is made half an inch from the middle line of the sternum in its whole length, this line is to be joined by another at right angles running the entire length of the clavicle to the acromion process, thence in a vertical direction half way down the upper arm, thence across the inner aspect of the arm as far as the level of the posterior fold of the axilla. Another incision is then to be made transversely outward from the ensiform cartilage to the posterior axillary boundary. The large flap of skin thus marked out is to be carried toward the arm. Beneath the skin is the subcutaneous fascia which often contains a considerable amount of fat. The mamma will also be exposed in the female or, in the male its rudiment.. In the subcutaneoust fascia are found the anterior cutaneous branches of the intercostal nerves and of the internal mammary artery. They appear at regular inoervals in the intercostal spaces on each side of the sternum as they pierce the pectoral muscle, and are of small size. Terminations of the superficial cervical plexus may also be found, and some twigs are found .s low down as the 4th. rib. The pectoralis major and minor are the two muscles found in this region which belong to the arm.

PECTORALIS MAJOR.--consists of a sternal and a clavicular portion, separated at their origin by a cellular interval. Origin, whole length of one side of sternum, cartilages of all the true ribs except the 7th., intercostal fascia and aponeurosis of external oblique. Anterior surface of sternal half of clavicle, Insertion, anterior or outer lip of bicipital ghoove by three superimposed laminae, superficial being the clavicular fibres, the middle of the upper sternal the deep of the lower sternal and those from the aponeurosis of the external oblique. Nerve, external and internal anterior thoracic.

PECTORALIS MINOR..-- lies beneath major, invested on both surfaces by a fascia attached above to the costo-coracoid membrane, below to the axillary fascia. Origin, anterior extremities of the bony portions of the 3rd., 4th. and 5th. ribs, and intercostal fascia, (sometimes also from the 2nd.). Insertion, inner side and upper surface of the coracoid process of the scapula and often into a septum between it and the coraco brachialis. Nerve, internal anterior thoracic which pierces it to reach the major. The muscle crosses obliquely the axillary vessels and nerves and is said to divide the artery into its three parts.

THE COSTO COPACOID MEMBRANE. is attached above to the clavicle so as to enclose the subclavius muscle. The posterior layer is continuous with the axillary sheath derived from the deep cervical fascia. The lower edge reaches from the the first rib to the coracoid process and passes downward over the pectoralis minor. It is pierced by the cephalic vein, the acromio-thoracic vessels, the superior thoracic artery and the internal and external anterior thoracic nerves.

THE AXILLA is a four-sided pyramid, apex, a cap of f.rcia lata bounded by the clavicle, first rib and scapula. base, the axillary fascia which is very strong fascia lata. Anterior wall, pectoralis major and minor and clavi-pectoral fascia. Posterior wall, subscapularis, teres major and latissimus dorsi, Inner wall ribs with muscles clothing them, Outer wall, humerus and coraco brachialis. The axilla is deepest with the arm at an angle of 45* to the side. The space contains the axillary vessels, the cords of the brachial plexus and their branches

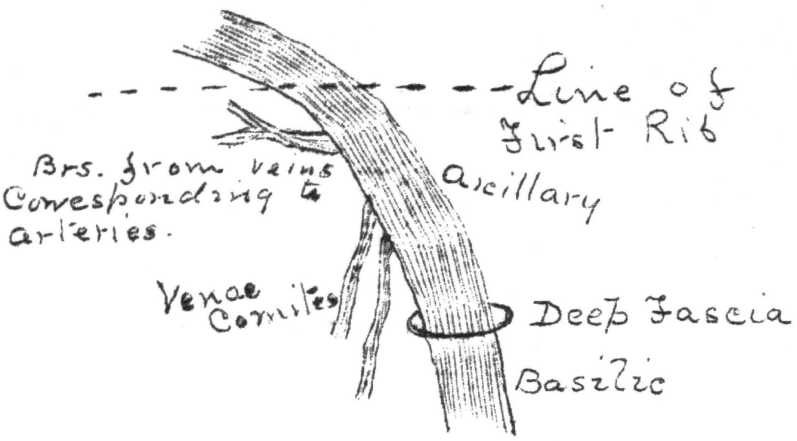

The Axillary Vein.

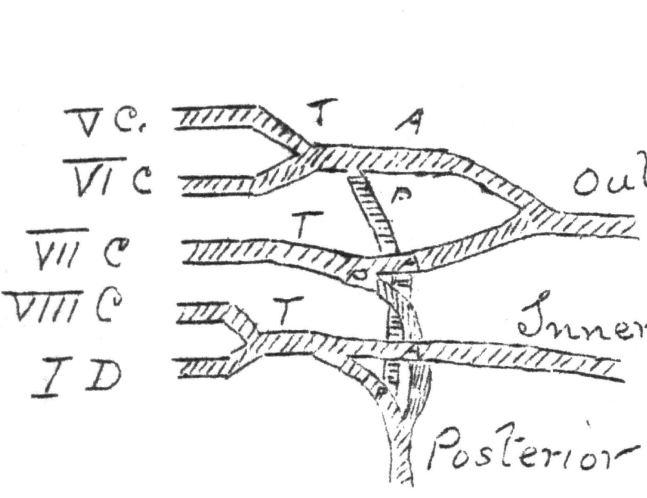

Br's.

Outer Cord
- Excl. Ant. Thor.
- Outer hd. Med.
- Musculo Cut.

Inner Cord
- Inner hd. Med
- Ant. Ant. Thor.
- Ant. Cut.
- Lesser Ant. Cut. Ulnar

Posterior Cord.
- Circumflex
- Subscapulairs
- Musculo spiral.

T indicates Trunks
A " Ant. Brs. of Trunks
P " Post. " " "

Brachial Plexus.

18 or 20 lymphatic glands and their accompnying vessels and a considerable mass of.fat

THE AXILLARY ARTERY begins at the outer border of the 1st. rib and ends at the lower border of the teres major. Its branches are the superior thoracic, acromio thoracic, (from the 1st. part) the long and alar thoracic (from the 2nd part) and from the 3rd. part the subscapular and anterior and posterior circumflex. (The pectoralis minor in its passage across the artery, as previously mentioned, dividing it into three parts).

Relations of the 1st. Part. Anteriorly, Pectoralis major and costo coracoid membrane, Posteriorly, Serratus magnus and nerve of Bell, Externally, cords of the brachial plexus, Internally, Axillary vein. Relations of 2nd. part, Anteriorly, Pectoralis major and minor, Posteriorly , posterior cord of the brachial plexus and the subscapularis muscle, Externally, the outer cord of the brachial plexus and Internally the inner cord and the axillary vein. In t 3rd. part of its course the artery has in fron the pectoralis major, the axillary fascia and the median nerve, behind it has the musculo spiral nerve, the circumflex nerve and the subscapularis muscle. To its inner side lie its vein the ulnar nerve, the internal cutaneous nerve and the nerve of Wrisberg, to it outer side the musculo cutaneous nerve and the coraco brachialis muscle.

THE AXILLARY VEIN is formed bythe basilic and the venae comites of the brachial arter y. On opening the axilla two or more arteries are seen running parallel along the inner wall, they can be thus distinuished. The long thoracic runs along the lower border of the pectoralis minor, the thoracic branch of the subscapular runs with the nerve of Bell.

Lymphatics of the arm consist of vessels and glands, the vessels are in two sets and run from the hand to the axilla, one is superficial and runs with the superficial veins, and a deep which runs with the arteries. Aout twi inches above the internal condly eof the humerus are two or three epi-thochlear glands while in the axilla are found from 18 to 20 glands which drain the lymph not only from the arm but from the thoracic wall, the arm and that region but also from the mamma.

THE BRACHIAL PLEXUS is formed by the antereor divisions of the 5th., 6th., 7th. and 8th cervical nerves, the 1st. dorsal and a small branch of communication with the 4th. cervical nerve. The nerves appear at the lower border of the scalenus anticus (outer border) because the 8th. cervical and 1st. dorsal unite close to the vertebral foramina. They all lia against the scalenus medius and posticss and above the level of the subclavian artery. The 5th. and 6th. next unite and thus three trunks are formed. The three trunks formed by the junction of the five nerves subdivide to form three cords as follows, each trunk divides into an anterior and posterior branch, the anterior branches of the upper and middle trunk formed by the union of the 5th. and 6th. cervical form with the anterior branch of the 7th. the outer cord, the anterior branch of the trunk formed by the junction of the 8th. and 1st. dorsal form the inner cord, uhile the postereor divisions of the three trunks form the postereor cord.. Above the clavicle the (a small branch lying in fro t of the plexus) branch to the subclavius, crosses the third part of the subclavian artery and communicates wit the phrenic. (NOTE, these are the supra-scapular branches) The nerve to the rhomboids from the 5th. pierces the scalenus medius, passes under the levator anguli scapulae to which it gives a

branch, and enters under surface of the rhomboids. The supra-scapular nerve the largest given off above the clavicle is given off from the cord formed by the 5th. and 6th. or the 5th., 6th. and 7th. It disappears behind the trapezius, clavicle and posterior belly of the omo-hyoid to reach the supra-scapular notch. The nerve to the serratus magnus, or nerve of Bell, is derived from the 5th. and 6th., and often also from the 7th. before they join, the formative branches uniting in the scalenus medius. A branch to the phrenic nerve is given by the 5th. at its upper part as also small branches to the longus colli and the scaleni which are given off from the nerves close to the foramina.. NOTE None, or very few of these nerves will be seen at this point in the dissection or in fact during the dissection of the arm, but it is deemed best to give the description of the plexus in full at this point. From the cords formed by the junction of nerves and branches of trunks as given above are given off the following nerves, from the outer cord, External anterior thoracic, a branch which unites with a branch from the inner cord to form the median and having given off these two the cord is continued as the external or musculo cutaneous. From the inner cord are given the internal anterior thoracic, internal cutaneous, lesser internal cutaneous, inner head of the median, and the cord then continues as the ulnar nerv. From the posterior cord are given off the three subscapular nerves, the circumflex and the cord continues as the musculo spiral nerve. The cords of the brachial plexus enter the axilla lying to the outer side of the artery at its first part, the posterior and inner cords then pass behind the second stage of the artery, the posterior remaining behind but the inner going to the inner side of the artery, it is from this new position that they get the names of inner, outer and posterior. In this position the cords give off their branches which in the third part of the artery more or less surround it. The division and reflection of the pectoral muscles will render the view of these relations much more clear.

THE DELTOID.--Origin, anterior border of outer half of the clavicle and adjacent portion of superior surface, tip and outer end of acromion, lower lip of spine of scapula. Insertion, a V-shaped surface on outer side of shaft of humerus, near the middle, embraced by the bifid origin of the brachialis anticus. Nerve, circumflex. A cellular interval separates the origins of Pect.maj. Serratus magnus, -- covers the side of the chest and forms, to a certain extent an internal boundary of the axilla. Origin, by eight digitations from the upper eight ribs, the first digitation being attached to the first and second ribs and to a fibrous arch extending over the intercostal space. Insertion, on the anterior aspect of the vertebral border of the scapula. Nerve, External respiratory of Bell (Long thoracic)

Upon division of the pectoral muscles the insertions of the pectoralis major, Teres major and Latissimus dorsi can all be seen in relation to the bicipital groove.

In order to see the parts about the scapula well one of two things must now be done, the clavicle divided internal to the origin of the deltoid and the arm with the scapula removed, or the body once more turned upon its back, in either case the following muscles will now be seen. Divide the deltoid near its origin and turn it down, a large bursa will be noticed lying between the muscle and the shoulder joint, Cut away the remains of the trapezius close to the spine of the scapula.

SUPRA-SPINATUS, -- Origin, ~~other~~ two-thirds of supra-spinous fossa, Insertion Upper facet on great tuberosity of humerus, Nerve, supra-scapular.

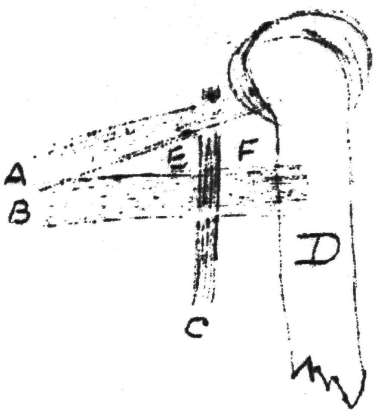

A Teres Minor.
B. " Major
C. Triceps
D Humerus
E Δ^{ar} space
F $\square^{ar}$ "

Triangular and Quadrangular Spaces.

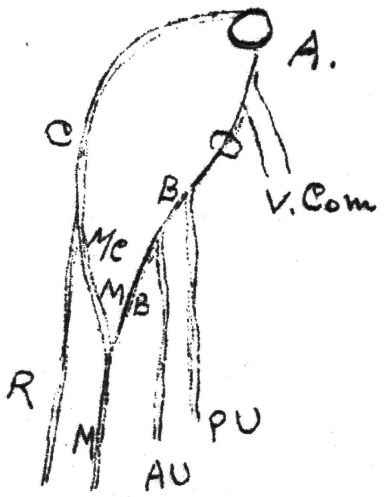

Veins of Arm.

INFRA-SPINATUS, -- Origin, inner two-thirds of infraspinous fossa (NOTE, in the description of the supra-spinatus on the preceding page the word "outer" occurs in relation to its origin, it should be "inner") from the fascia covering the muscle and the septum between it and the teres muscles. Insertion, middle facet on great tuberosity of humerus. Nerve, suprascapular.
TERES MINOR -- closely connected with the infra-spinatus. Origin, upper part of terest ~~erggin~~ area on dorsal aspect close to the axillary border, fascia covering it and septa between it and the infra-spinatus and teres major. Nerve special branch of circumflex, which has a perineural enlargment upon it.
TERES MAJOR, -- Origin, lower portion of the triangular teres area at the inferior angle of the scapula, intermuscular septa between it and the teres minor and infra-spinatus. Insertion, inner lip (or posterior) of the bicipital groove. Nerve, subscapular nerve.
In relation with some of these muscles two spaces are to be seen, one the QUADRILATERAL SPACE is bounded by the teres major, teres minor, humerus and long head of the triceps, the posterior circumflex vessels and the circumflex nerve pass through this space. If viewed from the front this space would have as its upper boundary the subscapularis instead of the terest minor. The TRIANGULAR SPACE lies internal to the long head of the triceps and has as its upper boundary the teres minor, as its lower the terest major. In this space is seen the dorsalis scapulae artery (dorsal branch of the subscapular) which does not pass through the space, as seen from behind, but winds beneath the teres minor in a groove on the axillary border of the scapula. It gives off a infra-scapular branch which runs on the venter under the subscapularis and otther branches which enter into a free anastomosis.
SUPRA-SCAPULAR ARTERY, branch of the thyroid axis, passes over the transverse ligament of the scapula, is distributed to the supra-spinous fossa and in part to the infra, also enters into anastomosis on the venter.
SUPRA-SCAPULAR NERVE. (gives a branch to the shoulder joint passes through the notch under the ligament and is distributed to the supra-and infra-spinatus muscles. The origin of the OMO-HYOID is also seen in close relation to the notch and ligament.
SUBSCAPULARIS, can only be seen in full if the arm has been removed. Origin, whole of the venter scapulae except the part to which the serratus magnus is attached and the small portion near the neck of the bone. Insertion, lesser tuberosity of the humerus and the bone below it for about an inch, also into the capsular ligament of the shoulder. Nerve, short subscapular. Now can be seen the SUBSCAPULAR NERVES, branches of the posterior cord of the brachial plexus. Long has been already seen in the axilla, going to the latissimus dorsi, the middle and short can now be seen, one going to the teres major, the other to the subscapularis. An incision is now made down the front of the arm to a point three inches below the bend of the elbow where it is joined by a transverse cut round the arm, the skin is then to be reflected for a couple of inches on either side of the first incision when the cutaneous vessels and nerves can be traced out. The veins of the arm are very variable, but the following is a common arrangment
VEINS OF THE ARM, are arranged in two sets, a deep set which run with the arteries as venae comites, and a superficial which run singly and independently. These two sets communicate by piercing veins of which the largest is just above the elbow and is called the Profunda vein. The superficial veins begin in great plexuses on the back and front of the hand, being specially marked over the little finger, Vena Salvatella. Four veins run up the forearm, the Radial,

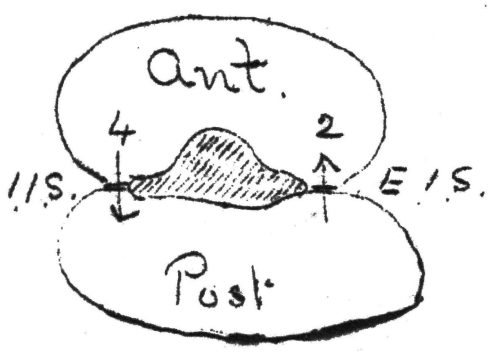

Intermuscular Septa of Arm.



A. Median N.
B. Artery
C Biceps.

Pron Rad. Teres

Supinator Longus.

Δ at Bend of Elbow

See p. 61

the median, and the anterior and posterior ulnar. The median bifurcates into the median cephalic and the median basilic, the latter unites with the anterior and posterior ulnar at a variable point and, piercing the deep fascia, is now called the ~~brachial~~ basilic, uniting with the venae comites of the brachial artery it continues as the axillary. The median cephalic unites with the radial and forms the cephalic which passes up the arm subcutaneously and is found near the shoulder lying in the cellular interval between the deltoid and pectoralis major in company with the humeral or descending branch of the acromio thoracic artery. It opens into the axillary or subclavian close to the outer border of the first rib.

BRANCHES OF AXILLARY ARTERY. These have already (page 3) been enumerated, but may now be described in brief detail. Superior Thoracic Artery, small branch supplying chest in region of first and second ribs, anastomoses with internal mammary and intercostals. Acromio-thoracic, a large branch arising behind pectoralis minor; on reaching upper border of muscle pierces the costo-coracoid membrane and divides into thoracic, acromial, humeral and clavicular branches, and these are distributed as indicated by their names. The Long thoracic runs along the lower border of the pectoralis minor to the side of the chest where it supplies the wall and the mamma. Anastomoses with the internal mammary, intercostals, acromio thoracic and subscapular arteries. Alar thoracic, a few small twigs distributed to the glands in the axilla. Subscapular, a large branch, runs along lower border of subscapularis with long subscapular nerve to chest wall anastomosing with intercostals, long thoracic and scapular arteries. An inch or less from its origin gives off dorsalis scapulae artery, already seen in the triangular space. Anterior circumflex a small branch winding round the neck of the humerus beneath the coraco brachialis and biceps, giving an ascending branch up the bicipital groove. Anastomoses with the posterior circumflex. The Posterior circumflex is larger than the anterior, winds behind neck of the humerus with the circumflex nerve, passing through the quadrilateral space. Supplies branches to the joint the greater tuberosity and the acromion. Anastomoses with the anterior circumflex, suprascapular and superior profunda.

The fascia lata of the brachium is very strong and divides the arm into two compartments; it is attached on either side to the lower half of the humerus where it forms the internal and external intermuscular septa. The external intermuscular septum is pierced by the musculo spiral nerve and the anterior division of the superior profunda artery, it gives attachment to four muscles, the triceps, brachialis anticus, supinator longus and the extensor carpi radialis longior. The internal intermuscular septum is pierced by the ulnar nerve, the nerve of Krause (a branch of the musculo spiral which supplies the inner head of the triceps) the inferior profunda artery and the posterior division or branch of the anastomotica magna artery. This septum gives attachment to three muscles, the brachialis anticus, the coraco brachialis and the triceps.

Coraco brachialis, is joined to the short head of the biceps. Origin, tip of the coracoid process with biceps but to its inner side, from the short head of the biceps, Insertion, inner side of shaft of humerus about its middle, opposite insertion of the deltoid and the internal intermuscular septum. Nerve, Musculocutaneous which pierces it and supplies it before doing so.

BICEPS.-- Arises by two heads, a long and a short, Origin, long head, from within the capsule of the shoulder joint from the top of the glenoid cavity and the glenoid ligament, the tendon traverses the joint enclosed in a tube of synovial membrane and enters the bicipital groove of the humerus. Short head, from the

tip of the coracoid process of the scapula, with, but to the outer side of the coraco brachialis. The two heads unite and form a large, fleshy belly, converge to a broad tendon inserted into the posterior surface of the bicipital tubercle of the radius. Above the elbow an expansion is given off which passes more superficially, covering the tendon, to be inserted into the fascia on the upper and inner part of the forearm. The tendon is twisted near its insertion so that the outer edge becomes anterior. Nerve, musculo cutaneous.

CUTANEOUS NERVES Internal cutaneous nerve, lies at first in front of or to the inner side of the artery, pierces deep fascia about middle of arm, runs in front of the elbow (inner condyle) supplies inner side of forearm, posterior branch supplies back. Lesser internal cutaneous (Nerve of Wrisberg) after joining with the intercosto-humeral nerve(lateral cutaneous branch of 2nd. intercostal) pierces fascia supplies lower third of upper arm on inner side. Not always present. Internal cutaneous branch of musculo spiral, appears on inner side of upper arm below teres major, supplies inner and back part of arm..

BRACHIALIS ANTICUS.-- Origin, front of lower half of shaft of humerus, both intermuscular septa, origin is bifid embracing the insertion of the deltoid. Insertion, rough impression on front of ulnar, just below coronoid process. Nerve musculo cutaneous and musculo spiral.

BRACHIAL ARTERY.--Extends from lower border of teres major to coronoid process of ulna (about half an inch below the bend of the elbow). It is superficial, but is overlapped by a well developed biceps, gradually turns from the inner side of the arm to the middle of the bend of the elbow. It is crossed by the median nerve and lies upon the musculo spiral nerve, the superior profunda artery, the triceps, the coraco brachialis and the brachialis anticus. To its outer side above are the median nerve with the coraco brachialis, afterwards the biceps. To its inner side is the ulnar nerve above, soon leaving it to pass through the internal intermuscular septum to the beak of the elbow, lower down the median nerve is in close relation. The basilic vein lies to its inner side side throughout. Venae comites surround the artery. All the branches from the outer side of the artery are muscular and are unnamed. Branches from inner side Superior profundacomes off from artery just below teres major, enters musculospiral groove, terminates by dividing into two branches which enter the anastomosis round the elbow, an anterior and a posterior, the former piercing the external intermuscular septum to reach the front of the elbow. Inferior profunda, passes with ulnar nerve through the internal intermuscular septum and enters anastomosis round elbow, behind the inner condyle. Nutrient, enters foramen about the middle of the inner side of the humerus. Superior radial collateral of Henle, small and inconstant, runs transversely outward a little above the middle of the arm and enters insertion of deltoid, anastomosing with the posterior circumflex. Anastomotica magna, arises an inch an a half above elbow, divides into two, an anterior which remains in front of elbow, and a posterior which pierces the internal intermuscular septum to enter anastomosis behind the internal condyle. The

ANASTOMOSIS ROUND THE ELBOW will be noted to be formed by eight arteries, four from above and four from below (from below we have the Anterior and posterior ulnar recurrent, the radial recurrent and the posterior interosseous recurrent) Of the eight arteries four are in front and four behind and all freely anastomose. Dissection for the brachial artery, Reflect Skin, superficial fascia with the cephalic and basilic veins and the external, internal and lesser internal cutaneous nerves, the deep fascia, including the bicipital fascia, and cut the

gedian nerve.

THE MEDIAN NERVE, arises by two heads, one from the inner cord the other from the outer cord of the brachial plexus; the two heads embrace the third part of the axillary artery and the formed nerve lies at first to the outer side of the brachial artery, about the middle of the upper arm it crosses the artery to lie at its inner side, where it will be found at the bend of the elbow under cover of the bicipital fascia. It enters the forearm between the two heads of the pronator radii teres, its furtner course and relations will be seen in the forearm and hand.

MUSCULO CUTANEOUS NERVE, the continuation of the outer cord of the plexus, takes a course downward and outward, it pierces the coraco brachialis, first supplying it, then runs between the biceps and brachialis anticus, just above the elbow it pierces the fascia lata and, having been crossed by the median cephalic vein becomes cutaneous to the outer side of the arm by two branches, an anterior and a posterior, the latter terminates above the wrist while the anterior terminates over the ball of the thumb, but sends one branch which piercing the deep fascia ends on the radial artery. The nerve supplies the coraco brachialis biceps and half of the brachialis anticus. The back of the upper arm must now be seen, the skin having been removed two external cutaneous branches of the musculo spiral nerve will be seen, the upper appears about the middle of the outer side of the arm, runs downward and forward to the upper part of the forearm, the lower appears close to the outer condyle , runs down back of the forearm to the wrist. (there is a third cutaneous nerve given from the musculo spiral, it is the internal, pierces the fascia near the tendon of the teres major supplies an area on the inner side of the arm behind the distribution of the intercosto-humeral nerve). Cutaneous branches also are found from the internal and lesser internal cutaneous nerves, as also filaments from the circumflex running down over the back of the arm and upward over the deltoid.

THE TRICEPS, arises by three heads, the long, inner and outer, the long is also called the middle. Origin, long head, from a triangular rough surface on the axillary border of the scapula just below the glenoid fossa; outer head, from immediately below the insertion of the teres minor and feom the outer side of the posterior aspect of the humerus, as far down as the musculo spiral groove, also from the external intermuscular septum, it forms a tendinous arch over the musculo spiral nerve; Inner head, from the whole of the posterior aspect of the humerus below the insertion of the teres major and the musculo spiral groove to within half an inch of the elbow joint on the inner side and extending back to condyle on the outer, fibres also arise from the external and internal intermuscular septa. The three heads unite and form a large muscular mass which terminates in a strong tendon, Insertion, posterior margin of the top of the olecranon process of the ulna and the deep fascia of the forearm, while a fasciculous is attached to the capsule of the elbow boint, forming the, so-called, subanconeus. Nerve, musculo spiral

THE MUSCULO SPIRAL NERVE, the continuation of the posteior cord of the brachial plexus, lies behind the axillary and brachial arteries as already seen, it enters the groove called by its name which lies between the inner and outer heads of origin of the triceps, in it it winds to the back of the arm and continues until it reaches the interval between the supinator longus and brachialis anticus at a point about an inch and a half above the elbow. It terminates by there dividing into the radial and posterior interosseous. Its branches may be divided into three sets, 1, before it enters the groove it gives off the internal cutan-

eous and the nerve of Krause, 2, while in the groove we have given off the external cutaneous and muscular branches to the triceps and anconeus, 3 after it has emerged from the groove muscular branches to the supinator longus, the extensor carpi radialis longior and half of the brachialis anticus.

THE NERVE OF KRAUSE, or ulnar collateral of Krause, is the branch to the inner head of the triceps, so called as it descends in close proximity to the ulnar and pierces the internal intermuscular septum with it.

TRIANGLE IN FRONT OF ELBOW At the bend of the elbow the median nerve and brachial artery lie in a triangular space, it is bounded above by an imaginary line drawn across the arm above the condyles, below the apex is formed by the junction of the pronator teres and the supinator longus, about two inches below the joint, the floor is formed by the lower part of the brachialis anticus and external to this may be seen the oblique fibres of the supinator brevis (sometimes) In this space in addition to the nerve and the artery is the tendon of the biceps, the three structures lying from within out as nerve, artery, tendon. The median nerve runs almost vertically through the space, the brachial artery usually terminates by dividing into the ulnar and radial upon the insertion of the brachialis anticus. By displacing outward the supinator longus the musculo spiral nerve is seen, but it is not a content of the space. AN incision now being made down the middle of the front of the forearm, another is made transversely across the front of the wrist, and the skin reflected inward and outw.rd.

CUTANEOUS VEINS AND NERVES OF FOREARM, the veins have been already (page 5) described. The nerves are as follows, internal cutaneous, sometimes forming a junction with the palmar cutaneous branch of the ulnar which may be found about three or four inches above the wrist, close to the radial edge of the flexor carpi ulnaris tendon and passes to the ulnar edge of the palm. The external cutaneous (or musculo cutaneous) is distributed as previously mentioned by an anterior and a posterior branch, while the palmar cutaneous branch of the median pierces the fascia in the center of the forearm about two inches above the wrist, communicating with the palmar cutaneous branch of the ulnar. The deep fascia of the forearm is continuous with the deep fascia of the upper arm and with the annular ligament below. It gives off intermuscular septa which pass in between the muscles and are attached to ridges on the radius and ulna giving origin to muscular fibres and forming sheaths for the muscles and tendons. The muscles arising from the internal condyle are five in number, four being flexors of the carpus and fingers while one is a pronator. From without inward they lie in the order in which they will be described. All have a common origin from the condyle, the fascia of the forearm, the intermuscular septa derived from it, but three of them, the pronator radii teres, the flexor sublimis digitorum and theflexor carpi ulnaris have additional bony attachments.

PRONATOR RADII TERES, OriginInternal condyle, coronoid of ulna, fascia and septa. Insertion, middle third of outer surface of radius. Nerve, median. Between the two bony origins of the muscle the median nerve passes into the forearm, while beneath both passes the ulnar artery to the ulnar side of the arm.

FLEXOR CARPI RADIALIS, Origin, internal condyle, fascia, septa, Insertion, (not seen at present) base of 2nd. metacarpal. Nerve, median. The tendon of this muscle pierces the substance of the anterior annular ligament and grooves the trapezium.

PALMARIS LONGUS, frequently absent, Origin, internal condyle, fascia, septa. Insertion, palmar fascia and annular ligament. Nerve, median. The function of the muscle is to make tense the palmar fascia and when absent this function is

taken by the flexors carpi ulnaris and radialis, which send aponeurotic expansions to join with the annular ligament. The palmaris longus has a small muscular belly and a long, thin tendon.

FLEXOR CARPI ULNARIS, Origin, internal condyle, fascia, septa and by an aponeurotic origin from the inner side of the olecranon and the upper two-thirds of the posterior ridge of the ulna with the profundus digitorum. Insertion, into the base of the 5th. metacarpal bone, after attachment to the pisiform bone, the annular ligament and by ligamentous bands to the unciform process of the unciform. Nerve, this is the only muscle on the front of the forearm which is supplied by the ulnar nerve. NOTE, the slip sent off to the annular ligament is constant and covers over the ulnar artery and nerve.

FLEXOR SUBLIMIS DIGITORUM , at its origin this muscle lies between the palmaris longus and the flexor carpi ulnaris. It is the only muscle of the forearm taking origin from the three bones. Origin, internal condyle, fascia, septa, from the internal lateral ligament, a tubercle on the inner side of the coronoid process of ulnar, the whole of the oblique line on the front of the radius and part of the external border of the radius.. Between its radial and ulnar origins the median nerve passes.. The muscle ends in four tendons, of which these for the 2nd. and 3rd. fingers lie anterior to those for the 1st. and 4th. Insertion, Both sides of the bases of the second phalagges, the tendons of the profundus passing between the split tendon. Nerve, median.

THE RADIAL ARTERY can now be seen in its course in the forearm. It is the smaller of the branches of bifurcation of the brachial and extends in the forearm from the bifurcation to the styloid process of the radius. It is superficial in this region, being only overlapped by the supinator longus, it lies between the supinator longus and pronator teres above and in the lower part of the forearm between the tendons of the supinator longus and the flexor carpi radialis. To its outer side is the radial nerve, close to it in its middle third, separated from it by about half and inch above and below.. The artery lies upon from above down, Tendon of the biceps, supinator brevis, pronator radii teres, flexor longus pollicis, flexor sublimis digitorum, pronator quadratus, and the lower end of the radius. It has two venae comites and gives off in the forearm four branghes, muscular, superficial volar arises near the root of the thumb and is of variable size. Runs forward and often beneath some of the fibres of the abductor pollicis to complete the superficial palmar arch formed by the ulnar artery. The anterior carpal is a small branch which runs across the wrist under the deep tendons to anastomose with a corresponding branch of the ulnar and twigs from the anterior interosseous and deep palmar arch. The radial recurrent runs out under the supinator longus and gives ascending and descending branmhes. Before dividing the flexor sublimis and other muscles arising from the inner condyle it is well to note that the ulnarartery lies between the flexor carpi ulnaris and the innermost tendon of the sublimis in the lower half of the forearm by separating the tendons the nerve will be noted lying to its ulnar side. In order to see the origin of the sublimis in detail the pronator radii teres, the palmaris longus and the flexor carpi radialis can now be divided, then divide the flexor sublimis near its origin and turn it down without injuring the median nerve, then will be seen the deep muscles of the forearm, the ulnar artery, the median nehye ,

FLEXOR LONGUS POLLICIS, Origin, whole of the anterior surface of the radius between the oblique line and the orgin of the pronator quadratus, the outer half of the whole length of the interosseous membrane; it often has a small addition-



Nerve Supply of Forearm.

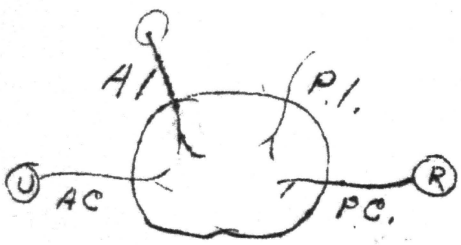

Post. Carpal
Anastomosis

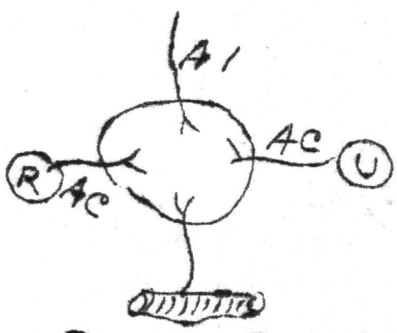

Deep Palmar
arch.

Ant. Carpal
Anastomosis

origin by a slip of variable size from the inner side of the coronoid process. Insertion, terminal phalanx of thumb, passing between the two heads of the flexor brevis pollicis. Nerve, anterior interosseous.

FLEXOR PROFUNDUS DIGITORUM, Origin, from two surfaces of the ulna, the anterior from the insertion of the brachialis anticus which it egbraces to the pronator quadratus, and the inner,(upper two thirds), also from the adjacent half of the interosseous membrane and from f.sciae and septa. Insertion, by four tendons which pass through the tendons of the flexor sublimis, into the terminal phalanges of the fingers.. The tendons give orgin to the lumbricales as will be seen in the palm. Nerve, anterior interosseous.

PRONATOR QUADRATUS arises from the anterior and inner surfaces of the ulna in its lower fourth, Insertion, whole of the front of the radius below the attachment of the flexor longus pollicis, also into the external border of the bone. Nerve, anterior interosseous. It will be noticed that all the superficial muscles on the front of the forearm are supplied by the median with the exception of the flexor carpi ulnaris, while the three deep muscles are supplied by the anterior interosseous branch of the median.

MEDIAN NERVE IN THE FOREARM. after passing between the two heads of the pronator radii teres and between the radial and ulnar origins of the flexor sublimis digitorum the nerve crosses the ulnar artery to lie between the flexor sublimis digitorum and the profundus. Near the wrist it lies superficially between the tendons of the flexor carpi radialis and the sublimis and passes under the annular ligament into the hand.. Branches, of supply to muscles as stated in the preceding paragraph, a cutaneous palmar branch arises a short distance above the annular ligament over which it passes to be distributed to the skin of the palm.

ULNAR ARTERY, the larger of the two branches of bifurcation of the brachial extends from the lower border of the coronoid process to the lower border of the anterior annular ligament where it divides into two branches, superficial and deep.. It at first takes an oblique course inward under the median nerve (separated from it by the deep origin of the pronator radii teres) and four of the muscles from the inner condyle, (all but the flexor carpi ulnaris). It lies at first on the insertion of the brachialis anticus, then upon the flexor profundus digitorum being there bound down by a process of deep fascia, is joined in the middle of the forearm by the ulnar nerve where it reaches the border of the flexor carpi ulnaris, which lies to its inner side for the rest of its course. In the lower third both artery and nerve lie comparatively superficially between the tendons of the carpi ulnaris and the sublimis and both rest on the profundus till they reach the annular ligament over which they pass into the palm, being covered by an expansion from the tendon of the flexor carpi ulnaris. BranchesAnterior ulnar recurrent (found between the brachialis anticus and pronator teres) Posterior ulnar recurrent (found running beneaththe sublimis and carpi ulnaris to the back of the internal condyle where it runs in the groove with the ulnar nerve) Interosseous artery, a short trunk arising about an inch from the commencement of the artery, subdivides in the interosseous space into the anterior and posterior interosseous. The anterior runs on the interosseous membrane with a branch of the median nerve between the flexor profundus digitorum and the longus pollicis, disappears under the pronator quadratus and goes to wrist joint, sometimes gives off a large branch accompanying the median nerve, gives nutrient arteries to the radius and ulna and a communicating branch to the anterior carpal arch. The anterior carpal artery

runs beneath the finger tendons near the lower border of the pronator quadratus anastomosing with the ant. carpal from the radial, branches from ant-interosseous and recurrent branches from the deep palmar arch; the posterior carpal runs to the back of the wrist, will be seen later.

THE ULNAR NERVE IN THE FOREARM, the nerve enters the forearm behind the internal condyle, by passing between the heads of the flexor carpi ulnaris. It lies under cover of that muscle and upon the profundus digitorum through all its course in the forearm, about the middle third of the forearm comes in close relation with the artery and, keeping to its ulnar side, passes with it over the annular ligament. Branches, supplies flexor carpi ulnaris and the inner half of the flexor profundus digitorum, gives small articular bbaanchhes to the elbow, and in the lower third of the forearm gives off a dorsal branch which turns backward beneath the tendon of the flexor carpi ulnaris to be distributed to the back of the little and half of the ring finger as far as the middle of their second phalanges. A cutaneous palmar branch arises below the middle of the forearm and becomes cutaoeous close above the annular ligament, distributed to the skin on the ulnar side of the plam.

THE RADIAL NERVE, was seen to arise from the musculo spiral near the elbow, lies at first upon the supinator brevis, separated from the artery above, passes down the arm lying under cover of the supinator longus, lies close to the outer side of the artery in its middle third, then leaves it to pass outward un- the tendon of the supinator longus to pass to the back of the forearm. Dissection to expose the radial nerve, Reflect, skin, superficial fascia with radial vein and cutaneous branches of the musculo spiral .nd mssculo cutaneous nerves, the deep fascia, , the supinator longus.

Two somewhat out-of-the-way dissections are sometimes asked for in the forearm, first, to find the radial recurrent artery,, to find it separate the supinator longus from the brachialis anticus, while, second, to find the anterior ulnar recurrent it is necessary to separate the pronator radii teres from the brachialis anticus. The front of the forearm being now completed the skin is removed from the back without any further incision than one along the inner side of the hand and one transverse to it across the back of the knuckles, an incision is then made up the back of the thumb and each of the fingers in the middle line and the skin reflected.

CUTANEOUS NERVES ON BACK OF THE FOREARM. In the middle by branches of the musculo spiral nerve, outer side by branches from musculo cutaneous nerve, Inner side by branches from the internal cutaneous nerve. At the wrist on the outer side the large radial nerve pierces the deep fascia and after communicating with the musculo cutaneous distributes digital branches to the back of the thumb and two and a half fingers(on the radial side) , the distribution usually extending as far as the middle of the second phalanges.

SUPERFICIAL VEINS originate in an irregular arch fro m which arise the radial and posterior ulnar veins, these wind round to join the veins on the front of the forearm and one or two branches form communications across the back of the forearm from one side to the other. . The deep fascia is now to be removed but a band one inch broad left at the lower end to represent the posterior annular ligament The muscles of the forearm (posteriorly) are found in the following order, the order of description, first will be considered those arising from and above the external condyle, they are extensors and supinators, the first from the radial side is the

SUPINATOR LONGUS, has been already seen in great part. Origin Upper two thirds

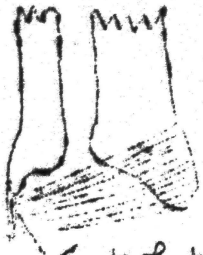

Post Annular Ligament

Ant. Lateral Ligaments

(See page 18)

Second Phalanx

First Phalanx

Metacarpo Phalangeal Joint

Insertion of Common Extensor.



Palmar Fascia

(See page 15)

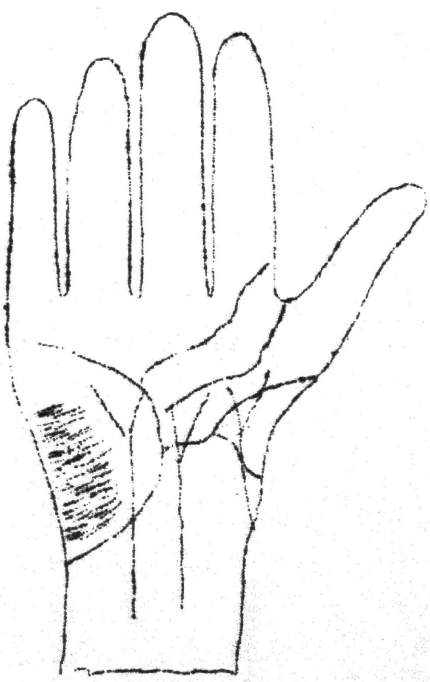

Superficial Palmer Structures - Page 16

of external supra-condyloid ridge of the humerus, external intermuscular septum, Insertion, outer surface of lower end of the radius at the bottom of the grooves for the extensores ossis and primi internodii pollicis. Its tendon is crossed by the two short extensors of the thumb at the annular ligament and the radial nerve passes under it to reach the back of the wrist. Nerve, special branch of the musculo spiral.

EXTENSOR CARPI RADIALIS LONGIOR, Origin, lower third of the external supra-condyloid ridge of the humerus, external intermuscular septum; tendon passes beneath extensors of the metacarpal bone and through 2nd. division of the annular ligament, is then crossed by the third extensor of the thumb and INsertion is into the base of the 2nd. metacarpal bone. Nerve, musculo spiral. NOTE. The muscles of the forearm may be divided into four groups according to their nerve supply, Anterior superficial, Anterior deep, Posterior and External, in such a division the Anconeus must be left out of consideration and treated as a close connection, if not actually a part of, the Triceps. The superficial anterior muscles are supplied by the median, the deep by the anterior interosseous branch of the median, the external group, (the two muscles just described are supplied by the musculo spiral, while all the posterior muscles are supplied by the posterior interosseous.

EXTENSOR CARPI RADIALIS BREVIOR. Is partly covered by the longior. Origin, outer condyle, fascia and septum between it and the next muscle. Tendon passes with long extensor to be Inserted, into base of the 2rd. metacarpal.

EXTENSOR COMMUNIS DIGITORUM, Origin, external condyle, fascia, septa on either side. Ends in three tendons which pass through the 4th. division of the annular ligament with the extensor indicis, the innermost then subdivides and the four tendons are thus Inserted, opposite the metacarpo-phalangeal joint each tendon receives slips on both sides from the interossei, it expands upon the phalanx and is joined on the radial side by the tendon of the lumbricalis, its lateral portions arethen continued upon the third phalanx whilst the middle portion terminates upon the second. The tendon to the ring finger is attached by slips to a greater or less extent to the tendons on either side, and the tendon to the index finger is joined by the tendon of the extensor indicis.

EXTENSOR MINIMI DIGITI Origin, external condyle, fascia and septa on either side, tendon passes through 5th. division of the annular ligament in the groove between the radius and ulna then generally divides and the two slips are inserted into the common expansion on the first phalanx.

EXTENSOR CARPI ULNARIS. Origin, back of the external condyle, fascia and septa, also from an expansion attached to the outer side of the posterior border of the ulna. Tendon passes through 6th. division in the annular ligament in a groove behind the styloid process of the ulna, Insertion, base of 5th. metacarpal. NOTE, all the flexors and extensors of the carpus are inserted directly or indirectly into the metacarpal bones. The radial extensors are abducturs and the ulnar extensor an adductor at the radio-carpal articulation.

ANCONEUS, a small triangular muscle on the back of the elbow, lying under cover of the fascia of the triceps, closely related to that muscle. Origin, External condyle of the humerus, posteriorly, Insertion, (fleshy) triangular surface on outer side of olecranon and posterior surface of the ulna above the superior oblique line. Is an extensor of the forearm .Nerve, musculo spiral. The Posterior interosseous recurrent artery can be seen on division of this muscle

SUPINATOR BREVIS Origin, external condyle, external lateral ligament of elbow,

(mainly from the ligament), back of the orbicular ligament, triangle of ulna below the lesser sigmoid cavity. Its fasciculi sweep spirally round the radius and Insertion is into the upper third of the radius, anteriorly, externally and posteriorly. The muscle is pierced by the posterior interosseous nerve which supplies it In order to see this last muscle it has been necessary to reflect the long extensors, but the supinator longus lies so far to the outer side of the arm that it has not been necessary to interfere with it.

EXTENSOR OSSIS METACARPI POLLICIS, Origin, posterior surface radius and ulna, on radius for about two inches , and the same distance on the ulna, on the latter bone extending from the attachments of the supinator brevis and the anconeus above to the extensor secundi below, on the radius the origin extends from the interosseous line to the attachments of the supinator brevis and the pronator radii teres. Insertion, base of 1st. metacarpal, sometimes sending a slip to the trapezium and the short muscles of the thumb. Tendon crosses obliquely the extensor carpi radialis longior and brevior, passes through the first divesion of the annular ligament and crosses radial artery.

EXTENSOR PRIMI INTERNODII POLLICIS, (Extensor brevis)Origin, posterior surface of radius immediately below extensor ossis for a space two inches long, half an inch wide, interrosseous memrane, radial half, for a like distance. Insertion, base of first phalanx of thumb. Tendon lies to the ulnar side of the ossis, passes through same opening in the annular ligament.

EXTENSOR SECUNDI INTERNODII POLLICIS (Extensor longus) Origin, middle of outer half of posterior surface of the ulna, between ossis above and indicis below and from the ulnar half of the interosseous membrane. Tendon becomes superficial just above the annular ligament, it passes through the third division in the ligament, ver: obliquely, Insertion, base of the terminal phalanx of the thumb, after crossing the long and short radial extensors and the radial artery Its tendon receives fibrous processes like those given to the finger extensors by the interossei from the abductor pollicis and the adductor obliquus...

EXTENSOR INDICIS, posterior surface of ulna below preceding muscle, slightly from the interrosseous membrane. Tendon passes through 4th. opening in the annular ligament with the common extensor, joins ulnar side of the tendon to the first finger. All supplied by the posterior interosseous nerve.

POSTERIOR INTEROSSEOUS ARTERY, is small, passes to the back of the forearm by crossing between the oblique ligament and the interosseous membrane. It appears between the supinator brevis and the ossis metacarpi pollicis, lies on the interosseous membrane close to the extensor carpi ulnaris, terminates by anastomosing with the terminal branches of the anterior interosseous which pierce the interosseous membrane to reach the back of the arm and with the carpal anastomosis generally.

POSTERIOR INTEROSSEOUS NERVE, , is given off above the elbow, passes to the back of the forearm by winding round the neck of the radius in the substance of the supinator brevis. It then runs down between the superficial and deep muscles until in the lower third it lies upon the interosseous membrane and back of the wrist joint, ending in a pseudo-gangliform enlargement at the back of the wrist. It supplies all the muscles on the posterior surface of the forearm, both superficial and deep.

DISSECTION FOR THE POSTERIOR INTEROSSEOUS NERVE, Reflect the skin by a double dodr flap incision, superficial fascia with branches of the internal, external cutaneous and musculo spiral nerves, also the posterior ulnar vein. Reflect the deep fascia, together with the posterior annular ligament, all 4

superficial extensors, the extensor carpi radialis longior, pull aside the extensor secundi and supinator longus, and the nerve will be found in the substance of the sppinator brevis

Dissection for the posterior ulnar recurrent artery, reflect the condyloid head of the flexor carpi ulnaris.

RADIAL ARTERY AT THE WRIST- This constitutes the second part of the radial artery, and extends from the styloid process of the radius to the base of the first interosseous space where the artery enters among the muscles of the thumb, the third part. This second stage of the artery lies against the external lateral ligament of the wrist joint and beneath the extensor tendons of the thumb. It winds over the back of the carpus to the interval between the metacarpals of the thumb and index, where it is crossed by the extensor of the second phalanx of the thumb, lastly, it passes between the two heads of the first dorsal interosseous muscle. The branches of this portion of the artery as follows, Posterior carpal, a small branch running transversely on under the tendons to join the posterior carpal branch of the ulnar and form an arch, giving off two dorsal interosseous branches which bifurcate at the webs of the fingers to form the dorsal digital arteries. (running to do so on the 3rd. and 4th. dorsal interossei). Metacarpal branches the first dorsal interosseous branch, runs on the second dorsal interosseous muscle. The dorsales pollicis are two small arteries distributed on the metacarpal bone of the thumb, the dorsalis indicis a similar branch which runs on the radial side of the metacarpal bone of the index finger. This is frequently replaced by a large branch which runs along the metacarpal and divides into branches to the fore-finger and thumb, being in such case the radialis indicis, a branch of the 3rd. part of the artery, arising earlier than usual.

POSTERIOR CARPAL BRANCH OF THE ULNAR ARTERy will be found appearing under the extensor carpi ulnaris, it completes the arch with the posterior carpal branch of the radial, ends in a branch to the ulnar side of the 5th. metacarpal.

POSTERIOR ANNULAR LIGAMENT is a thickened portion of the deep fascia of the back of the forearm and hand, it is attached to the ridges of the radius externally and posteriorly and to the cuneiform and pisiform bones internally, as also to the internal lateral ligament This ligament has six sub-divisions, each transmitting tendons, and these correspond to the grooves on the radius and ulna, or between them. The first division transmits the tendons of the extensor ossis and primi, the second transmits the tendons of the extensores carpi radialis longior and brevior, the third transmits the extensor secundi, the fourth has the extensor communis and the extensor indicis, the fifth has the extensor minimi digiti while the sixth transmits the extensor carpi ulnaris.. The dorsal interossei will be considered with the palmar. We now have to examine the PALM OF THE HAND. The skin of the palm is peculiar on account of, thickness absence of hair, many sweat glands present but no sebaceous g,ands, it has a large number of nerves ending in it and is consequently very sensitive. The superficial fascia of the palm contains the Palmaris brevis, a plexus of veins, and palmar branches of the median, and ulnar nerves as also terminal branches of the musculo cutaneous.

THE PALMAR FASCIA is the deep fascia which is strengthened for purposes of grasping and to maintain the breadth of the hand by preventing in the action of grasping the hand being increased in breedth and so weakened. This fascia is the remains of the expansion of the palmaris longus in the lower animals. It is divided into three parts, a central which is strong and a thenar and hypo-

Cutaneous Nerves of Hand (Palmar)
ant. Ann. Lig:

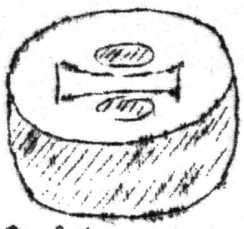

Relation of Tendon sheath

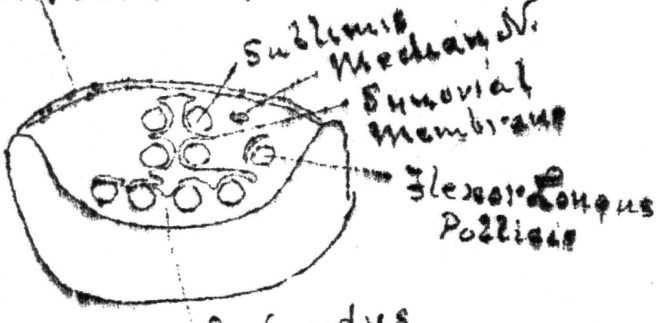

Structures passing Under Ant. Ann. Lig:

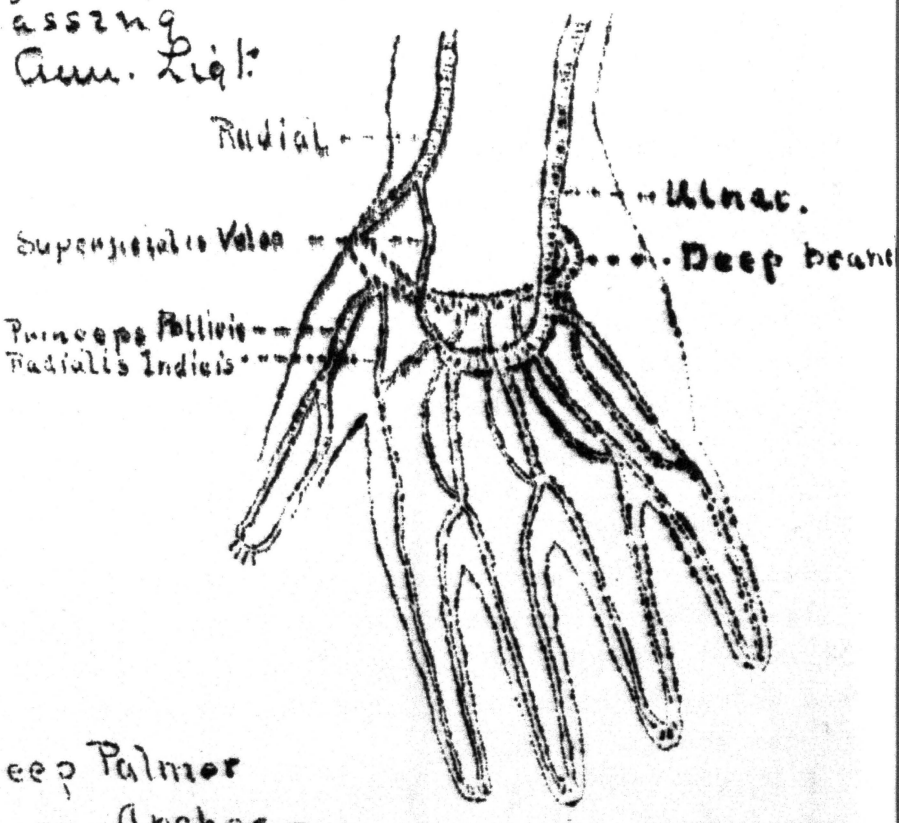

Superficial & Deep Palmer Arches -

thenar which are weak. The central portion is triangular and is posteriorly attached to the palmaris longus as also the anterior annular ligament, its base is divided into four slips, one for each finger, connected by deep transverse fibres, when traced to the end of the finger each of these slips divides into three, the central one forming the tendon sheath and the lateral ones are bound down to the transverse metacarpal ligament.

THE PALMARIS BREVIS. Origin, inner edege of the central palmar fascia, crosses the ulnar artery and nerve, inserted into the skin on the inner side of the hand. Nerve, ulnar. This muscle is a developmental, or rather evolutionary remnant.

THE SUPERFICIAL PALMAR ARCH. is formed by three arteries superficial ulnar, superficialis volae and a branch of the radialis indicis (sometimes only the first two or the first and third). To expose the arch you must reflect the skin superficial structures contained in the superficial fascia with the fascia, and the palmaris brevis. This arch is subject to great variations, if regglar it forms an arch with the convexity forw.rd about midway between the anterior annular ligament and the root of the middle finger. . From its convexity are given off four digital arteries, three of which divide at the webs of the fingers the other running to the ulnar side of the little finger. Traced along the fingers these are found to supply the cutaneous structures, sheaths of the tendons and the joints and send twigs to anastomose with the dorsal arteries, also supply the pulp of the finger and form a plexus under the nail.. They are accompanied by the nerves, but while the nerves lie deeper than the arteries in the palm they are mor anteriorin the fingers. The pulp of the finger is a pad of fat in front of the last phalanx it contains an anastomosis of arteries and one of veins, a plexus of nerves with touch corpuscles and some lyphatics.

NERVES OF THE PALM. The median and superficial ulnar.

TENDON SHEATHS IN THE FINGERS, a tendon sheath is a fibro osseous tunnel the floor is formed by the phalanges and the anterior ligaments, the roof by the tendon sheath proper. It extends from the middle of the last phalanx into the palm for one inch, and exists to prevent "bow-stringing" of the tendon. The stronger part of the sheath lies over the bones (ligamentum vaginale) over the joints the sheath is thin and the fibres are arranged like an X. The sheath contains two tendons, a synovial membrane and bands called vincula vasculosa each containing an artery surrounded by a synovial membrane and existing for the nourishment of the tendons.

ANTERIOR ANNULAR LIGAMENT is about one inch broad, is attached to the scaphoid and the trapezium on the one side and to the pisiform and unciform on the other. It forms a bridge and under it pass the superficial and deep flexor tendons and the tendon of the longus pollicis, as also the median nerve. There are 7 synovial membranes in the hand, two lie under the annular ligament, the others are one for each finger.

THE LUMBRICALES .re four in number and have their Origin from the flexor profundus tendons, the two on the radial side have oregin from one tendon (sometimes only the first) the two on the ulnar side from two tendons, they wind round the radial side of the fingers and are inserted into the expansion on the posterior surface of the base of the first phalanges. They flex the metacarpophalangeal joint while they extend the inter-phalangeal joint. The first two on the radial side are supplied by the median, the two on the ulnar side by the ulnar nerve.

THE MEDIAN NERVE IN THE HAND, the nerve is flattened as it passes under the annular ligament superficially to the tendons and divides into two trunks which subdivide to form four digital nerves to supply the thumb and two and a half fingers . The first, or outermost, after giving a small branch to supply the abductor, opponens and outer head of the flexor brevis pollicis bifurcates to supply both sides of the anterior aspect of the thumb, the second supplies the radial side of the index after giving a branch to the first lumbrical, the 3rd. after supplying the second lumbrical bifurcates to supply the contiguous sides of the index and middle fingers, while the fourth ifurcates to supply corresponding sides ofhh second and ring fingers. The digital branches are distributed to the pulp on the palmar side of the digits, and to the distal half of the dorsal integument.

ULNAR NERVE IN THE HAND. accompanying the ulnar artery over the annular ligament and under cover of the expansion from the flexor carpi ulnaris, the ulnar nerve at once divides into a superficial and a deep portion. The deep division accompanies the deep branch of the ulnar artery and supplies the muscles of the little finger around the ulnar side of the root of the unciform process between the flexor brevis and the abductor minimi digiti. It then forms an arch across the bases of the metacarpal bones accompanying the deep palmar arch and supplies the inner two lumbricales, the seven interossei, the oblique and transverse adductors of the thumb and the deep head of the flexor brevis pollicis. The superficial division sends a small twig to the palmaris brevis and to the integument on the i mer side of the palm and subdivides into two branches which supply the remaining finger and a half, in exactly the same manner as the median did the others.

THE TENDONS OF THE FLEXOR SUBLIMIS DIGITORUM, four in number, can be well seen on reflection of the superficial arch and the median nerve while the TENDONS OF THE FLEXOR PROFUNDUS lie beneath the corresponding sublimis tendons and show the attachment of the lumbricales to them. The tendon of the flexor longus pollicis is on the same level as the profundus tendons and can be traced between the sesamoid bones and the two heads of the flexor brevis to the insertion in the base of the terminal phalanx of the thumb.

ABDUCTOR MINIMI DIGITI, Origin, pisiform and annular ligament, as also the tendon of the flexor carpi ulnaris, Insertion, ulnar side of base of first phalanx of little finger.. Is bridge-like.

FLEXOR BREVIS MINIMI DIGITI, Uncifrom process of unciform and annular ligament is often closely connected to the Abductor, but the passage of the deep branch of the ulnar artery and nerve marks them off, Insertion, ulnar side of base of first phalanx with the abductor.

OPPONENS MINIMI DIGITI, deepest, Origin, same as preceding muscle, Insertion, inner margin of shaft of the 5th. metacarpal. These three muscles are supplied by the deepbranch of the ulnar nerve.. The opponens is somewhat triangular.

ABDUCTOR POLLICIS, , is a slender muscle and the most superficial. Origin, annular ligament and the ridgg on the trapezium as also the tubercle on the scaphoid, Insertion, radial side of base of first phalanx. This muscle is bridgelike.

OPPONENS POLLICIS, Origin, same as last, Insertion, outer border of shaft of the metacarpal bone of the thumb. These two muscles are supplied by the median.

FLEXOR BREVIS POLLICIS, consists at insertion of two portions between which the tendon of the long flexor is placed.Outer head .rises from thelower part of the annular ligament inserted with the abductor, has a sesamoid bone in the tendon.

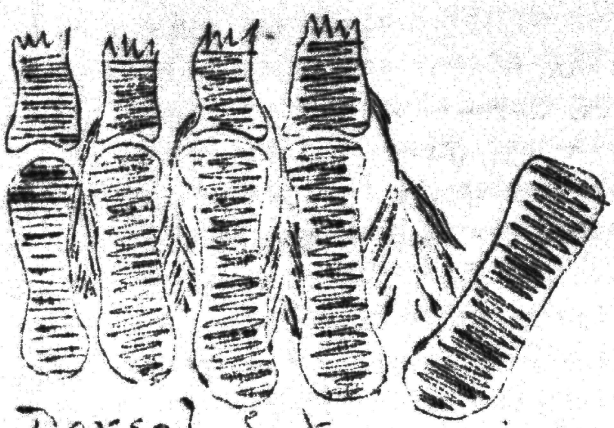

Dorsal Interossei

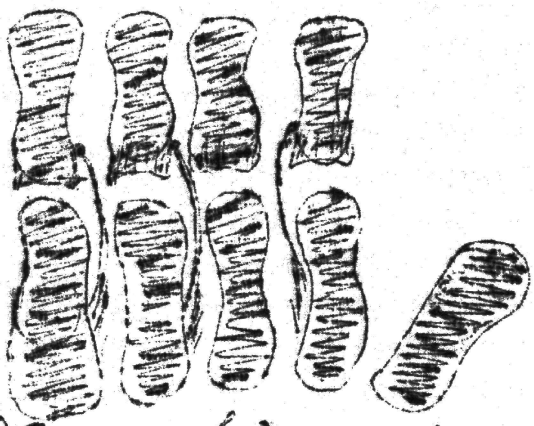

Palmar Interossei



Suture

Synchondrosis

Symphysis

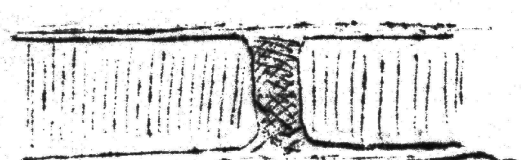

Amphiarthrosis

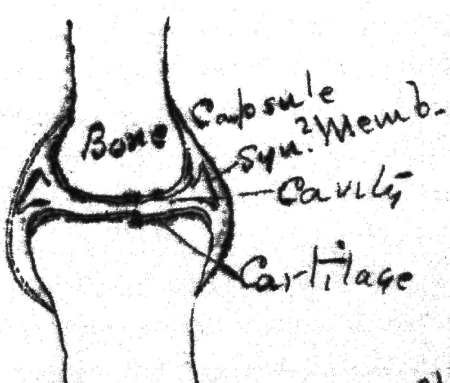

See page 19.



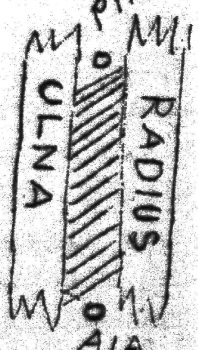

See page 20.

Inner head is very small, Origin, ulnar side of base of the first metacarpal bone, inserted with the adductor obliquus. Nerves, inner head, ulnar, outer head median.

ADDUCTOR OBLIQUUS POLLICIS, origin, bases of the second and third metacarpals sheath of flexor radialis and os magnum, Insertion, with deep head of the flexor brevis and the adductor transversus into inner side of the base of the first phalanx of the thumb, sesamoid bone in its tendon where it plays over the head of the metacarpal. Nerve, Ulnar. The deep palmar arch is buried in its fibers of origin and emerges between it and the adductor tranrversus.

ADDUCTOR TRANSVERSUS POLLICIS Origin, anterior surface of the lower two-thirds of the shaft of the middle metacarpal bone, insertion, base of first phalanx of the thumb and tendon of the extensor secundi, the muscle forming a triangle with its base to the ulnar side. Covers the muscles in the first and second interosseous spaces. Nerve, Ulnar.

DEEP BRANCH OF THE ULNAR NERVE is seen to arise from the ulnar trunk near the pisiform bone and to pass with the deep vessels round the ulnar side of the root of the unciform process and between the flexor brevis and adductor minimi digiti. It then forms an arch across the bases of the metacarpal bones accompanying the deep palmar arch and supplies the two inner lumbricales, the seven interossei, the two adductors and the flexor brevis of the thumb.

DEEP PALMAR ARCH, the termination of the radial artery, commences immediately after the artery has passed between the two heads of the first dorsal interosseous muscles. The deep arch has a convexity toward the fingers and is situated at the junction of the bases with the shafts of the metacarpal bones. It is completed by the anastomosis of the artery with the deep branch of the ulnar. Its branches are the princeps pollicis, large branch, passes toward the metacarpal of the thumb and then bifurcates to suppl: both sides of the thumb. Radialis indicis, supplies radial side of first finger receives a communicating branch from the superficial arch, anastomoses at the tip with the digital from the superficial arch. Small recurrent branches to the carpus, anastomosing with the branches of the anterior carpal arch. Perforating branches to the dorsum, pass between the heads of the three inner dorsal interossei to join the dorsal digital branches. Interosseous branches run on the palmar interossei to the roots of the fingers anastomose with the digital branches of the superficial arch at their bifurcation, supply the interossei.

INTEROSSEOUS MUSCLES. Seven in number, three palmar, four dorsal. The three palmar are placed in the interosseous spaces between the metacarpals of the fingers, are called 1st., 2nd. and third from the radial side. They are so arranged as to adduct to an imaginary line drawn through the middle of the second finger, the 1st. arise from the ulnar side of the metacarpal of the first finger and is inserted into the ulnar side of the first phalanx of the same finger, the 2nd. arises from the radial side of the 4th. metacarpal and is inserted into the radial side of the first phalanx of that finger while the 3rd. acts in a precisely similar manner with the 5th. metacarpal. Each muscle also sends an expansion to the adjacent side of the corresponding extensor tendon. The Dorsal interossei are bipenniform muscles, they are arnged so as to abduct from the same imaginary line as the palmars adduct to. Each arises from two bones and the insertions are as follows, the first and second, from the radial side, into the radial side of the base of the first phalanges of the first and second fingers, the 3rd. and 4th. into the ulnar side of the first phalanges of the second and ring fingers. Their in-

sertion into the base of the first phalanx enables the interossei to act as flexors of that phalanx and to give lateral movement to the fingers to which they are attached. The slip sent forward to the extensor tendons enables them to act as extensors of the second and third phalanges. All the interossei are supplied by the ulnar nerve.

TABLE OF JOINTS.

1 SYNARTHROSIS, (A) Suture, (B) Synchondrosis, (C) Gomphosis.
2 ANARTHROSIS.
3 DIARTHROSIS, (A) Enarthrosis, (B) Ginglymus, (C) Condyloid, (D) Arthrosis (E) Pivot.
(PSEUDARTHOSIS) Enarthroid, Ginglymoid.

Definition of a joint. The junction of two or more bones which never touch but are always separated. Note, They may be separated by membrane as in sutures, by hyaline cartilage as in synchondroses, by fibro-cartilage as in Amphiarthroses or by a cavity as in Diarthroses.

1 A synarthrosis is a joint with no movement, (A) Suture, as in the skull. (B) Synchondrosis, where we have two bones united by a bar of hyaline cartilage as in the first chindro-sternal joint. In the child the occipito sphenoid joint is a synchondrosis. (C) Gomphosis, a tooth fitting in a socket.

2 Amphiarthroses, joints which singly have almost no movement but a series of which have much movement, as in the case of the interverbebral joints by discs. The three classes of Group 1 are prone to ossify, those of Group 2 never do.

3 Diarthroses are freely moveable joints and have five essentials. Bone, its covering of hyaline cartilage, a caprule in which the stronger bands are called ligaments, a cavity and a synovial membrane which secretes a fluid.. A synovial membrane is not a sac but a wide shallow tube with no roof and no floor in every joint it merely lines the capsule and is never found lying over the cartilages. Just where it joins the cartilage we always have a fringe and in inflammations of joints this is always the first to be affected. Joints with no capsule, as in the superior radeo-ulnar, are those which freely communicate with other joints. (A) Enarthroses have seven movements (as in the shoulder) flexion, extension, abduction, adduction, external and internal rotation and circumduction. (B) Ginglymus move in two directions (as in the elbow) flexion and extension. (C) Condyloid, have three movements, (as in the knee) flexion, exteosion and rotation. (D) An arthrosis is a gliding joint and of (E) the pivot joint, we have an example in the atlo-axoid joint.

JOINTS OF THE ARM. STERNO-CLAVICULAR JOINT, a gliding joint, the ligaments of this joint are a capsule, anterior, posterior, interclavicular ligaments and the rhomboid ligament as also a meniscus which is attached to the sternum and costal cartilages below and to the clavicle above, it tends to prevent upward dislocation of the clavicle. Movements of the joint, upward, by the sterno-mastoid and trapezius, Downward by the weight, etc. Forward by the pectorale, Backward by the trapezius, rhomboids and latissimus dorsi. (NOTE, in the case of movement of joints the MAIN mausoles are mentioned, avoiding detail. ACROMIO-CLAVICULAR JOINT. Ligaments, capsule, superior, inferior and a meniscus. This is a weak joint and would be much weaker were it not for the conoid and trapezoid ligaments. Movements, Upward, and downward. SHOULDER JOINT. Here we have a socket, the glenoid fossa which is deepened by fibro-cartilage. The capsule is strong and lax and its weakest point is below. We also have the coraco humeral band. There are three openings into the cav-

ity of the joint, one for the long tendon of the biceps, the other two communicate with the subscapular bursa and the infraspinous bursa. The cervical ligament of Stanley is the homologue of the ligamentum reflexum of the hip. The shoulder has, but rarely, a ligament corresponding to the ligamentum teres in the hip and when it is present it is called the gleno-humeral ligament. The capsule is strengthened by the humeral muscles of the tuberosity being inserted into it. Nerves of the shoulder joint, the supra. and subscapular and the circumflex. Arteries of the joint, the supra.and subscapular, the circumflex and the acromio-thoracic. The muscles which produce the seven movements of the joint are as follows, Abduction by the deltoid, supraspinatus. Adduction, by the weight of the limb, pectoralis major, latissimus dorsi and the teres major. Flexion by the biceps, deltoid, coraco-brachialis.. Extension(is limited because the scapula gets locked) deltoid latissimus dorsi and Rotation external, teres minor, internal, pectoralis major, latissimus dorsi and teres major. Circumduction, all the muscles.

ELBOW JOINT is a ginglymus, slightly modified, and the movements are Flexion and Extension.. Bones of the joint are Humerus, (capitellum and trochlea) Radius, (cup) and Ulna, (greater sigmoid cavity.) In marking the capsule on the humerus we include the three fossae and exclude the condyles. Ligaments of the joint are Capsule, Anterior, weak, Posterior, weak, Internal, triangular and strong, External, a rounded cord which stretches from the external condyle to the orbicular ligament. Nerves of the joint, Ulnar, musculo-cutaneous and musculo spiral. Arteries of the joint are supplied by the brachial, radial and ulnar, all in a great anastomosis. The muscles which produce the movements of the joint are Flexion by the biceps, brachialis anticus, supinator longus and the flexors of the fingers. Extension by the triceps and the anmoneus.

RADIO-ULNAR JOINTS, the movements of the radius and ulna take place round an oblique axis, there are three radio-ulnar joints, superior, middle and inferior. The superior is a pivot joint, the bones being the rim of the radius and the lesser sigmoid cavity of the ulna. The ligaments of this joint are the orbicular and the external lateral of the elbow. The Inferior joint is between the head of the ulna and the sigmoid cavity of the radius, and the ligament here is a triangular fibro-cartilage. The Middle joint is formed by the fibres of the interosseous membrane which run from the radius to the ulna, downward and inward.(The radius and hand move as one bone) and the oblique ligament. Pronation is performed by the pronator quadratus and the pronator radii teres, supination by the supinator brevis and the biceps. The supinator longus bringing the hand to a position of semi-pronation when in supination, of semi-supination when in pronation. The Ulna it must be remembered has a slight motion.

WRIST JOINT is a complex arthrosis and comprises all those joints between the radius and the triangular cartilage above and the bases of the metacarpals below. The ligaments of this joint are Anterior, irregular bands, Posterior, irregular bands, External lateral which is attached to the radius, scaphoid, trapezium and the first metacarpal. Internal lateral attached to the styloid of ulna, pisiform uniform and base of the 5th. metacarpal. Interosseous ligaments, 8 in number. There are four synovial membranes in the wrist. The nerves of the joint are derived from the ulnar, posterior interosseous and the musculo cutaneous. The arteries of the joint are from the radial, ulnar and two interossei. The movements are Flexion, by the flexors carpi ulnaris and radialis, the palmaris longus and the flexors of the fingers. Extension by the Extensors carpi radialis

longior and brevior and carpi ulnaris, with the extensors of the fingers and the three extensors of the thumb. Ulnar flexion, or adduction is produced by the flexor and extensor carpi ulnaris and Radial flexion, or abduction, by the flexor carpi radialis, the extensor caripe radialis longior and the extensor ossis metacarpi pollicis. Circumduction is performed by all the muscles.
METACARPO-PHALANGEAL JOINT is an enarthrosis without rotation. The ligaments are the capsule, Anterior, (strong) glenoid, Posterior, practically wanting but replaced by the expansion from the extensor tendons, Lateral, strong.
The four inner joints are connected together by a great horizontal band, the transverse metacarpal ligament. Movements, Extension by the extensors and the interossei, Flexion by the lumbricales, Abduction and Adduction by the interossei.
INTER-PHALANGEAL JOINTS, are ginglymus and admit of flexion and extension, in the first row Extension is produced by the common extensor and Flexion by the flexor sublimis, while in the second row Extension is by the common extensors and Flexion by the flexor profundus.

End of Part 1, The Arm.

THE LEG.


Sciatic
Ext: & Sub-Circumflex
1st Perforating
Cruciate Anast:
(See page 23)

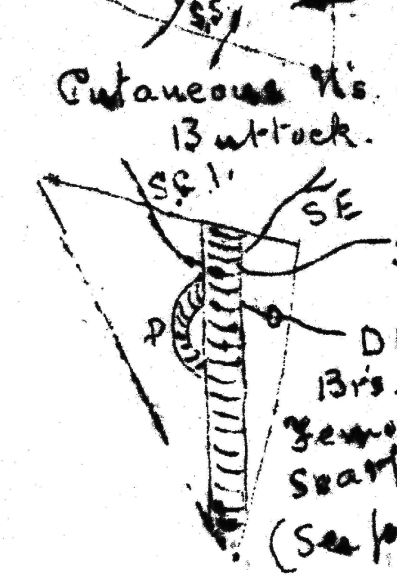
Cutaneous Ns. of
13 with rock.
SC 1'
SE
SEP.
DEP
Brs. of
Femoral in
Scarpa's Δ
(See page 24)

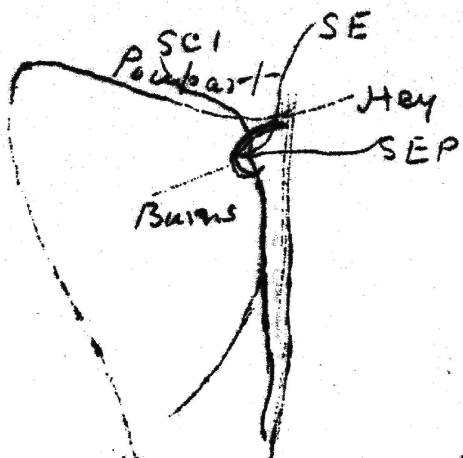
SC 1
Poupart's
SE
Hey
SEP
Burns
Saphenous Opening
(See page 25)


Venous
Anastomosis
Poupart
Holden's Line
Saphenous
Opening
Sides of
Pubic Arch
(See page 25)

EC
SC
MC
IC
Cutaneous
Ns. on front
of Thigh.

THE BUTTOCK. The skin of the buttock is coarse and the blood supply is poor, many cutaneous nerves are present, some ascending from the lesser sciatic (turning round lower edge of gluteus maximus), others are descending from the last dorsal and the ilio-hypogastric, as also from the sacral and coccygeal and the lumbar and external cutaneous. The superficial fascia usually contains much fat. The fold of the buttock varies according to the amount of fat and the muscular development of the subject. . The deep fascia in this region is strong and dips down among the fibers of the GLUTEUS MAXIMUS, the muscle with the coarsest fibers of any in the body. Origin, Ilium, between the posterior third of the crest and the superior curved line, lumbar fascia, lower part of sacrum, upper part of coccyx and by deep fibers from the great sacro sciatic ligament. Fibers run down and out, Insertion, two-thirds (upper) into ilio-tibial band of fascia lata, lower one-third into the gluteal ridge leading from the back of the trochanter major to the linea aspera, as also to the fascia at its lower part. Nerve, special branch of the sacral plexus, sometimes in addition a branch from the small sciatic.(Both nerves get the name of inferior gluteal).
GLUTEUS MEDIUS. Origin, Dorsum ilii between superior and middle curved lines, fascia between it and the maximus. Insertion, diagonal line of the great trochanter which extends from its posterior superior angle down and forward. Nerve, superior gluteal.
BURSAE in connection with the gluteus maximus three are found, one between the upper part of its tendon and the great trochanter, one between its tendon and the vastus externus and the last between the muscle and the tuberosity of the ischium. In connection with the medius two are found, one between the muscle and the trochanter above the diagonal line, the other separating it from the pyriformis.
GLUTEUS MINIMUS Origin, from dorsum ilii between the middle and inferior curved lines, upper part of the anterior margin of the great sciatic notch, and anterior border of the ilium as far as the anterior interior spine. Insertion, anterior border of great trochanter, having a bursa between it and the trochanter. Nerve, Superior gluteal.
SUPERIOR GLUTEAL NERVE, is a branch of the great lumbo-sacral cord which enters the buttock through the great sacro-sciatic foramen, above the pyriformis and supplies three muscles, gluteus medius and minimus and the tensor vaginae femoris (the three internal rotators).
GLUTEAL ARTERY, a branch of the posterior division of the internal iliac enters the buttock with the nerve. It appears at the lower border of the gluteus minimus and breaks up into superficial and deep divisions, the superficial lies under the gluteus maximus, the deep between the medius and minimus, the deep division being accompanied by the nerve, and divides into superior and inferior branches.
PARTS BENEATH GLUTEUS MAXIMUS. On reflection of the gluteus maximus the following structures can be seen in the order from above down as given, all covered by loose cellular tissue. Gluteus medius, gluteal vessels and superior gluteal nerve, Pyriformis, sciatic and pudic vessels and the

great sciatic, small sciatic and pudic nerves with the nerves to the obturator internus and quadratus femoris. Next are seen the two gemelli and the obturator internus with the circumflex (internal) vessels, the nerve to the quadratus again and five muscles, the quadratus femoris, adductor magnus and the three hamstrings. The gluteus maximus also lies over the tuber ischii and great trochanter, the two sacro-sciatic ligaments and the three bursae already mentioned.

THE PYRIFORMIS, Origin, front of the lateral mass of the sacrum between the foramina and the grooves external to the foramina, from the upper part of the great sacro-sciatic notch and sometimes from the sacro-sciatic ligaments. Insertion, a depression at the posterior part of the top of the great trochanter. Nerve, branch of the sacral plexus. The muscle is sometimes perforated by a part of the great sciatic nerve.. The muscles passes through the great sacro-sciatic foramen.

OBTURATOR INTERNUS, only the tendon is now seen. The muscle arises from the inner aspect of the ischium, partly also from the pubis and from the lower part of the obturator membrane. Tendon passes through the foramen with the last mentioned muscle and having been joined by the gemelli passes out under the tendon of the pyriformis, Insertion, depression at anterior part of the upper margin of the great trochanter.. Nerve, branch from the sacral plexus.

GEMELLUS SUPERIOR, Originexternal surface of spine of the ischium, Insertion, tendon of pyriformis and great trochanter, Nerve, nerve to the obturator.

GEMELLUS INFERIOR, Origin, upper and back part of the tuber ischii, Insertion same as last muscle, Nerve, Nerve to the quadratus.. The inferior muscle is more constant than the superior which is often wanting.

OBTURATOR EXTERNUS tendon can be seen lying deeply between the inferior gemellus and the quadratus. Origin, (will be seen later) Anterior and inferior margins of the obturator foramen and anterior two-thirds of the obturator membrane. Insertion, digital fossa of femur. Nerve, deep branch of the obturator

QUADRATUS FEMORIS, Origin, outer side of tuberosity of ischium, Insertion, a line on the back of the famur below the middle of the posterior intertrochanteric line just above the adductor magnus. Nerve, branch from the sacral plexus.. It is separated from the lesser trochanter by a bursa.

SCIATIC ARTERY, a branch of the anterior division of the internal iliac, emerges from the pelvis through the great sacro-sciatic foramen below the pyriformis. It gives large inferior gluteal branches to the gluteus maximus and muscular branches to the surrounding smaller muscles, its named branches are the coccygeal, the comes nervi ischiadici which runs upon the great sciatic nerve and into its terminal branches and the anastomotic or quadratal branch which enters into the crucial anastomosis

CRUCIAL ANASTOMOSIS, varies much in its formation, usually consists of the internal and external circumflex and the superior perforating from the profunda and the above branch from the sciatic, but we also at times have a branch of the gluteal.

DISSECTION TO EXPOSE THE GLUTEAL ARTERY, reflect the skin and superficial fascia with its vessels and nerves from the gluteal region, the deep fascia, the gluteus maximus, then will be largely cut away or exposed the superficial part of the artery, reflect the gluteus medius, then is exposed the deep part.

DISSECTION TO EXPOSE THE SCIATIC ARTERY, this artery is seen on reflection of the gluteus medius in its extrapelvic portion.

INTERNAL-PUDIC ARTERY isseen only in the small portion of its course which lies on the spine of the ischium as it winds out of the pelvis through the great sacro sciatic notch to re-enter through the lesser., the artery is accompanied by its vein and two nerves the

PUDIC NERVE, from the sacral plexus, lies on spine of ischium internal to the pudic vessels

NERVE TO THE OBTURATOR INTERNUS, lies external to the pudic artery, arises from the upper part of the sacral plexus, leaves pelvis below the pyriformis lies with pudic nerve and artery on spine of the ischium, gives a branch to the superior gemellus and re-enters pelvis through lesser foramen, supplies the obturator within the pelvis..

NERVE TO QUADRATUS FEMORIS , arises from front of sacral plexus, passes beneath the obturator internus tendon to supply quadratus and inferior gemellus. It lies against the back of the hip joint to which it gives a branch. This nerve lies parallel with the great sciatic but is separated from it (it lying at a deeper level than the sciatic) by the gemelli obtunator internus and the quadratus femoris.

DISSECTION TO EXPOSE NERVE TO QUADRATUS. Reflect skin, superficial fascia with vessels and nerves from the inferior gluteal region, the fascia lata, the gluteus maximus, then hook the sciatic vessels and nerves over the ischial spine and reflect the gemelli and the obturator internus.

GREAT SCIATIC NERVE, constitutes the great bulk of the sacral plexus, leaves the pelvis by the great sacro-sciatic foramen passing under the pyriformis or else pierces the muscle. It enters the thigh between the trochanter and the tuber ischii, lying upon the posterior lip of the acetabulum, then upon the gemelli and obturator internus, quadratus femoris and adductor magnus. It lies under cover of the long head of the biceps. It terminates by dividing into the internal and external popliteal nerves. Usually this portion of the nerve gives off no branches but sometimes the nerves to the hip joint and the quadratus come from it instead of from the sacral plexus..

DISSECTION TO EXPOSE GREAT SCIATIC NERVE, reflect the skin etc., the gluteus maximus and the long head of the biceps.

SMALL SCIATIC NERVE, a main branch of the sacral plexus, appears at lower border of pyriformis to become cutaneous nerve to the back of the thigh As soon as it leaves the pelvis it gives off recurrent branches to the skin of the buttock, then (sometiges) a muscular branch to the gluteus maximus, then the inferior pudendal nerve which winds below the tuberosity of the ischium to the perineum and other cutaneous branches to the back of the thigh..

The body is now turned upon the back and the front of the thigh seen. An incision having been made along Poupart's ligament and down the inner side of the upper half of the thigh is joined by another across the thigh at that point. The flap of skin is turned outward.

SUPERFICIAL FASCIA OF THE THIGH. is continuous with the superficial fascia of the abdomen over Poupart, generally contains a good deal of fat. It is divisible into two layers in the upper part of the thigh, the separation being marked by some small vessels, glands and minute nerves.

SUPERFICIAL VESSELS OF FRONT OF THIGH, are branches of the common femoral and are three in number, superficial epigastric, passes up and in over lower part

of abdomen. Superficial circumflex iliac, small branch running out a little below Poupart's ligament, superior external pudic running inward over the spermatic cord to the scrotum, or to the labium in the female. The veins correspond in course and open into the long saphenous vein. The superficial lymphatic glands are also found between the two layers of superficial fascia and are arranged intwo rows, one extending obliquely along the groin and receiving the lymphatics of the scrotum, perineum, nates and abdominal wall below the umbilicus, another runs vertically down the thigh below the groin draining the superficial lymphatics of the limb. A few deeper glands lie around the vessels. The superficial nerves are the termination of the ilio-inguinal, crural bhanch of the genito crural and external cutaneous from the lumbar plexus, and the middle and internal cutaneous branch of the anterior crural. The deep layer of the superficial fascia is more membranous than the superficial, this layer is attached to the fascia lata below Poupart and around the margin of an opening through which the saphenous vein passes, this layer does not pass over Poupart, as it crosses over, covering in, the saphenous opening it receives the name of the cribriform fascia.

THE SAPHENOUS OPENING is a cleft which is formed because the pubic and iliac portions of the fascia lata lie at different levels. The outer boundary of the opening is formed by the falciform margin of Burns, and this in its course has a well defined curve sweeping upward and inward beginning below the opening to terminate at the inner part of Poupart, to the whole length of which the iliac portion of the fascia lata is attached. The pubic or pectineal portion of the fascia is continuous with the iliac portion below the opening, put above it passes behind the femoral sheath, in front of which the iliac portion lies to become continuous with the ilio-psoas fascia. Taking advantage of the difference of level the long saphenous vein passes through this aperture to open into the femoral vein. It is through this opening that a femoral hernia makes its appearance on the thigh, hence it is sometimes called the external femoral ring. In truth there is no opening as the deep layer of the superficial fascia, here called as already mentioned the cribriform fascia, closes over the opening.. The external margin of the ring is called the falciform margin of Burns, the upper part the ligament of Hey, on the latter being traced to its termination we find that it passes under the inner part of Poupart, with which the rest of the iliac fascia is joined, to attach to, or become, Gimbernat's ligament. THe Saphenous opening transmits the long saphenous vein with its branches, the superficial circumflex artery, the superficial epigastric and superior external pudic artery, lymphatics and a venous plexus. In three regions of the body we find the superficial fascia split in two laminae, in the lower abdomen, upper thigh and upperior triangle of the perineum. In all these regions the deep layer becomes attached to the fascia lata along certain lines, Holden's line lies above Poupart, is more horizontal than Poupart and touches the ligament at its inner end, around the margin of the saphenous opening, the sides of the pubic arhh and at the posterior border of the triangular ligament. Between the superficial epigastric vein and the thoracic branches of the axillary there always exists a communication.

On removal of the superficial fascia there is exposed what has in

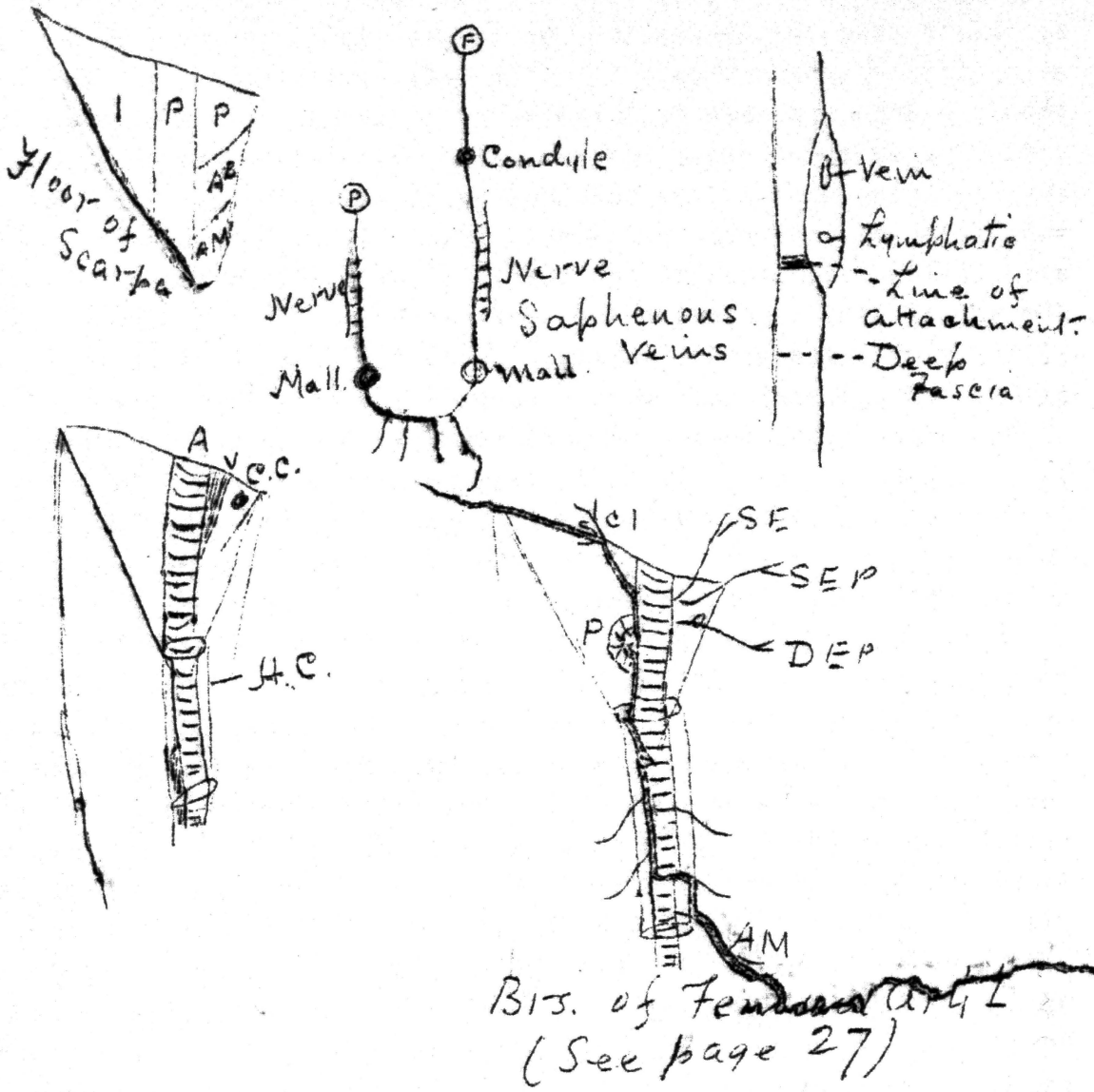
I
P
P
AL
AM
Floor of Scarpa
F
Condyle
Nerve
Saphenous Veins
P
Nerve
Mall.
Mall.
Vein
Lymphatic
Line of attachment
Deep Fascia
A
V
C.C.
H.C.
C1
SE
SEP
P
DEP
AM
Bif. of Femoral Art.

(See page 27)

part already seen, the
DEEP FASCIA OF THE THIGH, which is strong especially on the outer aspect where in constitutes the ilio-tibial band which is attached above to the front part of the iliac crest and below to the tibia and fibula. As this band which is about three inches broad ascends it divides into two portions, one of which passes to the iliac crest as mentioned the other to the hip joint. This latter is perforated by the ascending branch of the external circumflex artery. Between the two portions and attached to both, is the tensor vaginae femoris, which serves to make tense the band. Also attached to the band is the greater part of the insertion of the gluteus maximus.. The fascia lata can be divided into three parts, iliac, pubic and general. This last with parts of the others forms a strong investment for the thigh and sends in intermuscular septa between the muscles to the rideges on the bones from which they arise. The common femoral vessels lie outside of this investment although they lie under cover of the accessory processes which pass to Poupart. In the middle and lo part of the thigh the fascia sends in two strong intermusoular septa dividing the vastus externus from the hamstrings and an internal dividing the vastus internus from the adductors. The hamstrings are bound down by a layer of dee fascia within the true deep fascia and in addition each of the three muscles receives a special investment.
SCARPA'S TRIANGLE has the following boundaries, Above, Poupart, Externally, the sartorius, Internally the outer edge of the adductor longus. Roof, fascia lata, Floor, (from without inward) Iliacus, psoas, pectineus, and, if the subject be poorly developed muscularly a small portion of the adductor longus and possibly the adductor magnus. Contents, common femoral artery giving off some small branches and the profunda, femoral vein and some tributaries, some deep lymphatic glands, the anterior crural nerve and its branches, the superficial part of the obturator nerve, the crural branch of the genito crural, lymphatic vessels and glands. The saphenous vein is not one of the contents until it has pierced the fascia lata to enter the femoral vein..
SAPHENOUS VEINS, both veins begin in a plexus on the dorsum of the foot, the long passes upward in front of the internal malleolus but behind the internal condyle and, piercing the saphenous opening, opens into the femoral, while th short passes up behind the external . malleolus, pierces the popliteal fascia and opens into the popliteal. Both are accompanied by nerves which which are closely attached to their walls, both veins contain many valves.
FEMORAL SHEATH, or crural sheath is a triangular bag of fascia lata derived from the fascia lata inside the abdomen. This bag enters the thigh under cover of Poupart. Its base is up and its apex lost upon the femoral vessels downward.. It is incompletely divided into three compartments, the outer containing the femoral artery and the crural branch of the genito crural nerve, the middle one containing the femoral vein while the inner one contains the crural canal,(if such can be called a content) and a lymphatic gland. The crural canal is one inch long , it communicates with the abdomen through the crural ring.
DISSECTION TO EXPOSE THE FEMORAL ARTERY- Reflect the skin, superficial fascia with its vessels and nerves and the deep fascia from Scarpa's triangle, reflecting the iliac fascia outward , this will expose the artery in this pa

THE FEMORAL ARTERY extends drom Poupart's ligament to the "opening in the adductor magnust It is comparatively superficial in its upper part where it lies in Scarpa's triangle, in its lower half it lies in Hunder's canal and is not so superficial as it is covered by the sartorius. From above downward in Scarpa's triange it lies upon the psoas, the pectineus and, occasionally, between the adductor longus and the pectineus a msall bit of the adductor brevis, lower down it lies on the longus and magnus. In Scarpa the artery is behind the superficial fascia and the fascia of Burns, in the sheath, and one or two of the branches of the internal cutaneous nerve cross it. To the outer side throughout in the triangle is the anterior crural nerve, to its inner side are the femoral vein near Poupart, but the vein crosses behind it lower down and forms a posterior relation at the apex of the space. In Scarpa's triangle the artery gives off the three branches which have been mentioned as passing through the saphenous ocening, the deep external pudic (or inferior) the profunda femoris, and some muscular twigs.

THE FEMORAL VEIN at the lower part of Scarpa's triangle lies behind and a little to the outer side of the artery, it then crosses obliquely behind it and after being joined by the profunda vein reaches the inner side of the common femoral artery at the upper part of the space, there it receives the long saptenous vein which has passed through the saphenous opening.

ANTERIOR CRURAL NERVE, is derived from the 2nd. 3rd. and 4th. lumbar nerves, enters scarpa's triangle under Poupart's ligament resting on the adjacent borders of the psoas and iliacus. It breaks up into superficial and deep divisions which are separated by the external circumflex branch of the profunda artery, the superficial giving off themiddle .nd internal cutaneous nerves (also sometimes the long saphenous[U] while the deep supplies the pectineus, , rectus, crureus, vastus internus and externus (sometimes the sartorius) and (sometimes) gives off the long saphenous. The Sartorius is usually supplied by the superficial division. . The middle cutaneous appearr to be two nerves it runs down the front part of the thigh and ends in front of the patella, the internal cutaneous is formed by two branches which go down as far asa little below the knee. The long saphenous nerve approaches the femoral artery and enters Hunter's canal with it, it becomes cutaneous at the inner side of the knee joint and enters into the formation of the patellar plexus by communicating with the middle and internal cutaneous. The nerve can be traced as far as the the base of the first metatarsal bone. The muscles here are

TENSOR VAGINAE FEMORIS. Origin, outer side of anterior superior spine of ilium and part of the notch between the two anterior iliac spines, slightly from the crest and its fascial sheath, Insertion, into the fascia lata below the great trochanter, the fascia being split to receive the muscular fibers. Nerve, superior gluteal..

SARTORIUS, lies loosely on the subjacent muscles when dissected. Origin, anterior superior spine of the ilium and the notch below it and the outermost part of Poupart's ligament, crosses obliquely across the thigh winds behind inner tuberosity of the femur, turns forward below the inner tuberosity of the tibia and is INserted into the upper part of the internal surface of the tibia and the fascia. Nerve, anterior crural (by middle cutaneous branch).

RECTUS FEMORIS, has no attachment to the femur but sretches over it from the ilium to the patella. Its Origin is by two heads, one the straight from the anterior superior spine of the ilium, the other, the reflected, from the de-

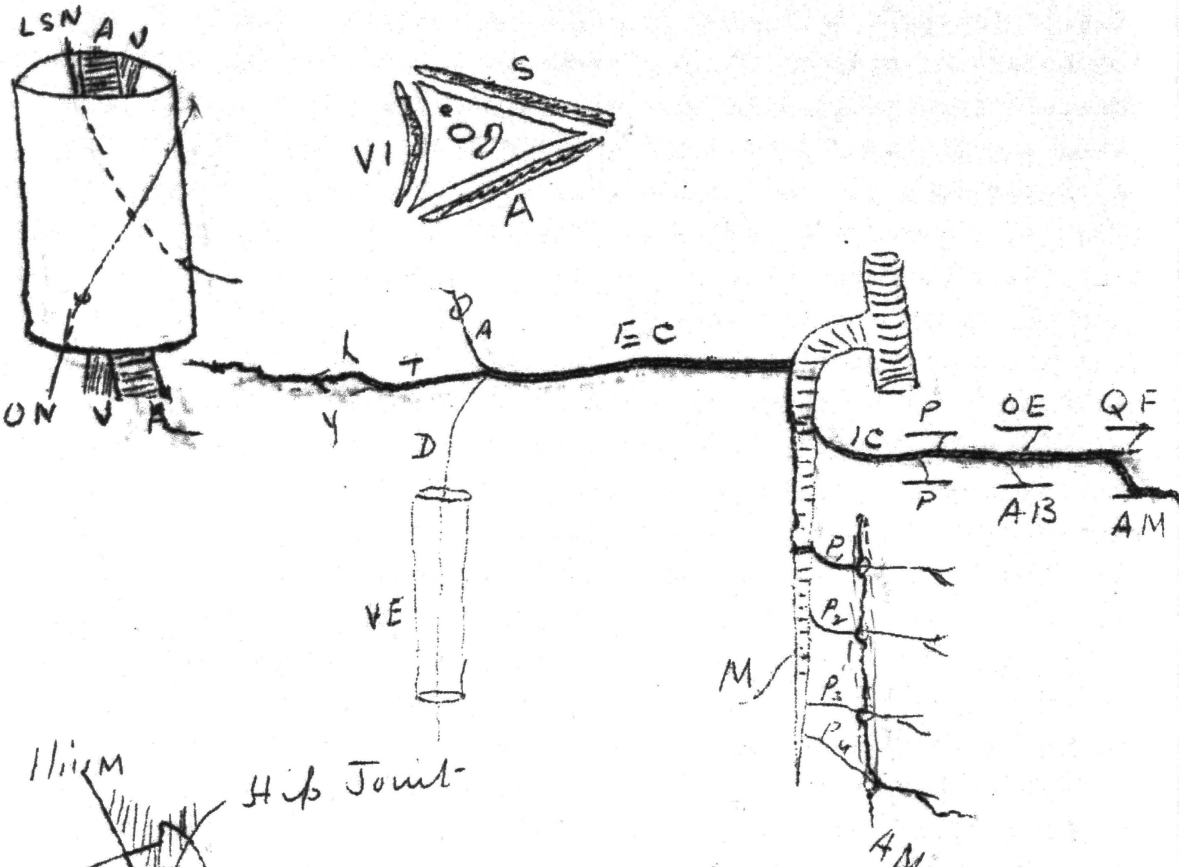

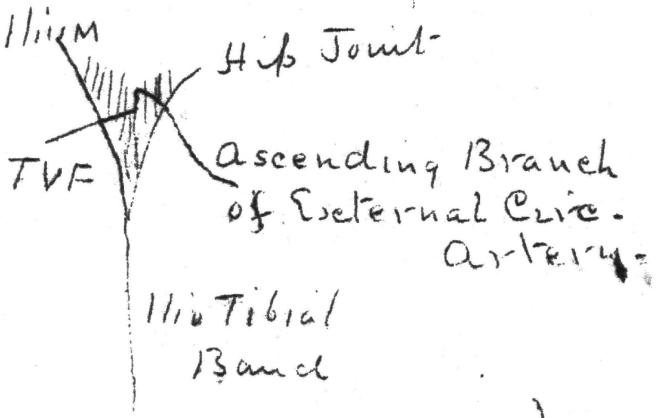

(See page 29)

(See page 29)

prosnion above the acetabulum uhich can be seen by separating the tensor vaginae femoris from the rectus and clearing away the fat and fascia from the deep region. The two heads unite to form a bi-penniform muscle which is tendinous on its upper surface above and on its lower surface below to lessen friction. In conjunction with the other muscles forming the quadriceps extensor the Insertion is into the patella, the strong fibers which pass in front of the patella forming the superficial portion of the ligamentum patellae. The crureus joins the back of the tendon above the patella, the vasti are attached to its borders. Nerve, anterior crural.

HUNTER'S CANAL is an intermuscular canal or space beneath the sartorius in the middle third of the thigh, it is about four inches in length and is a tube of fascia lata in which four structures liethe femoral artery and vein, the long saphenous nerve at the upper part of the canal, the articular branch of the obturator nerve at the lower part. On transverse section the canal is to a certain extent triangular. Boundaries, Anteriorly, sartorius, Externally, vastus internus, Posteriorly the adductors longus and magnus. The canal is continuous above with Scarpa's triangle, , below, through the opening in the adductor magnus with the popliteal space. On laying open the space by the reflection of the sartorius the femoral artery is found lying with its vein behind and external to it.

FEMORAL ARTERY IN HUNTER'S CANAL gives off muscular branches and an anastomotica magna artery, the latter leaves the artery at the lower end of Hunter's canal and divides into articular to the knee and cutaneous which runs with the long saphenous nerve. (See previous paragraph for further notes on artery)

VASTUS EXTERNUS , Origin, outer lip of the linea aspera and lines leading from it, adjacent external surface for three quarters of an inch, also from fascia and septa, Insertion, into tendon of the rectus laterally and the patella. Nerve, anterior crural. The muscle can be lifted up from the femur, its origin is tilted up on to the anterior surface just below the gluteus minimus.

VASTUS INTERNUS is more or less united with the crureus, lower half of the spiral line, inner lip of the linea aspera, upper part of the internal supracondyloid ridge, the internal intermuscular septum and intermuscular septa. Insertion, rectus tendon and patella The orgin is closely united with that of the crureus and the insertion of the adductors longus and magnus. Nerve, anterior crural.

CRUREUS, covers the front of the femur between the vasti and beneath the rectus. Origin, upper part of the spiral line, anterior and outer surfaces of the femur to about four inches from the lower end of the bone, also from the external intermuscular septum, Insertion, into the patella with the other 3 muscles. Its surface is tendinous to allow of frictionless movement. Nerve, anterior crural.

INNER SIDE OF THE THIGH a few cutaneous branches of nerve to the skin on the inner side of the thigh are found appearing below the adductor longus. They are branches from the obturator.

ADDUCTOR LONGUS Origin by a round tendon from the front of the pubis, just be- the crest, Insertion, inner border of the linea aspera in middle third of the femur, internal intermuscular septum with adductors magnus and brevis. Nerve, obturator (superficial). In middle third of thigh it lies between the superficial and deep femoral vessels.

THE GRACILIS, the most internal of the muscles of the thigh, Origin, ramI of ischium and pubis by a thin, brief tendon. Insertion, inner side of tibia under cover of the sartorius and over the semi tendinosus, a bursa intervening. Nerve, superficial branch of obturator.

PECTINEUS, Origin, inner part of ileo-pectineal line and triangular surface in front of it between pubic spine and ilio pubic eminence. Winds to back of femur. Insertion, upper part of line leading from back of trochanter minor to linea aspera. Nerve, anterior crural and obturator. The musole is in ralation anteriorly with tha femoral and profunda vessels and part of the anterior crural nerve, above it pass the internal circumflex vessels, below it pass the profunda vessels, its deep surface is in relation with the obturator externus, adductor brevis, superficial division of the obturator nerve and inner part of the capsule of the hip joint.

PSOAS and ILIACUS insertion. The two muscles are conjoined as they pass into the thigh, the first is inserted by tendon into the small trochanter, the iliacus by fleshy fibers into the tendon of the psoas and into a triangular mark on the femur below the trochanter, in front of insertion of pectineus.

ADDUCTOR BREVIS has superficial branch of tha obturator lying on it, and the deep branch lying between it and the magnus. Origin, front of pubic ramus belo the adductor longus between gracilis and obturator externus, Insertion, whole length of the line leading from the lesser trochanter to tha linea aspera, behind the pectineus and upper part of the adductor longus and in front of the magnus. Nerve, , deep or superficial obturator.

THE PROFUNDA ARTERY, arises from the femoral in Scarpa's triangle about an inc or so below Poupart, lies at first to the outer side of the femoral and against the iliacus, then inward under the femoral vessels and its own vein on the pectineus, it then passes below the border of the pectineus behind the adductor longus and on to the adductor brevis and magnus, ending by piercing the last named. Its vein is superficial to it in all of its course. The

BRANCHES OF THE PROFUNDA ARTERY are the external and internal circumflex, 3 or 4 perforating arteries and a terminal branch, besides muscular twigs. The external circumflex artery arises near the orgin of the profunda from its outer side, it runs out almost transversely between the branches of the anterior crural nerve and is covered by two structures, the sartorius and rectus femoris. It then divides into three parts, ascending, transverse and descending. The ascending pierces the internal lamina of the ilio-tibial band and anastomoses with the circumflex iliac. The transverse ends in the crucial anastomosis. The descending lies in the vastus externus and ends at the knee.

DISSECTION TO EXPOSE EXTERNAL CIRCUMFLEX ARTERY, reflect skin, superficial fascia with its structures, the deep fascia, the rectus femoris and the sartorius and a few branches of the anterior crural nerve. The internal circumflex artery winds round the femur to the back of the thigh and lies between three pairs of muscles, the psoas and pectineus, the adductor brevis and obturator externus, the quadratus femoris and adductor magnus.

DISSECTION TO EXPOSE PROFUNDA FEMORIS ARTERY reflect skin, superficial fascia, fascia lata, split up Hunter's canal, pull outward the sartorius and remove the long saphenous nerve, reflect from below up the femoral vessels, and the profunda femoral vein, reflect the adductor longus.

The perforating arteries pierce the adductor muscles to supply the hamstrings.

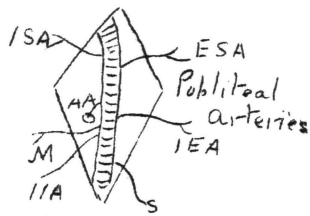

(See page 31)

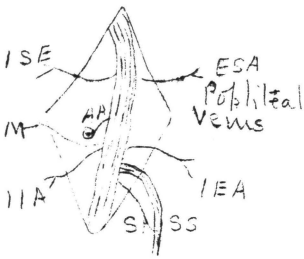



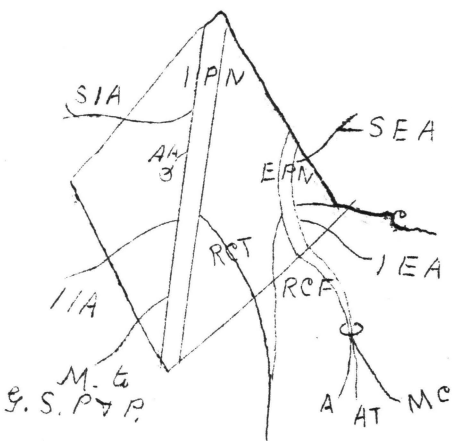

Nerves of Popliteal Space.

(See page 31)

The termical branch ends in the adductor magnus or pieroes it to anastomose with the inferior perforating and superior internal articular. .The three perforating arteries and the terminal branches form a chain if anastomoses in and behind the adductor magnus.

THE PROFUNDA VEIN receives branches corresponding to the arteries and lies superficial to the artery throughout.

THE OBTURATOR NERVE is derived from the 2nd., 3rd. and fourth lumbar nerves. it is one of the internal branches of the plexus. After a short course in the pelvis it leaves it by passing over the free border of the pelvic fascia, it t en divides into two portions, a superficial and a deep, both of which pass through the obturator foramen, the superficial passing over the obturator externus, the deep piercing it. Having entered the thigh these two are separated by the adductor brevis. The superficial division supplies the adductor brevis, the gracilis, adductor longus and half of the pectineus, while the deep supplies the adductor magnus, obturator externus and both the hip and knee joints.. An accessory obturator nerve is occasionally found passing from the third and fourth nerves of the lumbar plexus over the pubic bone to supply the pectineus.

DISSECTION TO EXPOSE THE OBTURATOR NERVE, reflect the skin superficial fascia with its vessels and nerves and the fascia lata from Scarpa's triangle, the pectineus and the adductor longus, now is exposed the superficial part, reflect the adductor brevis and the deep portion of the nerve is exposed.

THE ADDUCTOR MAGNUS Origin, external surface of ramus of ischium and pubis, lower part of the ischial tuberosity. Insertion, anterior fibers back of the femur from insertion of quadratus to the linea aspera (adductor minimus), the middle fibers into the whole length of the linea aspera and the line leading from it to the internal condyle, posterior, ischial, fibers end in a round tendon inserted into the tubercle above the inner condyle and the line leading from it. This tendon forms an arch and the interval between it and the rest of the insertion of the mus le constitutes the "opening in the adductor magnus". Nerve, obturator and great sciatic.

OBTURATOR EXTERNUS. Origin, anterior and inferior margins of the obturator foramen and the anterior two-thirds of the obturator membrane. Insertion into digital fossa. Nerve, deep obturator.

THE POPLITEAL SPACE, a few branches of the small sciatic and internal cutaneous nerves may be found in the superficial fascia which is removed to expose the deep, or popliteal, fascia., which is continuous with the fascia lata and strengthened by fibers from the hamstring muscles. It stretches across the space to protect the vessels and nerves. The space is a lozenge shaped cavity whose roof is formed of deep fascia, the floor is formed by the lower part of the posterior surface of the femur, the posterior ligament of the knee and the popliteus muscle. It is continuous above with Hunter's canal and below with the deep intermuscular spaces of the leg.. Its upper external boundary is the biceps, internally the adductor magnus, the semi-membranosus and tendinosus. ITs lower boundaries are the fleshy heads of the gastrocnemius on either side with the plantaris in addition on the outer side. The contents of the space are vessels, nerves and a pad of fat. The internal popliteal nerve is the most superficial of the important structures, it is the larger division of the great sciatic and lies in the center of the space,

disappearing beneath the gastrocnemius, the artery crosses under it from its inner to its outer side. Branches, superior, inferior internal articular and azygos articular, muscular to the gastrocnemius, soleus and plantaris as also the popliteus, and the communicans poplitei which will be found on the back of the leg uniting with the communicans peronei to form the short saphenous nerve. The external popliteal nerve, or peroneal, lies under cover of the biceps at the upper part of the space, becomes visible near its tendon close to the upper end of the fibula. Branches, two sometimes three articular on the outer side corresponding to those from the internal nerve, an external cutaneous branch to the outer side of the leg and the ramus communicans peronei which unites with the poplitei as already mentioned.

THE popliteal artery is the direct continuation of the femoral artery, extends from the opening in the adductor magnus to the lower border of the popliteus. It lies near the bottom of the space, only separated from the floor by a pad of fat. its vein is at first to its outer side, then crosses it superficially and lies to its inner side below. Emerging from the opening in the adductor magnus with the artery is a branch of the obturator neeve, which passes to the knee joint. Branches, superior and inferior internal and external articular, azygos articular, superior and inferior muscular. The external superior articular passes outward under the tendon of the biceps, the internal under cover of the adductor magnus and the two other hamstrings passes inward. The internal inferior articularfollows the upper border of the popliteus and passes under the long portion of the internal lateral ligament, wtile the external passes out under cover of the eternal lateral ligament and between it and the semilunar cartilage, quite above the level of the fibula, to the front of the joint. The popliteal vein is formed by the junction of the anterior and posterior tibial veins at the lower border of the popliteus, it lies superficial to the artery and receives branches corresponding to the branches of the artery as also the external saphenous vein. It is closely adherent to the artery and has very thick walls. A few small lymphatic glands are situated in the space close to the artery. The efferent vessels end in the deep femoral glands. DISSECTION TO EXPOSE EXTERNAL POPLITEAL NERVE reflect the skin, superficial fascia with the branches of the small sciatic nerve, cutaneous nerves and rami nerves, and the external saphenous vein, the deep fascia, and reflect the biceps, then is exposed the nerve.

THE BACK OF THE THIGH is a region whose floor is formed by the femur and the adductor magnus, upon which lie the three hamstrings and the great sciatic nerve with its two terminal divisions. This floor has in its muscular portion a series of foramina, five of which lie close to the femur and transmit the perforating and terminal branches of the profunda artery. We also find muscular branches of the profunda artery.

SEMITENDINOSUS, SEMIMEMBRANOSUS and BICEPS. BICEPS, Origin, long head from tuber ischii in common with tendinosus, great sacro-sciatic ligament; short head, outer lip of linea aspera nearly as high up as the insertion of the gluteus maximus down to within two inches of the condyle and from the external intermuscular septum, Insertion, bicipital tuberosity on outer side of head of fibula, fascia of the leg, and by a slip into the anterior and external part of the tibial protuberance. Tendon is split to enclose the long external lateral ligament, from which it is separated by a bursa. Nerve, Gt. sciatic

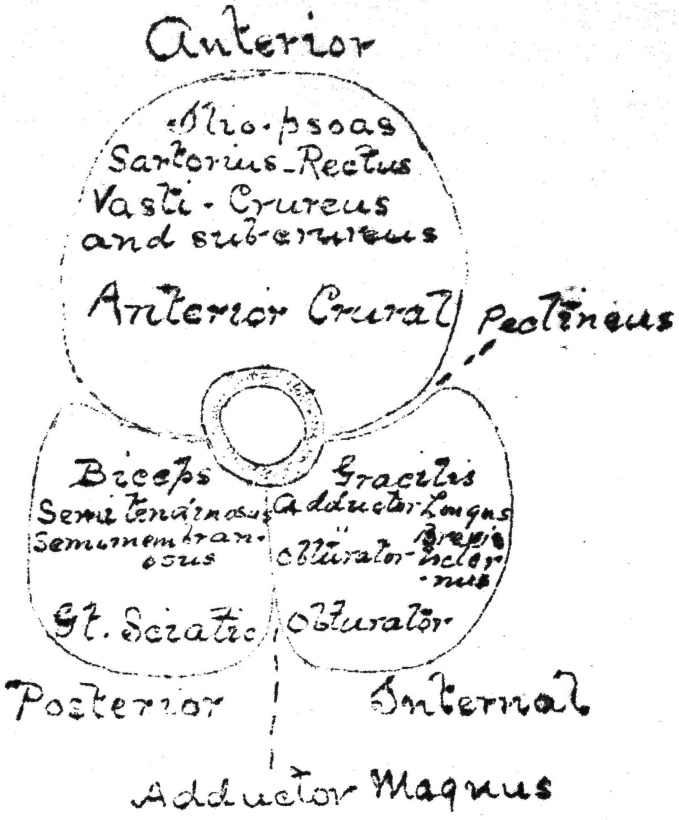

Nerve supply of thigh muscles.



Cutaneous Nerves of Back of Leg.

Tendo Achilles

SEMITENDINOSUS, Origin, by fleshy fibers from the tendon of the biceps and in common with it from the inner part of the tuberosity of the ischium. It ends in a long slender tendon which lies on the semimembranosus and is Insertedinto the deep fascia of the leg and the tibia below the internal tuberosity lying under the tendon of the sartorius and below the gracilis and in relation with a bursa as mentioned in regard to those muscles. Nerve, great sciatic.
SEMIMEMBRANOSUS, though an internal hamstring lies external to the biops at its Origin, by a strong tendon from the upper and outer part of the tuber ischii, spreads into a broad membranous tendon from which the muscular fibers arise to form a thick belly that extends almost as far as the knee. Insertio b a sh rt strong tendon into a depression behind the inner surface of the internal tuberosity of the tibia and a horizontal groove beneath the internal lateral ligament of the knee joint. , bursae are in connection, one between the tendon and the i ner head of the gastrocnemius and the knee joint, the other between the tendon and the internal lateral ligament. Nerve, gt. sciatic
CRUCIAL ANASTOMOSIS the terminal branch of the internal circumflex artery enteriog into the crucial anastomosis between the adductor magnus and the quadratus femoris is also on the back of the thigh. DISSECTION TO EXPOSE; Reflect the gluteus maximus, the sciatic vessels and nerve and the quadratus femoris.
THE BACK OF THE LEG. On reflecting the skin on the back of the leg by a double door-flap incision the external spphenous nerve is found, as also the few branches of the internal saphenous nerve and the external or short saphenous vein. The EXTERNAL SAPHENOUS NERVE is formed by the junction of the communicans peronei with the communicans poplitei. The poplitei will be found piercing the deep fascia and uniting with the peronei. The former pierces the fascia about half way down the leg while the latter becomes cutaneous a short distance below the knee. The nerve runs along the outer side of the tendo Achilles to pass behind the external malleolus to the outer side of the foot and the little toe. The internal saphenous nerve gives off one or two branches to the inner side of the back of the leg.
THE SAPHENOUS VEINS, the external arises in a p,exus on the outer side of the dorsum of the foot, it passes up behind the external malleolus, pierces the popliteal fascia and opens into the popliteal vein. The long passes up,(after beginning in a plexus on the inner side of the dorsum of the foot,)in front of the internal malleolus, passes behind the internal condyle, passes through the saphenous opening and empties into the femoral vein. Both veins are accompanied by nerves which are closely attached to their walls, both contain many valves.
DEEP FASCIA OF THE LEG, is continuous with that of the thigh. It receives reinforcements from the hamstring tendons and gives attachment to the fibers of tibialis anticus and the extensor longus digitorum on the front of the leg. It is cosely adherent to the front of the tibia and from its deep surface pass two strong intermuscular septa, one in front of and one behind the peronei longus and brevis. It forms fascial investments for all the muscles as well as deep fascial investments which at the neighborhood of the ankle become strengthened and form the annular ligaments. The superficial muscles are
THE GASTROCNEMIUS, Origin, back of the femur immediately above the condyles, the orgin of the inner head extending into a little depression above the back of the popliteal groove while the inner head runs up for an inch along the

internal supracondyloid ridge, also both from fascia and septa. Insertion, the two heads uoiteto form a large fleshy bedly the fibers of which end about the middle of the leg in a broad thin tendon which is joined anteriorly and laterally by the soleus. The conjoined tendon contracts into a rounded tendon which is known as the tendo Achilles, this is constricted about two inches above the os calcis, then broadens out again and is attached to the middle part of the posterior surface of the os calcis. The inner belly descends lower down and the under surface of the muscle is tendinous. Nerve, internal popliteal.
PLANTARIS, Origin, popliteal surface of the femur just above the outer head of the gastrocnemius. Its fleshy fibres are about three inches long the tendon is the longest in the body and can be stretched out into a membrane. This muscle is inserted in one of three ways, into the os calcis, into the tendo achilles or into the deep fascia. The muscle is often absent. Nerve, int. popliteal.
SOLEUS, Origin, Oblique line on tibia, middle third of inner border of tibia, posterior surface of head and upper third of shaft of fibula, the intermuscular septsm between it and the peroneus longus and from a tendinous arch between the tibial and fibular origins. Insertion, by a tendinous expansion which unites with that of the gastrocnemius into the tendo achillus. THe muscular fibers extend down to within two inches of the heel on the deep surface. The superficial aspect of the muscle is tendinous. Nerve, internal popliteal.
TENDO ACHILLES has already been to a certain extent described. It is about four inches in length, narrowest about two inches or an inch and a half above the os calcis. On its superficial aspect it appears to be tendinous, but the fibres of the soleus extend far down on its deep aspect.
On dividing the fibres of the soleus vertically the arch over the deep muscles and the vessels and nerves will be exposed. The deep muscles are
THE POPLITEUS is covered by a strong fascia mainly derived from the tendon of the semimembranosus and on this rest the lower parts of the popliteal vessels and nerves. Origin, the muscle arises within the knee joint (inside the capsule but outside the synovial cavity) by a round tendonwhich is attached to the anterior half of the groove on the outer condyle of the femur. The tendon passes beneath the the long external lateral ligament and is closely connected withthe short external lateral ligament. It is in the politeal gnoove only during flexion. Insertion, almost the whole of the surface on the back of the tibia above the oblique line. Nerve, internal popliteal.
FLEXOR LONGUS DIGITORUM- Origin, posterior surface of tibia below oblique line internal to the tibialis postious, interosseous membrane and an intermuscular septum between it and the tibialis posticus. Insertion, by four tendons into the terminal phalanges of the four outer toes (perforans) These tendons will be seen again in the tendon layer in the sole of the f ot. Nerve, posterior tibial.
TIBIALIS POSTICUS Origin, (only muscle among the deep attached to both bones) posterior surface of tibia below oblique line and external to the longus digitorum, nearly the whole of the interosseous membrane, whole of the internal surface of the fibula immediately behind the interosseous line, fascia and septa. Insertion, into the tubercle of the scaphoid and by slips into a variable number of the pones of the tarsus and metatarsus, except the astragalus Nerve, posterior tibial.

FLEXOR LONGUS HALLUCIS is a well marked bi-penniform muscleOrigin, posterior surface of the fibula below the orgin of the soleus to within an inch of the ankle, intermuscular septa, fasciae and the lower part of the interosseous membrane. The muscle ends at the level of the ankle joint in a tendon which lies on the back of the tibia to the outer side of the posterior tibial vessels and nerve, passes through a separate division of the annular ligament, winds to the sole of the foot through a groove on the posterior surface of the astragalus and beneath the sustentaculum tali Insertion, terminal phalanx of hallux. Its tendon gives a slip to the tendon of the flexor longus digitorum in the sole. Nerve, posterior tibial.

POSTERIOR TIBIAL ARTERY is the direct continuation of the popliteal, begins at the lower border of the popliteus muscle, in the upper part of its course it rests between the superficial and deep muscles, below the soleus it is held down by a prolongation of the intermuscular layer of fascia and lies by the side of the tendo Achilles. It lies upon the tibialis postious, the flexor longus digitorum, the posterior surface of the tibia and the ankle joint. The vessel then passes through a special opening in the internal annular ligament midway between the internal malleolus and the great tuberosity of the os calcis The posterior tibial nerve lies in close relation with the artery, at first lying to its inner side but crossing it to lie at its outer. The artery has two venae comites. Branches, Peroneal, muscular, nutrient to the tibia, communicating and internal calcanean. The peroneal is always of considerable size, at first lies between the tibialis postious and the soleus, afterwards passes into the substance of the flexor longus hallucis and runs in that muscle close to the inner border of the fibula almost as fas as the end of the bone. It gives off muscular branches and the nutrient artery to the fibula, an anterior peroneal branch and is joined by the communicating branch from the posterior tibial. It terminates as the external calcanean. The muscular branches of the posterior tibial are given to the deep muscles and the soleus. The nutrient to the tibia is large, the communicating runs transversely immediately above the ankle to join the peroneal while the internal calcanean is variable and is often replaced by three or four irregular branches. The calcanean or its representatives nourish the sole-pad in the neighborhood of the heel.

DISSECTION TO EXPOSE THE PERONEAL ARTERY , reflect skin, superficial fascia with structures, deep fascia, superficial muscles, special arch of deep fascia cut the artery out of the substance of the flexor longus hallucis.

DISSECTION TO EXPOSE THE POSTERIOR TIBIAL ARTERY is the same as for the last but the flexor longus hallucis needs no cutting.

ANTERIOR TIBIAL ARTERY I is seen on this surface of the leg before it pierces the interosseous membrane to reach the front. Here it gives off the posterior tibial recurrent which runs up over the head of the fibula, and the superior fibular

POSTERIOR TIBIAL NERVE has the same extent as the artery, is the direct continuation of the internal ppliteal. Crosses artery from within outward and passes with the artery under the internal lateral ligament. The nerve divides near the ankle joint into the internal and external plantars, of which the internal is much the larger. The nerve supplies the tibialis postious, flexor longus hallucis and flexor longus digitorum and gives off a calcaneo plantar branch near the ankle which supplies the skin of the sole and heel.

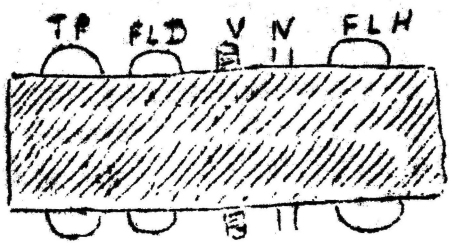

Int. Annular Lig't.

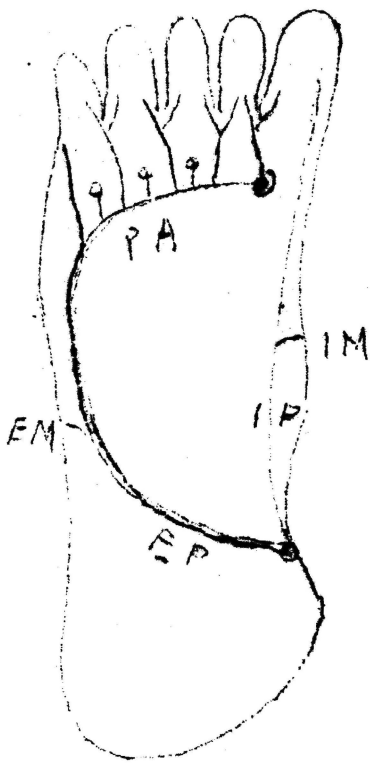

NOTE on the previous page under "dissection to expose posterior tibial artery" there is an omission, the posterior tibial nerve must be cut in order to fully expose the artery.

The parts behind the internal malleolus and below it are continuations of those already seen. The internal annular ligament is quite artificial, it is a thickened portion of deep fascia stretching from the inner malleolus to the os calcis. There are four divisions in the annular ligament and at the level of the ankle in division one we find the tibialis postious, second, flexor longus digitorum, third, posterior tibial vessels and nerve, fourth, the flexor longus hallucis. Below the malleolus the tibialis tendon is the highest, the longus digitorum next and the hallucis lowest. The plantar vessels and nerves are superficial to the longus hallucis tendon as they approach the sole each tendon is lubricated by a distinct synovial membrane.

THE SOLE OF THE FOOT. The skin is thick, has no hairs, has many sweat glands, is sensitive and vascular. It is ridged like the palm but the lines are not so well marked. The superficial fascia contains much distinctly lobulated fat. In the sole pad there is also much fibrous tissue, and bursae are sometimes found.

THE PLANTAR FASCIA resembles that of the palm and is divisible into three parts, the central which is strong is attached behind to the os calcis, as it passes forward it splits up into five parts opposite the heads of the metatarsal bones and here distinct transverse fibers are seen binding the foot together. The five processes are attached to the sides of the proximal phalanges and to the sheaths of the flexor tendons of each toe and between them pass the digital vessels and nerves.. The central portion gives origin by its deep surface to muscular fibres and also by two intermuscular septa one on each side of the flexor brevis digitorum. The lateral portions are much thinner than the central, mainly cover the muscles of the great and little toes, but on the ~~inner~~ outer side there is a strong band running from the outer tubercle of the calcaneum to the base of the 5th. metatarsal.

THE MUSCLES OF THE SOLE are in five layers, the first layer consists of three muscles, the flexor brevis digitorum in the middle with the abductor hallucis to its inner side and the abductor minimi digiti to its outer.

FLEXOR BREVIS DIGITORUM, Origin, anterior border of the great tuberosity of the os calcis, from the plantar fascia covering it and the intermuscular septa on either side. It divides into four tendons which pass into tendinous sheaths on the under surface of the four lesser toes and are perforated by the tendons of the longus digitorum, Insertion, the sides of the phalanges(second) of the toes, as in the fingers. The toes have tendon sheaths similar to those in the hand with synovial membranes and vincula vasculosa, but all much less developed. Nerve, internal plantar.

ABDUCTOR HALLUCIS, Origin, great tuberosity of os calcis, plantar fascia and the intermuscular septum between it and the flexor brevis digitorum, also from the internal annular ligament... Insertion, with the inner head of the flexor brevis hallucis it is inserted into the base of the first phalanx of hallux. Nerve, internal plantar.(inserted also by a fibrous expansion into the inner side of the long extensor tendon.)

ABDUCTOR MINIMI DIGITI. Origin, great tuberosity of the os calcis in front

of the flexor brevis digitorum, from the plantar fascia and intermuscular septum and from the fascia of the outer side of the foot as far forward as the base of the 5th. metatarsal bone. Insertion, outer side of the base of the first phalanx of the little toe. Nerve, external plantar.

THE PLANTAR ARTERIES, internal and external are the terminal branches of the posterior tibial and enter the foot as seen already beneath the abductor hallucis and in close relation with the plantar nerves. The internal plantar artery is the smaller and runs forward in the fascial septum between the abductor hallucis and the flexor brevis digitorum to the great toe where it anastomoses with the internal and communicating branches of the dorsal artery. The external artery runs obliquely outward across the foot between the flexor brevis digitorum and the accessorius and turning round the outer border of the accessorius runs inward under the digital tendons toward the great toe, there joining the communicating branch of the dorsal artery and completing the plantar arch. It is accompanied by the external plantar nerve(which gives a deep branch across the foot) and supplies the muscles, giving a branch to the outer side of the foot to anastomose with the external calcaneun branch of the peroneal..

NERVES OF THE SOLE OR PLANTAR NERVES, internal and external, are the branches of the posterior tibial nerve. The posterior tibial nerve having entered the sole divides into these of wtich the internal is the larger and supplies 3½ toes and 5 muscles. The external plantar supplies 1½ toes and all the other muscles. The external plantar nerve supplies all the muscles of the sole except the abductor hallumis, flexor brevis digitorum and hallucis and the two inner lumbricales which are supplied by the internal plantar nerve. The termination of the internal artery can be seen on reflection of he first layer of muscles, but the deep division of the external given off at the outer border of the accessorius is not seen until later. The nerves of the sole of the foot are identical in their distribution with those of the palm, the internal plantar corresponding to the median, the external to the ulnar and the deep branches of the last pair also correspond.

THE SECOND LAYER OF MUSCLES includes the tendons of the flexor longus digitorum and longus hallucis with the accessorius and the lumbricales. The tendon of the flexor longus digitorum runs on the inner side of the sustaculum tali inside of the vessels and nerves and crosses below these and over the longus hallucis tendon to the center of the foot where the fibres of the accessorius are attachhed to its deep surface. , it then divides into 4 tendons which give origin to the lumbricales, and are then inserted after passing forward as already described in the description of the muscle

THE LUMBRICALES arise from the tendons of the longus digitorum, the most internal from one, the rest from two tendons each, and wind to the inner side of the 4 small toes to reach thair dorsal aspect where they are inserted into the corresping sides of the bases of the proximal phalanges., Nerve, the two outer by the external, the two inner by the int. nerv

ACCESSORIUS, Origin, by two heads from the under surface of the os calcis, the outer head is tendinous and is also attached to the long plantar ligament which is seen between thetwo heads. The inner head is fleshy and the larger is attached to the concave line separating the inferior from the internal surface of the os calcis and to the inner edge of the long plantar ligament.

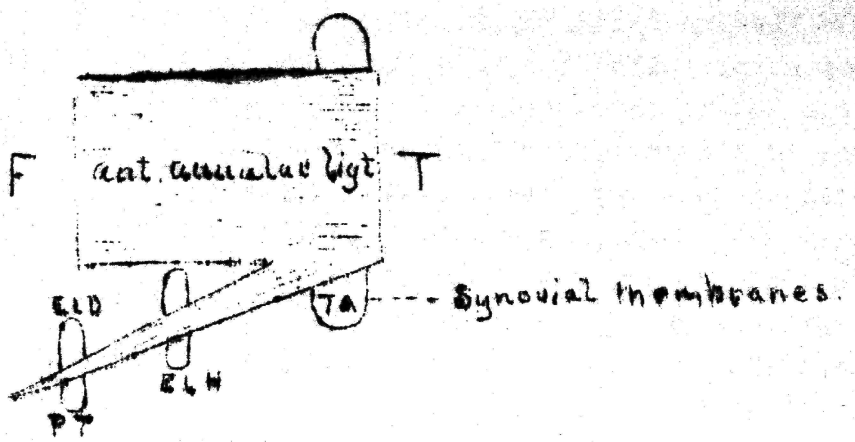
F
ant. annular ligt
T
E.I.D
E.L.H
P.T
T.A
Synovial membranes.

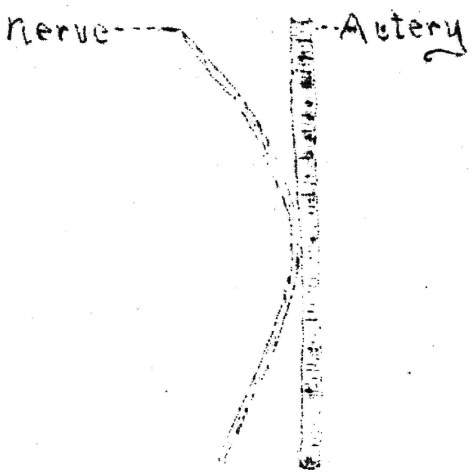
nerve
Artery

(See p 39)

the muscle is inserted into the deep surface and outer border of the flexor longus digitorum and sends slips to the tendons connected with the second, third and fourth toes. The tendon of the flexor longus hallucis after lying in the groove behind the astragalus and below the sustentaculum tali of the os calcis runs forward to the great toe under cover of the vessels and nerves and is crossed by the tendon of the flexor digitorum to which it gives a reinforcing slip. It then lies between the two heads of the flexor brevis hallucis and the two sesamoid bones with their connecting ligament form a deep channel for it, runs then in the sheath formed by the ligamentum vaginale to its insertion into the base of the terminal phalanx of the great toe.

THE THIRD LAYER OF MUSCLES consists of the flexor brevis hallucis, flexor brevis minimi digiti and the adductor trasversus hallucis & obliquus hallucis.

FLEXOR BREVIS HALLUCISOrigin, narrow tendinous from the inner side of the cuboid, long calcaneo-cuboid ligament etc. . Its fibres form two heads which are Inserted into the base of the first phalanx of the great toe, each having a sesamoid bone and being inserted with the abductor and the adductors respectively. The tendon of the long flexor runs between them. Nerve, internal plantar. The sesamoid bones form the anterior resting point of the plantar arch.

ADDUCOR OBLIQUUS HALLUCIS Origin, bases of the second, third and fourth metatarsal bones and from the long plantar ligament where it bridges over the peroneus longus tendon. Insertion, outer side of base of first phalanx of hallux with the outer head of the flexor brevis. Nerve, external plantar.

ADDUCTOR TRANSVERSUS HALLUCIS, of variable size consists of three or four small bundlesOrigin, from the plantar transverse ligaments over the heads of three or four metatarsal bones and separate the tendons and nerves from the interossei and vessels. Insertion, outer side of first phalanx of great toe. Nerve, external plantar.

FLEXOR BREVIS MINIMI DIGITI Origin, projecting base of 5th. metatarsal and sheath of the peroneus longus, insertion, outer side of base of first phalank of little toe. External plantar is its nerve.

PLANTAR ARCH. The external plantar artery after turning round the accessorius muscle takes a deep course superficial to the interossei to the base of the metatarsal of the hallux. This part of the course of the artery has been called the plantar arch and is joined by the communicating branch of the dorsal artery which enters the sole between the first and second metatarsals. Branches, recurrent twigs, posterior perforating arteries pierce the intervals behind the origins of the three outer dorsal interossei and anastomose with the interosseous arteries on the dorsum. Four digital arteries arise from the anterior part of the arch, the outer goes to the outer side of the little toe the others supply branches by bifurcation to the contiguous sides of the other four toes. The communicating branch from the dorsalis pedis artery besides completing the arch gives off an inner branch which supplies the inner side of the hallux.

EXTERNAL PLANTAR NERVE the deep portion of the nerve accompanies the artery under the adductor obliquus hallucis in which it ends. It gives small branches to the muscles which it supplies.

THE FOURTH AND FIFTH LAYERS OF MUSCLES consist of the plantar and dorsal interossei which will be seen better from the dorsum of the foot.

FRONT OF THE LEG AND FOOT. The superficial veins form an arch across the dor-

sum of the foot, and from this arise both the long and the short saphenous veins. On the outer side of the leg are a few cutaneous nervesderived from the external popliteal nerve. THE MUSCULO CUTANEOUS NERVE pierces the deep fascia about the lower third of the outer side of the leg and just before doing so divides into two branches, the inner gives branches to the inner side of the foot and the inner 2½ toes, the outer supplies outer side of the third, both sides of the fourth and the inner side of the fifth toe and gives a communicating branch to the external saphenous nerve. THE EXTERNAL SAPHENOUS NERVE winds round the external malleolus from the back of the leg and is distributed to the outer side of the fifth toe and joins with the musculo cutaneous nerve. THE ANTERIOR TIBIAL NERVE runs beneath the annular ligament and to the outer side of the dorsalis pedis arteryafter giving off articular and an external branch . The terminal branch receives a communication from the inner division of the musculo cutaneous and is then prolonged on the first dorsal interosseous to end by bifurcation to the adjacent sides of the first and second toes. THE IOTERNAL SAPHENOUS NERVE lies with the internal saphenous vein, it may be traced as far as the ball of the great toe..

THE FASCIA OF THE LEG is dense and white, at its upper part gives origin to muscular fibres. The

ANTERIOR ANNULAR LIGAMENT consists of two parts, one passing to the fibula from the tibia and having a separate synovial sheath for the tendon of the tibialis anticus while the rest of the structures pass beneath it, the other is attached externally to the upper surface of the os calcis and reaches by one or or more bands the inner malleolus and the inner row of tarsal bones. This latter part has three synovial compartments for three muscles, the tibialis anticus, the extensor longus hallucis and the extensor longus digitorum, with the latter passing the peroneus tertius, really a part of the digitorum.A similar band between the external malleolus and the outer surface of the calcis is called the external annular ligament and encloses the tendons of the peroneus longus and brevis. The extensor muscles are as follows, the tibialis anticus on the inner side, the extensor longus digitoru with the peroneus tertius on the outer side and the extensor longus hallucis between the others.

TIBIALIS ANTICUSOrigin, upper two-thirds of the outer surface of the shaft of the tibia and from its outer tuberosity, inner half of the upper two-thirds of the interosseous membrane, fascia covering the muscle and the septum between it and the longus digitorum. Fibres converge to form a broad tendon which passes thhough the most internal opening in the anterior annular ligament, Insertion. under surface of endocuneiform and base of metatarsal of first toe. Nerve, anterior tibial.

EXTENSOR LONGUS DIGITORUM Origin, upper three-fourths anterior surface of the fibula, an inch of the interosseous membrane and the outer tuberosity of the tibia, from the fascia over the muscle and the intermuscular septa on either side of itself. The muscular fibres extend low down and the tendon passes through the outermost division of the anterior annular ligament and at once divides into four tendons wtich pass to the four outer toes. Insertion, each tendon forms an expansion on the back of the first phalank and is there joined by a lumbricalis tendon or a corresponding interosseous tendon (usually the latter) it is then continued forward and divides into three portions, the central goes to the second phalanx, the laterals to the third. Nerve, ant-tibial.

THE PERONEUS TERTIUS, is really apart of the extensor longus digitorum and in many cases will be found continued to its proper insertion. Origin, below the extensor from the lower half or two-thirds of the anterior surface of the fibula, slightly from the interosseous membrane and from the septum between itself and the peroneus brevis. Its tendon passes through the same opening in the anterior annular ligament as the extensor and its Insertion is into the upper surface of the base of the metatarsal bone of the 5th. toe. When the muscle goes to its proper insertion it passes as a tendon of the extensor to the little toe. Nerve, anterior tibial.

EXTENSOR LONGUS; OR PROPRIUS, HALLUCIS. appears between the tibialis anticus and longus digitorum in the lower part of the leg. Origin, middle two-fourths of anterior surface of fibula, internally to the longus digitorum and from the interosseous membrane, its tendon crosses the anterior tibial vessels and nerve and passes through the annular ligament (or more correctly speaking, under it, Insertion, base of terminal phalanx of the halluk. It is joined opposite the proximal phalanx by expansions from the plantar muscles of the hallux. ..Nerve, anterior tibial.

EXTENSOR BREVIS DIGITORUM, Origin, upper surface of greater tuberosity of os calcis, from the interosseous calcaneo-astragaloid ligament and from the lower border of the anterior annular ligament. It ends in four tendons, the outer three passing obliquely across the foot to the second, third and fourth toes to be inserted with the general extensor aponeurosis, the innermost passing to a special attachment to the base of the proximal phalanx of the hallux. Nerve, anterior tibial. The extensor tendons are so arranged that each toe receives two except the little toe (it does when the peroneus tendon (tertius) passes to its proper insertion and does not exist as an "arrested tendon". The extensor expansion is just the same as in the fingers but is less marked.

THE ANTERIOR TIBIAL ARTERY is a branch of the popliteal and has been already noted at its commencement on the back of the leg. It reaches the front of the leg by piercing the interosseous membrane between the two heads of the tibialis postious and below the popliteus. It extends from the lower border of the popliteus to the lower border of the anterior annular ligament. It lies at first on the interosseous membrane between the tibialis anticus and extensor longus digitorum, then between the tibialis anticus and the extensor proprius hallucis, then being crossed by the hallucis lies between the longus digitorum and the hallucis. It passes beneath the anterior annular ligament and at the lower border of that ligament receives the new name of the dorsalis pedis artartery. It is accompanied by two venae comites. The anterior tibial nerve runs to its outer side as far as the middle third of the leg, then lies in front of it and in the lower third again lies to its outer side. A small lymphatic gland sometimes as found near the artery about the middle of the leg. Branches, Posterior recurrent articular and the superior fibular as already seen on the back of the leg then, after it has reached the front, the anterior tibial recurrent rises as soon as the artery reaches the front and ascends through the fibres of one of the muscles to enter the anastomosis with the articular arteries, muscular branches are given off and the internal and external malleolar, the latter being the more constant. The ANTERIOR PERONEAL BRANCH of the peroneal artery appears between the tibia and fibula through an open-

ing in lower part of the interosseous mebrane and separated by the inferior tibio-fibular joint from the posterior peroneal artery, it enters into the an astomosis with the external malleolar and tarsal arteries.

DORSALIS PEDIS ARTERY, is the continuation of the above artery and extends from the ankle joint to the base of the first metatarsal bone where it divides into the communicating branch to the plantar arch and the dorsal artery of the hallux. it has the anterior tibial nerve to its outer side, and has two venae comites. Branches, tarsal branches arise irregularly while the tarsal artery arises from the outer side of the vessel and anastomoses around the external malleolus. The metatarsal arises lower down and gives off three interosseous branches to the outer spaces, these run forward and bifurcate to supply the adjacent sides of two to es. the outer one also giving a branch to the outer side of the little toe. The communicating passes through the interosseous space as already described and the dorsalis hallucis gives a branch to the inner side of the hallux and then bifurcates to supply the adjacent sides of the first and second toes.

THE ANTERIOR TIBIAL NERVE, a branch of the external popliteal, arises in the substance of the peroneus longus and passes to the front of the leg under cover of that muscle and reaches the artery by piercing the extensor longus digitorum. It lies external to its artery above, on it in the middle and to its outer side again at the lower third of the leg. Its relations to muscles are the same as those of the artery. In the leg it supplies the four anterior muscles and at the lower border of the anterior annular ligament it divides into an inner and an outer branch, the inner supplies the first dorsal interosseous muscle and piercing the deep fascia is distributed to the first toe-cleft, the outer is distributed to the extensor brevis digitorum, the second dorsal interosseous and the articulations of the tarsus and metatarsus.

DISSECTION TO EXPOSE THE ANTERIOR TIBIAL ARTERY,, reflect the skin superficial fascia with the long saphenous, musculo cutaneous and branches of the external popliteal nerves, the deep fascia, then separate the pairs of muscles between which it lies, divide the tendon of the extensor proprius hallucis and cut the anterior annular ligament.

DISSECTION TO EXPOSE THE ANTERIOR TIBIAL NERVE, is the same as for the artery only in addition you have to cut the peroneus longus, the extensor longus digitorum and the extensor longus hallucis.

THE PERONEUS LONGUS,, Origin, slightly from the outer tuberosity of the tibia, from thehead and upper two-thirds of the external surface of the fibula, from the intermuscular septum on either side and the fascia covering it. It ends in a strong tendon which lies superficial to the brevis and runs behind the external malleolus and under the external annular ligament, then in a separate sheath of fascia along the outer side of the os calcis behind the peroneal tubercle to be Inserted into the outer side of the base of the first metatarsal bone on its under surface, running in the sole in a groove in the cuboid bone and in an osseo-fibrous sheath.(insertion is also very commonly also into the endocuneiform.) This sheath is formed largely by the long plantar ligament The tendon has a sesamoid bone where it plays on the cuboid,. Nerve, Musc.cut

PERONEUS BREVIS, lies beneath the longus, arises from the lower two-thirds of the outer suffface of the fibula and from the intermuscular septa, at the external malleolus its tendon is lodged in a groove below the longus, runs along

the outer side of the aclées in a sheath of fascia in front of the long tendon and peroneal tubercle and is inserted into the most prominent part of the tuberosity at the base of the fifth metatarsal. Nerve, musculo cutaneous.

EXTERNAL POPLITEAL NERVE has been seen running in close relation to the tendon of the biceps and entering the peroneus longus. It gives off a cutaneous branch before entering the muscle and then divides into three branches in the substance of the muscle, the musculo cutaneous, anterior tibial and a recurrent articular which passes to the front of the knee..

MUSCULO CUTANEOUS NERVE gives branches to the peroneus longus and brevis and then appears between the longus and the extensor longus digitorum finally becomes cutaneous by piercing the fascia in the lower third of the leg.

THE INTEROSSEI are seven in number, four dorsal and three plantar, the dorsals are between the bones while the plantar lie towards their lower surface. The four dorsals arise from the adjacent sides of the metatarsal bones and are inserted so as to abduct from an imaginary line drawn through the middle of the second toe and into the extensor expansion. The plantans arise from the inner sides of the third, fourth and fifth metatarsals and are inserted into the corresponding sides of the first phalanges and the extensor tendons. They are thus adductors towards the middle line of the second toe.. Nerve, the deep branch of the external plantar except those in the fourth space which are supplied by the superficial and the two inner dorsal which are supplied by the anterior tibial.

Homologues in the Arm and Leg.

The clavicle	corresponds to	Poupart's ligament.
The Scapula	----------	Os inominatum
Humerus,	----------	Femur,
Radius,	----------	Tibia,
Ulna,	----------	Fibula
Scaphoid and semilunar,	----------	Astragalus
Cuneiform and pisiform,	----------	Os calcis
Trapezium,	----------	Entocuneiform
Trapezoid,	----------	Mesocuneiform
Os magnum,	----------	Ectocuneiform
Unciform,	----------	Cuboid
Os centrale (in apes)	----------	Scaphoid.

Joints of the leg.

The HIP JOINT. is an enarthrosis. It consists of the acetabulum and the head of the femur. The acetabulum is deepened by the cotyloid ligament.. Ligaments Capsule, attached to the margin of the acetabulum and to the neck of the femur just internal to the trochanter. This capsule has a weak point below and in it we find three distinct bands, the ilio-femoral, the pubo-femoral and the ischio-femoral. On opening the hip joint we find the ligamentum teres, this, like the ilio-femoral band is shaped like a "Y". To mark the attachments of this ligament the borders of the cotyloid notch are taken. The ligamentum teres limits flexion, adduction and external rotation. It is the remains of a muscle which is still existent in the ostrich. On the neck of the femur, within the joint are fibrous bands and these constitute the ligamentum reflexum. The

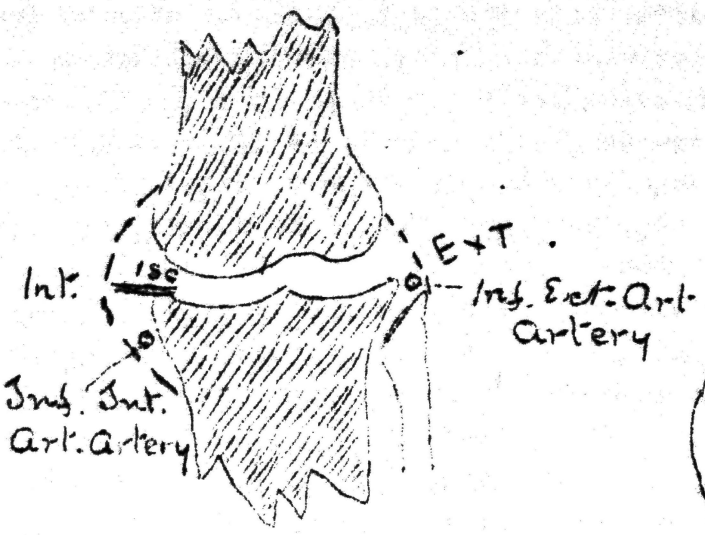

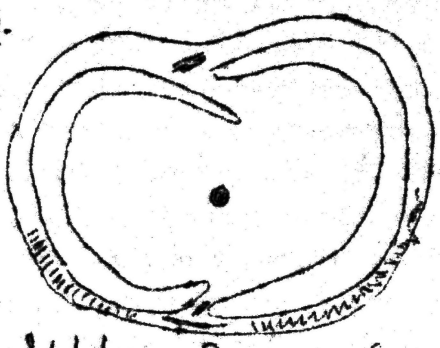

Upper End of Tibia.

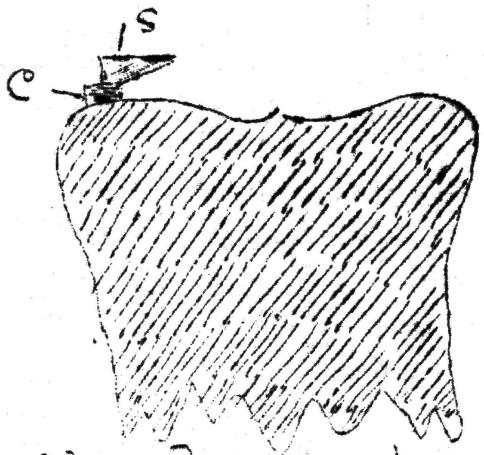

Attachment of Semilunar.

synovial membrane is very extensive and at the bottom of the socket is a pad of fat, Haver's gland, to protect the vessels of the joint, this is held in position by a delicate membrane derived from ligament. The arteries to the joint are from the obtunator and the circumflex in the buttock. The nerves are obturator, sciatic, anterior crural and the nerve to the quadratus. Movements are seven in number, Flexion by the psoas, iliacus, pectineus and rectus. Extension by the gluteus maximus and medius and the hamstrings. Adduction by the weight of the limb, the pectineus, the three adductors, the quadratus and to some extent by the gracilis and sartorius. Abduction by the three glutei. External rotation, obturator externus and internus, the gemelli, the gluteus maximus, the quadratus femoris, psoas and iliacus and pyriformis. Internal rotation by the gluteus medius and minimus and the tensor vaginae femoris. Circumduction by all the muscles.

THE KNEE JOINT is a condyloid joint, the movements of the joint are flexion, extension and rotation in the semi-flexed position. The bones entering into the formation of the joint are the femur, tibia and patella. The ligaments of the joint are divided into external and internal, thus,

External ligaments, Capsule, anterior, posterior, internal lateral, external lateral. Internal ligaments, (cartilagincus) semilunars, (Fibrous) coronary, transverse and crucials. (synovial) ligamentum mucosum, ligameota alaria. The capsule is weak at three points, on either side of the patella and under t e crureus. The aoterior ligament is formed largely by the ligamentum patellae. The posterior ligament (ligament of Winslow) is very broad and is largely derived from the tendon of the semimembranosus. The internal lateral is four inches in length and is attached to the condyle of the femur, the internal semilunar cartilage and the shaft of the tibia. The external lateral is double, consists of long and short. Both are attached to the condyle, the short is posterior and goes to the styloid, the long goes to the external surface of the head and it splits the tendon of the biceps. The arteries of the knee are seven in number, they are the superior internal and external, inferior internal and ex.ernal and azygos articular, the recurrent tibial, the external circumflex (descending branch). On the upper surface of the head of the tibia from before backwards are attached the following structures, the transverse ligament, the internal semilunar cartilage (anterior portion) the anterior crucial, the external semilunar (anterior part), we now reach the spine of the tibia, behind it we come upon the posterior part of the external semilunar cartilage, the posterior part of the internal semilunar cartilage and the posterior crucial ligament. The semilunar cartilages are formed of fibro-cartilage and are attached by their margins only. They are attached by the coronary ligaments. They act as bumpers and being freely mobile they also serve to constantly keep the femur in contact with the tibia. The coronary ligaments are little fibrous bands while the transverse ligament connects the anterior extremities of the semilunar cartilages. The crucial ligaments are anterior and posterior and exist for two reasons, to prevent over-extension of the knee and to limit rotation, especially internal. The anterior is attached below in front of the spine of the tibia, it passes upward to be attached to the posterior part of the inner surface of the external condyle, while the posterior is attached below to the tibia behind the spine and above passes to the anterior part of the outer side of the internal condyle. They are

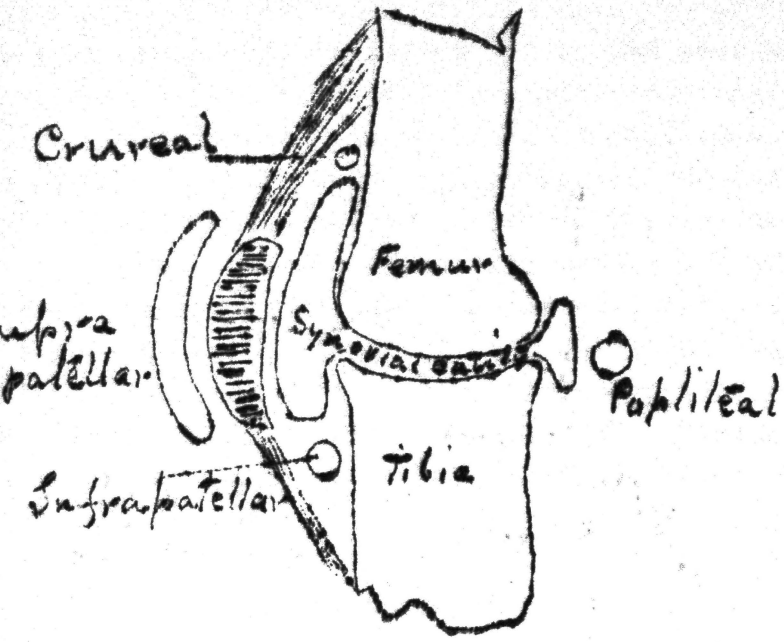



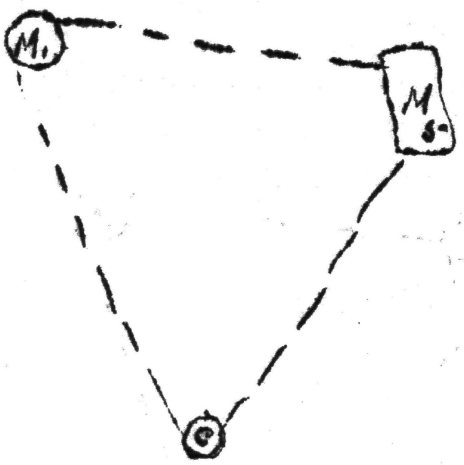

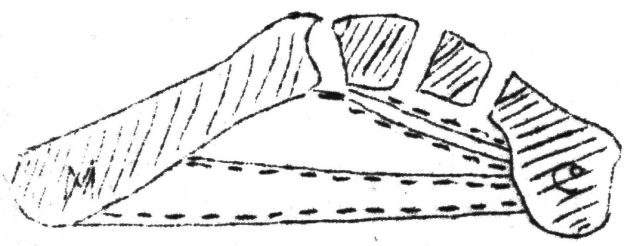

Antero-posterior Arch of Foot

connected together and cross each other doubly and lie in a synovial tube. The ligamentum mucosum is a triangular fold of synovial membrane whose base is at the apex of the patella and the apex in the intercondyloid notch. The ligamenta alaria are the margins of the last which are often loaded with fat.. The knee joint has three fat pads, the popliteal, the infrapatellar and the suprapatellar. The Nerves to the knee are as follows, branches from the nerves to the vastus internus and externus, the superior internal and external articular, the inferior internal and external articular and the two azygos articular There are 9 bursae in connection with the joint, four of which are important. they are the bursa patellae which is attached to t e periosteum, the infra-patellar which lies under the ligamentum patellae, the sub-cruroal and the bursae of the popliteal space. The synovial membrane is the most extensive in the entire body.

THE TIBIO-FIBULAR JOINTS, are three in number, the Superior, is a gliding join has a capsule and an anterior and posterior ligament. The Inferior is also a gliding joint and has anterior and posterior ligaments, an interosseous ligament and a transverse, the last being attached to both bones behind.. The Middle joint has no movement and is formed by the fibres of the interosseous membrane, the fibres of which run downward and outward and prevent the displacement of the fibula, further, the length of the external malleolus is such that it keeps the foot well bound outawd, it is characteristic of man, hence Pott's fracture only occurs in man.

THE ANKLE JOINT. Bones are astragalus, tibia and fibula. It is a ginglymus joint. The movements are flexion and extension, and in extreme extension of the joint we have a slight "goggling" motion owing to the narrowness of the astragalus posteriorly. The ligaments of the joint are Anterior, weak; Posterior, weak, generally replaced by the transverse of the inferior tibio-fibular joint; External lateral, three bands, all attached to the malleolus, the anterior and posterior going to the astragalus, the middle to the calcis.; Internal lateral, deltoid in shape, is attached by its apex to the inner malleolus and by its base to the scaphoid, calcis and astragalus. The extensors of the joint are the gastrocnemius, soleus, plantaris, tibialis postious, peroneus longus and brevis and the long flexors of the toes. The movement of extension is far better termed plantar flexion. The movement of flexion, (or better dorsi-flexion) is produced by the tibialis antious, peroneus tertius and the long extensors of the toes.

THE JOINTS OF THE FOOT are divided into two sets, Intertarsal and Tarso-metatarsal. The ligaments of the foot are Dorsal, irregular bands; Plantar, irregular bands three of which are large and named, Long plantar, from the under surface of the calcis between the tuberosities, runs forward and is attached to the cuboid and the bases of the second, third and fourth metatarsals and to the peroneal sheath; Short plantar, lies under cover of the last, it is attached to the posterior tuberosity of the calcis and in front to the cuboid; Inferior calcaneo-scaphoid which stretches from the sustentaculum tali to the scaphoid, the upper surface being free. Interosseous ligaments are ten in number and we have six synovial membranes. The mid-tarsal joint divides the foot into two segments an anterior and a posterior. At this joint we have inversion and eversion of the foot occurring. Eversion is the more easy. The muscles which produce inversion are tibialis antious and postious, the peron-

ei. The human foot is a bony tripod. The tread is in the line of the heads of the metatarsal bones. There are two arches in the foot, one antero-posterior the other transverse. The pillars of the antero-posterior arch are the calcis and the heads of the first and second metatarsals with the sesamoid bones, the pillars are fixed by the plantar fascia and the long and short plantar and inferior calcaneo-scaphoid ligaments as also by muscles. The transverse arch is mainly maintained by the tendon of the peroneus longus.

THE METATARSO-PHALANGEAL JOINTS are the same as in the hand, as also are the INTER-PHALANGEAL JOINTS-

End of THE LEG.

THE THORAX

The thorax is a pyramidal cavity whose apex is the superior aperture, whose base is formed by the diaphragm and the sides of which are formed by the 12 dorsal vertebrae, 12 pairs of ribs with their cartilages, the sternum, ligaments and intercostal muscles.

EXTERNAL INTERCOSTAL MUSCLES are 22 in number, and extend from the tubercle on the rib to the costal cartilage. THe fibres downward, forward inward. They are attached to the lower and upper borders and outer surfaces of the adjacent bone beyond the junction of the rib to the cartilage their place is taken by a thin fascia whose fibres have the same direction as the fibres of the muscle.

INTERNA INTERCOSTAL MUSCLES, take a direction the opposite of the external. Extend from the angles of the ribs to the extremity of the cartilages. The muscles are attached to the upper and lower borders of adjacent ribs and encroach slightly on the inner surfaces of the ribs. In the last two spaces the muscle goes to the end of the rib.

INTERCOSTAL NERVES are 11 on each side, each is the anterior primary division of a dorsal nerve. They run between the membrane, which behind the angle of the rib takes the place of the internal intercostal muscle, and the external intercostal, then they run between the two muscles, and at the anterior extremity of the space run internally to the internal intercostal muscle. Each gives off a communicating branch to the sympathetic, muscular branches to the intercostal and other muscles and lateral and anterior cutaneous branches. In the first nerve we have no lateral branch, and in the second the lateral cutaneous becomes the intercosto-humeral. The lower 5 or 6 nerves having passed along the spaces pass behind the cartilages, run in the abdominal wall between the transversalis and internal oblique then, piercing the posterior layer of the sheath of the rectus, pierce the rectus, the anterior layer of the sheath and supply the muscles of the abdominal wall.

THE INTERCOSTAL ARTERIES are really 22 in number, but only 18 are derived from the thoracic aorta, the upper two on each side being derived from the superior intercostal, a branch of the subclavian. The arteries come off from the back of the aorta, they lie at first between the external muscle and membrane, then between the two muscles, then between the internal muscle and membrane. The right arteries are longer than the left, the aorta lying to the left of the middle line of the body in this region.

THE INTERCOSTAL VEINS open into the venae azygi and the lymphatic are connected with sternal glands. In each intercostal space from above downward we find vein, artery, nerve, except in the first one or two spaces where the order is artery, vein, nerve. Both vessels and nerves are very small.

THE MAMMA OR BREAST is characteristic of mammalia, they are asymmetrical and are found on the vectral aspect of the body. Supernumerary breasts are recorded, as many as six have been found, the position varying, the abdomen, axilla groin and buttock. Every child male or female is born with breasts, and in the infant these are similar in both sexes, a few ducts surrounded by a fibrous stroma, the nipple being quite rudimentary. At puberty the female breast undergoes an enormous change and is enlarged, and it is studied under three distinct conditions. First, in the woman who has never borne children. Here the breast is rounded, is convex on the anterior surface and usually concave on the posterior. Usually symmetrical. The position of the breast in tall wo-

men the breast is low and in small women it is high up. It extends from about the lower border of the second rib to about the lower border of the 6th. costal cartilage. It extends from nearly the middle of the sternum to the mid-axillary line. The breast is firm, elastic and rounded. Large breasts do not of necessity mean robust health. Anatomy, the breast is developed in the superficial fascia and is everywhere surrounded by it. It is connected to the pectoral fascia below and also to the skin which covers it, it is surrounded by fat which also lies on its anterior surface but is never found on the posterior The breast consists of two parts, a central which is solid and is called the corpus mammae, is firm and pinkish, and peripheral processes which stretch indefinitely into the surrounding fat, are also found behind the breast and even under the pectoral fascia. The corpus mammae is divided into some 20 lobes which are bound together by fibrous tissue. Each lobe consists of first, mil ducts, second, branching ducts from these, these branching ducts pass to the peripheral processes and end in tubular acini where the milk is secreted. Each acinus is tubular and lined by granular epithelium and is surrounded by capillaries and lymphatics. The above constitutes the parenchyma of the breast. The second constituent of the breast is stroma which is firm, fibrous and elastic and binds all the lobules together. Third, we have fat, which never exists diffusely, but in small separate lobules. Just below the middle of the breast is the nipple, a small conical eminence which points upward and outward. The nipple has no fat under it and lies over the 4th. interspace, in inspiration over the 5th. It is surrounded by the areola which is about half an inch broad and both nipple and areola are rosy pink, but this varies with the complexion of the woman, pigment being present in both. Up till puberty the nipple is smooth then it becomes wrinkled. Near the base and over the areola are small elevations which are caused by the presence of small glandular masses, Montgomery's glands, these become enormous during pregnancy and lactation and secrete a sebaceous material which protects the nipple from the juices of the mouth of the child. The nipple is very vascular and sensitive and contains a large amount of non-striate muscle hence under an irritant becomes erect. The arteries of the breast are derived from the Acromio-thoracic, Long thoracic, Internal mammary and the intercostals. The veins correspond to the arteries but in addition we have a circulus venosus round the nipple. The lymphatics are divided into 5 sets, skin lymphatics which drain the nipple, areola and skin; stromal lymphatics; intra-mammary lymphatics; retro-mammary lymphatics and the lymphatics of the surrounding fat. The axillary glands are over 40 in number, they are small and should not be felt. They are divided into . sets, those which lie with the axillary artery, drain the arm; those with the long thoracic artery, drain the mamma; those with the subscapular artery which communicate with the back; The nerves of the breast are lateral and anterior branches of the intercostals also a few branches from the superficial cervical plexus. Second, Breast of pregnancy, the nipple and areola swell, are darkened in color and tuberculated on the surface. The breast enlarges and on the surface are seen large veins. The enlargement is due to budding. The alveolar epithelium proliferates and becomes fatty, the cells break down and the resulting fluid is milk, an emulsion. The breast of a woman can contain about two ounces of milk.. Third, the breast after lactation, the nipple and areola always remain stained. The breast is flabby due to an enormous increase in the fat in the stroma. After lactation it becomes loose due to a special layer of fat developed under it.

After the menopause the breast atrophies, being largely replaced by fat and sometimes only the duct remains, cysts are very common and a thin old women has a plate shaped breast. In fat women the breasts are very pendulous. The breast is especially liable to disease owing to its functional activity. Male breast at the age of puberty the male breast becomes swollen and painful and sometimes a slight discharge occurs from the nipple. The breast is a modified sebaceous gland. Accessory breasts are sometimes found.

RECTUS STERNALIS, always occurs on one side only, it is an almost vertical muscle which runs along one side of the sternum, is probably a separated portion of the pectoralis major. On removing a window from the front of the thorax. THE TRIANGULARIS STERNI is seen, its Origin is from the inner surface of the ensiform cartilage and lower portion of the sternum and from the cartilages of the last two or three true ribs, Insertion, into the upper costal cartilages Its idigitations pass behind the internal mammary vessels. Expiratory muscle. THE INTERNAL MAMMARY ARTERY is a branch of the subclavian passes into the thorax through the superior aperture, having been crossed by the phrenic nerves. It runs down parallel with the outer border of the sternum, from a half to one inch from it, superficially to the triangularis sterni. At the level of the 6th. costal cartilage it divides into its terminal branches, the superior epigastric and the musculo phrenic, the former passing through the sternal triangle enters the sheath of the rectus and anastomoses with the deep epigastric, the musculo phrenic supplies the diaphragm and anastomoses with the phrenic branches of the abdominal aorta. The other branches of the internal mammary artery are the comes nervi phrenici, mediastinal and pericardiac branches, anterior intercostals, two to each of the upper six spaces and perforating branches, to the pectoral muscles, the mamma and the skin.

THE PLEURAE are two shut sacs of serous membrane lining the thorax and covering the lungs. The pleura can be traced over the inner surface of the sternum and ribs, (the costal portion,) to the back of the root of the lung forming the lateral boundary of the posterior mediastinum, (mediastinal portion) thence around the lung, (pulmonary portion) to the front of the root from which it passes on to the pericardium (pericardial portion) and is carried forward to about the middle of the sternum where it becomes continuous with the costal portion. If the lung be drawn out, below its root will be seen a fold of pleura called the ligamentum latum pulmonis connecting the lower lobes with the side of the pericardium and the diaphragm. The pleura is reflected on the upper surface of the diaphragm below (diaphragmatic layer) and above is continued to a greater or less extent into the neck through the superior aperture of the thorax (cervical portion). The right pleura is shorter but wider than the left.

THE MEDIASTINUM is the region of the middle line of the thorax, may be described as the space between the pleurae. It is bounded in front by the sternum, and behind by the 12 dorsal vertebrae. It is sub-divided into four and is bounded below by the diaphragm, above by the superior apertuhe of the thorax. A vast amount of time and trouble have been wasted on attempting to memorise the contents of these four artificial regions, it is simplest to remember that the anterior mediastinum is that portion of the middle line of the thorax lying in front of the heart, the posterior is that portion lying behind the heart, while the middle mediastinum contains the heart enclosed in the pericardium and the roots of the lungs, the superior is that portion of the mediastinum which lies above the level of the base of the heart. Remembering

this it will not be difficult to say in which of the mediastina any structure lies provided its general position in the thorax is known..

THE PERICARDIUM is a fibro-serous sac, pyramidal in shape, apex upward. The outer or fibrous layer is strong and its base is firmly attached to the upper surface of the central tendon of the diaphragm from end to end, and partly to the muscle on the right, still more so on the left. The apex is lost on the sheath of the large vessels, the aorta and pulmonary artery. It contains the heart lying base upward. . The fibrous layer receives a band of fibrous tissue from the deep cervical fascia in front, and it is connected to the sternum and spine by fascial ligamentous processes. Its outer surface gives attachment in the greater part of its extent to the pleurae which leaves a small portion uncovered in the middle line posteriorly, and a very narrow anterior mediastinal space to the left of the middle line in front. This last usually lies to the left side of the lower third of the meso-sternum. The serous layer is like all other such membranes in having visceral and parietal reflections. The parietal covers the inner surface of the fibrous layer, while the visceral is reflected over the heart and the roots of all the vessels, extending as a common tube enclosing the aorta and pulmonary artery for a distance of abouttwo inches from their origin. It also invests the superior vena cava, but the inferior is only covered in front, the posterior portion of the vessel being blended with the fibrous pericardium. The reflections of the serous pericardium are very complex and not of importance.

THE PHRENIC NERVE arises from the 4th. and 5th. cervical nerves usually with a branch from the 3rd. It lies upon the scalenus anticus which it crosses from within outward, reaching the 1st. stage of the subclavian artery it crosses it as also the internal mammary artery and runs in front of the root of the lung. It pierces the muscular substance of the diaphragm and supplies that muscle on its under surface, the right also giving a few branches to the upper surface of the liver. The nerves give branches to both sides of the pericardium as also to the pleurae. With each nerve goes the comes nervi phrenici artery.

THE ROOTS OF THE LUNGS are each formed of a pulmonary artery, two pulmonary veins and a bronchus, with bronchial vessels, the anterior and posterior pulmonary plexus of the vagus and sympathetic and some lymphatics, all bound together by connective tissue. The three principal structures lie in the same order from before back on both sides of the body, veins, artery, bronchus, from above downward on the right side the order is reversed owing to the presence of a large ep-arterial bronchus given off from the bronchus to the upper lobe of the lung, so that the order would be bronchus, artery, vein, on the left side the order from above down is artery, bronchus, vein. The root of the right lung lies in relation in front to the superior vena cava and phrenic nerve, behind the vena azygos major and the vagus while the vena azygos major curves over it to open into the superior vena cava. The, left root has in front the phrenic nerve, behind the descending aorta and the vagus, above the horizontal arch of the aorta and the recurrent laryngeal nerve.

THE LUNGS vary much in shape, condition, color and weight in various individuals. Each lung consists of several parts. The apex goes 1½ into the neck, is blunt and is held in position by a process of deep fascia, Sibson's fascia. The base rests on the diaphragm and is concave with sharp margins. The external surface is moulded to the thoracic wall is strongly convex and marked by oblique lines corresponding to the intercostal spaces and by a long oblique fissure.

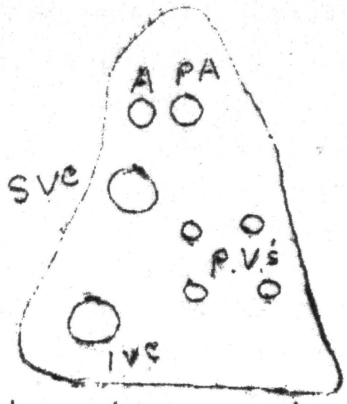

Openings in Pericardium.

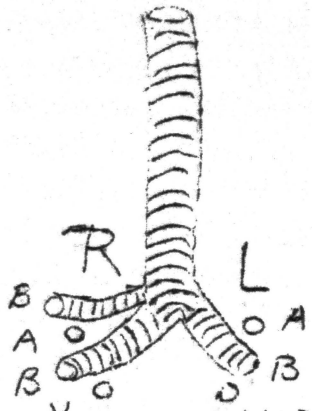

Roots of Lungs

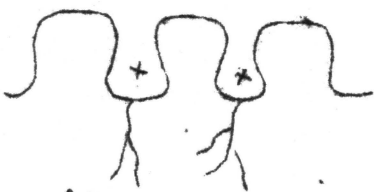

×× Foramina Thebesii

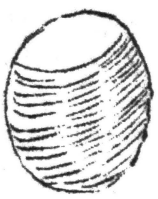

Foramen Ovale

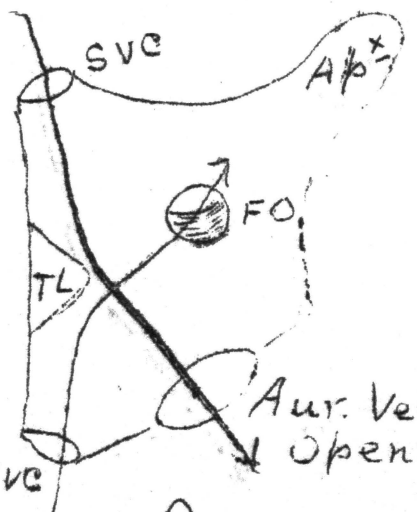

Tubercle of Lower - shewing function in Foetus -

running from a little below the apex at the back to the lower part of the anterior border in front. In the right lung the portion above this fissure is again divided by a second deep fissure, passing almost horizontally forward from the middle of the oblique fissure to the anterior margin. The internal surface is small and concave and shows the hilus or root of the lung, and may be divided up into the several portions of the mediashinum. In a lung hardened and modelled from after the method of His the markings are distinctly to be seen of the various structures which laid in contact with the soft, impressible lung tissue. The anterior border of the right lung is very sharp and straight, that of the left is also sharp but is not so straight being "scolloped" out by the presence of the heart. The posterior border of the lungs is blunt and rounded. The anterior border of the right lung extends as far down as the 6th. costal cartilage, the aoterior border of the left is straight as far as the 4th. costal cartilage when it describes a curve outward and again appears in the middle line at the junction of the 7th. costal cartilage with the sternum. This proce s is called the proce sus lingualis. Each lung presents a great oblique fissure as already mentioned. The left lung in longer than the right but the right is broader and thicker and has a greater air capacity..

THE HEART is a four-chambered muscle about the size of a closed fist, it consists of a base, a body and an apex. The base lies opposite the 5th. to the 8th dorsal vertebrae, the apex lies in the 5th. left interspace, 3½ inches from the middle line of the sternum. The heart lies base up, it has two obliquities and one rotation, the obliquities are downward and forward and downward and to the left, the rotation is to the left, this is the anatomical rotation in virtue of which the physiological rotation to the right takes place at each ventricular systole. There are 8 openings in the pericardium, two for the venae cavae, four for the pulmonary veins one each for the pulmonary artery and aorta. RIGHT AURICLE, the larger of the two, contains venous blood and is divided into two parts, one small with rough walls, the auricular appendix, the other large with smooth walls, the sinus venosus. The appendix is rough owing to the presence of of musculi pectinati, the walls are very thin, but rupture never occurs in this part of the heart. The sinus venosus shows the orifice of the superior vena cava, valveless, the inferior vena cava provided with a valve which, in the adult, is of no value, the valve of Eustachius. The tricuspid, or right auriculo ventricular opening, guarded by the tricuspid valve, the orifice of the coronary sinus guarded by the valve of Thebesius, the foramina Thebesii, valveless the fossa ovalis, surrounded by an indistinct ring the annulus ovalis, and the tubercle of Lower, best seen in infants. The valve of Eustachius is a fold of endocardium continuous with the anterior margin of the annulus ovalis. The tricuspid orifice admits three fingers. The coronary sinus is the dilated mouth of the great cardiac veins and its valve, a fold of endocardium, is quite incomplete. The foramina thebesii are little crypts in a depression of the heart substance, into some of them open the venae minimae cordis. The fossa ovalis is an oval depression in the inter-auricular wall, in the adult it is usually closed but in one case in about four a small opening may be found. In the foetus this is an opening between the right and left auricles, the foramen is open at the upper part and is then called the foramen ovale. Should the opening persist to a marked degree the condition is very serious owing to the mixing of venous blood with arterial, it then constitutes one of the forms of malformation of the heart. The tubercle of Lower only exists in the foetal heart, it

Semilunar valves

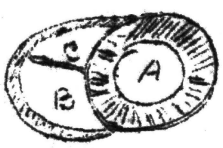

A Cavity of L. Ventricle
B " " R "
C "Moderator Band"

lie a little eminence on the wall of the right auricle between the openings of the superior and inferior vena cava.

RIGHT VENTRICLE, has a relatively thin wall, is divided into two parts, one is large and rough, the ventricle proper, the other is small and smooth, the conus arteriosus. This latter is near the pulmonary artery's orifice. The ventricle proper is rough owing to the presence of columnae carneae of which we find 3 varieties, a mere elevation, a bridge and musculi papillares. In the right ventricle there are usually two true musculi papillares, but a third is commonly present taking origin from one of the two main musculi. The anterior muscular papillaris is large the posterior is small, is the one which is usually the origin of the third. The chordae tendineae are fibrous cords, covered with endocardium and they are distributed to the margins of the cusps and also to their deep surfaces. Although there are three cusps in the tricuspid valve and only two chordae tendineae commonly, the remaining chordae take their attachment from the interventricular septum. There are two openings into the ventricle, the tricuspid and the orifice of the pulmonary artery. A cuspid valve is one where the segments are arranged like fangs, the base of the fang being the line of attachment. There edges and apices are thus free. Each cusp is a double fold of endocardium, strengthened by a layer of fibrous tissue which lies between them. The tricuspid valve has really six cusps as between each pair of the regular cusps there is a small secondary cusp. The tricuspid valve prevents regurgitation inti the auricle doring ventricular systole, this valve in distended conditions of the heart allows of a slight regurgitation, it sometimes receives in consequence the title of safety valve of the heart. The orifice of the pulmonary artery is guarded by the pulmonary semilunar valves, a lunate fold is formed of a double layer of endocardium, strengthened by fibrous tissue, these little folds are attached by their margins and their bases are turned upward and are free. behind each is a slight dilatation of the wall of the vessel, this is called a sinus of Valsalva and these are best marked in the aorta. The fibrous tissue in these lunate folds is arranged like the spokes of a wheel, radiating from a little fibrous nodule in the free margin, this little fibrous nodule is called a corpus Aurantii. When the valve closes tae three corpora aurantii all lie together in the center at the point of meeting. The right ventricle is specially liable to become gorged with blood, and in the ventricle we find a special structure which when first described was supposed to prevent the wall becoming over-distended. The moderator band, as this was therefore called, is an oblique band of muscle fibre stretching from the base of the anterior papillary muscle upward and inward and ending on the fore-part of the interventricular septum.

LEFT AURICLE is smaller than the right, lees somewhat behind it, like the right it is divided into two parts, the appendix with musculi pectinati like the teeth of a comb or the fingers of a gloove, and the sinus venosus which is smooth and shows the orifices of three, four or five pulmonary veins which are valveless, the mitral orifice admits two fingers and leads from the auricle into the ventricle, we also see the fossa ovalis with the annulus which we saw from the other side in the rightauricle, also a few foramina thebesii.

LEFT VENTRICLE, its walls are three times as thick as the walls of the right, it is divided into two parts, the ventricle proper which has rough walls due to

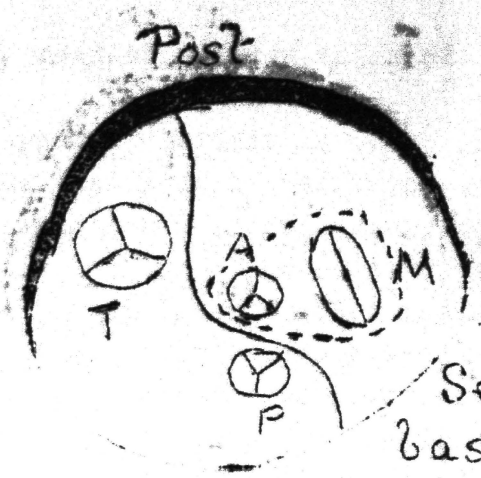

Section through base of heart shewing position of valves

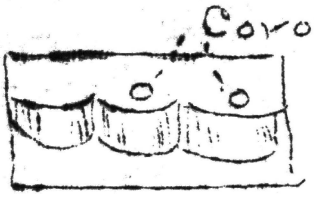



Arch.

(See page 52)

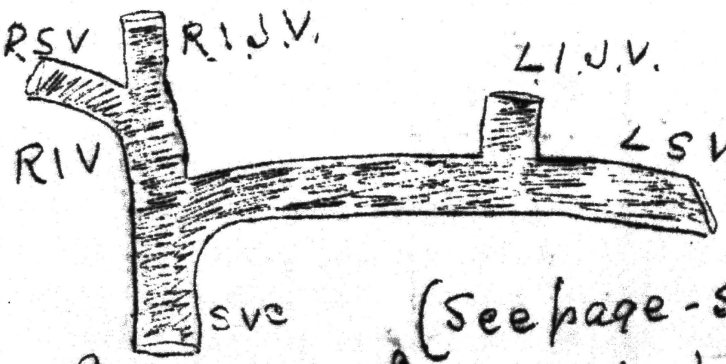

(See page-52)

Formation of Innominate veins and Sup-Vena Cava-

columnae carneae in the form of elevations, bridges and musculi papillares from which chordae tendineae are distributed exactly as in the right ventricle, and the conus arteriosus, wtich is a small smooth part leading to the aorta. The mitral valve has two cusps of which the anterior is the larger and is the largest cusp in the heart. In the case of the pulmonary and aortic semilunar valves we note that the unpaired segments lie together. The heart muscle consists of a peculiar form of muscle tissue which is intermediate in structure between striate and non-striate. The myocardium, or muscle substance of the heart is built up of these fibres arranged in an extesmely complex manner. The fibres are in some 7 layers and some are peculiar to the auricles, some to the ventricles, some belong to both ventricles, some to both auricles,. Fibrous tissue is found in various regions, most prominently in the neighborhood of the auriculo-ventricular septum where it forms fibrous rings for the valve openings. If the heart be boiled the fibrous rings drop out and this fibrous tissue is so closely applied around the orifices of the aorta and mitral aperture that these two come out in one piece and one hole is left. The myocardium of the heart is supplied by the two coronary arteries. These are given off from the first part of the ascending aorta, immediately after its commencement, just above the anterior and left lateral sinuses of Valsalva. The coronary artery, right or left, always lies in the auriculo ventricular groove, they give off interventricular, inter-auricular and ventricular branches. These all run on the surface of thex heart. The blood is returned from the heart in two ways, directly into the auricles through the foramina thebesii and by a series of superficial veins which run on the surface of the heart especially its posterior surface. The coronary sinus is a sac into the base of which some of the veins open. The Nerve supply of the heart consists of a complex mechanism which is not completely understood, first we have inthinsic ganglia which lie chiefly in the auriculo-ventricular groove, Remak's ganglia and a series in the interauricular groove, the ganglia of Bidder. These ganglia are connected together by a series of nerve fibres which are acted upon by three nerves which are indirectly derived from the vagi and the sympathetic nerves in the neck through the cardiad plexuses, superficial and deep.. The three nerves are the cardio inhibitory, the cardio accelerator and the sensory or depressor. Of these the cardio inhibitory, the vagus, is constantly in action so that if it be divided the accelator is allowed full play and the heart will beat more rapidly, on the other hand if we divide the accelerator, the sympathetic, no effect is at once noticed as it is now constantly in action; if the depressor be divided the heart will beat more rapidly. Irregularity in the heart beat may be either functional or organic. The Precordia is that part of the heart which is uncovered by lung and lies against the anterior chest wall. It is a small triangular surface about two inches in diameter lying between the 5th. and 7th. ribs on the left of the sternum. It usually corresponds fairly closely to a circle described with a center halfway between the ensiform cartilage and the nipp

THE PULMONARY ARTERY is about two inches in length and extends from the conus arteriosus of the right ventricle to the concavity of the arch of the aorta. At first it lies to the left and in front of the aorta and passes upward, backward and to the left, a somewhat spiral course, and divides just under the concavity of the arch of the aorta into right and left pulmonary arteries. It carries the venous blood to the lungs, it is an artery because it carries blood from the

heart and because it has the structure of an artery. Relations, anteriorly pericardium, posteriorly the first part of the aortic arch and on either side an auricular appendix and a coronary artery, in addition to the right the aorta. From the left division there extends to the descending aorta a little fibrous cord, the remains of the ductus arteriosus which about the 8th. day after birth closes. In the foetus this is a large wide tube which conveys the blood which ought to go to the lungs but is now not need there for purification into the aorta.

THE PULMONARY VEINS, are typically four in number, two for each lung and they open into the left auricle. The right veins are the longer and pass beneath the arch of the aorta, the left veins crossing the front of the descending aorta. Occasionally the two veins for a lung unite to form a single vein, in other cases there may be three veins for the right lung, we may thus have 3 4 or 5 veins as already mentioned.

THE ARCH OF THE AORTA. The aorta arises from the left ventricle and at first takes a course upward forward and to the right, then backward and slightly to the left, over the root of the left lung and round to the left of the trachea. For convenience the arch is divided into three portions, ascending, transverse (which would be more properly called anterOposterior) and descending. The arch extends from the base of the heart, from the middle of the sternum opposite the 3rd. costal cartilage, to the lower border of the 5th. dorsal vertebra. The ascending portion extends from the base of the heart at the point above indicated to the upper border of the right second costal cartilage where it joins the sternum. The direction of this paortion of the arch is upward, forward and to the right. Relations, Anteriorly, the pulmonary artery, pericardium and the right auricular appendix. Posteriorly, we have the root of the right lung. To the right side is the right auricle with the superior vena cava while to the left is the pulmonary artery. The Transverse portion extends from the upper border of the 2nd. right costal cartilage to the lower border of the 4th. dorsal vertebra. The directiin is upward, backward and a little to the left. Relations, Anteriorly, left phrenic, left vagus, cardiac branches of the vagus and sympathetic, and the left superior intercostal vein. NOTE, owing to the antero posterior direction of the transverse portion of the arch these structures while lying anterior are much more truly to the left of this portion of the artery. Posteriorly (or to the right) are the oesophagus, the thoracic duct, and the left recurrent laryngeal nerve. Above, we have the branches of the aorta and the left inominate vein, while below are the root of the left lung and the superficial cardiac plexus The descending portion of the arch lies pasted up against the left side of the vertebral column and extends down the length of the 5th. dorsal vertebra. to its left holding itin position is the left pleura, which also lies behind it, in front are the vagus, pleura and lung, on the right the vertebral column, oesophagus and thoracic duct.

THE SUPERIOR VENA CAVA is 2½ inches long. It is almost vertical with a slight convexity to the right. It is formed by the junction of the two inominate veins and ends in the sinus venosus of the right auricle. Its lower half is enclosed in pericardium. Relations, Anteriorly pleura and the right appendix Posteriorly, the riot of the right lung and the vena azygos major, to the

right the pleura and the right phrenic nerve and to the left the 1st. part of the aortic arch. It receives the vena azygos major just above the root of the right lung.

The second part of the arch of the aorta gives off three great vessels.

THE INOMINATE ARTERY generally begins on the left of the middle line of the body. It passes obliquely upward and to the right, dividing into the right common carotid and the right subclavian behind the upper border of the right sterno-clavicular joint and between the two heads of the sterno-mastoid. It is about an inch and a half long and lies surrounded by the connective tissue of the mediastinum. It is crossed nearly at right angles by the left inominate vein and obliquely by the right inferior thyroid vein. Behind it, near its origin are the trachea and the root of the left common carotid artery (owing to the antero-posterior position of the transverse aorta), afterward the prolongation of the right pleura into the neck. To the right are the pleura and lung, right inominate vein and right phrenic nerve, to the left the inferior thyroid veins and the the trachea. The artery commonly gives off no branch but occassionally the thyroidea ima, a small branch to the thyroid, arises from it or the aorta close to it.

LEFT COMMON CAROTID leaves the arch on the left of the middle line, runs up and to the left at a level anterior to that of the subclavian. The thoracic portion of the artery has in front thhe manubrium sterni with the remains of the thymus gland, the origins of the sterno-hyoid, thyroid muscles, the root of the inominate artery and the commencement of the left inominate vein. It li lies upon the root of the subclavian artery, the trachea and the left border of the oesophagus and thoracic duct a little higher up. To its right are the inominate artery, inferior thyroid vein, ~~left vagus with~~, the trachea and the left recurrent laryngeal nerve, to its left are the left pneumogastric with its cardiac branches and the left pleura and lung.

THE LEFT SUBCLVIAN ARTERY arises near the end of the transverse aorta behind and a little to the left of the carotid, extends to the lower border of the first rib and is divided into a thoracic and a cervical portion. The thoracic part is nearly vertical, lies behind and a little to the left of the carotid. . In front of it crosses the left inominate vein and the cardiac nerves, to its inner side and behind it are the trachea, oesophagus, the left recurrent nerve the thoracic duct and the spine with the longus colli. On the outer side are the left vagus and the left pleura and lung.

RIGHT- INOMINATE VEIN. is short and almost vertical, it is 1½ inches long. It has anteriorly the sternum and pleura. Behind it is the inominate artery, to its right side are the right phrenic nerve and the pleura, to its left the inominate artery. It commences at the inner end of the clavicle by the junction of the subclavian with the internal jugular vein, and unites with the left vein to form the superior vena cava.

THE LEFT INOMINATE VEIN is longer than the right is almost horizontal, it is 3½ inches long. It orginates on the same plan as does the right and runs obliquely downward and to the right lying above the level of the arch of the aorta and in front of the three branches from the arch. Each inominate vein receives the internal mammary, the inferior thyroid and the vertebral veins.

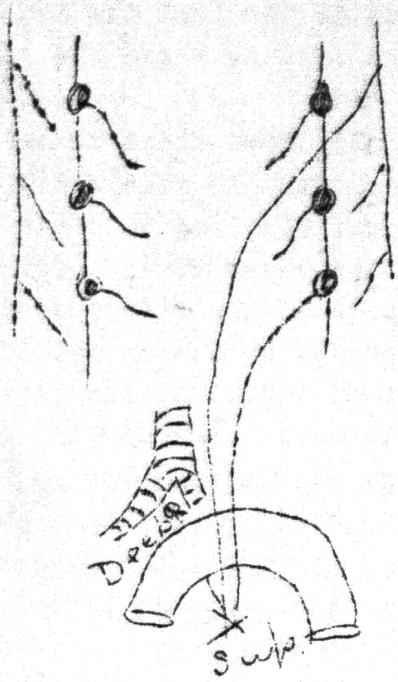

Cardiac Plexuses.

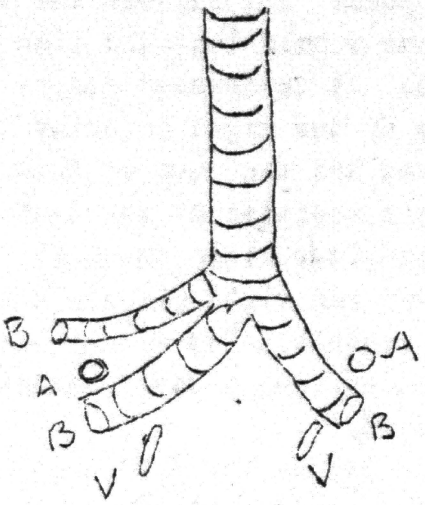

The Roots of the Lungs. (See p. 54)

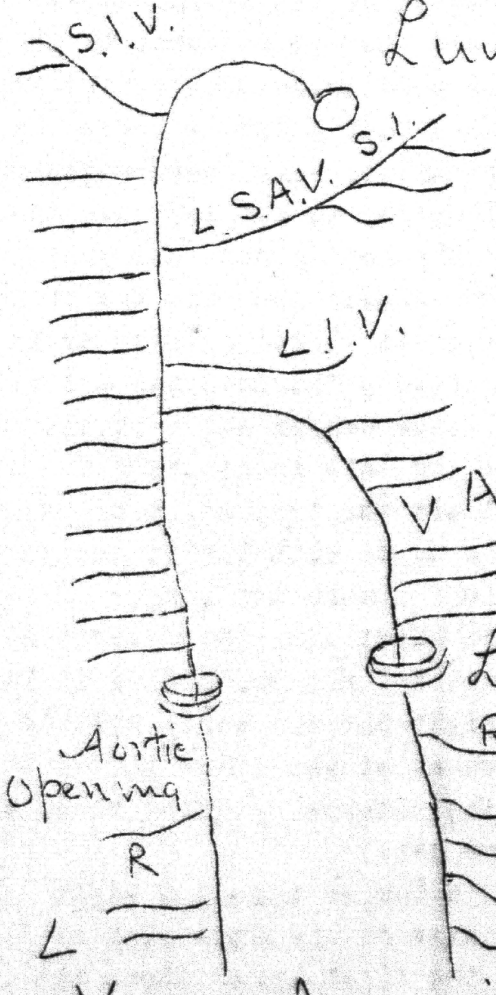

Vena Azygi. See page 55

the left also receives the left superior intercostal, the right entering the vena azygos major.

THE CARDIAC PLEXUS are two in number, the superficial and the deep. The superficial lies in the concavity of the arch of the aorta and is formed by the superior cardiac branch of the left sympathetic and the inferior cardiac branch of the left vagus. The deep lies behind and to the right of the horizontal part of the arch and in the front of the bifurcation of the trachea, it is formed by ten nerves, the superior middle and inferior cardiac branches of the right vagus and symathetic, the upperior and middle cardiac branches of the left vagus and the middle and inferior branches of the left sympathetic. The nerves of both are derived from the neck, six from the vagi and six from the sympathetic. The two plexus are connected by a branch which passes under the aortic arch and from them pass branches which probably terminate in the ganglia of the heart.

DISSECTION TO EXPOSE SUPERFICIAL CARDIAC PLEXUS, open the thorax in the usual manner, expose the transverse portion of the arch of the aorta by removing from it the pleura, clear out the concavity of the arch when the two nerves and the plexus will be seen. DISSECTION FOR DEEP PLEXUS, open the thorax, excise the pericardium, heart etc. throw the aortic arch and large veins to the left, expos- thus the bifurcation of the trachea, the plexus is seen.

THE TRACHEA IN THE THORAX lies behind the sternum, the remains of the thymus gland, the inferior thyroid veins, the anterior part of the horizontal aorta, the lower part of the inominate and left common carotid arteries and the left inominate vein. Behind it lie the oespohagus, to its right the pleura and lung, right vagus and a lymphatic gland, on its left the curve of the aorta, left carotid and subclavian arteries, left vagus and recurrent laryngeal nerve and the deep cardiac nerves. It bifurcates into the right and left bronchus opposite the upper border of the 5th. dorsal vertebra.

THE RIGHT-BRONCHUS is larger than the left, about one inch from its orgin is given off a large eparterial branch to the upper lobe of the lung. The right pulmonary artery passes under this branch to reach the posterior part of the main bronchus.

THE LEFT BRONCHUS runs beneath the arch of the aorta, crossing the oesophagus and the descending portion of the arch. Its undivided part is nearly twice as long as that of the right because the branch to the upper lobe comes off much lower down. The pulmonary artery passes over it before breaking up into its branches.

THE OESOPHAGUS is a muscular tube continuous with the pharynx. It is nine inches in length and extends from the level of the upper part of the 6th. cervical vertebra to the 9th. dorsal, where it pierces the diaphragm and dilates to form the stomach. It lies on three structures, the prevertebral region, the upper dorsal vertebrae and the aorta, to which it bears a four-fold relation, at first behind the arch, then to the right side of the descending portion of the arch, then in front of the thoracic aorta and at last to the left. In the neck the oesophagus has a curve to the left, in the thorax it passes first to the right, then forward, then to the left. It is supplied by three arteries, the inferior thyroid, the aorta and then by the coronary (gastric). Nerves of the oesophagus, in the lower half of the oesophagus the two vagi form a great plexus called the plexus gulae.

THE THORACIC DUCT begins opposite the 2nd. lumbar vertebra in a dilatation or plexus called the receptaculum chyli. It passes through the aortic opening in the diaphragm and ascends on the front of the vertebral column, lying to the right of the aorta, between it and the vena azygos major. It goes up as high as the 4th. dorsal vertebra, then curves toward the left passing very deeply behind the aortic arch also behind the great veins at the root of the neck and behind the oesophagus, leaving the thorax through the superior aperture of the thorax. It reaches as high as the 6th. cervical vertebra when it curves forward and outward upon the scalenus anticus and passing inward opens into the venous junction. It is about as thick as a crow-quill and is crowded with valves, in part of its course is often double. The largest of its valves are at the opening into the veins. The left lymphatic duct opens into it. The receptaculum chyli receives all the lumbar lymhatics, also the lacteal trunk which collects all the lymph from the small intestine. The thoracic duct drains all the lymph from the body except the right side of the head and neck, right arm, right thorax, and the upper surface of the liver which last is drained by a fine plexus of ducts opening into the right lymphatic duct.

DISSECTION FOR THE THORACIC DUCT, as the duct lies in the abdomen, thorax and neck three dissections are required. In the Abdomen, open the abdomen by a cross cut, remove the viscera and the peritoneum, also the right crus of the diaphragm, then is exposed the receptaculum chyli. In the Thorax, open the thorax in the usual post mortem manner, excise the pericardium, heart, lungs and right parietal pleura, reflect the oesophagus and vagi, then is exposed the greater part of the duct, split the diaphragm down to the aortic opening, reflect the aortic arch and its branches to the left side. In the Neck, reflect skin etc. from the left posterior triangle of the neck and expose the left sterno mastoid which reflect from below up. Reflect the clavicle with its muscles, vessels and nerves upward, excise the anterior half of the first rib and remove the left inominate and left internal jugular vein, pull the trachea to the right.

VENA AZYGOS MAJOR begins in the right ascending lumbar vein and communicates with the right renal. It passes through the aortic opening in the diaphragm, and ascends on the right of the vertebral column as high as the 3rd. or 4th. dorsal vertebra when it bends forward over the root of the right lung and ends in the superior vena cava. It receives all the right intercostals, the vena azygos minor, which enters it by passing behind the aorta about the level of the 6th. or 7th. dorsal vertebra, the superior left azygos which also passes behind the aorta about the level of the 4th. or 5th. dorsal vertebra, an occasional left intercostal, mediastinal, pericardiac and bronchial branches and the superior intercostal.(right)

VENA AZYGOS MINOR, begins in the left lumbar veins and communicates with the left renal. It passes through the left crus of the diaphragm and ascends on the left side of the vertebral column as high as the 6th. or 7th. dorsal vertebra, then crosses the column under the aorta and opens into the major. It receives the lower left intercostal veins.

LEFT SUPERIOR AZYGOS is sometimes the direct continuation of the left superior intercostal, which, however, often opens into the inominate vein. When the superior left azygos exists it begins above in the left superior intercostal and drains the left upper spaces, crosses the vertebral column about the the

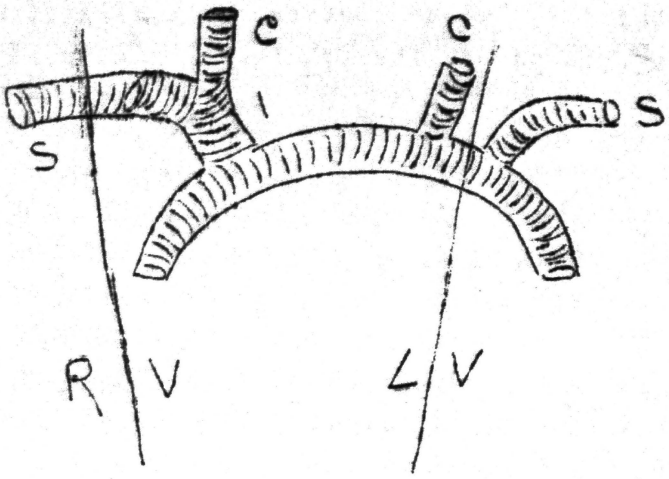

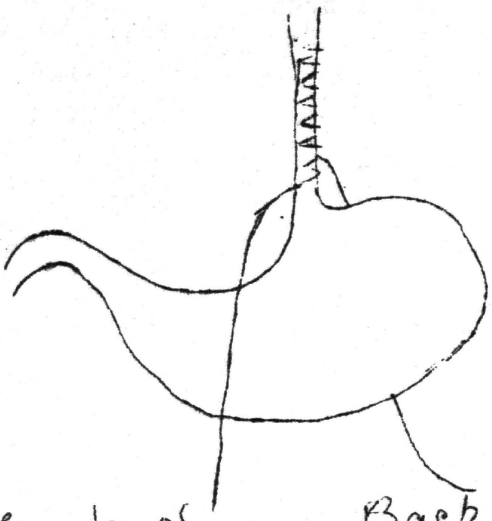

Front of Stomach - Liver

Back of Stomach — spleen.

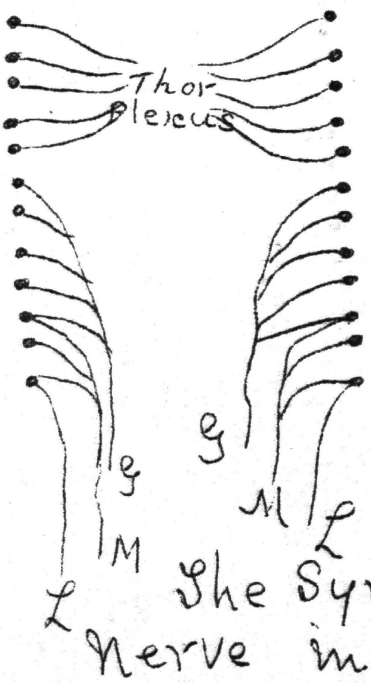

The Sympathetic Nerve in Thorax.

4th. ch 5th. DOrsal vertebra and enters the vena azygos major. The venae azygi are the remains of of two large veins uhich exist in the foetus, the cardinal veins.

THE RIGET VAGUS enters the thorax between the subclavian artery and the right inominate veins.it passes to the right side of the trachea toward the bifurcation giving off the antesior pulmonary plexus, then passing behind the root of the lung to break up into the posterior pulmonary plexus which receives communicating branches from the last cervical and upper four dorsal nerves, then it runs by the side of the oespphagus, then behind it dividing into branches which form the plexus gulae, finally the nerve-fibres re-unite and the nerve passes through the oesophageal opening in the diaphragm and is distributed to the back of the stomach and the spleen. Cardial branches are given off in the thorax which go to the deepcardiac plexus.

The LEFT VAGUS, enters the thorax between the left carotic and subclavian arteries and behind the left inominate vein. It descends between the horizontal arch and the left lung giving off its recurrent branch and the anterior pulmonary plexus, passes behind the root of the left lung and in front of the descending aorta there giving off the posterior pulmonary plexus. It reaches the front of the oesophagus and enters into the formation of the plexus gulae, finally passes through the oesophageal opening in the diaphragm to be distributed to the front of the stomach and the liver. The recurrent laryngeal branch runs below the remains of the ductus arteriosus and up on the right of the ascend- horizontal aortapassing to the neck between the trachea and oesophagus, it gives off cardiac branches to the deep plexus.

THE THORACIC AORTA is the continuation of the arch of the aorta, e tends from the lower border of the 5th. dorsal vertebra to the lower border of the 12th., where it passes behind the diaphragm and enters the abdomen. Its direction is downward, forward and to the right. Relations, anteriorly it has the root of the left lung and pleura, pericardium, oesophagus at middle part; Posteriorly, vertebral column, left sympathetic and vena azygos minor; to its Right, the oesophagus above, the vena azygos major and the thoracic duct, to its Left the vena azygos minor, Oesophagus (below) and left pleura. From the front of the aorta are given off pericardiac, left bronchial, oesophageal and mediastinal branches. The pericardiac branches are small and irregular, the oesophageal are four or five small branches to the oesophagus anastomosing above with the oesophageal branches of the inferior thyroid and below with the branches of the coronary. The intercostal arteries from the aorta are nine or ten in number on each side and arise from the back of the aorta and supply the nine or ten lower spaces, anastomosing with the superior intercostal above. The right arteries are of neoesaity longer than the left. The lower vessels run transversely outward passing beneath the oesophagus, thoracic duct, vena azygos major and the ganglioted cord of the symphathetic on the right, on the left passing under the hemi-azygos veins and the sympathetic. Each artery gives off close to the vertebrae a posterior branch which passes back between the transverse processes and dividing into a muscular branch to the muscles of the pack and a small spinal branch to the cord and the body and arch of each vertebra.

SYMPATHETIC NERVE IN THORAX the ganglioted cord of the sympathetic is placed over the heads of the ribs on each side of the thorax, beneath the pleura, it

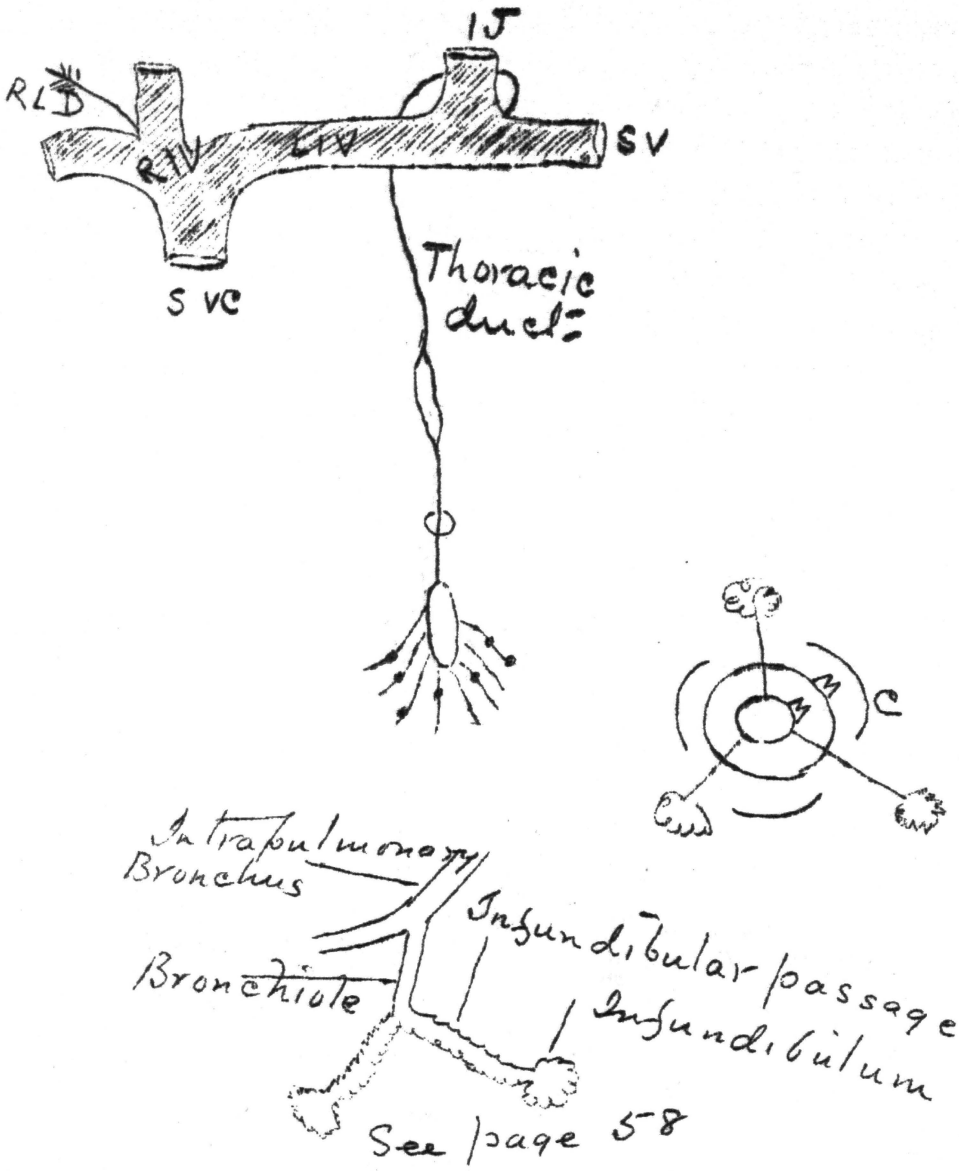
IJ
RLD
RTV
LTV
SV
SVC
Thoracic duct
M
C
Intrapulmonary Bronchus
Bronchiole
Infundibular passage
Infundibulum

See page 5-8

is connected above with the inferior cervical ganglion. the thoracic ganglia are generally said to correspond in numberto the ribs, but the first ganglion is often coonected to the inferior cervical and occasionally two of the lower ganglia are united. Each ganglion gives off ascending branches to the ganglion above, descending to the ganglion below and external, usually two, branches to the thoracic spinal nerves and internal branches of distribution. The upper five or six nerves go to a plexus in the thorax, to vertebrae and their ligaments, the oesophagus, the anterior and posterior pulmonary plexuses and the aortic plexus. From the internal branches of the lower 9 or 7 ganglia arise the splanchnic nerves.

THE SPLANCHNIC NERVES, the great splanchnic nerve is derived from 5 ganglia, 8th. to 10th. by separate fibres. It runs inward in the posterior mediastinum and, after piercing the crus of the diaphragm joins the semilunar ganglion and the renal and supra-renal plexus in the abdomen. The lesser splanchnic is derived from the 10th. and 11th. ganglia, also pierces the crus to join the solar, renal and supra-renal plexuses. The least splanchnic is derived from the 12th. ganglion, goes to the renal plexus. Nothing in the thorax can be the sympathetic unle s it goes from top to bottom of the thorax and lies in relation with the heads of the ribs. Another structure communicating with the sympathetic but anterioh to it will be a splanchnic nerve.

THE TRACHEA has been already mentioned (page 54). it is composed of a series of incomplete cartilaginous rings the extremities of which are connected together behind by fibrous and muscular tissue. There are from 16 to 20 cartilages each measuring about two lines in depth, but decreasing in size as we pass down. The last cartilage is cut obliquely on each side so as to be adapted for the commencement of the bronchi. The cartilages are connected together by elastic fibrous tissue and is clung from the cricoid in the same manner. The cartilages are contained betweenthe two layers of a fibrous membrane, and it is the two laminae blending together between the cartilages that frovides the elastic fibrous connecting membrane, The extremities are connected together by muscula fibres which exist in two layers, an outer whioh has longitudinal fibres and an inner which has transverse. The epithelium lining the trachea is columnar ciliated. On looking into the lower end of the trachea a septum is seen between the two bronchi, this is placed a little to the left of the median line.

BRONCHUS IN THE LUNG. On tracing a bronchus into the lung it will be seen that each main bronchus extends to the base of the lung, the left one forming a sigmoid curve round the heart. They give off lateral branches and the right has in addition a large eparterial branch. The branches of the pulmonary artery lie in immediate contact with the back of the bronchi and follow their course exactly, the veins lie on the ventral aspect and are not quite so regular.

An extrapulmonary bronchus has the same structure as the trachea only its rings are less regular, having entered the lung the structure remains as in the trachea only the muscle is a continuous layer outside the membrane, the cartilage is not crescentic but is divided into three different layers or bars, and the muscle is internal to it. Mucous glands are found in the walls. A bronchiole is a small bronchus, it has no cartilage but much muscle, the bronchioles in their turn break up into infundibular passages, narrow sacs with sacculated walls and this passage in turn leads into an infundibulum which is the space

surrounded by the air-cells or alveoli, the air cells of one infundibulum have no connection with those of another.. In the bronchioles the cilia gradually get lost and the epithelium becomes in the infundibula passage squamous. An alveolus is a sac whose walls are formed of a single layer of endothelium or squamous epithelium, strengthened by elastic tissue, white fibrous tissue and non-striate muscle. Each alveolus is surrounded by a capillary plexus. In ordinary respiration it is merely the air in the larger passages which is change with each breath. The wall of the alveolus and the wall of the capillary lie between the air in the alveolus and the blood in the capillary. The pulmonary artery carries blood to the lung for oxygenation, the bronchial artery carries the blood for the nourishment of the lung. Lymphatics are present in the form of vessels and glands and at the root of the lung these are specially abundant. They occur as peribronhhial, perivascular and subpleural lymphatics.
ARTICULATIONS OF THE THORAX are divided into Costo-vertebral, Costo-transverse Costo-chondral, Inter-chondral and Chondro-sternal. Costo-vertebral joints, the articulation takes place between the head of the rib and the bodies of two vertebrae. Ligaments, capsule, anterior or stellate, (three bands two of which go to the vertebrae the middle one to the disc) interarticular. Costo-transverse joints, articulation is between the tubercle of the rib and the transverse process of vertebra. Ligaments, Capsule, Interosseous or middle from the front of the transverse process to the back of the neck of the rib, External costo-transverse ligament extends from the tubercle of the rib to the tip of the transverse process, it lies outside the joint, Superior ligament, from the upper border of the neck of the rib to the transverse process above.. The costo chondral joint is the reception of the cartilage into the end of the rib where it is held in position by many fibrous bands. The Chondro-sternal joints are 14 in number and have anterior and posterior ligaments. Each joint has a synovial membrane except the 2nd. and 3rd. which have each two, and the 1st. which has none. The 2nd. has an interarticular ligament. Inter-chondral joints exist between the 7th. 8th. 9th. and 10th. costal cartilages. Each has a capsule and a synovial membrane. The thoracic wall is so arranged that on inspiration all of its diameters are increased.

End of THE THORAX.

THE ABDOMEN.

THE ABDOMEN.

THE PERINEUM. The boundaries of the space are the same in the male and female and the space corresponds with the inferior aperture of the pelvis. In front is the symphysis pubis with the divergent ischio-pubic rami running to the ischial tuberosities which form the lateral boundaries, posteriorly are the inferior margins of the great sacro-sciatic ligaments overlapped by the margins of the gluteus maximus and in the middle line posteriorly is the tip of the coccyx. The shape as a whole is much like an inverted ace of hearts. The inferior aperture of the pelvis is larger than in the male in the female. The space may be conveniently divided into triangles by a line passing laterally from one tuber ischii to the other, the anterior, or urethral, half gets the name of the perineum proper and contains the urino-genital organs, while the posterior half is called the ischio rectal region and contains the lower extremity of the bowel and ischio-rectal fossae..

The posterior space in both sexes corresponds closely. The integument surrounding the anus is pigmented and beset with hairs and large sebaceous follicles. In it there is some scattered non-striate muscular tissue to which has been given the name of corrugator cutis ani, this is continuous with the dartos of the scrotum and perineum.

EXTERNAL SPHINCTER consists of two symmetrical halves which are attached behind to the tip of the coccyx, run round either side of the bowel and meet at a point, about one inch in front of the anus, which is tendinous and is called the central point of the perineum. When the muscle contracts it compresses the bowel laterally, it is usually in a condition of semitone it is supplied by a branch of the 4th. sacral nerve and the inferior hemorrhoidal nerve.

THE CENTRAL POINT OF THE PERINEUM is a tendinous point of meeting of the sphinter ani, the bulbo-cavernosi and the transversi perinei.

THE ISCHIO RECTAL FOSSA is the space on each side of the rectum, bounded superficially by the gluteus maximus, ischial tsberosity and the great sacro-sciatic ligament behind, by the junction of the fascia of Colles with the triangular ligaments in front and by the sphincter ani internally. The space is a 4-sided pyramid the base of which is on the surface and whose apek is deep. The base is formed of skin and superficial fascia while all the walls are formed of fascia. Externally we have the obturator fascia, internally the anal fascia, Anteriorly the pelvic fascia and posteriorly the sacro-sciatic ligament. When the finger is pushed into the space it is prevented from passing clear up by the junction of the anal and the obturator fascia, as will be seen on considering the pelvic fascia on a lateral view these fascias are processes of the same fascia produced by the splitting of the fascia. The space extends for a depth of about two or three inches, it runs forward almost to the symphysis pubis over the ledge of tissue which constitutes the true perineum, posteriorly it runs for some distance over the sacro-sciatic ligaments to the coccyx. So if looked at frontally it is pyramidal, but on sagittal section it would be anvil shaped. The space is filled with loose fatin which lie the inferior hemorrhoidal vessels and nerve. On the outer side lying above the level of theinner border of the ischial tuberosity and enclosed in a little fibrous canal, (the canal of Alcookx) formed in the obturator fascia are the pudic vessels and nerve.

THE LEVATOR ANI arises within the pelvis from the back of the pubis, the inner surface of the spine of the ischium and to the "white line" of the pelvic fas

cia, a fibrous band which stretches between those points and marks the separation of the recto-vesical and ischio-rectal planes of pelvic fascia from the obturator.. The muscle is Inserted into the side of the lower part of the rectum and also into the central point of the perineum and the tip of the coccyx. Nerve, branches from the 3rd. and 4th. sacral.

INFERIOR HEMORRHOIDAL ARTERY, a branch of the internal pudic, given off under cover of the ischium, runs almost straight across the space to the rectum and anastomoses with the middle hemorrhoidal.

INFERIOR HEMORRHOIDAL NERVE, branch of the internal pudic nerve, runs here superficially to the vessels, is distributed to the external sphincter and skin of the anus, communicates with the superficial perineal nerves. In this region are also found a perineal branch of the 4th. sacral and a perforating cutaneous branch of the sacral plexus.

ANTERIOR SPACE IN THE MALE. The superficial fascia of the anterior half of the perineum is divisible into two layers, superficial and deep. The superficial layer is continuous with that of the scrotum, is fatless and contains some non-striate muscular tissue, the dartos. The deep layer, or fascia of Colles, is continuous with the fascia of the scrotum and penis and over the root of the penis with the fascia of the abdomen, laterally it is attached on each side to to the ischio-pubic rami as far back as the tuberosity and posteriorly turns around the transversi perinei muscles and joins the posterior layer of the deep perineal fascia or triangular ligament as it is commonly called. Thus is formed a pouch between the fascia of Colles and the triangular ligament (space between the layers of the triangular ligament) and this encloses the bulb of the corpus spongiosum and the crura of the corpora cavernosa, together with its surrounding muscles, vessels and nerves.

SUPERFICIAL PERINEAL ARTERY, a branch of the internal pudic enters the superficial pouch of perineal fascia passes forward either over or under the superficial transversus perinei muscle to supply the superficial muscles of the perineum.

TRANSVERSE PERINEAL ARTERY, branch of internal pudic, runs to median line and anastomoses with its fellow.

PERINEAL NERVE generally leaves the pudic as a single branch in the ischio-rectal fossa and supplies the two superficial perineal nerves, muscular branches to the external sphincter, levator ani and the three muscles in the half of the superficial perineal interspace, traosversus perinei, ischio-cavernosus and bulbo cavernosus and a branch which may be followed to the bulb of the urethra. The two superficial perineal nerves run forward and are distributed to the scrotum. The inferior pudendal nerve or nerve of Soemmering, is a branch of the small sciatic which pierces the deep fascia of the thigh about one inch in advance of the tuberosity of the ischium. It generally runs forward to the scrotu

SUPERFICIAL MUSCLES, BULBO-CAVERNOSUSOrigin, central point of the perineum, its fibres run in three directions, some into the triangular ligament, some embrace the bulb and some surround the root of the penis. Nerve, pudic.

ISCHIO--CAVERNOSUS, Origin, inner side of the ramus of the ischium where it embraces and covers the crus penis. Insertion, its fibres are lost upon the surface of the penis metting with its fellow and acting like a ring. Nerve, pudic.

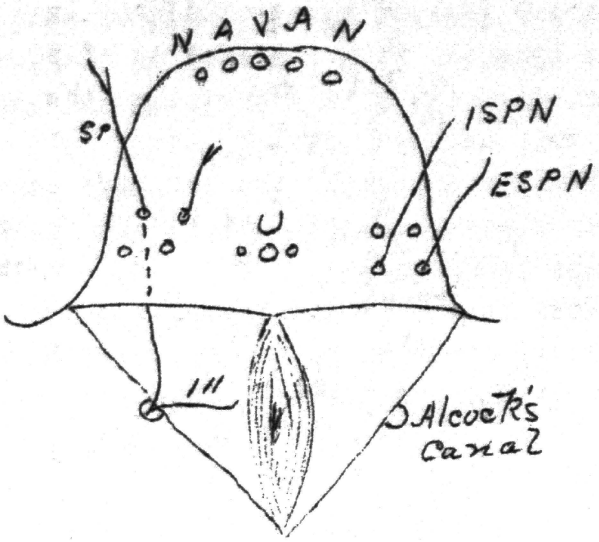
NAVAN
SP
ISPN
ESPN
U
IM
Alcock's
canal

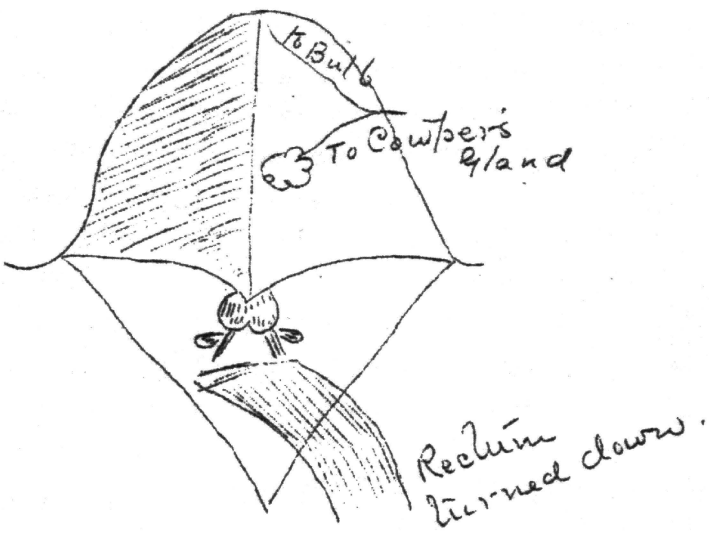
To Bulb
To Cowper's gland
Rectum
turned down.

TRANSVERSUS PERINEI, Origin, inner side of ramus of ischium, runs forward and inward, meets its fellow on opposite side in central point of the perineum.
THE BULB OF THE URETHRA is the posterior expanded portion of the corpus spongiosum which lies immediately in front of th e triangular ligament. It is slightly expanded from side to side and consists of two halves united by a delicate septum of fibrous tissue. It is closely connected with the triangular ligament with which its fibrous covering is continuous.
SUPERFICIAL TRIANGULAR LIGAMENT is attached to the rami of the pubis and ischium on either side behind the crura. The apex is separated from the sub-pubic ligament by the opening for the dorsal vein of the penis and the base which is like an inverted V with the angle at the tendinous central point of the perineum is continuous with the fascia of Colles around the posterior porder of the the superficial transversus perinei and also with the base of the triangular ligament. On cutting the superficial triangular ligament we come on
DEEP TRANSVERSUS PERINEI, Orggin, inner surface of ischio pubic rami, it divid into anterior and posterior slips which run transversely inward and enclose th membranous portion of the urethra. Within the fibres of the muscle on either side are Cowper's gland, the pudic artery, the corresponding veins, and the dorsal nerve of the penis a branch of which supplies the muscle
COWPER'S GLANDS lie close to the membranous portion of the urethra, one on each side of the middle line. The gland is like a pea in size and shape and consist of many minute lobules. The duct is nearly an inch in length and pierces the superficial triangular ligament to openinto the bulbous portion of the urethra
THE PUDIC ARTERY, is foond under cover of the pudic arch, the artery as will be seen elsewhere lies in five regions, we find it now in two of these, in the ischio-rectal fossa and in relation with the membranous portion of the urethra. After running in Alcock's canal and giving off its inferior hemorrhoidal and superficial perineal branmhes it pierces the deep triangular ligament near its base and enters the deep perineal interspace. Here it runs in the fibres of the compressor urethrae(deep transversus) and gives off the artery to the bulb and continues as the dorsal artery of the penis. The artery to the bulb passes almost transversely inward to supply the bulb, piercing the superficial triangular ligament. It generally gives a branch to Cowper's gland. The artery to the corpus cavernosum, also from the pudic enters the orus, While the dorsal ~~artery~~ vein of the penis runs between the sub-pubic and triangular ligaments to join the prostatic plexus of veins, the artery pierces both the superficial triangular ligament and then the subApubic ligament to reach the upper surface of the penis.
THE PUDIC NERVE lies below the artery in the ischio rectal fossa, gives off hemorrhoidal and perineal branches and ends in the dorsal nerve of the penis. The course to the penis lies close to that of the artery.
THE DEEP TRIANGULAR LIGAMENT closely resembles the superficial in its mode of attachment to the ischio-pubic rami, but is placed higher and is really a continuation of the pelvic fascia acro s the sub-pubic arch. It is in contact below with the deep transversus perinei muscle and above with the continuation of the ischio-rectal fossa's fat, the apex of the prostate, the recto-vesical fascia and the anterior fibres of the levator ani. It is pierced by the following structures. The urethra and the duct of internal pudic vessels and the dorsal nerve of the penis. The dorsal vein running between its apex and the sub-pubic

ligament.

ANTERIOR SPACE IN THE FEMALE. The superficial fascia resembles that of the male in being divisible into two layers. The superficial fascia (layer of fascia) is continuous with the fascia of the body generally, while the deep has the same connections as in the male but is not so well marked. Owing to the presence of the vulva the deep layer is divided in the middle line and becomes continuous with the sheath of the vagina.

SUPERFICIAL PERINEAL ARTERY, or artery of the labium, a branch of the internal pudic and is larger than in the male. The transverse artery also a branch of the internal pudic arises with or just in front of the last, runs inward close to the superficial traosverse muscle.

SUPERFICIAL PERINEAL NERVES are two in number, branches of the pudic, the internal or anterior runs upward and inward to the back part of the vulva, the external or posterior is larger and supplies the superficial muscles.. The inferior pudendal is a branch of the small sciatic and appears in the same situation as in the male, runs up and in to join with the external superficial perineal.

THE PERINEAL BODY, or obstetrical perineum, consists of a mass of elastic and fibrous tissue with some fat placed between the orifices of the vagina and rectum and uniting all the structures which meet in the central point of the perineum.

The superficial muscles of the female closely correspond to those of the male with the exception that the two portions of the central muscle, corresponding to the bulbo-cavernosus are separated by the vulva.. On each side we have, therfore a separate muscle, one half of the male musole.

BULBO-CAVERNOSUS or sphincter vaginae, Origin, from the perineal body, from the reflection of the deep layer of the superficial fascia. The fibres are divided into three sets, some pass forward to meet with its fellow upon the clitoris, the middle fibres pass beneath the clitoris and over the veins on the urethra, the posterior fibres pass to the triangular ligament.

ERECTOR CLITORIDIS, Origin, front of tuber ischii, Insertion, sides of crus.

TRANSVERSUS PERINEI, Origin, inner side of ramus of ischium, meets fellow in perineal body, blends with bulbo-cavernosus, sphincter ani and sphincter vagin

LEVATOR ANI practially the same as in the male.

THE BULB OF THE VAGINA corresponds exactly to one half of the bulb in the male. Iti is a vascular body placed on the side of the orifice of the vagina and enclosed in a sheath of fascia derived from the triangular fascia. Each bulb is about one inch long and is composed of a plexus of veins which communicate the one side with the other under the clitoris.

SUPERFICIAL TRIANGULAR LIGAMENT resembles that of the male. It ii perforated b the urethra and is divided posteriorly by the vagina with the coats of which i is closely incorporated.

THE DEEP TRANSVERSUS PERINEI has the same attachments as in the male but is co posed largely of non-striate muscle. Involuntary muscle surrounds much of the female urethra, may correspond to part of the prostate in the male.

GLANDS OF BARTHOLINI correspond to Cowper's glands in the male but are more su erficially placed. Each is the size of a bean and is placed behind the bulb. A minute duct opens in front of the hymen between the clitoris and post. commis

PUDIC ARTERY AND NERVE, these correspond to the same structures in the male b

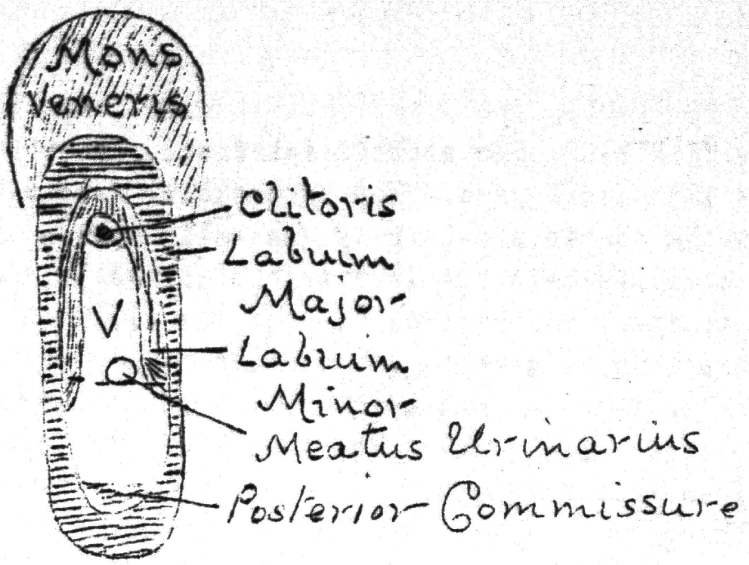
Mons Veneris
Clitoris
Labium Major-
Labium Minor-
Meatus Urinarius
Posterior-Commissure
V
A
V
Glans
Corpus spongiosum.
Corpus Cavernosum
Crus
Bulb
Crus

are much smaller. The artery lies under cover of the ramus of the pubis and in company with the nerve, it gives off arteries to the bulb and the clitoris and the crus clitoridis. . The pudic nerve gives off muscular branches and ends in the dorsal nerve of the clitoris which is relatively much larger than in the male. The deep triangular lig.ment differs only in being pierced by the vagina.

FEMALE EXTERNAL GENITALS. The term vulva is applied to everthing outside of the hymen. The mons veneris is a pad of fat resting in front of the symphysis pubis, it is covered by skin which bears very strong hairs. The labia majora are connected in front and behind, their meeting places being called the anterior and posterior commissures. A labium major is made of skin, the applied inner surfaces are constantly kept moist and sodden by the vaginal discharges. The two labia majora are always in contact unless artificially separated. The labia minora are formed of skin, each nympha is cleft above to enclose the clitoris forming the hood of the clitoris or prepuce, behind they are lost on the labia majora. The clitoris is the homologue of the glans penis and like it is largely composed of erectile tissue. This erectile tissue is found not only in the clitoris and partly in the nymphae but it extends backward and outward ar two great lobes or masses, the bulb of the vagina as previously mentioned. The vestibule is a triangular space whose apex is at the clitoris and the base of which is a line drawn through the urethra and whose sides are formed by the nymphae. This is the most sensitive part of the vulva. The meatus urinarius has a somewhat prominent posterior lip and this is taken as a guide in the passage of the catheter unaided by sight. . The vagina has a small orifice which is largely closed by the hymen. The hymen varies in shape and size, it is a vascular mebrane which is sometimes imperforate. NOTE, absence of the hymen is no positive proof of absence of virginity. After the rupture of the hymen its place is taken by the caruncular myrtiformes.

MALE EXTERNAL GENITALS The penii shows the following parts, a glans, a body and two crura. The penis is formed of three cylinders, two corpora cavernosa and one corpus spongiosum. The corpus spongiosum is perforated by the urethra. Each of these cylinders is a strong fibrous bag from whose walls strong septa pass into the substance and divide it into a series of compartments lined by endothelium and containing blood which is supplied to them by tortuous arteries called helicene, the blood being carried away by veins which are for the most part superficial. The corpus spongiosum can be dissected completely off from the rest of the penis, but the corpora cavernosa cannot be separated one from the other, the septum between them is called the septum pectiniforme. The corpora cavernosa end anteriorly in two rounded knobs and end posteriorly by diverging from each other and becoming attached to the sides o the pubic .roh, constituting the crus penis. The corpus spongiosum when traced back ends in a knot the bulb, in front it ends by broadening out to form the glans penis. The skin of the penis is very delicate and the superficial fascia never contains fat. The dorsal vein returns the blood from the skin and opens into the prostatic plexus of veins. The prepuce is a fold of skin which surrounds the glans and is attached to the glans below where it constitutes the fraenum, and posteriorly round the corona glandis, the posterior limit of the glans. It is not a mucous membrane but has glands on its inner aspect which secrete the sebaceous material, the smegma. Frequently in children the prepuce is attached at one or more points to the glans

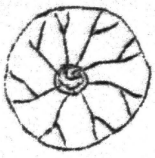

Umbilicus

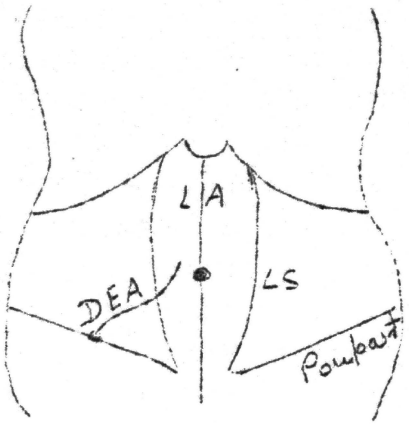

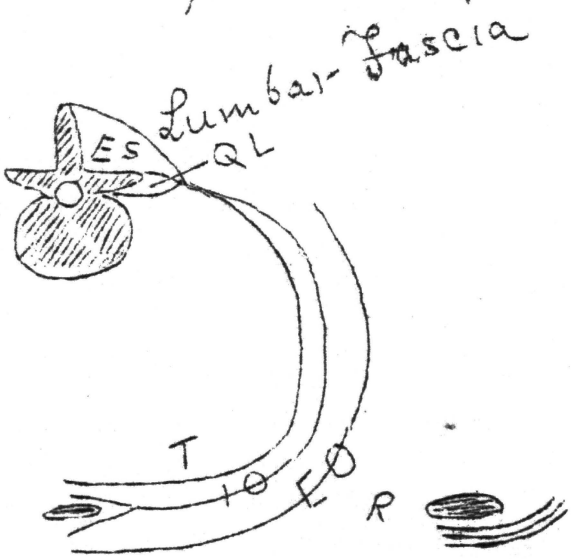

Sheath of Rectus

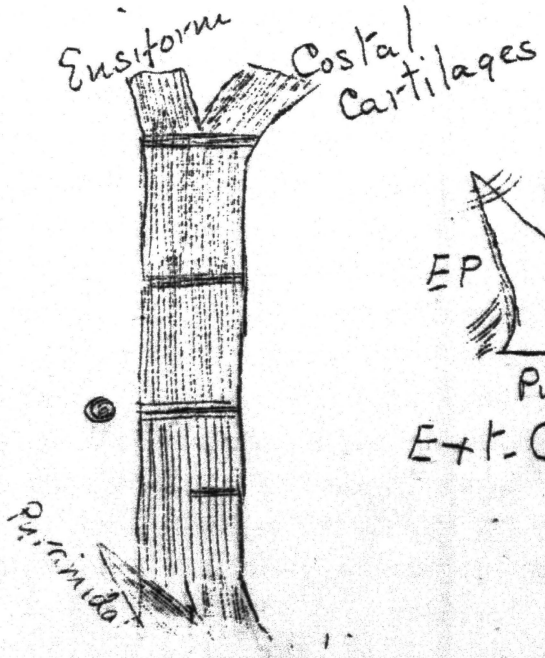



Ext. Abdom. Ring

HOMOLOGUES . The glans penis corresponds to the clitoris, the body of the penis to a mass of erectile tissue which is found not only under the vestibule but which also exists as a ring around the orifice of the vagina. The scrotum corresponds to the labia majora, the male urethra to the nymphae, Cowper's glands to the glands of Bartholin, the sinus pocularis to the vagina and uterus, the prostate to the uterus and the testicles to the ovaries. There are three defects in the male genitals which may occur congenitally. Epispadias, where the urethra is incomplete along the dorsum of the penis, Hypospadias where it is incomplete along the under surface and Ectopion vesicae where epispadias is prolonged on to the abdominal wall and the bladder protrudes through it.

THE CAVITY OF THE ABDOMEN is bounded above by the diaphragm, below by the pelvic bones, fascia, ligaments, muscles and the lower pelvic outlet, posteriorly by the five lumbar vertebrae, the sacrum and coccyx, anteriorly by the "abdominal wall", composed of muscles mainly. The abdomen is divided into two parts, the abdomen proper and the pelvis. The skin over the abdomen is very thin, especially in the region of the groin. It is fairly sensitive being supplied by the lower six intercostal nerves and the ilio-hypogastric neeve. The cutaneous NERVES OF THE ABDOMINAL WALL consist of two sets, an anterior and a lateral. The anterior are very small, are found in two rows, one quite near the middle line, the other piercing the tendon of the external oblique two inches from the middle line., the lateral branches are longer, come through the external oblique and about two inches behind the anterior spine of the ilium and half an inch above it will be found the last dorsal nerve, while the hypogastric branch of the ilio-hypogastric will be found in relation with the rectus abdominis, its iliac branch, as was seen in the buttock, will be found behind the last dorsal, close to the crest of the ilium. Small branches of arteries will be found running with these nerves(intercostal, internal mammary and epigastric). The superficial fascia is divided into two layers in two regions, first in the lower half of the abdomen, second, in the groin (see Leg) The deep fascia of the anterior abdominal wall is very thin, the thinnest deep fascia in the body.

THE UMBILICUS is a scar in the middle of the linea alba. It is surrounded by a plexus of veins which are joined by a circular vein at the circumference. In dropsical conditions these veins becime engorged.

THE LINEA ALBA is a fibrous line extending from the ensiform cartilage to the symphysis pubis, it is crossed by no vessels, this line can scarcely be said to exist when the abdomen is normal as the two recti muscles lie so very close together.

LINEAE SEMILUNARIS, are fibrous lines which mark the outer boundary of the rectus muscle. The linea is crossed by the deep epigastric artery in its lower half. The muscles of the anterior abdominal wall are as follows,

EXTERNAL OBLIQUE, Origin, outer surfaces of the bony parts of the eight lower ribs and from the intercostal fascia between them, it interdigitates with the serratus magnus by four or five points above and with the latissimus dorsi by three or four below, Insertion, the fibres pass downward and forward and are inserted into the anterior half of the outer lip of the crest of the ilium, the spine of the pubis and the crest of the opposite side decussating with its fellow over the symphysis, the whole length of the middle line blending with the aponeurosis of the internal oblique. Stretching from the anterior superior

spine of the ilium to the spine of the pubis the muscle is unattached, but the fibres here take strong attachments at those points and between them the edge of the muscle is incurved below affording attahhment to the internal oblique and transversalis. This attachment constitutes what is known as Poupart's ligament. It is joined at its inner end by the prolongation of the fascia of the thigh from the margin of the saphenous opening, the ligament of Hey, the continuation of the falciform process of Burns, this process of fascia attaches to the under surface of Poupart at its inner end and is prolonged downward to the innermost part of the ilio-pectineal line constituting Gimbernat's ligament, theinner boundary of the crural canal and the constricting band in femoral hernia. Nerve, lower 6 intercostals, ilio-hypogastric, ilio-inguinal.

THE EXTERNAL ABDOMINAL RING is merely a cleft in the external oblique tendon placed obliquely immediately above the and to the outer side of the pubic spine. It is thiangular with the base down and the apex pointing outward, it is about one inch long and half an inch across. The tendinous fibres limiting it above and below have been termed the pillars of the opening, of these the outer is flat and triangular above, round and thick below where it attaches to the pubic spine and the inner extremity of Poupart, while the inner is flat and continuous with the rest of the tendon where it attaches to the pubic crest. At the upper part of the opening some fibres are seen running across from one pillar to the other in a curved manner, these constitute the intercolumnar fibres, the continuation of which forms the the intercolumnar or external spermatic fascia and is prolonged as as a covering of the testicle and cord. The spermatic cord does not lie in the center of the ring but upon the outer pillar which is slightly drawn down by the weight of the testicle.

It is common in works on anatomy to devote a large amount of time to the anatomy of Hernia. Hernia is pathological not anatomical.

INTERNAL OBLIQUE, Origin, lumbar fascia, anterior two-thirds of crest of the ilium, outer half of Poupart's ligament. Insertionlower margins of the 4 lower ribs, ensiform cartilage and the linea albàa The insertion into the linea alba is by an aponeurosis which splits in its upper upper two-thirds to enclose the rectus muscle, in the lower third the aponeurosis passes in front of the rectus. The lower fibres of the muscle become more and more horizontal in their course and at the lastarch downward to be inserted into the pubic crest and the ilio-pectineal line behind Gimbernat, blending with the transversalis at this point to form the conjoined tendon.. A few pale muscular fibres are found in the male on the surface of the cord, these are continuous with the lower border of the internal oblique and constitute the cremaster muscle. The nerve is the same as the external muscle.

TRANSVERSALIS, Origin, inner surface of the cartilages of the 6 lower ribs, interdigitating with the diaphragm, the lumbar fascia, the anterior two-thirds of the inner lip of the crest of the ilium, outer third of Poupart. Insertion, its tendon passes to the linea alba behind the rectus for the upper two-thirds of the length of the rectus and then in front of it for the last third being united with that of the internal oblique, and into the pubic crest and the ilio pectineal line with the internal oblique forming the conjoined tendon. Nerve, same as internal and external oblique.

THE SPERMATIC CORD will be found to consist of the vas deferens or duct of the testicle together with the deferential branch of the superior vesical artery



Spermatic Cord. (page 65)

½ inch

Inguinal Canal



Rectus

Heselbach's △ (page 67)

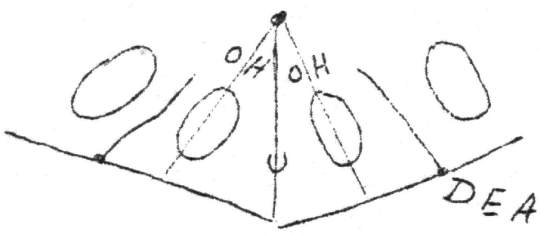

(page 67)

Pouches of the Peritoneum

and the deferential veins with lymphatics, the spermatic artery with its veins and lymphatics, the cremaster, the obliterated processes vaginalis of the peritoneum, sub-peritoneal tissue surrounding all these structures. The coverings of the cord from within out are the infundibuliform fascia from the fascia transversalis (internal abdominal ring), cremasteric fascia (from the inguinal canal and internal oblique) intercolumnar fascia (from the external oblique at the external abdominal ring), superficial fascia and the integument. The vas deferens feels like a hard cord in the spermatic cord, can always be distinguished from the other structures..

THE INTERNAL OBDOMINAL RING is an artificial opening in the fascia tnansversalis placed midway between the symphysis pubis and the anterior superior iliac spine about half an inch above Poupart immediately outside the deep epigastric vessels.

THE INGUINAL CANAL is the interspace about an inch and a half in length extending from the internal to the external ring and transmitting the cord. In front of it is the tendon of the external oblique, in its outer third the lowest part of the muscular fibres of the internal oblique and a small portion of the cremaster, Behind it (beginning at the internal ring) fascia transversalis for all of its length, the conjoined tendon in its inner third and the deep epigastric vessels immediately internal to the internal ring. Below, the line of junction between Poupart and the lower border of the fascia transversalis, Above, the arched border of the transversalis fibres.

THE SHEATH OF THE RECUS is formed by the tendons of the external and internal oblique and the transversalis, or rather their tendons of insertion, which are broad and membranous. In the upper two-thirds of the sheath the tendons are arranged thus, the tendon of the transversalis unites with the posterior lamina of the split tendon of the internal oblique and lies behind, while the anterior lamina of the internal oblique unites with the tendon of the external and lies in front. These thus lie a tendon and a half in front and the same behind. In the lower third of the rectus muscle a change occurs and all the tendons pass in front of the muscle. Where the tendons cease to pass behind a large free border is left, the fold of Douglas, in front of this the epigastric vessels pass and enter the rectus. The sheath contains the rectus abdominis, the pyramidalis, the deep epigastric vessels, the superior epigastric vessels and the termination of the lower intercostal nerves, the sheath is incomplete behind, above and below. behind where the tendons all pass in front, i.e. in its lower third, above to admit the superior epigastric vessels, below to admit the deep.

THE PYRAMIDALIS Origin, the pubic crest, Insertion, linea alba. The muscle is about two inches in length, exists to tense the linea alba, and is supplied by the lower intercostal nerves etc.

The vessels and nerves of the abdominal wall run between tte transversalis and the internal oblique

RECTUS ABDOMINIS Origin, pubic crest and supra-pubic ligament and by an interlacement from the front of the pubic bones and the symphysis, the inner fibres are fleshy, the outer tendinous but there is no division into two heads. Insertion, Ensiform cartilage and anterior surface of the cartilages of the three last true ribs. The lineae transversae are usually three in number and exist as tendinous intersections in the substance of the muscle. One is at the level

of the umbilicus, one about the ensiform cartilage and the third is about midway between them, a fourth is sometimes found, partial, between the umbilicus and the pubis. These lines rarely extend all the way through the muscle and are especially marked in front where they are adherent to the sheath..

THE DEEP EPIGASTRIC ARTERY is a branch of the external iliac, it passes upward and inward ending in the substance of the rectus by anartomosing with the superior epigastric, one of the terminal branches of the internal mammary.. The artery lies first on the peritoneum, then pierces the fascia transverralis and lies on it, then enters the sheath of the rectus and lastly enters the rectus

THE FASCIA TRANSVERSALIS is the membrane lining the transversalis muscle and is continuous with the fascia covering the psoas and iliacus. It gives processes to strengthen the femoral sheath. It is usually thin and transparent and at the internal abdominal ring is prolonged over the elements of the spermatic cord as the infundibuliform fascia.

On holding up the anterior abdominal wall and viewing it by transmitted light five cords are seen taking a course toward the umbilicus, the central one is the obliterated urachus, the two next it, one on each side are the obliterated hypogastric arteries while the outermost pair are the deep epigastric arteries. By ttere five structures existing in the abdominal wall the four peritoneal pouches are formed, these are four shallow depressions found on the anterior abdominal wall just above Poupart. It is through these pouches that direct or indirect inguinal herniae must pass.

HESSELBACH'S TRIANGLE is bounded by Poupart, the outer border of the rectus and the deep epigastric artery, this triangle lies immediately behind the external abdominal ring. Its floor is formed by the conjoined tendon and crossing it we have the obliterated hypogastric artery.

CAVITY OF THE ABDOMEN.

REGIONS OF THE ABDOMEN. For convenience of description the cavity of the abdomen is divided into 9 regions by means of 4 lines, two vertical extending from the 8th. costal cartilage above to the middle of Poupart below and two horizontal, one at the level of the 10th. costal cartilage the other at the level of the highest point of the iliac crest.

THE PERITONEUM is a serous membrane having a visceral and a parietal layer. In the male it is a closed sac, in the female the sac is open at the terminations of the fallopian tubes. Where the visceral and parietal layers become continuous we have a point of reflection, this holds good in any serous membrane The peritoneum differs from all the other serous membranes of the body in that having many viscera to cover and almost all being freely moveable it is necessarily complicated. In the female there are extra folds for the covering of the uterus and ovaries. The peritoneal cavity contains nothing but a few drops of fluid, all the viscera lying outside of it, invested by it. An Omentum is a double fold of peritoneum which connects the stomach with any other viscus, of these omenta we have three, the gastro-colic, the gastro-hepatic and the gastro-splenic. A Mesentery is a double fold of peritoneum which connects any part of the alimentary canal, except the stomach, to the posterior abdominal wall, the following are the mesenteries, mesoduodenum, THE mesentery which attaches the jejunum, and ileum to the abdominal wall, the mesovermiform, the me-

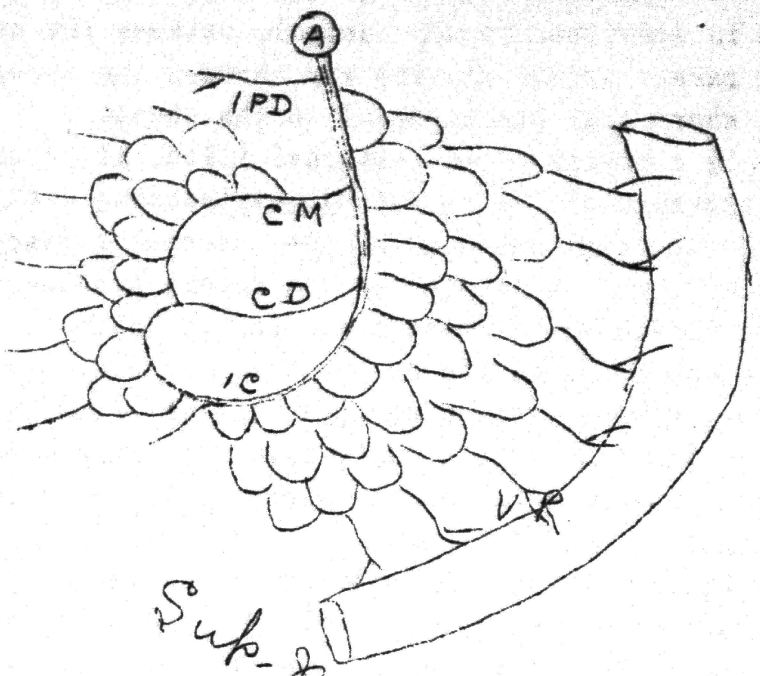

Sup. Mesenteric Art.



Sigmoid

Pelvic Line

Superior Hemorrhoidae

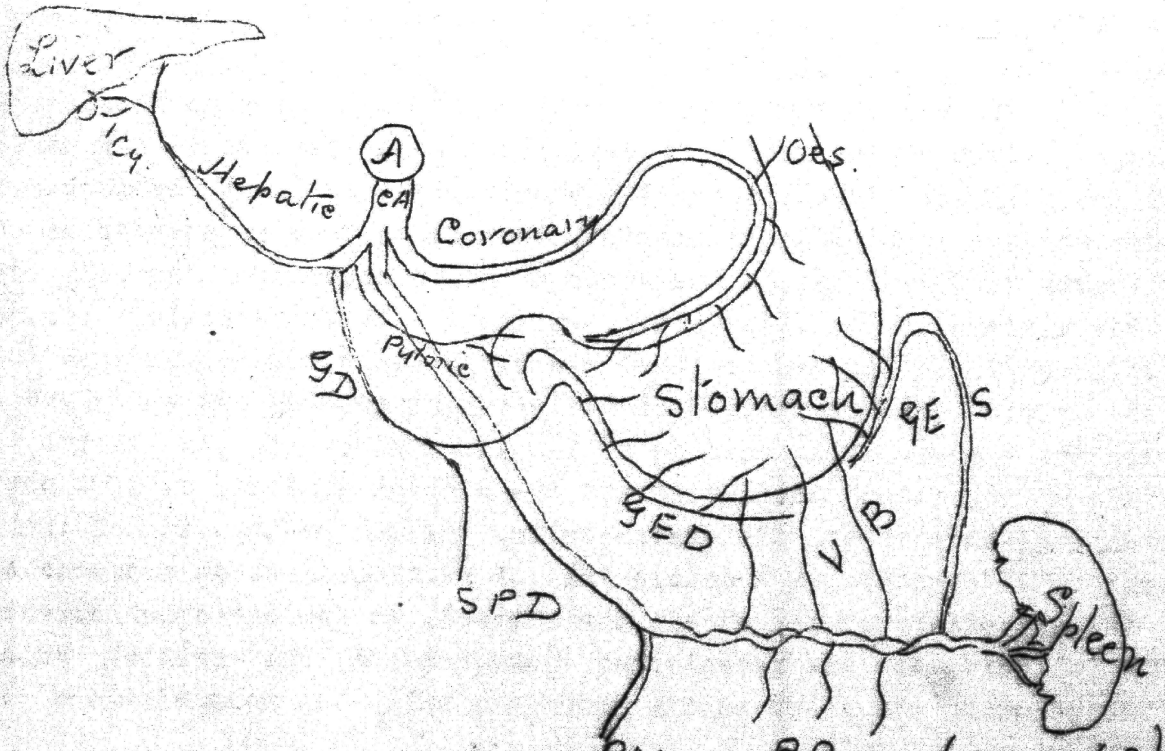

Coeliac Axis. (page 69)

socaecum, the mesocolon(transverse colon only), the mesosigmoid and mesorectu (first part only). A Ligament is a double fold of peritoneum connecting any visous except the alimentary canal with the abdominal wall., such are found in relation with the liver, the uterus, the ovaries and the bladder In considering the peritoneum it must be remembered that at an early stage in development the alimentary canal was a straight tube, this tube was invested with the peritoneal covering which attached it to the posterior wall of the abdomen. As time went on and the tube incresed in length and acquired a dilatation, the stomach, the tube with its peritoneal covering of necessity became convoluted. The stomach distinding led to a twisting round a vertical or rather oblique axis and so the peritoneal sac became constricted, by this twisting at a point which we call the foramen of Winslow and so the cavity of the peritoneum was imperfectly divided into two compartments which communicateby this aperture. There is no good attempting to relate the reflections of the peritoneum, they can be found in any work on anatomy. The foramen of Winslow admits two fingers and is foond by the following method, the liver and gall bladder are pulled well up, the finger of the other hand being then curved and passed behind the neck of the gall-bladder passes from the greater sac of the peritoneum into the lesser. The foramen of Winslow is bo nded by the caudate lobe of the liver above, below it the hepatic artery as it passes to the liver, with it the bile duct and portal vein, the same structures lying in front of it and behind it are the right crus of the diaphragm and the inferior vena cava. The mesentery is attached along an oblique line extending from the left side of the second lumbar vertebra to the middle of the right ilin-pectineal line.

MESENTERIC ARTERY; SUPERIOR. is the vessel which supplies almost all of the sma and half of the large intestine. It comes off the aorta opposite the 1st. lumba vertebra, behind the pancreas. It runs forw.rd between the pancreas and transverse duodenum, gives off the inferior pancreatico dundoenal branch, then curve strongly to the right from the left with a large sweep. From the convex side ar given off the vasa intestini tenuis which form a series of primary, secondary and tertiary loops. From the concave side are given off the ileo-colic, colica dextra and colica media to the lower and of the ileum and commencement of the colon, ascending and transverse colon respectively. The branches to the intestine all form loops as in the case of the vasa intestini tenuis. The superior pancreatico duodenal artery from the gastro-duodenal anastomoses with the infer ior from the superior mesenteric. The inferior mesenterico duodenal runs betwee the head of the pancreas and the duodenum and gives branches to both structures

Branches of the mesenteric vein correspond fairly closely to the arteries, th vein as will be seen later unites with the splenic to form the portal. To see the superior mesenteric artery all the intestines have to be turned over to the left side, to see the inferior mesenteric artery they must now be turned over to the right.

INFERIOR MESENTERIC ARTERY, is given off from the aorta about an inch and a hal above its bifurcation, it takes a course downward and to the left. It gives off the colica ~~dextra~~ sinistra to the descending colon, three or four sigmoid branches to the sigmoid flexure and the superior hemorrhoidal to the first part of the rectum The inferior mesenteric vein has branches corresponding to the arterial branches, the lowest of these is the superior hemorrhoidal which enters into a free anastomosis with the middle hemorrhoidal from the internal iliac. The in-

ferior mesenteric vein passes up to join the splenic or superior mesenteric on pulling up the liver and drawing down the stomach and removing the lesser omentum near the free border of the latter will be found the bile-duct to the right and most anterior, to the left the hepatic artery and behind and between them the portal vein. Behind the lesser omentum in the middle line is the COELIAC AXIS which is given off from the front of the aorta and is only half an inch in length. It divides into three, the coronary or gastric which passes to the stomach, lesser curvature, with a double curve, first upward and to the right, then downward and to the left. it runs down the lesser curvature of the stomach and gives off an oesophageal branch to the lower end of the oesophagusIt gives branches to both surfaces of the stomach and enters into a free anastomosis. The HEPATIC ARTERY is medium in size, it runs up behind the firs first part of the duodenum, lying in the lesser omentum, and so reaches the transverse fissure of the liver where it divides into two branches, a right and a left, the right most commonly giving off the cystic branch to the gall bladder. The artery gives off pyloric branches to the pyloric end of the stomach ((anastomoses with coronary)and the gastro-duodenal which passes down behind the first part of the duodenum and divides into the superior pancreatico duodenal and gastro-epiploica dextra. The gastro-epiploica dextra runs from right to left along the greater curvature of the stomach, while the superior pancreatico duodenal is foond between the head of the pancreas and the duodenum. THE SPLENIC ARTERY, is very large and takes a very tortuous course along the upper border of the pancreas. It runs behind the stomach to the spleen and enters the hilum. It gives off the gastro-epiploica sinistra, which runs along the greater curvature of the stomach from left to right, vasa brevia to the stomach, pancreaticae parvae,(small branches to the pancreas) and the pancreatica magna which also enters the pancreas. As the artery enters the spleen it breaks up into five or six branches..

DISSECTION TO EXPOSE COELIAC AXIS abdomen opened by cross cut, pull down the great omentum, cut through the lesser omentum and strip off the posterior layer of the lesser bag. THE SPLENIC VEIN is placed below its artery and lies behind the upper border of the pancreas. It receives tributaries corresponding to the branhhes of the artery and usually also the inferior mesenteric vein but it is fairly common for the latter to enter the superior vein. The vein unites with the superior mesenteric behind the upper border of the head of the pancreas, the two forming the vena porta.

THE STOMACH lies very obliquely in the abdomen, it is somewhat pear-shaped and is everywhere covered by peritoneum except a small triangular surface near the oesophagus. Its surfaces are superO-anterior and infero-posterior. It receives at its larger or cardiac end the oesophagus and ends in a smaller or pyloric extremity in the duodenum. The expansion on the left of the oespphagus is called the fundus, this portion lies nearest to the heart and is separated from it only by the diaphragm and pericardium. Connecting the fundus with the pyloric end is the body, which is bounded above by the lesser curvature, below by the greater, the lesser curve is connected with the lesser omentum and the greater curvature is is connected with the greater omentum below and the gastro-splenic omentum on the left. Along the upper curvature runs the coronary artery while the gastro-epiploica sinistra and dextra run along the greater.

The oesophageal orifce lies about an inch to the left of the middle line on a level with the tenth dorsal vertebra and behind the junction of the 7th. costal cartilage with the sternum. The pyloric orifce lies betind the quadrate lobe of the liver on a level with the first lumbar vertebra and about two inches to the right of the median line, but it extends more to the right when much distended, more to the left when quite empty. The antero-superior surface is opposed to the left lobe and part of the lobus quadratus of the liver, the diaphragm and the fascia transversalis. The posterior surface is related to the spleen, the pancreas, left kidney and supra-renal body, third stage of the duodenum near its termination, the splenic and left renal vessels, the commencement of the abdominal aorta, the solar plexus and the semilunar ganglia and the crura of the diaphragm. Below it is in relation with the transversa colon, the spleen lies to the left of the fundus as well as behind. The muscular coat of the stomach has three layers, an internal of circular fibres, chiefly found near the pylorus where a strengthening of the fibres constitutes a perfectly competent valve; an oblique which is found near the cardiac end and is mainly continuous with the circular fibres of the oesophagus and a longitudinal layer which exists chiefly along the curvatures and is continuous with the longitudinal fibres of the oesophagus. The stomach receives its blood supply from five arteries, the coronary from the coeliac axis, the pyloric branch of the hepatic, the gastro-epiploica dextra from the gastro-duodenal the vasa brevia of the splenic and the gastro-epiploica sinistra from the splenic. There is a free anastomosis is all over the distribution of these arteries. The veins of the stomach open into the portal. The nerves of the stomach are branches of the sympathetic and the vagi, of the latter the right supplies the posterior surface the left supplies the front. The areolar or submucous coat of the stomach consists of areolar tissue in which ramify the vessels and a very free plexus of lymphatims and between the mucous coat and this coat there is a thin layer of non-striate muscular tissue. The mucous membrane is arranged in longitudinal folds or rugae whilh disappear when the organ is distended, the mucous membrane is thick and soft, the surface is divided into a number of shallow alveoli at the bottom of which open the tubes which secrete the gastric juice and mucus. Solitary glands are scattered over the surface of the interior of the organ.

THE SMALL INTESTINE extends from the pyloric valve to the ileo-colic valve, is about 21 feet in length (but varies much) of this the duodenum occupies about ten inches, of the balance the jejunum takes two fifths, the ileum three- fifth The small intestine can be distinguished from large by three points, in adult life the large intestine is larger, (in the foetus they are the same size, the small may even be larger than the large) the large intestine is sacculated owing to the peculiar disposition of its muscular tissue; and in the large intestine we find on its outer surface the appendices epiploicae, stalked masses of fat covered by peritoneum.

THE DUODENUM is about ten inches in length, is divided into three parts, ascending, transverse and descending (the descending portion is the second). It extends from the pyloric orifice of the stomach to the left side of the second lumbar vertebra. The first part, or ascending, ends at the transverse fissure of the liver, the second, or descending, at the right side of the third lumbar vertebra, the third, transverse, at the left side of the second lumbar, so it will be seen that the third portion is really an ascending portion. . The

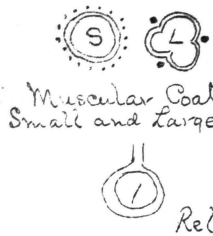



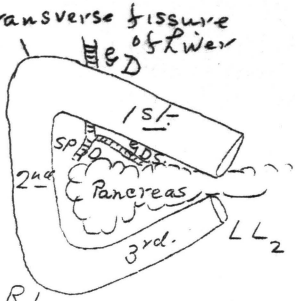

The Duodenum.

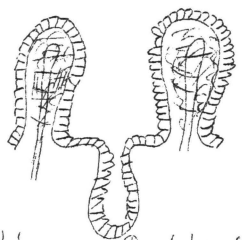

Villi and Crypt of Lieber-Kuhn.

Hepatic Flexure

Splenic Flexure

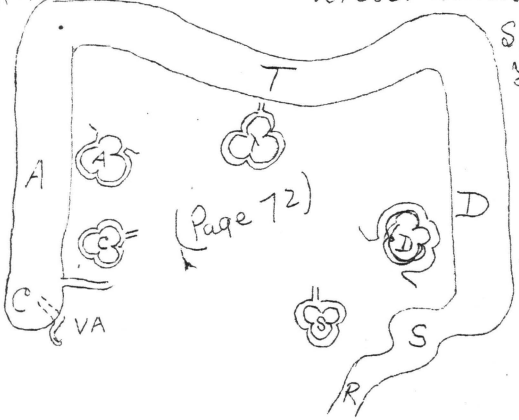

first portion has in front of it the lobus quadratus and the adjacent portion of the right lobe proper of the liver and the gall bladder, behind it are the common bile duct, the vena porta and the gastro-duodenal artery and a portion of the head of the panoreas. It rests against a special impression on the liver in front of the lobus caudatus, internal to and between the renal and colic impressions. The second part is partially covered by the peritoneum and has in front of it the right extremity of the transverse colon, behind it are the right kidney and it lies in contact with the outer side of the head of the pancreas the pancreatico-duodenal vessels intervening. The third or transverse portion is fixed to the abdominal wall below the line of attachment of the meso colon and is covered in front by peritoneum save where it is crossed by the superior mesenteric vessels. It runs obliquely upward and to the left crossing the vena cava, aorta and thoracic duct as also the crus of the diaphragm This is the most fixed portion of the intestine.

THE JEJUNUM and ILEUM are completely covered by peritoneum except at the interval between the two laminae of the serous membrane and are fixed to the spine by the mesentery. Valvulae conniventes are found in the small intestine, these are reduplications of the mucous membrane which are almost transverse and very seldom join one another, they are characteristic of man. The villi are just visible to the eye. A villus is a club-shaped projection from the wall of the intestine and is covered by columnar epithelium. In the center we have a minute mass of connective tissue and in it a lacteal vessel, there is also a minute artery and vein and also some muscular tissue. Lieberkuhn's glands also exist, they are like test-tubes lined with columnar epithelium, they secrete intestinal juice or succus entericus. Peyer's patches do not, practically speaking, exist after 12 years of age. In the adult the glandular tissue of which they were once composed is only represented by a thin intestinal wall. Each patch is about one to four inches in length, and lies opposite the attachment of the mesentery. The patch consisted at the time when it was a gland of many solitary glands held together by fibrous tissue and a fairly well-defined capsule. A peyer(patch in adult life secretes nothing. In typhoid efer these are the portions of intestine which are most apt to undergo destructive ulceration. On the surface of a peyer patch villi are not present. As regards the division of the small intestine the jejunum is well marked off from the duodenum by the second lumbar vertebra, but no such sharp distinction can be drawn between the ileum and the jejunum. The LARGE INTESTINE begins at the ileo-colic valve and ends at the anus. It will be noted as a wide, sacculated tube averaging six feet in length. It commences in the right iliac fossa and is divided into three parts, the caecum or caput coli the colon and the rectum. The caecum is a short but capacious cul-de-sac about 2½ inches in length lying below the point of entrance of the ileum into the large intestine. It has a mesentery and attached to it, usually to its back and lower part, is the little vermiform appendix, a developmental remnant.. On the inner side of the caecum lie the small intestines and the junction of the colon and ileum. The vermiform appendix is a blind tubular prolongation of diameter of a goose quill averaging from 2½ TO 3 inches in length, is variously bent and curved. It is provided with a mesentery, it is the remnant of the large caecum of the herbivora. The colon is divided into four parts, ascending, dransverse, descending and the sigmoid flexure. Its entire length averages about 4½ feet. The

caecum and colon have their muscular tissue arranged in a different manner from that of the small intestine, the longitudinal fibres being arranged in three bands, two of whimh can be seen through the peritoneum, the third lying between the layers of the mesocolon. In the rectum the fibres once more have the ordinary position and arrangement. The longitudinal bands of fibres being shorter than the intestine the latter is drawn up so as to have a sacculated appearance. The ileo-coecal valve is formed by a prolongation of the mucous membrane and the circular fibres of the intestine into the cavity of the caecum and it appears as a slit-like aperture bounded by two folds, the upper of which is horizontal in direction, the lower somewhat more vertical. This valve opposes regurgitation. The mucous membrane of the large intestine has no villi, as these cease abruptly at the ileo-colic aperture, but is like that of the small intestine in having columnar epithelium, tubular glands like the crypts of Lieberkuhn and solitary glands.. The ascending colon is usually covered with peritoneum only in front and laterally. It begins in the right iliac fossa at the level of the anterior superior spine, lies in front of the right kidney external to the second part of the duodenum, reaches the inner surface of the right lobe of the liver inferiorly forming the hepatic flexure and is succeeded by the transverse colon. The transverse colon is invested by peritoneum derived from both sacs and runs in a curved direction inward, forward and downward opposite the umbilicus, then outward, backward and upward to terminate at the lower end of the spleen in the splenic flexure, it is succeeded by the descending colon. The descending colon begins below the splenic flexure, is usually bound down to the posterior abdominal wall without a mesentery, being covered by peritoneum in front and laterally, passes down over the front of the left kidney, the transversalis tendon and the crest of the ilium to enter the iliac fossa. The gut then develops a mesentery and is known as the sigmoid flexuse. The sigmoid flexure resembles the rest of the colon but has a mesentery. It first runs downward and forward reaching the anterior abdominal wall on the inner side of the anterior superior spine of the ilium, thence passes back into the true pelvis, turning upon itself in a sigmoid manner, at length loses its mesentery opposite the third sacral vertebra, but at that time is more generally considered to be the first part of the rectum. . The rectum is said to begin at the left sacro-iliac symchondrosis. The rectum is 8 or 9 inches in length and extends from the left sacro-iliac joint to the anus. The first portion is about 4 inches in length and terminates at the third sacral joint, it has a mesentery. The second portion, three inches in length, ends at the tip of the coccyx, the third is about an inch in length and terminates at the anus or skin surface. The first portion of the rectum is marked off from the sigmoid flexure by the absence of sacculation, the second portion has peritoneum in front over its upper third. The direction of the first part is downward, backward and inward, of the second downward and forward, and of the third downward and backward.. The anal orifice is surrounded by the external sphincter and the third portion of the rectum has its circular fibres much thickened forming the internal sphincter. This portion of the canal has its walls in apposition and the mucous membrane is thrown into folds, the columns of Morgagni. This one inch anal canal is converted into a 4-inch passage in the erect posture by the approximation of the buttocks. The internal appearance of the rectum will be seen later with the other pelvic organs.

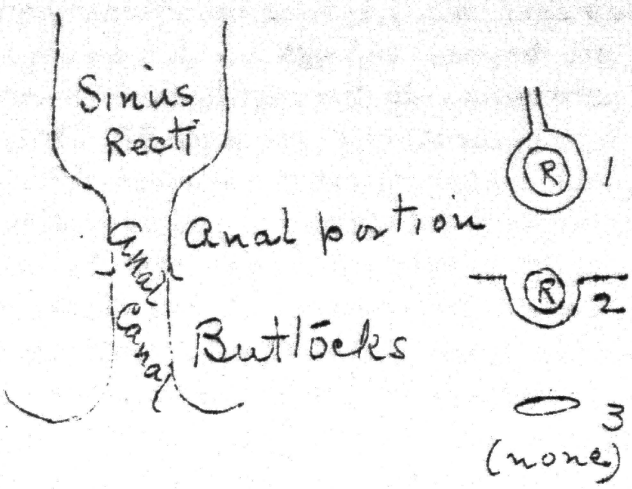

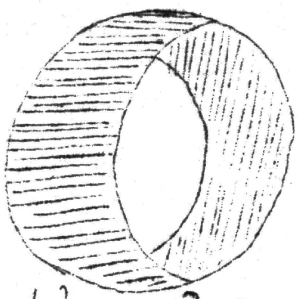

3rd sphincter from below.

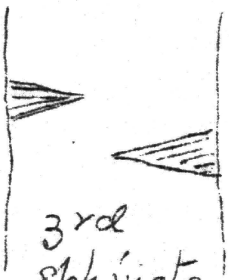

3rd sphincter

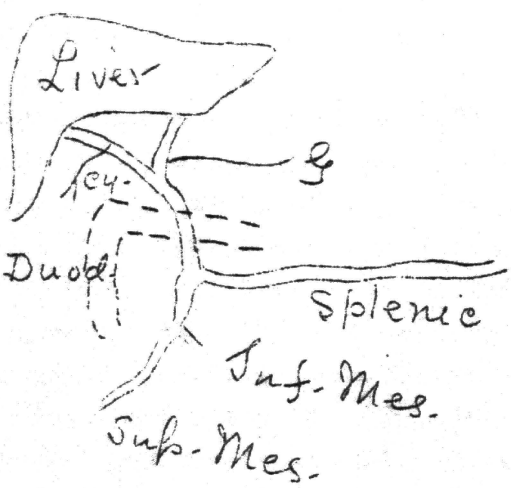

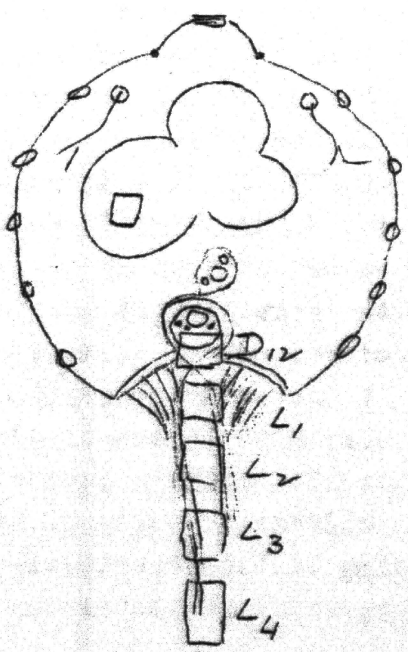

THE PANCREAS lies transversely in the abdomen and is subdivided into a head, a body and a tail. The head is embraced by the concavity of the duodenum and sends a processdownward and inward behind the superior mesenteric vessels, the body is concave posteriorly and crosses the aorta and left kidney opposite the 1st. lumbar vertebra, the tail runsx in the gastro-splenic omentum to come in contact with the the lower and back part of the visceral surface of the spleen. In front of the pancreas we have peritoneum, the posterior layer of the lesser bag) more anteriorly toward its lower border is the transverse colon, while in front again we have the stomach. It rests upon the crura of the diaphragm, the vena cava, the commencement of the portal vein and its formative branches, the superior mestenteric and splenic veins as also the inferior mesenteric, the aorta and the commencement of the superior mesenteric artery, the thoracic duct, the azygos veins, the left kidney and ad-renal body and the sympathetic nerves.

On splitting open the pancreas its duct is seen, the canal of Wirsung, and this runs from left to right and opens into the 2nd. part of the duodenum in common with the ductus communis choledochus upon the summit of a small papilla. The pancreas is well supplied with blood receiving the pancreaticae parvae and pancreatica magna from the splenic, thhe superior pancreaticoo duodenal from the gastro-duodenal, the inferior pancreaticoo duodenal from the superior mesenteric.

DISSECTION TO EXPOSE THE PANCREAS open abdomen by a cross cut, pull the great omentum well up over chest, cut through the mesentery, strip off the posterior layer of the lesser bag.

THE BILE DUCT can be traced up to the liver from the second portion of the duodenum. It commences in right and left hepatic ducts which emerge from the transverse fissure of the liver and unite to form the common hepatic duct, this is joined at an acute angle by the cystic duct and now we have the common bile duct or ductuss communis choledochus. It at first lies between the layers of the lesser omentum to the right of the hepatic artery, then passes behind the first part of the duodenum to open into the back part of the second.

THE PORTAL VEIN is formed to the right of the median line by the junction of the of the superior mesenteric with the splenic, the inferior mesenteric opening into one or other of the mormative branches. The junction occurs behind the upper border of the pancreas immediately in front of the vena cava. The vein is 4 inches long, ascends betweenthe layers of the lesser omentum to the transwerse fissure of the liver, between and behind the hepatic artery and bile duct. It receives the gastric and cystic veins, has no valves.

THE SPLEEN is a flattened organ of purple color, oval in outline which lies in back part of the left hypochondrium opposite the 9th., 10th. and 11th. ribs, its long axis lying in the axis of the 10th. It is attached to the stomach by the gastro-splenic omentum and to the diaphragm by the phrenico-splenic ligament (or lieno-phrenic) Its parietal surface is in contact with the diaphragm and its visceral surface is divided into two parts, the posterior of which is in relation with the left kidney and ad-renal body, the anterior in relation to the stomach tail of the pancreas and the splenic flexure of the colon. The anterior border is notched and sharp, the posterior is blunt and rounded. Its visceral surface shows between its sub-divisions the hilum, here the splenic artery is seen breaking up into some half dozen divisions before entering the substance of the organ. The spleen has three sets of movements, it moves with the diaphragm, it enlarges during digestion and it has a regular pulsation, about one or two beat

per minute. Its weight averages 6 ounces, but varies within wide limits.. The spleen is completely invested with peritoneum save at the hilum.

THE DIAPHRAGM is an arched muscle with its concavity toward the abdomen. It rises to the level of the 5th. costal cartil.ge at its junction with the sternum on the right side and as high as the 6th. on the left. Origin, ensiform cartilagex, the inner surfaces of the cartilages of the lower six ribs interdigitating with the transversalis from the internal and external arcuate ligaments which are really the free borders of the muscle bridging over, the internal the psoasand the sympatheteic nerve, the external the quadratus lumborum and the last dorsal nerve, and by two muscular crura which are attached to the lumbar vertebrae, the right crus is the larger and extends down as low as the 4th. lumbar vertebra while the left goes down as fas the third. The Insertion of the muscle is into the central tendon, which is roughly trefoil in shape and the muscle is supplied by the phrenic nerves. The ligamentum arcuatum externum is a fibrous arch stretching from the from the transverse process of the last lumbar verbebra to the tip of the last rib, the ligamentum arcuatum internum is a similar arch extending from the the outer border of the crus to the tip of the transverse proce s of the last lumbar vertebra. The inner fibres of the crur decussate with one another and form a figure of 8 before they pass into the central tendon, thus almost completely surrounding the aorta and the oesophageal openings. The right leaflet of the trefoil or central tendon is somewhat the larger. In the diaphragm there are several openings, one for the aorta which is really behind the diaphragm between the crura, this opening is bounded anteriorly by the muscular fibres of the crura forming the first part of the figure-of-8 loop, and through this opening pass the aorta, the vena azygos major and the thoracic duct. The oesophageal opening lies at the level of the 9th. dorsal vertebra (the aortic opening is at the level of the 12th.) and this opening lies entirely surrounded by the muscular fibres from the crura, now finishing the figure of 8. This opening transmits the oesophagus and the two vagi. The opening for the inferior vena cava is also at the level of the 9th. dorsal vertebra and is situated so that it is in the central tendon and the walls of the vein are firmly attached to the margins of the opening. A branch of the phrenic nerve also passes through this opening to be distributed to the upper surface of the liver. The greater and lesser splanchnic nerves pierce the crus on either side and the vena azygos minor also passes through on the left. The sternal triangle on either side of the ensiform cartilage transmits the the superior epigastric vessels. The diaphragm is essentially a muscle of inspiration buthas many other functions being concerned in all movements involving the compression of the abdominal contents or the enlargement of the cavity of the thorax. The muscle is supplied by the phrenic nerves which pierce it and supply it on its under surface. Its arteries are the musculo-phrenic from the internal mammary, the phrenic from the aorta, and the comes nervi phrenici from the internal mammary..

The SYMPATHETIC NERVE IN THE ABDOMEN on each side of the aorta and close to the crura of the diaphragm is a small, crescentic body of a pinkish color, the semilunar ganglion, to which passes the great splanchnic nerve from the thoracic sympathetic ganglia. The solar plexus is formed by the passage from one semilunar ganglion to the other of fibres around the coeliac axis and superior mesenteric artery. It receives the middle splanchnic nerve and gives branches to the aortic plexus and others distributed on all the main branches of the aorta.

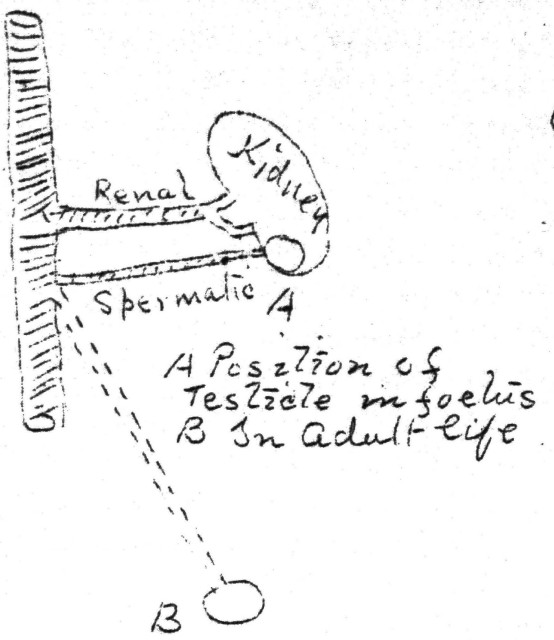

A Position of Testicle in foetus
B In adult life



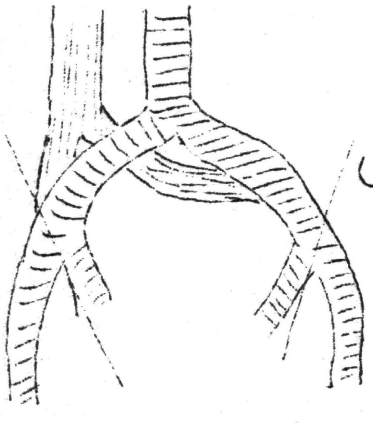



The least splanchnic nerve may be traced, sometimes, into the renal plexus. THE ABDOMINAL AORTA is the direct continuation of the thoracic aorta and enters the abdomen by passing behind the diaphragm through the so-called aortic opening. it extends from the front of the twelfth dorsal vertebra to the left side of the 4th. lumbar, where it divides into the common iliac arteries. It rapidly decreases in size as it passes down, giving off large branches. Relations, anteriorly, liver, stomach, transverse colon, small intestine and peritoneum and in more immediate contact the pancreas with the splenic vein, the left renal vein, the transverse duodenum and its anterior branches. Behind are the bodies of the lumbar vertebrae and their ligaments and the left lumbar veins. The vena cava lies to its right side below, above is the right crus and deeply placed between the aorta and the right crus are the receptaculum chyli and the thoracic duct with the vena azygos major. To the left are the gangliated cord of the sympathetic, the left crus, the splanchnic nerves and the beginnign of the vena azygos minor. The BRANCHES are divided into paired and unpaired, of the former group are the phrenics, two small branches which may come off from the aorta or one of its higher branches. They are distributed on the under surface of the diaphragm and anastomose with the other branches of supply to that muscle. Each supplies a small branch to the ad-renal body, the superior capsulara The right vein opens into the cava, the left into the renal. The coeliac axis has been already described., as has also the superior mesenteric. The supra renal arteries, or middle capsular, arise opposite the first lumbar vertebra and pass one on either side transversely to the ad renal bodies, the right going beneath the vena cava. The renal arteries are large and arise from the sides of the aorta immediately below the capsular arteries about half an inch below th the superior mesenteric. They run transversely to the concave border of the kidney, the right going behind the vena cava. The artery breaks up into three or four branches before entering the hilum of the kidney but on the whole the relation of structures at the hilum is the same from before backward vein, artery, ureter. The renal or emulgent veins open into the vena cava, the left crossing in front of the aorta immediately below the superior mesenteric artery and receiving the left spermatic, phrenic and supra-renal veins. The spermatic arteries are very long slender branches which arise from the front of the aorta abou an inch below the renals and pass down behind the peritoneum to the internal abdominal ring and through the inguinal canal to the testis. The right crosses obliquely the vena cava and each crosses the psoas, the ureter and the genitocrural nerve and, near Poupart, the external iliac vessels. In the female the spermatic arteries become the ovarian and pass into the pelvis to ramify in the broad ligament. One small twig accompanies the round ligament to the inguinal canal, another runs along the fallopian tube and a third supplies part of the uterus anastomosing with the uterine branch of the internal iliac. The spermatic veins form a plexus round the arteries and open the right into the vena cava the left into the renal.. The inferior mesenteric artery has been already described. The middle sacral is the direct continuation of the aorta passes down into the pelvis along the middle of the sacrum. It anastomoses with the lateral sacral branches of the internal iliac. The vein opens into the left common ilia vein. The lumbar arteries are usually four in number on each side, they come from the back of the aorta and lie on the bodies of the vertebrae. The upper a eries pass under the crura of the diaphragm. When followed out they are found divide into an anterior and a posterior branch, the anterior runs between the

abdominal muscles to supply them and anastomose with the other arteries which run there, the posterior branch passes between the transverse processes subdividing into muscular branches to the erector spinae and other musoles and spinal to the vertebral canal through the intervertebral foramina. The lumbar veins open into the vena cava.

THE COMMON ILIAC ARTERIES, extend from the left side of the 4th. lumbar vertebra to the upper part of the sacro iliac joint where they divide into the internal and external iliac arteries. The right is slightly longer than the left owing to the bifurcation taking place on the left side of the median line. Anteriorly we have some relations common to both arteries, they are both covered by peritoneum and have crossing them near their termination the ureter, but the left in addition has crossing it the rectum and the superior hemorrhoidal vesselsposteriorly, both arteries rest upon the vertebral column and have their own vein behind, but the right artery has in addition high up the left vein as it passes to unite with the right vein to form the inferior vena cava. The only branches, if any, will be small muscular twigs to the iliacus and the ureter.

COMMON ILIAC VEINS the left common iliac vein lies to the inner side of its artery, then passes behind the right artery to reach the vena cava, while th right vein is at first behind then ti the outer side of its artery. They receive the lateral sacral and ilio-lumbar veins and the middle sacral vein enters the left common iliac.

INFERIOR VENA CAVA lies to the right of the aorta, it is close to it below but is separated from it by a considerable interval above and is longer than the aorta for the reason that it is formed at a lower level and passes through the diaphragm at a higher level. The vein is also greater in capacity than the aorta. It is formed by the junction of the two common iliac veins on the right of the 5th. lumbar vertebra and keeps to the right of the vertebral column as high up as the liver, when it passes somewhat forward entering a deep groove, sometimes actually a tunnel, between the lobus spigelii and the right lobe proper and receives the hepatic veins, then passes through the quadrilateral opening in the diaphragm. Anteriorly to the vein we have peritoneum with the foramen of Winslow, the duodenum, the pancreas, the liver, the portal vein and the right spermatic vein, Behind it are the vertebral column, the right crus, right capsular, phrenic, renal and supra-renaland lumbar arteries, the right sympathetic . To the right of the vein lie the kidney and ureter, to the left the aorta and thoracic duct, the commencement of the azygos major and the solar plexus and semilunar ganglion. It receives the right lumbar, left lumbar, right spermatic, renal, right supra-renal and right phrenic veins and as it pa ses throughthe liver the hepatic veins open into it.

EXTERNAL ILIAC ARTERY, extends from the upper part of the sacro-iliac joint to Poupart's ligament, under wtich it passes to begin as the common femoral. It runs along the brim of the true pelvis and both arteries are of the same length. Relations, Anteriorly, small intestine and peritoneum and nerves, and near its termination it isPorcssed by the spermatic wessels, genito-crural nerve, vas deferens and the circumflex iliac vein. It lies upon its own vein and the psoas musole and the psoas also lies external to it. Occasionally the ureter also crosses it. Branches, the deep epigastric and the deep circumflex iliac are usually given off just above Poupart's ligament, but may spring from the femora

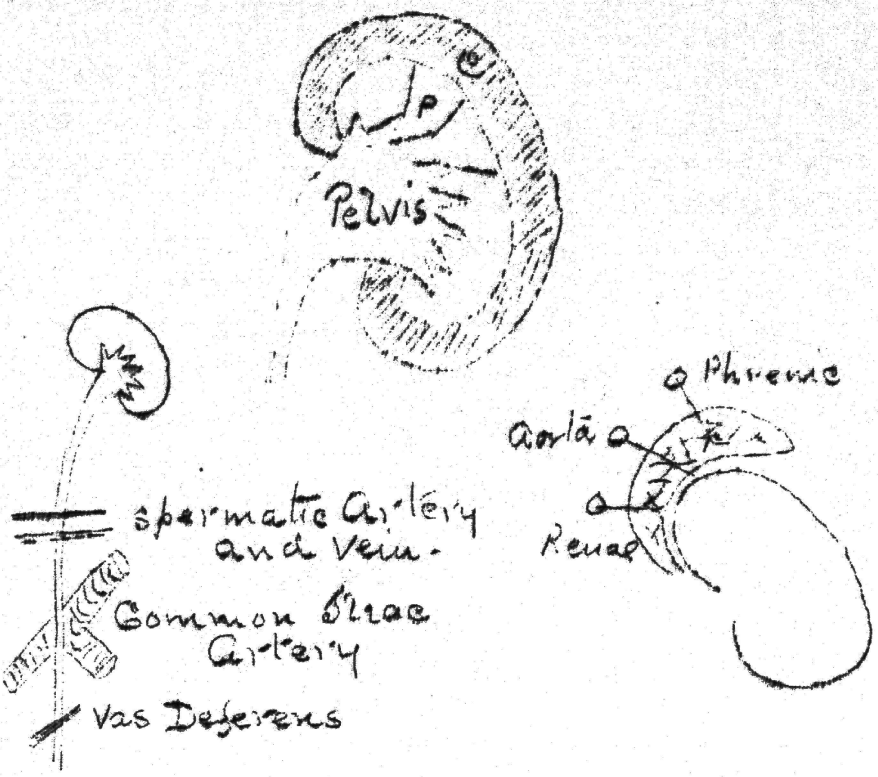



The Lumbar Plexus in Relation to Psoas.

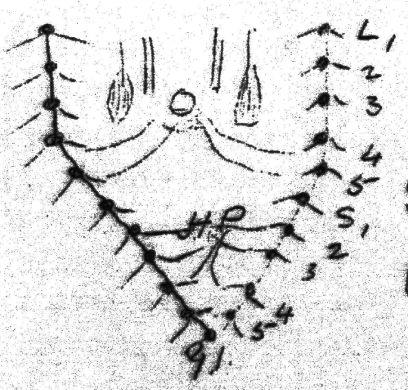

Sympathetic in Abdomen.

below the ligament. The epigastric passes inward and upward immediately outside the peritoneum as already described with regard to the rectus muscle and Heselbach's triangle. An abnormal branch is sometimes found coming off this artery close to its origin and escending into the pelvis, this is the obturator and as it lies, when it occurs, close to the inner side of the crural canal and neck of the sac in a case of femoral hernia might give rise to danger in operating. It has to be borne in mind by the surgeon. The circumflex runs out along Poupart, lies at first outside the peritoneum, pierces the transversalis fascia and muscle and runs along the crest of the ilium.

THE KIDNEYS are a pair of bean-shaped organs, each is about 4½ inches in length 2½ in breadth and an inch and a quarter in thickness, they lie behind the peritoneum in a kind of lymph space in the sub-peritoneal tissue opposite the last dorsal and the upper three lumbar, the right extending down half an inch further than the left. The long axis of eaah is directed downward and outward. the antero-external surface is directed outward and forward, the postero-internal is directed backward and inward. , the outer border is narrow and convex, its inner border is convex above and below, concave in the middle and is fissured by the hilum. The lower extremity lies further from the median line than the upper. The hilum is a slit-like aperture through which enter the artery and vein and which emits the ureter. It communicates with the pelvis of the kidney the dilated extremity of the ureter, into which project a series of papillae containing the termi ations of the uriniferous tubules. Relations, . anteriorly Left kidney, descending colon, the spleen, the pancreas and the parietal peritoneum. In front of the right are the right lobe of the liver, the ascending colon, the second stage of the duodenum and the parietal peritoneum. Behind both are the diaphragm, the psoas and the anterior lamella of the lumbar fascia containing the quadratus lumborum. . The kidney shows on section two areas of tissue and the pelvis, the cortical portion is more pale than the more central portion and has in it little dark spots, the malpighian tufts, the medullary or central portion is built up of the malpighian pyramids, and these consists for the most part of the uriniferous tubules. The kidney is surrounded by a capsule which in health is readily stripped off and under t is lies a special series of veins, t e stellate. The pelvisis the dilated extremity of the ureter, and has a direction downward, owing to the tilting of the kidney, it is broken up into infundibula and off these there open little depressions called calices. Into these project the papillae carrying the uriniferous tubules or ducts. The URETER begins in the pelvis of the kidney, is about 18 inches long. It ends in the bladder by piercing its wall very obliquely, taking nearly an inch to pass through, thus making the wall act as a kind of valve. The ureter runs downward and inward on the sheath of the psoas and enters the pelvis by crossing the bifurcation of the common iliac artery. It passes to the wall of the bladder lying on the posterior ligament of the bladder. Will be seen again in the pelvis.

THE SUPRA-RENAL BODY is a small cocked-hat-shaped body which never changes with age. It has a cortex and a medulla, the former yellowish in color, the latter dark brown. The body has a large blood supply, receiving blood from the phrenic the supra-renal and the inferior capsular from the renal. it is riddled with sympathetic nerves and where these cross one another are little swellings. This organ is about the first in the body to decompose. The right ad-renal body is in relation anteriorly with a special impression on the back of the right lobe

of the liver, below this with the peritoneum and .a msall portion of the duoden enum and is overlapped by the inferior vena cava along its inner border. The left is covered in front by the peritoneum of the lesser sac which separates it from the stomach, externally is relation with the spleen and extends along the inner border of the kidney as far as the hilum..

The iner surface of the muscles forming the posterior abdominal wall gets a covering of fascia which is named according to its muscle, the fascia transversalis being connected above with the tendon of the muscle at its attachment to the lumbar fascia and covers it as far as its attachment to the iliac crest and ilio-lumbar ligament.. The psoas fascia is attached to the lower edge of the ligamentum arcuatum internum and the vertebrae from which the muscle takes its origin and joins the fascia iliaca below. The fascia covering the iliacus is attached above to the inner lip of the iliac crest and is continuous below with the psoas fascia.

PSOAS MAGNUS, Origin, by five slips from thesides of the intervertebral discs between the last dorsal and the lumbar vertebrae and the adjacent parts of the bodies and roots of the transverse processes of these vertebrae, and from a series of arches crossing the constricted bodies of the four upper lumbar vertebrae. Insertion, lies in close relation to the iliac vessels and is inserted into the apex of the lesser trochanter.

PSOAS PARVUS, occasionally found. Origin, in front of the of the upper slip of the magnus from the Bodies of the last dorsal and first lumbar and the disc between them, insertion, by a long tendon into the ilio-pectineal eminence and part of the ilio-pectineal line, gives an expansion to the iliac fascia.

ILIACUS INTERNUS, upper half of the iliac fossa reaching the margins of the crest, iliac notch and anterior inferior spine, from the sacro-iliac and ilio-lumbar ligaments and from the capsule of the hip (often). Insertion, its fibres unite with the tendon of the psoas and are inserted into the lesser trochanter and the shaft for an inch below.

QUADRATUS LUMBORUM, is the short muscle filling the space between the crest and the last rib. Its orgin is below from the posterior portion of the inner lip of the crest of the ilium and the adjacent ilio-lumbar ligament, Insertion lower border of the last rib, and the tips of the transverse processes of the lumbar vertebrae.

NERVE SUPPLY OF THE ABOVE MUSCLES, psoas, lumbar nerves; iliacus, anterior crural, (intra pelvic branches); quadratus, posterior branches of lumbars.

THE LUMBAR PLEXUS. is a looped plexus derived from the the anterior primary divisions of the 1st., 2nd., 3rd., 4th., and 5th. lumbar nerves. The plexus lies in the substance of the psoas which must be removed to expose it and its branches are related to that muscle in three ways, external, aoterior and internal. The diagram of the plexus in relation to the muscle will show position The ilio-hypogastric and ilio-inguinal arise from the 1st. nerve, they are often joined together and have a similar course, running on the quadr.tus lumborum and in the abdominal wall, each dividing into two branches, those of the ilio-hypogastric running one to the buttock in company with the buttock branch of the ilio-inguinal, the other running between the transversalis .nd internal oblique, becoming cutaneous 2 inches above the external abdominal ring. The branches of the ilio-inguinal are one to the buttock and one passing between the internal oblique and transversalis, enters the inguinal canal, passes out

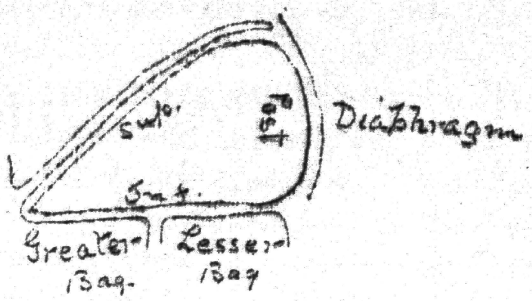
Diaphragm
Greater Sac.
Lesser Sac

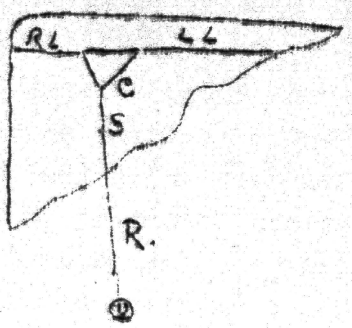
RL
LL
C
S
R.

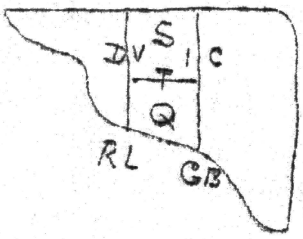
DV
S
C
Q
RL
GB

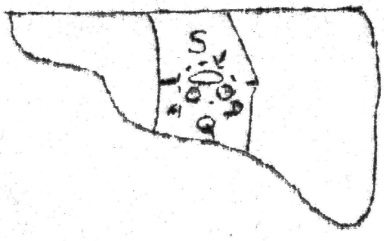
S
Q

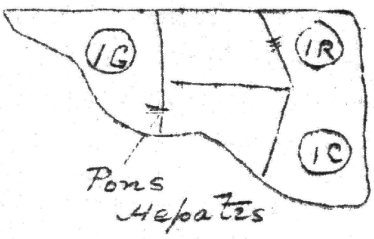
IG
IR
IC
Pons Hepatis

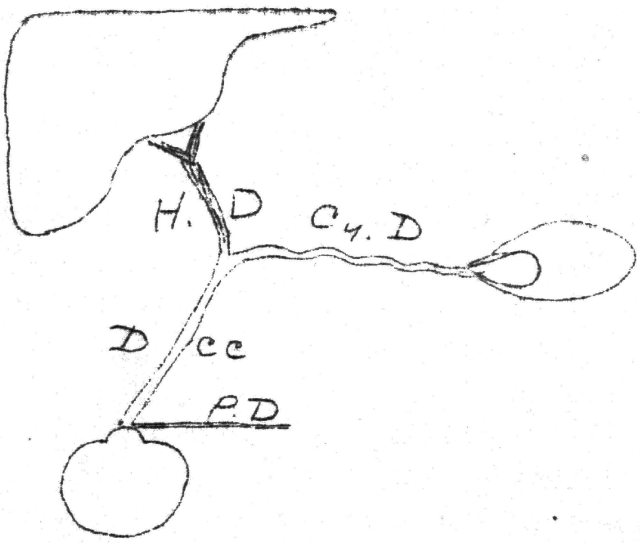
H. D
C4. D
D
CC
P.D

through the external abdominal ring and divides into two branches, one going to the scrotum, the other to the thigh. Genito crural nerve, derived from the 1st. and 2nd. nerves, pierces the substance of the psoas and lies anterior to it, runs down on it below its fascia and near the pelvis divides into two portions, one runs into the thigh under Poupart lying in the sheath of the femoral artery, the otherruns in the substance of the spermatic cord and supplies the cremaster. External cutaneous from the 2nd. and 3rd., an external branch, runs downward and outward on the quadratus lumborum and iliacus, enters thigh under Poupart between the two anterior spines of the ilium. It pierces the fascia lata about 4 inches below the anterior superior spioe. Anterior crural, from the 2nd. 3rd. and 4th. runs downward and outward lying on the iliacus, enters the thigh under Poupart lying between the psoas and iliacus, divides into a leash of nerves which are muscular and cuttaneous. Obturator nerve, from the 2nd., 3rd. and 4th. one of the internal branches, after a short course within the pelvis it leaves it by passing over the obturator membrane thhough the thyroic foramen it then divides into a superficial and deep branch. The lumbo sacral cord is always larger than the last and is derived from the 4th. and 5th. it enters the pelvés lying behihd the internal iliac artery. It joins the sacral plexus and gives off one branch called the superior gluteal..

GANGLIATED CORD OF THE SYMPATHETIC lies in each side of the vertebral column and behind the vena cava on the right. A ganglion is situated opposite each vertebra and these may be divided into sets which communicate with the ganglia above and below, communicate with spinal nerves and branches to the plexuses on neighboring arteries supplying the viscera, the vertebrae and ligaments. The branches to the spinal nerves are commonly two in number and accompany the lumbar arteries under the tendinous arches of the psoas.

RECEPTACULUM CHYLI is benind the right crus of the diaphragm, between the vena cava and the aorta opposite the 2nd. and 3rd. lumbar vertebrae

THE LIVER is the largest gland in the body it forms an almost complete arch across the body. It shows three surfaces, 5 ligaments, 5 lobes, 5 fissures, one border, 2 incisurae and 4 impressions. (the four impressions are those which were described before the models of His were made, we now know that the liver bears a good many more than four impressions of other structures.. Surfaces, superior, convex, lies in relation with under surface of diaphragm, Inferior, concave, both the superior and inferior surfaces are in relation to peritoneum, Posterior, not invested by peritoneum, is in relation to the diaphragm, is very irregular and is somewhat attached to the diaphragm. Ligaments, Falciform or suspensory, is one to two inches in breadth, is very lax and stretches from the front of the liver to the abdominal wall, along its free border runs the round ligament from the umbilicus to the under surface of the liver, The right and left lateral ligaments are the continuations to the right and the left of the margins of the falciform, between them lies the coronary formed in like manner. The round ligament is a fibrous cord which in the foetus was the umbilical vein passing from the placenta. Fissures, may all be seen on the under surface of the liver, for the ductus venosus, for the inferior vena cava, for the gall-bladder, for the round ligament and the transverse fissure connecting the other four and forming the cross bar of the letter H roughly marked out on the under surface of the liver. The structures found in the transverse fissure from before backward are the hepatic duct, the hepatic artery and the portal vein and

these are surrounded by the capsule of Glisson which accompanies them for some distance into the interior of the liver. On the upper surface we see 2 lobes, the right and the left, but on turning the inferior surface upward we find that the under surface of the right lobe is further subdivided so that we have on the under surface five lobes, the quadrate, bounded by the transverse fissure, the fissure for the round ligament and the fissure of the gall bladder; the spigelian lobe is mushroom like, it is bounded by the transverse fissure, the fissure for the ductus venosus and the fissure for the inferior vena cava. The caudate lobe in man is slightly marked and is a thin edge of liver substance extending from the lower end of the spigelian to the under surface of the right lobe proper. The anterior border of the liver is sharp and is marked by the two incisurae, the one for the round ligament the other for the gall bladder. The four impressions are that for the heart, for the stomach, the right kidney and the hepatic flexure of the colon. The liver and the pancreas are both developed from the hypoblast, being simply diverticula from the embryonic intestine around which the mesoblastic structure is built up. The hypoblast forms the ducts and the hepatic cells, the mesoblast furnishes the stroma, the blood vessels and connective tissue as also the nerves of the liver. The foetal liver differs from that of the adult in its relatively great size, the similarity in size of the right and left lobes, the large size of the caudate lobe and in the foetus its function is that of a a blood gland. The liver has two sets of movements, , it moves with the diaphragm on inspiration and it has a certain amount of rotation through a vertical axis owing to the looseness of the ligament.

THE GALL BLADDER is a little pyriform bag which is capable in full distension of containing two to four ounces and is attached to the liver by peritoneum and by connective tissue. From the apex of the gall bladder proceeds the cystic duct, the canal of which is exceedingly tortuous. The mucous membrane of the gall bladder is honey-combed and that of the cystic duct has a series of spiral folds in it, the valves of Heister. From the transverse fissure of the liver proceed two hepatic ducts and these unite and form a single duct which is joined by the cystic, the combined duct being now called the ductus communis choledochus which opens into the back of the 2nd. part of the duodenum in common with the pancreatic duct. The opening of the duct is guarded by a sphincter, the gall bladder has a wall in which there is much muscle and as food passes along the duodenum an impulse is sent to the muscular wall of the gall bladder, at once it contracts, the sphincter is relaxed and the bile is poured out on the food.

THE PELVIS, the parietal layer of the peritoneum passes down on the anterior abdominal wall to the upper part of the pubis, overlying the obliterated hypogastric arteries and the urachus, it passes on to the anterior and upper part of the bladder, dips down slightly between the bladder and rectum and then forms a complete investment for the first part of the rectum. Betweenthe rectum and bladder there is thus formed a depression which is called the recto-vesical pouch of peritoneum, as it passes thus overlying the obliterated hypogastric arteries and the ureters it forms what are called the posterior false ligaments of the bladder, passing from the sides of the bladder to the pelvis it forms the lateral false ligaments, while where it overlies the ura-

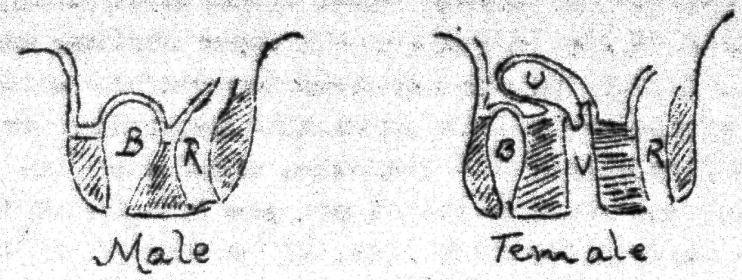
B
R
Male
U
B
V
R
Female

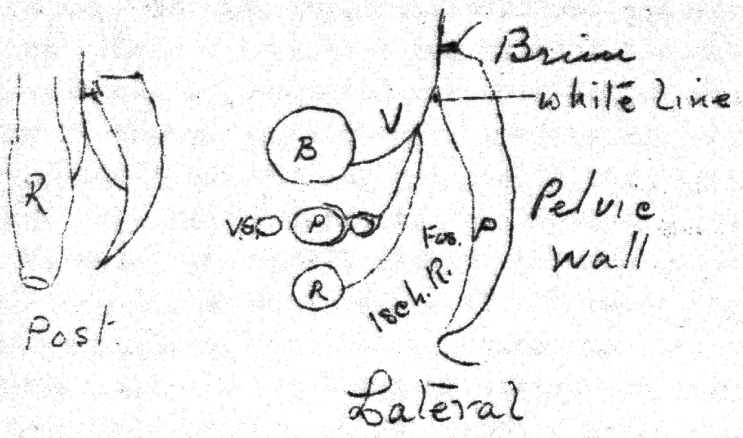
R
Post.
Brim
white line
B
V
VDP
P
R
Fos.
Isch. R.
Pelvic
Wall
Lateral

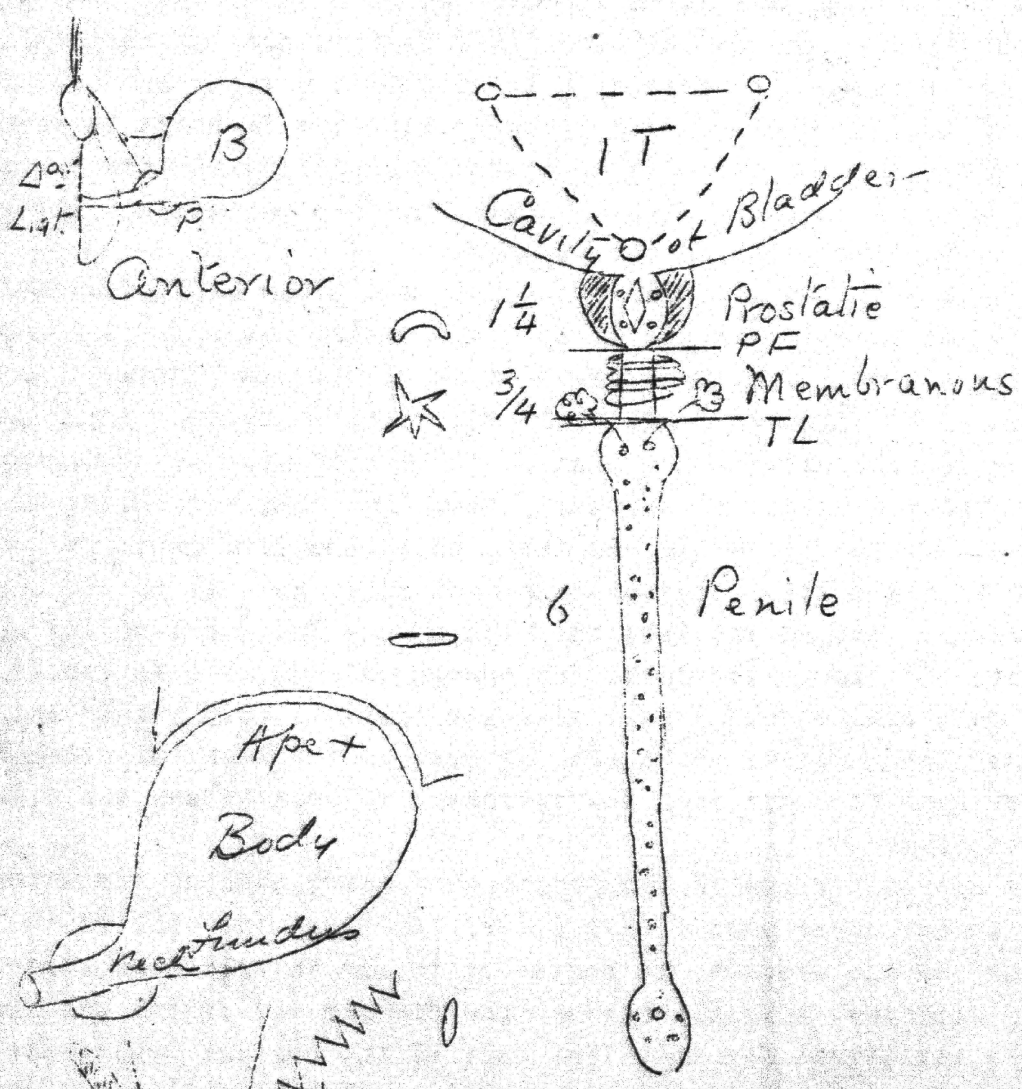
B
Ant.
Lat.
P
Anterior
IT
Cavity of Bladder
1 1/4
Prostatic
PE
3/4
Membranous
TL
6
Penile
Apex
Body
Neck
Lymphatics
VDP
R
Prostate

onus it forms the superior false ligament. In the female the peritoneum passes from the rectum to the posterior wall of the vagina, about an inch below the its attachment to the cervix uteri forming the recto-vagical pouch of Douglas and the posterior ligaments of the uterus, thence over the body of the uterus and from the front of the cervix to the bladder forming the utero-vesical pouch. On each side of the uterus it is stretched out across the pelvis forming the broad ligament of the uterus, which contains in front the round ligament, the ovary and its ligament behind, the fallopian tube above and some vessels and connective tissue and non-striate muscular fibre. The false ligaments of the bladder are the same as in the male and the reflection of the peritoneum from the bladder to the uterus in front has been named the anterior ligament of the uterus.

THE PELVIC FASCIA is the fascia lata of the pelvis, it is continuous above with the fascia lata covering the interior of the abdomen and in the pelvis it fulfils a double purpose, it lines the walls and forms ligaments for its viscera. The entire pelvic fascia is derived from the ilio-psoas fascia which lines the back, front and sides of the pelvis. The pelvic fascia has a visceral and parietal layer. The fascia is studied in three aspects, posterior, here the fascia is very thin, it becomes attached to the brim of the pelvis and going down it divides. The lateral aspect is more difficult because while the fascia splits in the usual way into visceral and parietal layers the visceral layer has a difficult task to perform because it has three or four viscera to which to give ligaments and not only one as it has in the case of the posterior aspect. The visceral layer gives off three distinct parts, one to the bladder, one to the prostate and the seminal vesicles and one to the rectum. The point of splitting of this fascia on this aspect into the visceral and parietal layers is along a line called the white line, which stretches from the body of the pubis to the spine of the ischium and from this line the levator ani takes origin. The parietal layer is often called the obturator fascia. The Anterior aspect is difficult for the reason that now we have no fascia coming from above, the transversalis fascia having stoppedshort. The visceral and parietal layers are both attached to the back of the pubis, the visceral being the higher. The visceral goes to the bladder and prostate, forming the pubo-prostatic ligament, the parietal goes to the triangular ligament of which it is sometimes called the posterior layer. As the pelvic fascia enters the pelvis it becomes attached along a line near the brim, this line behind is near the base of the sacrum, along the posterior half of the ilio-pectineal line, it then dips as it passes toward the pubis, crosses the obturator foramen a little above its middle and is attached to the body of the pubis low down. It is on account of the dipping that the obturator artery does not pierce the pelvic fascia in getting outside of the pelvis. All the arteries of the pelvis are inside the pelvic fascia and must either pierce it or pass over it, all pierce it except the obturator. All the nerves lie outside the pelvic fascia.

DISSECTION FOR THE PELVIC FASCIA (This dissection will only expose the fascia in its lateral aspect). Amputate the leg at the hip, remove all the muscles attached to the outside of the pelvis, make the following saw-cuts, enter the saw at the anterior inferior iliac spine and carry it to the middle of the horizontal ramus of the pubis, saw down into the great sciatic notch behind and to the thyroid foramen in front without opening the acetabulum. Second, make a

saw-cut across the ischium from the thyroid foramen to the lesser sciatic notch, just above the tuber. Snip off the spine of the ischium and remove the large piece of bone within the saw-cuts leaving the spine of the ischium attached to the dissection. Then is exposed the obturator internus muscle which reflect, then is exposed the pelvic fascia. The spine of the ischium is left to mark the position of the white line.

THE BLADDER is the same size in both male and female. The bladder shows an apex, or summit, covered by a cap of peritoneum, a body and a neck, its most sensitive part and on whose floor is the internal trigone. The bladder has 10 ligaments, five are peritoneal or false as already seen, five are tendinous or true, they are the urachus, the pubo-prostatic, formed from the visceral layer of the pelvic fascia and two posterior formed of folds of pelvic fascia. The wall of the bladder has a large amount of muscle in it, the fibres are in three distinct layers but the most important is that which starts from prostate behind passes over the summit and terminates in prostate in front. The mucous membrane of the bladder like that of the pelvis of the kidney and the ureter is formed of transitional epithelium and is when the organ is empty everywhere thrown into folds except at the trigone..

THE URETHRA the male urethra is 8 inches long and is divided into three parts, penile, 5 inches long, membranous, ¾ inch and prostatic 1¼ The penile portion extends from the meatus to the triangular ligament and has two dilated parts, one near the point, the fossa navicularis, and one in front of the triangular ligament, the bulb, it has also two narrow parts one at the meatus, the other at the triangular ligament. A transverse section of this portion of the urethra shows a vertical slit at the meatus and near the point, a transverse slit in the middle and a stellate appearance at the bulb. In this part of the tube a series of little ducts open, the urethral lacunae a very large one is found near the meatus in the roof. These are sometimes called the glands of Littre. The membranous urethra is ¾ of an inch long, it lies between the triangular ligament and the pelvic fascia. Its walls are very thin and it is surrounded by the compressor urethrae muscle. There are no openings in this portion of the urethra. On either side is a Cowper's gland, it is the most fixed portion of the urethra. The prostatic portion is an inch and a quarter in length and extends from the membranous portion to the bladder where its opening has a little fold of mucous membrane called the luette. The urethra here tunnels through the prostate and is fusiform in shape. Along the center of its floor runs a mucous fold, the veru montanum, and about the middle of this there is a little opening or pit, the sinus pocularis. Just inside this sinus are the openings of the seminal ducts, on either side of the veru are the little openings of the prostatic sinuses themselves. The internal trigone is an area on the floor of the bladder near its neck, the angles of this figure exist, its sides are imaginary. The points are the openings of the ureters and the urethra. The mucous mebrane here is smooth and sensitive. The external trigone lying on the outside of the bladder accurately corresponds with the internal, its base is formed by a reflection of peritoneum, its apex is at the prostate, its sides are formed by the vas deferens and common duct. The mucous membrane of this part lies against the rectum. The urethra has upon it two curves, one is posterior and is fixed, the other is anterior and moveable. The prostatic and membranous portions are fixed, the penile alone is moveable.

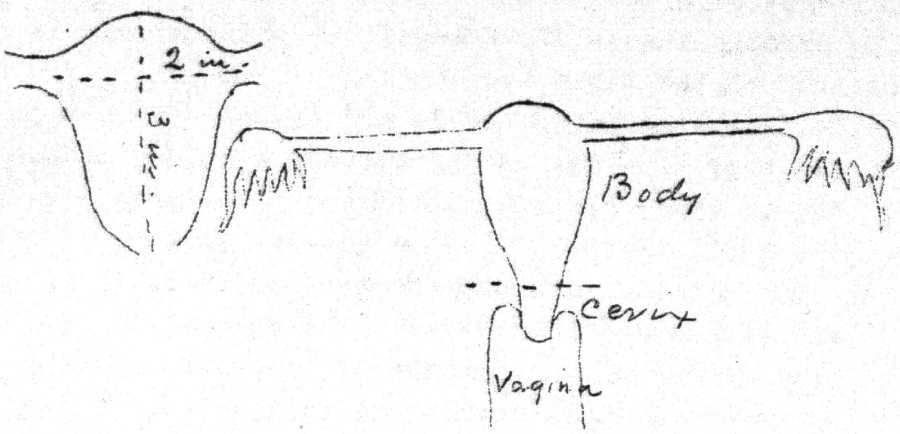
2 in.
Body
Cervix
Vagina

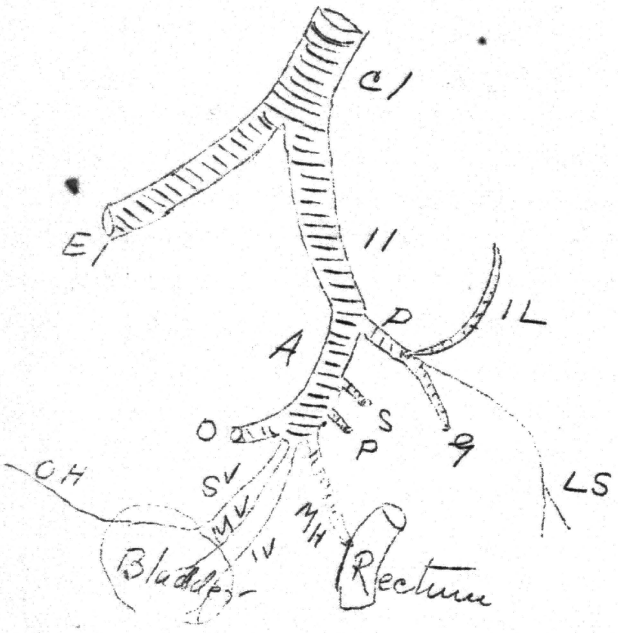
C1
E
II
IL
A
P
O
S
P
Q
LS
OH
SV
MH
IV
Bladder
Rectum

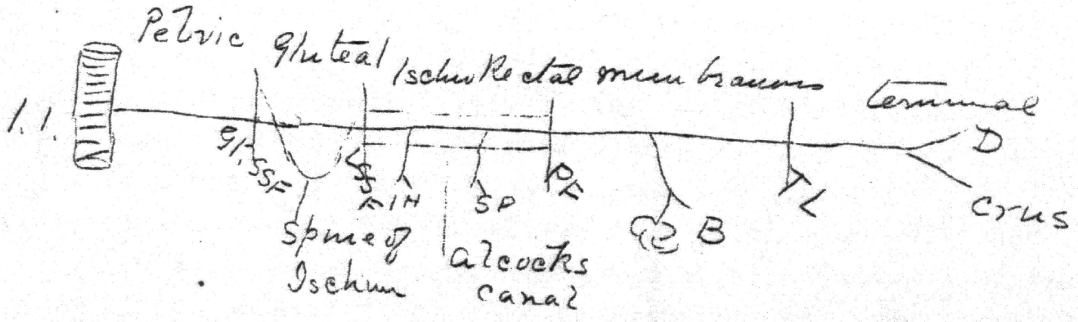
Pelvic
Gluteal
Ischio Rectal membranes
Terminal
I.I.
D
Spine of Ischium
Alcocks canal
B
TL
Crus

THE PROSTATE GLAND surrounds the urethra and is firmly attached to the bladder. It is abou the size of a horse-chestnut, its base is against the bladder and from its apex issues the urethra. The upper surface shows a slight groove and a division into right and left lobes. The lower surface shows the same two lobes but the groove is here a notch behind. In this notch is sometimes seen the rudiment of a third lobe and on either side opens the common ejaculatory duct. The prostate is held in position above and behind by the bladder, below and in front by the parietal layer of the pelvic fascia and theo again by pelvic fascia, the visceral layer by special bands which are called ligaments, e.g. the pubo-prostatic. Antero-posteriorly the prostate measures 1¾ inches, in length it is 1¼, in thickness ¾ The gland is enclosed between two capsules, the outer is derived from the pelvic fascia, the inner is the capsule proper. Both are fibrous and are separated from one another by a plexus of veins. Into this plexus opens below the dorsal vein of t e penis and the plexus opens behind and above into the vesical plexus. There are two distinct elements in the prostate, non-striate muscle and glandular, the latter secretes a clear, mucoid fluid.

VESICULUS SEMINALIS is about the size of a little finger and lies on the posterior aspect of the bladder. It ends below in a small duct which joins with the vas deferens and forms with it the common ejaculatory duct. The vesiculus is about 2 inches long but when dissected out becomes four inches long and is a long tube with diverticula upon it. This tube in the natural state is somewhat coilde and possesses a large amount of muole in its walls. The testicle is constantly forming spermatozoa and these work their way along the epididymis and vas deferens toward the vesiculus, a large majority dying by the way. They reach the neck of the seminal vesicle, rwim in and rest there.

THE FEMALE URETHRA is a simple tube about an inch and a half long, runs downward and slightly forward in front of the vagina, pierces the triangular ligaments and deep transversus perinei muscle to open into the vestibule. The mucous and muscular coats are like those in the male io the membranous portion, the upper part of the tube has a good deal of non-striate muscle which acts as a sphincter

THE VAGINA is composed of longitudinal muscular fibres enclosing erectile tissue and lined by a mucous membrane which is seen on being laid open to form a series of transverse rugae starting from longitudinal ridges on the anterior and posterior walls. Its anterior wall is about 3½ inches long, the posterior 4½. The lower end of the uterus projects into its upper part the point of reflection of the wall being much higher behind than in front. At its lower end are the caruncular myrtiformes or the hymen, and just below this the aperture of the duct of Bartholin's gland.

THE UTERUS is more or less pyriform in shape, it opens below into the vagina. The direction of the long axis of the uterus probably varies a good deal owing to the condition of the bladder and the intestine. Under ordinary circumstances it never rises aboue the plan eof the pelvic inlet. It is about three inches long, its maximum transverse diameter is about 2 inches, its antero-posterior about one inch. Its anterior surface is flattened and covered by peritoneum as far as the junction of the body and cervix, its posterior is convex, is invested by peritoneumas far as the attachment to th vagina. Its narrow lateral margins give attachment to the to the broad and sacro-uterine ligaments and

and from its sup. angles run the oviducts, the ligaments of the ovary and round ligaments. The relative lengths of the cervix and body vary at different periods of life, in the child the cervix is longer, in the virgin they are about equal after parturiton the body is nearly twice as long. The cavity is triangular with the apex down at the os internum, the extremities of the base correspond to the orifces of the fallopian tubes. It is lined by smooth mucous membrane, ciliated. The cavity of the cervix is fusiform it opens into the cavity of the body by the os internum, into the vagina by the os externum.
The utero-sacral ligaments are two flat bands of non-striate muscular tissue which run from the body of the uterus, sides of the body, backward to the front of the sacrum, near the sacro-iliac joint, on either side of the rectum. The uterine artery, a branch of the internal iliac, enters the root of the broad ligament to reach the organ at the level of the cervix, crosses in front of the ureter, runs up along the side of the uterus gives branches to both walls and the vagina at the upper part. Uterine veins form a plexus with the ovarian and terminate in the internal iliac. The nerves are derived from the hypogastric plexus, the spermatic plexus and the 3rd. and 4th. sacral nerves.
THE FALLOPIAN TUBES ar . in the upper part of the broad ligament, one on each side of the uterus, to the angles of which they are attached. Each tube is about 4 inches in length of very small calibre at the uterus but gradually expands to form a large, trumpet shaped mouth furnished with a number of fimbriae which radiate from the external opening of the canal. One of the fimbriae is is attached to the ovary. The tube is muscular in structure and is lined by a longitucinally plicated mucous mebrane with ciliated epithelium. Its external orifice opens into the peritoneal cavity. The round ligament is placed in the anterior part of the broad ligament, is composed of non-striate muscular tissue is covered with peritoneum. It extends from the angle of the uterus through the inguinal canal to become lost in the fat of the labium.
THE OVARY, an almond shaped body projecting from the posterior part of the broad ligament attached to the superior angle of the uterus by a muscular band the utero-ovarian ligament and by its opposite extremity by the long fimria to the ovary- fallopian tube. It rests in a shallow peritoneal sulcus at the side of the true pelvisbetween the internal iliac artery and vein a little below a point midway between the anterior superior spine and the median line. It is composed of a fibro-muscular stroma condensed peripherally into a cortex which is covered by epithelium and presents numerous ovisacs or Graafian follicles.
THE BROAD LIGAMENTS are duplications of peritoneum extending from the lateral borders of the uterus to the sides of the true pelvis. Between the two laminae are the following, At the superior border the oviduct, projecting from the posterior surface the ovary, projecting from the anterior surface the round ligament, the organ of Rosenmuller(relics of the Wolffian body) bands of non-striate muscular tissue, connective tissue continuous with the subperitoneal tissue, the uterine, ovarian and funicular arteries all meeting in the upper angle of the uterus and the uterine and ovarian nerves.
The INTERNAL ILIAC ARTERY extends from the upper part of the sacro-iliac joint to the upper part of the great sciatic notch where it divides into the anterior and posterior divisions Anteriorly we have it is crossed by the ureter near its origin, peritoneum, small intestine. Posteriorly, the internal iliac vein,

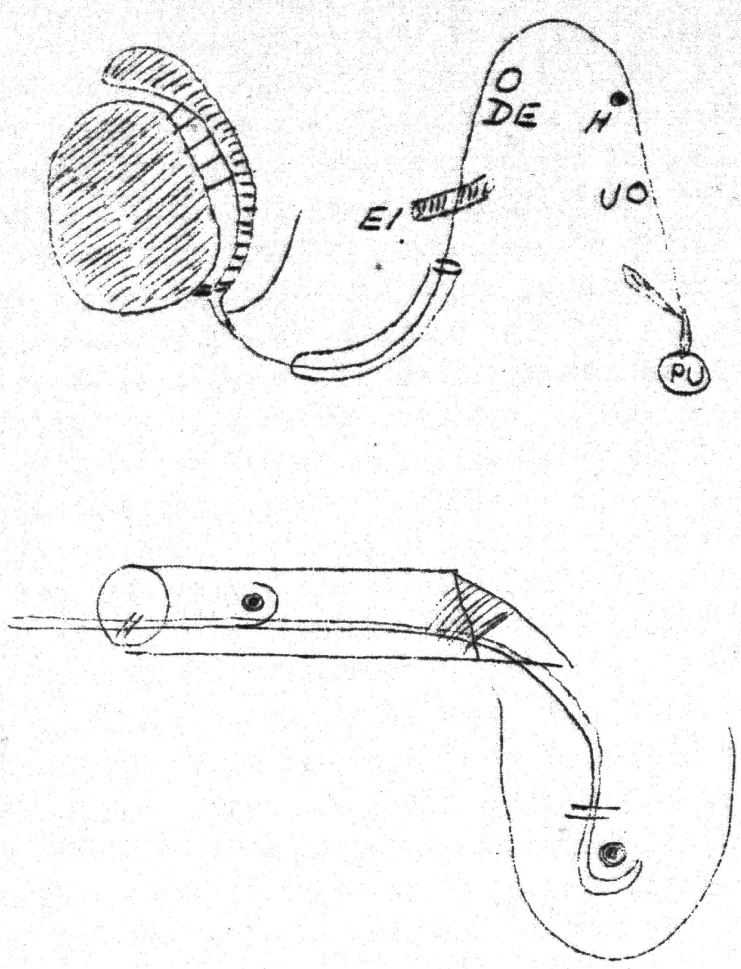
O
DE
H
UO
PU

the sacrum with the pyriformis and the lumbo sacral cord. From the anterior division of the artery are given off three visceral and three parietal branches. It is the larger division. Parietal branches are Pudic, Sciatic and Obturator. The pudic and sciatic are seen only for a short distance in the pelvis as they soon leave it by passing through the great sacro-sciatic notch. The PUDIC ARTERY lies in five regions, the pelvis, the gluteal region, the ischio-rectal fossa, urethral, and terminal. Passing through the great sacro-sciatic foramen below the pyriformis it usually lies a little in front of the sciatic it crosses the spine of the ischium and re-enters the pelvis by passing through the lesser sciatic foramen, it runs along the outer side of the ischio-rectal fossa lying in a little canal, Alcock's, it then pierces the pelvic fascia, runs along the membranous urethra, pierces the triangular ligament and divides into the dorsal artery of the penis and the artery to the crus. The first and second parts have no branches, the third gives off the inferior hemorrhoidal and the superficial perineal, the 4th. gives off the artery to the bulb, which in turn gives off a branch to Cowper's gland.. The Sciatic is distributed outside the and has been seen in the buttock.

OBTURATOR ARTERY, passes outside the pelvis through the upper part of the thyroid foramen. In so doing it does not pierce the pelvic fascia but passes over its free border. Immediately after reaching the outside of the pelvis it divides into two branches which form an arterial ring round the outside of the foramen. The visceral branches of the are the superior vesical, inferior vesical and middle hemmorhoidal, also in the female the uterine, vaginal and ovarian are given off. The superior vesical is in the foetus enormour, (the hypogastric) and it is by this artery that the blood is returned to the placenta. After birth the portion extending from the umbilicus to the bladder shrivels up and from the pervious portion remaining are given off two named branches, the middle vesical and the artery to the vas.. The anterior dive

The posterior division of the artery is the smaller and it gives off 1 branches

ILIO LUMBAR ARTERY, runs toward the transverse process of the 5th. lumbar,

LATERAL SACRAL, runs down the side of the sacrum and joins with other arteries notably the sacra media. The gluteal artery has been seen in the buttock.

THE TESTICLE hangs in the scrotum with its upper end forward and outward, it is a flattened, oval body. Measurements, 1½ long, 1 inch broad, ¾ thick and its weight is under one ounce. It is enclosed in a fibrous capsule, the tunica albuginea which is very dense. Inside this tunic the vessels form a tunica vasculosa. At the back of the testicle is a large amount of fibrous tissue, the mediastinum testis from which partitions run forward throughout the gland forming loculi and in these loculi lie the seminal tubules. A seminal tubule begins in a loop or knob and is about two feet long. It opens posteriorly into a network the rete testis, which lies in the substance of the mediastinum testis. From the upper part of the rete a number of small ducts arise, the vasa efferentia, and these pass to the globus major of the ~~epicymie~~ epididymis. The epididymis lies at the back and top of the testicle, its upper part is called the globus globus major, the lower the globus minor, intermediate we have the body of the epididymis. The globus major is connected by vasa efferentia to the testicle, the globus minor by fibrous tissue. The body is not attached to the testicle. It is really an enormously contorted tube which if teased out would be about

20 feet long. From the globus major there often grows out a small stalked body the hydatid of Morgagni, it is a mere cyst and is developed from one of the coils of the epididymis. From the beginning of the vas deferens there runs upward a blind tube about 1½ inch long, the vas aberans. The vas deferens is two feet long and extends from the globus minor to near the prostate where, joining with the duct of the seminal vesicle it forms the common ejaculatory duct. In the lower part of its course the vas deferens forms a constituent of the spermatic cord and is found along its posterior aspect as a hard cord. Having entered the abdomen it crosses the external iliac artery, hooks around the deep epigastric artery and runs inward and backward and reaches the obliterated hypogastric around which it turns. It then runs downward and forward toward the prostate having the ureter on its outer side. A seminal tubule is lined by epithelial cells in more than one row, the inner cells become much swollen and in the interior of these spermatozoa are formed. These daughter cells eventually burst and the spermatozoa are set free. They take the following course, Two feet in the seminal tubes, two feet in the rete, twenty feet in the pepidymis, two feet in the vas deferens. The testicle in the foetus is an abdominal organ, and at the time of birth descends through the inguinal canal into the scrotum. In passing down it must carry with it the fascine covering the muscles of the anterior abdominal wall. First it carries with it Peritoneum, (parietal), Fascia transversalis, cremasteric fascia which covers the internal oblique muscle and then, as it issues from the external abdominal ring, it receives an investment from the intercolumnar fascia. Thus it reaches the scrotum. The peritoneum which has passed down through the inguinal canal into the scrotum becomes closed at two points, at the testicle itself and at the internal abdominal ring. The process lying in the canal shrivels up and forms the funicular process. That portion of the peritoneum which becomes stut off at the testicle forms the tunica vaginalis and persists during life. The tunica vaginalis is a true serous membrane and is composed of a visceral and a parietal layer.

END OF ABDOMEN.

THE HEAD AND NECK.

THE SCALP consists of the following layers, Skin, which is thick and vascular, bears hairs and is intimately attached to the tendon of the occipito frontalis by the next layer, one of fine connective tissue. In the true skin are found sebaceous follicles and the little arrectores pilorum muscles, the hair-bulbs and sudoriparous glands lying in the upper part of the layer, the temporal and other ves els in the lower. After the connective tissue layer comes in xorder of depth the tendon of the occipito frontaliswhich covers the vertex is prolonged laterally ov erx the temporal fascia. Anteriorly and posteriorly the tendon is replaced by the muscular fibres of the muscle.

OCCIPITO FRONTALIS.; Origin, mastoid process and superior curved line of the occipital bone, Insertion, central tendon, Second Origin, has no true bony attachment, but blends with the pyramidalis nasi (by many considered as part of the muscle), the rest of the muscle is attached to the tissues of the eyebrow, there is no free margin, it merges into all the tissues in the region. Insertion, central tendon or galea. Nerve, facial.

THE SCALP, the 4th. layer of the scalp is the loose connective tissue lying under the occipito frontalis and permitting its free movement, while the 5th. layer is formed by the periosteum of the cranium.

CUTANEOUS VESSELS AND NERVES OF THE SCALP in front of the ear are branches of the 3 divisions of the 5th. nerve and branches of the facial, with twigs from the ophthalmic and temporal vessels. Behind the ear are posterior auricular branch of the facial nerve, auricular branch of the vagus, great and small occipital and the great auricular. The sensory branches of the 5th. give branches to the muscles with which they are in contact, uniting with the motor filaments from the facial nerve. Supra-orbital nerve is found in relation with the supra-orbital notch, it divides into two branches in the orbit, the larger passes through the supra orbital notch or foramen, the smaller through a shallow groove to its inner side. Supra trochlear nerve, (both these come from the 1st. division of the 5th. nerve) is a small branch leaving orbit at its inner angle. Supra-orbital artery, from the ophthalmic, goes with the nerve, the frontal artery, ophthalmic, is of small size goes with supra-trochlear. The supra-orbital and frontal veins unite to form the angular which is the commencement of the facial and communicate freely with the ophthalmic. The temporal branch of the temporo malar is small, (2nd. division of 5th.) while the auriculo-temporal nerve (3rd. of 5th.) lies immediately in front of the ear close to the artery. It goes with the temporal artery and distributes branches to the pinna above the meatus and to the meatus and is lost in the skin of the temporal region. Temporal branches of the facial nerve run obliquely over the zygoma to the temple and join with the branches of the 5th. in that region and supply the muscles. The temporal artery will be described in connection with the external carotic, it is found in front of the ear and gives offsome facial branches, an orbital and then divides into anterior and posterior branches. The anterior lies on the temporal fascia and is subcutaneous, the posterior turns back above the ear and anastomoses with the occipital. The temporal vein is formed by branches corresponding to those of the artery, enters the parotid gland to join the internal maxillary and form the temporo maxillary trunk. The veins do not accompany the arteries in the scalp, both run in the deep portion of the true skin, but the arteries retract in their fibrous canals when cut, the veins are more firm-

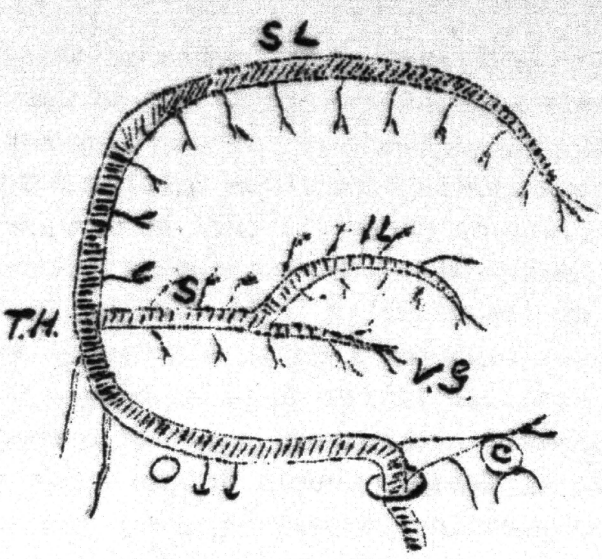

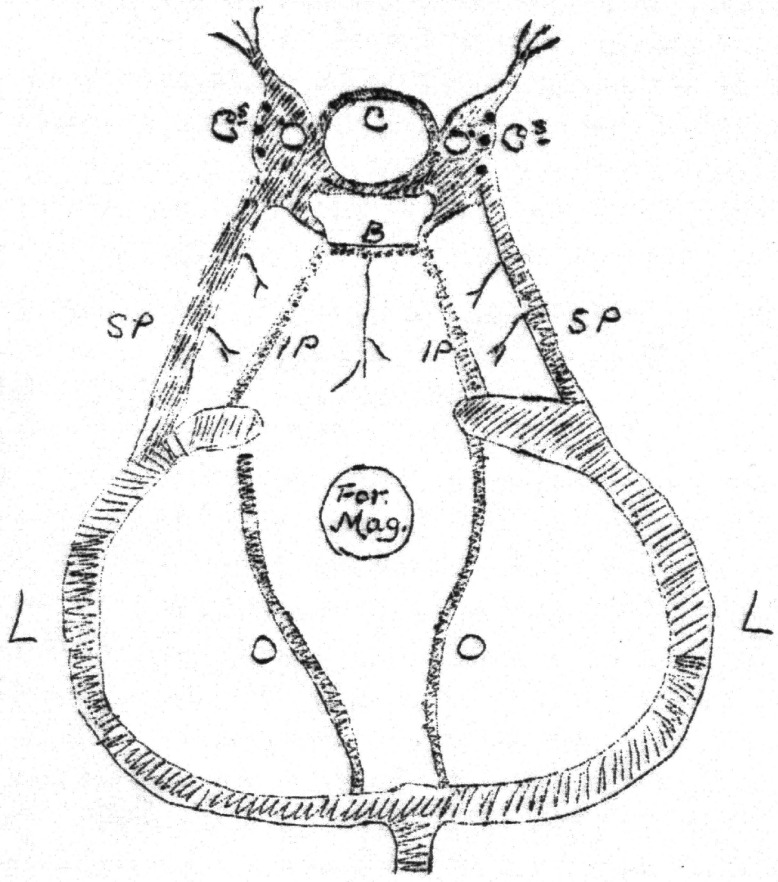

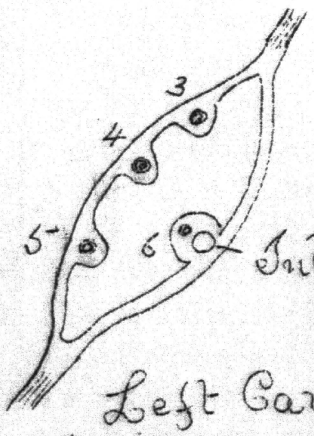

Left Cavernous Sinus.

(5th Nerve here is too low)

ly attached to their walls of surrounding connective tissue and tend to gape. Posterior auricular nerve(facial) runs over the mastoid process behind the ear with an accompaying artery, the arterybeing from the external carotid and by its auricular branch is distributed to the pinna, by its mastoid branch to the skin behind it.. The great auricular nerve (2nd. and 3rd. cervical) goes to the pinna, supplies a mastoid branch to the skin. Small occipital nerve, same orgin, passes directly upward to supply the scalp. Great occipital, (posterior division of 2nd. cervical) is a large nerve and pierces the trapezius near the occipital protuberance. Its branches lie over the posterior part of the occipito frontalis, distributed to the scalp, and it communicates with the small occipital and its fellow. The third, or smallest occipital nerve is an occasional posterior division of the 3rd., distributed to the occipital region internally to the great occipital. The occipital artery, from the external carotid, lies close to the great occipital nerve, but its relations are inconstant. It ramifies on the back of the scalp, anastomoses with its fellow and with the posterior auricular and the temporal of the same side.

THE TEMPORAL fascia, is attached above to the superior temporal ridge on the frontal, parietal and temporal bones, splits below to be inserted on both lips of the upper border of the zygoma, encloses some fat, a small orbital branch temporal artery and the temporal branch of the orbital nerve from the superior maxillary..

THE TEMPORAL MUSCLE Origin, frontal, sphenoid and parietal bones between the superior temporal ridge and the pterygoid ridge of the sphenoid and the under surface of the temporal fascia. Insertion (seen later) tip and inner aspect of the coronoid process of the jaw.

THE DURA MATER AND SINUSES The dura is a strong fibrous membrane lined internally with endothelium, firmly attached to the base of the skull especially at the sutures and foramina, it sends processes through the foramina forming sheaths for the nerves, splits to form sinuses and to enclose the gasserian ganglion and the pituitary body. It forms the three great partitions in the brain, the falx cerebri, falx cerebelli and the tentorium cerebelli, is continuous below with the dura of the cord and forms the internal periosteum of the skull. The falx cerebri is a sickle shaped double fold of dura mater placed between the two hemispheres of the brain, in its upper edge is the superior longitudinal sinus, inferiorly the inferior. It is attached in front to the crista galli and behend to the internal occipital protuberance. The tentorium cerebelli is a process of dura which lies horizontally between the cerebrum and the cerebellum. When perfect its margins form an oval opening through which pass the crura cerebri with the corpora quadrigemina, the superior peaunoles of the cerebellum and the posterior cerebral arteries. In front it is attached to the anterior and posterior clinoid processes, the petrous portion of the temporal, there splitting to form the petrosal sinuses.(superior) behind to the margins of the groove for the lateral sinus on the occipital, parietal and temporal bones. The falx cerebelli lies below the tentorium in the middle line, is attached to the median ridge of the occipital bone nearly as far as the foramen magnum. The inferior longitudinal sinus runs along the lower border of the falx cerebri, is much smaller than the superior, is more like a true vein, opens into the straight sinus. The straight sinus is form-

ed by the union of the venae Galeni with the inferior longitudinal, receives the superior cerebellar veins, opens into torcula Herophili, thus connects the two longitudinals. Occipital sinus, formed by the splitting of the falx cerebelli, communicates above with the torcula Herophili bifurcates below to joint the posterior spinal veins. The torcula Herophili is the meeting place of the superior longitudinal, straight, occipital and the two lateral sinuses. It is in the neighborhood of the internal occipital protuberance. The lateral sinuses, the largest, commence at the torcula, take a curved course to the jugular formmen. Grooves the occipital parietal, temporal and again the occipital bones (OPTO) Receives the superior petrosal and a number of veins in the region. Passes through the jugular foramen, is joined by the inferior petrosal sinus and forms the internal jugular vein, the interval between the two sinuses at the foramen lacerum posterius being occupied by the 9th., 10th. and 11th. nerves The lateral sinus which receives the superior longitudinal is usually the larger of the two. Superior petrosal sinus, lies along the upper border of the petrous bone, is small, runs from the cavernous back to the lateral, entering it just where it turns downward on the temporal bone. Inferior petrosal runs forward from the jugular foramen along the lower border of the petrous bone to the posterior clinoid process. Communicates with the cavernous, behind with the internal jugular vein, is brought into communication with its fellow by the transverse, or basilar, sinus which runs across the basilar process of the occipital. The cavernous sinus, is placed by the side of the pituitary bodyand lies in close relation to the 3rd. 4th., ophthalmic division of the 5th., 6th. nerves The 3rd. is close behind the anterior clinoid process, the 4th. at the point of decussation of the free and attached borders of the tentorium, 5th. immediately below the tentorium, 6th. pierces the dura nearer the median line, half an inch behind the posterior clinoid. Sinus receives the circular, superior petrosal, spheno-parietal sinuses, the ophthalmic vein etc. The circular sinus surrounds the pituitary body, connects the two cavernous sinuses, Spheno-parietal sinus is a small vessel running in the fold of dura over the posterior border of the lesser wing of the sphenoid. It receives some diploic veins and ends in the cavernous sinus.

THE GASSERIAN GANGLION, the largest of the cranial ganglia, isof pinkish colour, lies in a shallow fossa on the tip of the superior surface of the petrous portion of the temporal enclosed in a sort of pouch of dura, the space of Meckel. it is formed upon the sensory root of the 5th., the motor portion passes under it. From the ganglion three great divesions of the 5th. are given off, the 1st. or ophthalmic passes to the sphenoidal fissure, the 2nd. goes to the foramen rotundum while the 3rd. passes through the foramen ovale. The motor trunk of the nerve joins this last after its emergence from the foramen. The ophthalmic division passes along the outer side of the cavernous sinus In the cavernous sinus the nerves lie at first 3, 4, 5, ., but before they the sphenoidal position is changed and they lie 4,5,3,6, io each case from above downward. The 3rd. will be seen before entering the orbit to divide into two, between which the nasal branch of the 5th. passes.

THE INTERNAL CAROTID ARTERY lies here close to the side of the sella turcica after emerging from the carotid canal. It has been cut in removing the brain.

SYMPATHETIC NERVES IN THE REGION, a network of filaments exists on the arotid artery forming the carotic plexus, it receives a communication from the super-

ior cervical ganglion and gives branches of communication to the 6th. nerve, the Gasserian ganglion, Meckel's ganglion (by the deep petrosal) and Jacobson's nerve. The cavernous plexus is on the inner side of the artery, close to the anterior clinoid process, from it pass twigs of communication to the 3rd., 4th., 5th. and 6th. and the lenticular ganglion.

THE PETROSAL NERVES lie in relation with the upper surface of the petrous bone, the greater, small and external, the great passes through the hiatus Falopii to join the facial, (seen later in relation with Meckel's ganglion) the small, entaring the temporal bone on the outer side of the Hiatus Fallopii the communication between the facial and the otic ganglion and the external also passing to the facial from the plexus on the middle meningeal artery.

MENINGEAL ARTERIES the anterior enter the cranium through the ethmoidal foramina. The middle enters at the foramen spinosum, it ramifies on the outside of the dura and divides into an anterior and a posterior branch, the latter crossing the squamous portion of the temporal and grooving the parietal from its anterior inferior angleupward and backward. It the anterior branch with th posterior supply nearly the whole of the dura and cranial bones and gives small twigs to the facial and 5th. nerves, the orbit and the temporal fossa. It is accompanied by venae comites and a plexus of sympathetic filaments. The plexus gives filaments to the otic ganglion. The small meningeal artery is a branch of the internal maxillary or the middle meningeal and enters the skull through the foramen ovale. The meningeal branch of the ascending pharyngeal enters through the foramen lacerum medium, the posterior are small branches of the occipital and vertebral which enter by the jugular foramen and the foramen magnum. The nerves of the dura are derived from the 4th., 5th., 1mth. and carotid plexus of the sympathetic.

THE ORBIT is a 4 sided bony pyramid, the base of which is facial while the apex passes backward and inward and ends at the optic foramen and the foramen lacerum anterius. The ROOF is formed by the following bones, orbital plate of frontal, and the lesser wing of the sphenoid posteriorly. Floor, orbital surface of superior maxilla, orbital surface of malar and orbital process of palate. Outer wall, orbital surface of malar, great wing of sphenoid and extrernal angular process of frontal. Inner wall, frontal, nasal process of superior maxilla, external surface of lachrymal, os planum of ethmoid, body of sphenoid. It will be noticed that 7 bones enter into the formation of the orbit, superior maxilla, malar, palate, sphenoid, frontal, ethmoid and lachrymal. Two points exist on the bony roof, the lachrymal fossa for the gland toward the outer angle and the supra-orbital notch, sometimes a foramen, in the supra orbital ridge. The floor shows the infra-orbital groove and the canal for the nerve and vessels. The outer wall shows a foramen for the temporo-malar nerve and the Inner wall shows three foramina, the nasal duct, the anterior and posterior ethmoidal. Between the floor and the outer wall in the posterior three-fourths of the space is a great fissure called the spheno-maxillary fissure, this is wider in front than posteriorly and is bridged over by the orbitalis muscle, a mass of non-striate musce mingled with some fat which lies outside the periosteum of the orbit(The muscle of Muller) This fissure leads into two fossae, the zygomatic and the spheno-maxillary and it transmits the superior maxillary nerve, the orbital branch of Meckel, sympathetic filaments, the temporo-malar nerve and the infra-orbital vessels. The periosteum

lining the orbit is a dense fibrous membrane which is continuous pehind with the the dura mater through the foramen at its apex. On being traced forward this periosteum divides into two, one of which passes to become the periosteum of the skull, the other passes to the eyelid of which it becomes the tarsal ligament. On cutting away the roof of the orbit the first thing exposed is the periosteum and on splitting that and reflecting it a mass of soft fat is exposedwhen three nerves and two arteries can be brought to sight by removing the fat piecemeal. The nerves are the the frontal of the 5th. with the supra-orbital artery in the center of the space, thr lachrymal nerve and artery to the outer side and the small fourth nerve to the inner side. At the upper and front part is seen the lachrymal gland. The fourth nerve having passed through the cavernous sinus where it occupied the second highest position, passed through the sphenoidal fissure lying highest, now lies to the inner side of the orbit and supplies the the superior oblique on its orbital surface. The frintal nerve, the largest of all in the orbit, appears to bisect the orbit, it divides at the back part of the orbit into supra-orbital and supra-trochlear branches, the supra-orbital passes through the supra-orbital notch and is distribsted as far far back as the vertex of the skull, the supra-trochlear leaves the orbit by way of a shallow groove nearer the middle line. The lachrymal branch runs superficially along the outer aspect of the orbit and supplies the lachrymal gland and the skin near it, it sends a communicatioh to the temporo-malar nerve (or the orbital branch of the superior maxillary) The supra-orbital artery is a branch of the ophthalmic and accompanies the supra-orbital nerve. The two veins, supra-orbital and supra-trochlear form the commencement of the facial. The lachrymal is a smaller branch of the ophthalmic. The lachrymal gland is about the size and shape of an almond, is situated on the outer and anterior part of the orbit. It fits into the little fossa on the bone, has 7 or 8 ducts and exists to lubricate the surface of the eye. The muscles seen on this, the superior aspect are the Obliquus superior, Origin, roof of the orbit near the optic foramen. The muscle works at a right angle through a little fibrous pulley situated at the trochlear surface on the front part of the orbital surface of the frontal bone, it then turns downward, backward and outward to be Inserted after expanding into the sclerotic on the outer side of the posterior half of the eyeball, betweenthe superior and ex ernal recti. Nerve, 4th. on its orbital surface. The Levator palpebrae superioris, Origin, close to the last muscle it expands anteriorly and is Inserted into the upper border of the tarsal cartilage. Nerve, 3rd. Superior rectus, Origin, margin of the optic foramen, Insertion, sclerotic a little behind the corneo-sclerotic junction. Nerve, 3rd. The nasal nerve enters the orbit through the two heads of the external rectus, passes through the anterior ethmoidal foramen and re-enters the skull. Runs into the nose through the slit beside the crista galli and appears on the face between the nasal bone and the superior lateral nasal cartilage. and divides into two sets of branches which supply the skin of the eyelids and side of the nose the other the mucous membrane. It gives off in the orbit the ganglionic branch to the lenticular ganglion, two long ciliary nerves which run with the short ciliary nerves and perforate the sclerotic near the entrance of the optic nerve and the infra-trochlear which escapes from the orbit beneath the pulley of the superior oblique. The lenticular ganglion lies in the back part of the orbit between the optic nerve and the external rectus. its sensory

root is derived from the nasal branch of the 5th., its motor root from the braoch of the 3rd. which goes to the inferior oblique, the sympathetic root from the cavernous plexus. The short ciliary branches of the ganglion are 8 or 10 in number and run with the long ciliary branches to supply the iris, the ciliary muscle and the cornea. The ophthalmic arteryarises from the internal aretid olose to the anterior clinoid process, enters through ~~sphenoidal~~ optic foramen to the outer side of the nerve. It gives off lachrymal, supra-orbital muscular, retinal, ciliary, ethmoidal, palperal and frontal branches. (Mnemonic, "Lazy students must remember college examiners pass no fools). (Note, nasal branches have been omitted above) The supraorbital is the largest branch and accompanies the nerve of the same name. The ophthalmic veinskcorrespond with the arteries but form two trunksa superior and inferior which end in the cavernous sinus. The optic nerve, enters by the optic foramen and passes by piercing the sclerotic, choroid and retinal coats of the eye about a tenth of an inch to the inner side of the center of the retina and ends in the retina. It has a sheath derived fhom the meninges of the brain.. The inferior, internal and external recti arise by a common tendonous origin from the ligament of Zinn, a fibrous ring attached in the neighborhood of the optic foramen and the sphenoidal fissure. The external rectus has a second origin from the alisphenoid and between its two heads the 3rd. , nasal, 6th. nerves and the ophthalmic vein all pass.The Insertions of these muscles is into the sclerotic coat near the corneo-sclerotic junction. The inferior oblique has its Origin on the floor of the orbit near the lachrymal canal. These muscles are all supplied, (all the muscles of the eyeball) by the 3rd. nerve, or motor oculi, except the superior oblique, 4th., external rectus, 6th., and the orbitalis (muscle of Muller) sympa hetic. The 6th. nerve, abducens, is seen on the inner surface of the external rectus which it supplies. Note, all the muscles of the eye ball are supplied on their ocular surface except the superior oblique which is supplied by the 4th. on its orbital surface. The third nerve enters the orbit in two parts, one above the other below the nasal nerve. It receives branches from the cavernous plexus and the nasal nerve. The upper division supplies the superior rectus and the levator palpebrae, the lower supplies the other muscles. Outside the periosteum of the orbit lie the infra-orbital nerve, the temporomalar and the orbital branches of Meckel, while the infraorbital artery also lies beneath the periosteum. The lymphatics of the orbit for the most part consist of vessels and one peculiar lymph space called the capsule of Tenon. This surrounds the middle zone of the eyeball and ii no doubt placed there in order to diminish friction, all the muscles of the eyeball pierce the space. All the structures in the orbit are embedded in the mass of fat which fills the cavities of the space.

THE SIDE OF THE NECK is a region wtich is crossed by the sterno-mastoid musmuscle, it is boonded in front by the middle line of the neck, posteriorly by the anterior border of the trapezius, hence is somewhat square-shaped. The sterno-mastoid crossing it divides it into an anterior and posterior triangle. Beneath the skin in this region lies the superficial fascia between the layers of which is found the platysma myoides musole, the superficial vessels and nerves lie between the platysma and the deep fascia.

THE POSTERIOR TRIANGLE OF THE NECK, boondaries, Anteriorly, the sterno-mastoid, Posteriorly, Trapezius, Inferiorly the clavicle and the apex of the triangle is

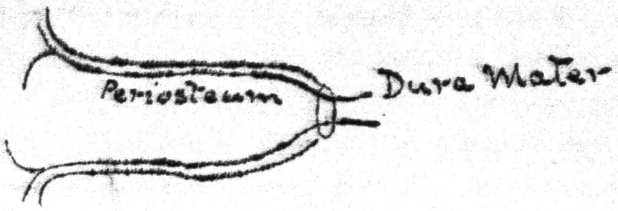

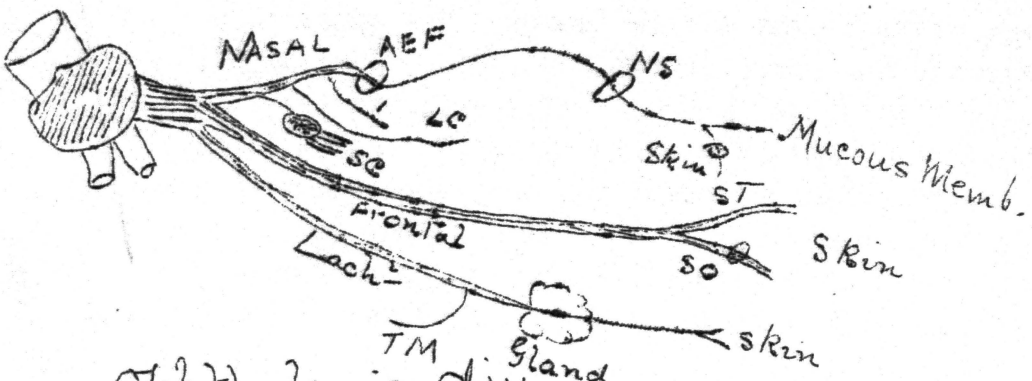

Ophthalmic div. of V Nerve

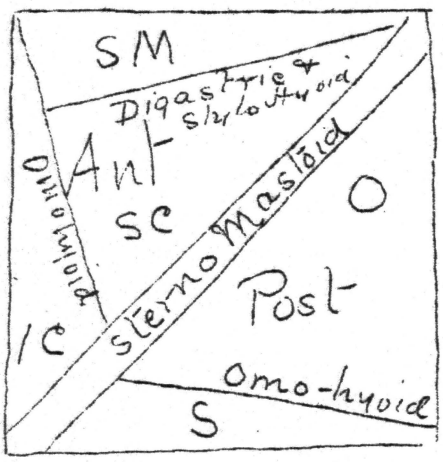

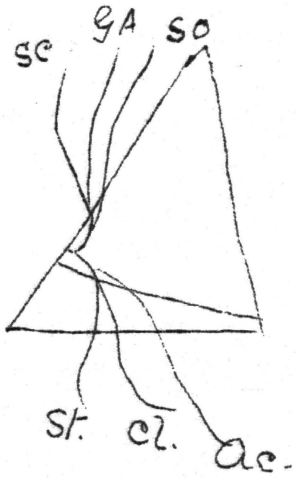

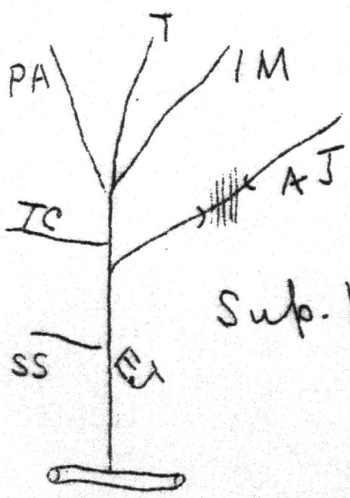

Sulp. Veins

at the skull. The triangle is subdivided into two by the passage across it of the posterior belly of the omo-hyoid. Thus are formed the occipital triangle and the supra-clavicular triangle.The roof of the triangle is formed by the skin, superficial fascia with the platysma and the deep fascia, while the floor is formed by, from above down, the splenius capitis, levator anguli scapulae scalenus medius, scalenus postious and the upper digitation of the serratus magnus.

THE PLATYSMA, is a subcutaneous muscle arising from the fascia over the pectoral and deltoid muscles and very slightly from the front of the clavicle. , Insertion, lower border of the mandible and lower lip, fibres interlacing below the symphysis. Nerve, facial. Under the platysma lies the external jugular vein. SUPERFICIAL VEINS OF NECKCommencing in the substance of the parotid gland by the junction of the temporal, internal maxillary and posterior auricular veins is the external jugular which passes down lying on the sterno-mastoid, it pierces the deep fascia in the posterior triangle and opens into the first part of the subclavian vein. Branches, the anterior jugular, commences underneath the skin, passes down and pierces the deep fascia in order to pass behind the sterno-mastoid, again pierces the deep fascia to become superficial to it, ends by opening into the external jugular, the transversalis colli vein, the suprascapular and sometimes the posterior jugular.

SUPERFICIAL BRANCHES OF THE CERVICAL PLEXUS, are arranged in two setsthree ascending, the small occipital, the great auricular and the superficial cervical. three descendingl, sternal, clavicular and acromial. All supply skin in the regions indicated by their names.

THE OCCIPITAL TRIANGLE cont.ins these last mentioned six nerves, the spinal accessory nerve, muscular branches of the cervical plexus to the levator anguli scapulae, scalenus medius and trapezius, communicating branches to the spinal accessory, the occipital artery, the transverse cervical vessels, the upper part of the brachial plexus and some lymphatic glands which lie in close relation to the the posterior border of the sterno-mastoid. . The Spinal accessory nerve is seen crossing this trianglerunning along the outer surface of the levator anguli scapulae into the trapezius where it communicates with the 3rd. and 4th. cervicals. The nerve has at this time pierced the sterno-mastoid

TRANSVERSALIS COLLI ARTERY passes transversely across the space, divides under cover of the trapezius into an ascending cervical branch and a posterior scapular.. THE ASCENDING CERVICAL passes upward lying on the complexus and anastomoses with the superficial branch of the princeps cervicis from the occipital, while the posterior scapular passes downward under the trapezius and having arrived at the vertebral border of the scapula between the rhomboius and the serratus magnus, anastomosing with various arteries around the scapula. The tendon of the omo-hyoid crosses the triangle at a variable height from the clavicle, being bound to the clavicle and the first rib by a process of deep fascia so that either belly of the muscle may act from this fixed point

THE SUPRASCAPULAR ARTERY AND VEIN lies close behind the clavicle, the artery is usually a branch of the thyroid axis, but may arise from the 2nd. or 3rd. part of the subclavian, it rus in front of the subclavian artery, passes behind the clavicle to reach the upper border of the scapula. The

THIRD PART OF THE SUBCLVIAN ARTERY extends from the outer border of the anter-

ior scalenus obliquely downward and outward behind the clavicle to the outer border of the 1st. rib where it becomes the axillary. Relations of the 3rd. part of the artery, Anteriorly, the 5 structures, the clavicle, the subclavius and the supra-scapular vessels, it is crossed by the nerve to the subclavius and the external jugular vein. Behind are the scalenus medius and the pleura. Above, are the cords of the brachial plexus and below is the subclavian vein in an anterior plane and some distance below. This portion usually gives off no branch, should there be one it will be the posterior scapular or the supra-scapular.

THE BRACHIAL PLEXUS HAS BEEN ALREADY DESCRIBED, (page 3) but in this triangle is seen the formation of the cords. The nerves appear at the outer border of the scalenus anticus as 4 cords, because the 8th. cervical and 1st. dorsal unite close to the vertebral foramina, they all lie against the scalenus medius and posticus and above the level of the subclavian artery. The branches of the plexus given off above the clavicle are the nerve to the subclavius, a small branch lying in front of the plexus derived from the trunk formed by the 5th. and 6th. above the supra-scapular, it crosses the thirdstage of the subclavian artery. Nerve to the rhomboids, from the 5th. , pirces scalenus medius, passes under the levator anguli scapulae to which it gives a branch, enters under surface of the rhomboids. Supra-scapular nerve, the largest of the supra-clavicular branches, from the cord formed by the 5th. and 6th. disappears behind the trapezius, clavicle and omo-hyoid to reach the supra-scapular notch where it dies under the ligament, the artery going over. The posterior thoracic or nerve of Bell, lies behind the plexus against the serratus magnus, from the 5th. and 6th. before they join (sometimes also the 7th.)the branches uniting in the scalenus medius.. A branch to the phrenic nerve is given from the 5th. at the upper part. also small branches to the longus colli and scalene muscles.

THE STERNO MASTOID MUSCLE origin, by a rounded tendon from the anterior surface of the manubrium sterni about half an inch below the supra-sternal notch and by a a broad tendinous origin from the inner third of the upper surface of the clavicle. Between the two heads is a cellular interval. Insertion, mastoid process of temporal and outer half of the superior curved line on the occipital.

THE ANTERIOR TRIANGLE OF THE NECK, bounded in front by the median line from the symphysis menti to the sternum, behind by the sterno mastoid, above by the line of the jaw and an imaginary line extending from the angle of the jaw to the mastoid, is apex is below at the summit of the sternum. Its roof is formed by the 5 structures and it is subdivided into three smaller triangles by the anterior belly of the omo-hyoid and the posterior belly of the digastric and the stylo hyoid. The upper triangle is called the submaxillary, is bounded above by the jaw and the imaginary line, below by the posterior belly of the digastric and the stylo hyoid, anteriorly by the middle line of the neck, from the chin to the hyoid bone. Its floor is formed by the anterior belly of the digastric, the mylo-hyoid, the hyo-glossus and the middle constrictor of the pharynx. it contains part of the facial and lingual vessels with some of their branches, the submaxillary salivary and some lymphatic glands, the hypoglossal nerve and the mylo-hyoid branches of the inferior dental vessels and nerve. The superior carotid triangle, bounded by the stylo-hyoid and the posterior belly of the digastric above, anterior belly of the omo-hyoid below, sterno-mastoid behind.

Floor, hyoid bone, thyroid cartilage, thyro-hyoid membrane and ligament, the prevertebral region, the hyo-glossus, the middle and inferior constrictors and a small part of the thyro-hyoid muscle. It contains parts of the common, internal and external carotid arteries, with the branches of the external. veins, lymphatic vessels and glands, the vagus nerve with its pharyngeal, laryngeal and superior cardiac branches, the branches of the superior cervical ganglion and the hypoglossal nerve with its thyro-hyoid and descendens cervicis branches. The inferior carotid triangle is bounded in front by the median line from hyoid bone to sternum, behind and above by the omo-hyoid, behind and below by the sterno-mastoid. Floor, sterno-hyoid and thyroid muscles, the body of the thyroid gland, larynx, trachea, oesophagus, thyroid vessels, some small nerves and lymphatics. (NOTE, many of these structures are considered as contents and not as forming the floor.

DESCENDENS CERVICIS NERVE, lies either on or in the sheath of the carotid vessels is a branch of the hypoglossal and runs down to supply the sterno-hyoid, sterno-thyroid and the omo-hyoid. It gives a branch to each muscle. From the cervical plexus is given off a small branch which unites with the hypoglossal to form a loop the ansa hypoglossi, .

THE STERNO-HYOID is the most superficial muscle, Origin, back of upper part of sternum, posterior sterno-clavicular ligament, inner extremity of the clavicle. Insertion, body of hyoid.

STERNO-THYROID, Origin, back of sternum below the last and from the 1st. and possibly the 2nd. costal cartilage, Insertion, oblique line on the side of the thyroid cartilage.

THYRO-HYOID, Origin, oblique line on thyroid cartilage, Insertion, lower border of the body and greater cornu of the hyoid.

OMO-HYOID, now seen in its whole length, crosses the neck below the sterno-mastoid, consists of two bellies united by a central tendon which is held down to the clavicle and first rib by a process of deep fascia. Origin, margin of the suprascapular notch and from the transverse ligament, Insertion, body of hyoid The three muscles are supplied by the descendens cervicis nerve except the posterior belly of the omo-hyoid which is supplied by the ansa hypoglossi.

DIGASTRIC, consists of two bellies placed above the hyoid bone to which the central tendon is attached. Origin, digastric fossa on mastoid, Insertion, lower border of inferior makilla close to the median line. Nerve, posterior belly, branch of the facial, Anterior by the mylo-hyoid branch of the inferior dental nerve. The submakillary gland lies in the interval between the two bellies.

STYLO HYOID, is in immediate connection with the posterior belly of the digastric., is pierced by the tendon of the digastric near its insertion. Origin, posterior of base of styloid process of temporal, Insertion, upper surface of body of the hyoid at junction with the great cornu. Nerve, digastric branch of facial.

THE COMMON CAROTID ARTERY has the same relations on both sides above the articulation of the clavicle with the sternum. Anteriorly, the five structures in the superficial neck, sterno-mastoid, hyoid, and thyroid muscles, the sterno-mastoid branch of the superior thyroid artery, internal jugular vein (on left) middle and superior thyroid veins, hypoglossal nerve and a part of the lateral lobe of the thyroid. Behind, prevertebral region, vertebral and inferior thyr-

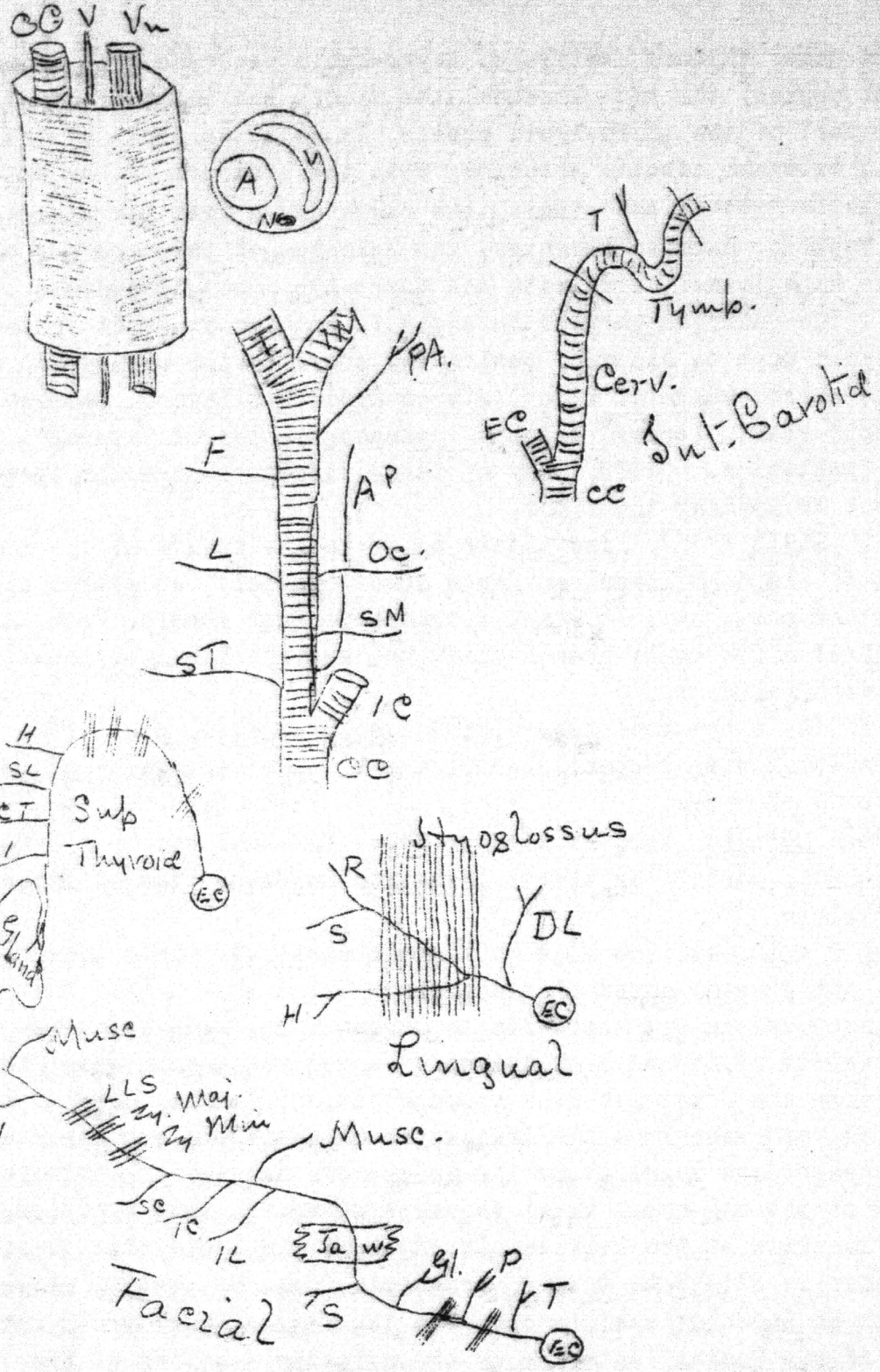

M. = Mastoid
D Digastric
SM Sterno mastoid
TM Trachelo "
SO Supr. Oblique
RCPM = Rect. Cap. Post. Maj.

roid arteries, recurrent laryngeal nerve the sympathetic cord and middle cervical ganglion, the thoracic duct on the left side and the right lympathic trunk on the right. Externally are the internal jugular vein which tends to overlap it below on the left, Internally the trachea, larynx, thyroid body, pharynx, oesophagus and recurrent laryngeal nerve. The arter: bifurcates about the level of the upper border of the thyroid cartilage into ex ernal and internal carotids.

INTERNAL CAROTID ARTERY ascends to the base of the skull, lying close to the pharynx on the prevertebral region, the vagus and the sympathetic. It is at first external to the extern l carotid, is crossed by the hypoglossal nerve, the digastric and stylo-hyoid muscles and the posterior auricular and occipital arteries. Behind it Passes the superior laryngeal branch of the pneumogastric. In its further course it lies deeper than the external and is separated from it by the styloid process, the stylo-glossus and pharyngeus, the glosso-pharyngeal nerve and the pharyngeal branch of the vagus. It then enters the carotid canal in the petrous portion of the temporal bone.

THE EXTERNAL CAROTID ARTERY lies at first to the inner side of and superficial to the internal, ascends in the parotid gland to a point opposite the condyle of the jaw. It is crossed in the neck by the digastric and stylo-hyoid, hypoglossal nerve, lingual and facial ~~nerves~~ veins and is separated from the internal by the structures previously mentioned with the internal carotid. Its branches are divided into three sets, Anterior, superior thyroid, lingual, facial. Posterior, occipital, posterior auricular and sterno-mastoid and Ascending, temporal, internal m.xillary and ascending pharyngeal.

SUPERIOR THYROID arises close to the bifurcation, runs forward beneath the depressrors of the hyoid, than downward to the thyroid body to anastomose with the other thyroid arteries. It gives off an inferior hyoid branch which runs along the lower border of the hyoid, a superior thyroid which pierces the thyro-hyoid membrane, a crico thyroid which anastomoses with its fellow on that membrane and a superficial descending branch which goes to the depressor muscles and gives off a sterno-mastoid branch.

LINGUAL ARTERY runs up then tranrversely on the middle constnictor just above the hyoid bone disappears in or under the hyo-glossus muscle. It is crossed by the digastric and stylo-hyoid muscles and the hypoglossal nerve, overlapped by the submaxillary gland.

FACIAL ARTERY passes up and forward under the digastric and stylo-hyoid and hypoglosral nerve, then forms a sigmoid curve and lies in a groove on the submaxillary gland. It crosses the jaw lying to the inner side of the nerve just in front of the masseter, In the neck it gives off inferior palatine and tonsillar branches as also submaxillary to the gland and submental to the chin.

All of these arteries will be further considered, as will also those which will now be considered.

OCCIPITAL ARTERY, now only seen in its first part. Runs back along the inferior border of the digastric and then under its origin in a special groove in the mastoid portion of the temporal bone, usually giving off a sterno-mastoid branch around which the hypoglossal nerve hooks. The artery crosses the hypoglossal nerve the internal carotid artery, the vagus, internal jugular vein, spinal accessory nerve and the sympatheteic.

POSTERIOR AURICULAR ARTERY is much smaller, arises under the digastric and runs the mastoid process which it crosses. Near the mastoid gives off the stylo-mast

towards the mastoid process which it crosses, near it giving off a stylo-mastoid branch into the foramen of that name. Then gives off auricular, mastoid and and temporal branches.

STERNO-MASTOID ARTERY sometimes given off from the external carotid, sometimes from the occipital. The hypoglossal nerve winds round it. Enters the under surface of the sterno mastoid.

THE VEINS do not take quite the same course, the temporo maxillary is formed in the substance of the parotid, afterwards receives the posterior auricular, passes down in the gland on the outer side of the artery and the facial nerve. Divides at the angle of the jaw into the ex ernal jugular and the facial communicating, latter joins the facial to form the common facial which enters the the internal jugular, lingual vein joining the facial, the occipital vein generally ends in the network under the complexus.

INTERNAL JUGULAR VEIN, is deeply placed to the outer side of the internal carotid artery, immediately below the base of the skull, afterwards lies in the same relation to the common carotid. It receives the facial, lingual, pharyngeal, superior thyroid and middle thyroid veins, unites with the subclavian to form the inominate.

THE SUBCLAVIAN ARTERIES differ on the two sides, the right beginning at the bifurcation of the inominate opposite the sterno-clavicular articulation, the left in the thorax at the arch of the aorta.. Both arteries are divided into three parts of which the second and third are the same on both sides, the relations in the first part only differing very slightly. The first part on the right extends from the bifurcation of the inominate to the inner margin of the scalenus anticus, upward and outward. Anteriorly it has the origins of the sterno hyoid, thyroid and mastoid, the commencement of the common carotid artery, the internal jugular and vertebral veins, the pneumogastric, cardiac, phrenic and recurrent laryngeal nerves. Posteriorly are the apex of the pleura, the recurrent nerve, the sympathetic cord and some cardiac nerves. On the left the first part extends from the arch of the aorta to the inner border of the scalenus antious, the relations are the same in the cervical portion of this course as on the right save that the recurrent nerve does not wind round it, the thoracic duct arches above and in front of the artery to open into the junction of the subclavian and internal jugular veins. The branches of the first part of the artery are Vertebr internal mammary and thyroid axis.

VERTEBRAL ARTERY is only seen in a small part of its course now, it arises from the posterior part of the upper border of the subclavian, runs up in front of the transverse process of the 7th. cervical vertebra, enters the foramen in the transverse process of the 6th., passes through the foramina in the transverse processes of all above, winds inward on the atlas to enter the foramen magnum t supply the brain. Spinal branches are given off in the neck which enter the canal through the intervertebral foramina, muscular branches supply the spinal muscles behind the column. The vein takes the same course, but begins in the neighborhood of the foramen magnum.

INTERNAL MAMMARY ARTERY, at once descends into the thorax, being crossed superficially by the phrenic nerve close to its origin. The artery runs behind the costal cartilages of the true ribs, giving off comes nervi phrenici, mediastinal, pericardiac, anterior intercostal and perforating branches and terminates

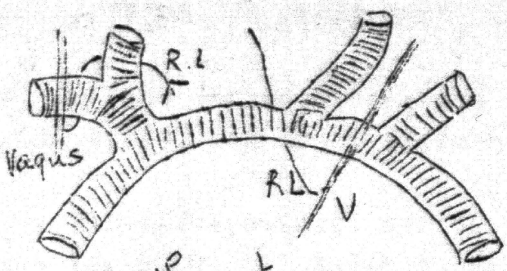

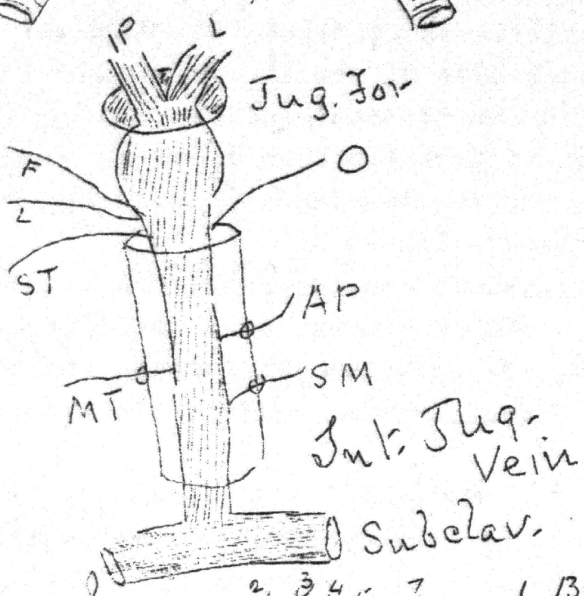

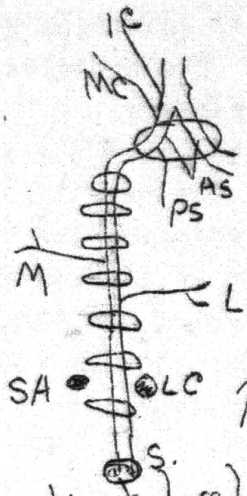

Page 97

Vertebral

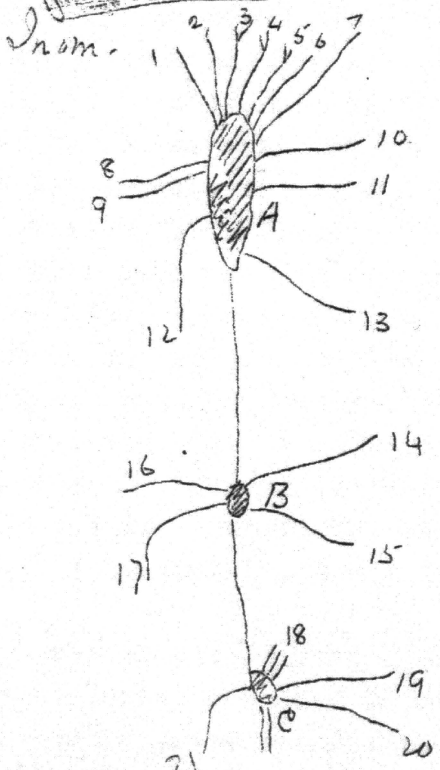

A Sup. Ganglion
B Mid "
C Inf "

1. Br. to Ext. Carotid
2 " " Int. "
3 " " 9th Nerve
4 " " 10th "
5 " " 11th "
6 " " 12th "
7 " " 1st C. "
8 Pharyngeal Br.
9 Laryngeal Br
10 to 2nd Cervical
11 to 3rd "
12 Sup. Cardiac
13 4th Cervical
14 5th "
15 6th "
16 Thyroid Branch
17 Middle Cardiac
18 Brs. to Vertebral
19 to 7th Cervical
20 to 8th "
21 Inferior Cardiac

Page 99.

by dividing into the musculo phrenic and the superior epigastric.
THE THYROID AXIS is a short thick trunk from the upper part of the artery which at once divides into the inferior thyroid, transversalis colli and supra-scapular.
INFERIOR THYROID at first runs up and in across the vertebral artery and behind the carotid sheath and sympathetic, then curves in and down opposite the 6th. cervical, goes down as far as the lower border of the thyroid body, passes in behind the recurrent nerve, turns upward and breaks up into a leash of branches which enter the thyroid. It gives off oesophageal, tracheal, and a small inferior laryngeal and the ascending cervical which runs between the prevertebral muscles in front of the anterior tubercles on the transverse processes of the cervical vertebrae. The inferior thyroid veins pass down in front of the trachea after forming a plexus below the isthmus of the thyroid. They open into the inominate.
TRANSVERSE CERVICAL ARTERY runs transversely out in front of the scalenus anticus and the phrenic nerve, has been already seen in the posterior triangle.
SUPRASCAPULAR ARTERY, runs out in front of the scalenus anticus, phrenic nerve and third part of the subclavian artery, has been seen in the posterior triangle It gives off ster-no-mastoid, supra-sternal, clavicular and acromial branches in the neck and a small subscapular at the upper border of the scapula.
THE SECOND PART OF THE SUBCLAVIAN ARTERY lies behind the scalenus anticus. In front are the clavicular origin of the sterno mastoid and the scalenus anticus with the superficial structures, behind are the apex of the pleura, the scalenus medius, Above are the cords of the brachial plexus and below is a small portion of the inner border of the first rib. The vein is below the level of the artery and the scalenus anticus lies between them. The branch from this part of the artery is the superior intercostal on the right, the left artery usually arising internal to the anterior scalene.
SUPERIOR INTERCOSTAL ARTERY arises about half an inch external to the vertebral. It runs up for a short distance, then divides into the first intercostal and the deep cervical, descends into the thorax in front of the neck of the first rib, gives branches to the first intercostal spaces and laso spinal and posterior branches just as do the aortic intercostals.
THE THIRD PART OF THE SUBCLAVIAN ARTERY was seen in the posterior triangle.
THE SUBCLAVIAN VEIN, is the direct continuation of the axillary, lies anterior but below the artery. It passes over the groove in the first rib anterior to the scalenus anticus, runs in front of the apex of the pleura and joins the internal jugular to form the inominate. The thoracic duct opens into the venous junction on the left side, the right lymphatic duct does the same thing on the right.
THE THORACIC DUCT rises as high as the lower border of the 7th. cervical vertebra then crosses behind the carotid sheath in front of the vertebral artery, the first stage of the subclavian artery and the phrenic nerve to enter the venous junction. It is sometimes double, carries all the lymph except that of the right side of the trunk which is carried by the right duct and by it is carried to the right subclavian vein.
THE VAGUS IN THE NECK, is enclosed in a separate compartment of the carotid sheath lies behind and between the jugular vein and the common carotid artery, enters the superior aperture of the thorax on the inner side of the phrenic nerve, on the right side passing between the subclavian and the inominate vein, on the left be-

tween the common carotid and subclavian arteries and behind the inominate vein.
SUPERIOR LARYNGEAL NERVE is a branch which springs from the ganglion of the trunk and runs forward beneath the internal jugular vein and the internal carotid artery, appears opposite the hyoid bone and pierces the thyro-hyoid membrane to supply the mucous membranes of the larynx. It gives off a small external laryngeal branch to supply th crico-thyroid, also some filaments to the inferior constrictor.
RECURRENT LARYNGEAL NERVE or inferior runs up along the side of the trachea between it and the oesophagus, it passes under the thyroid body and disappears under the lower border of the inferior constrictor. . On the right it arises from vagus in the neck, in front of t e subclavian artery and winds below and then behind that vessel, on the leftit rises in the thorax and turns in the same way round the arch of the aorta external to the ductus arteriosus. It gives off cardiac, tracheal and oesophageal and filaments to the inferior constrictor and supplies all the intrinsic muscles of the larynx except the crico-thyroid.
CARDIAC BRANCHES OF THE VAGUS, are superior given off high up in the neck and which join the sympathetic and inferior which arise a little above the superior aperture of the thorax through which they pass to the cardiac plexuses.
Pharyngeal branch is given off higher up, will be seen later.
THE HYPOGLOSSAL NERVE, has been already seen, after communicating with the 1st. cervical nerve and the superior ganglion of the sympathetic appears below the posterior belly of the digastric, hooks around the sterno-mastoid branch of either the external carotid or the occipital and curves forward lying anterior to the great vessels. It passes beneath the stylo-hyoid and the posterior bell y of the digastric and lies in he angle between the two bellies of the digastric, on the hyo-glossus, finally passes beneath the posterior border of the mylo-hyoid to reach the tongue. Its descending branch, the descendens cervicis, arises opposite the occipital artery,. runs downward and forward either on or in the carotid sheath to supply the sterno-hyoid, thyroid and omo-hyoid and to form the ansa hypoglossi as already mentioned. .
THE SYMPATHETIC IN THE NECK lies behind the carotid sheath on the prevertebral region, it is a slender cord with three ganglea, superior, middle and inferior. The diagram of this plexus (from Gray) is sufficiently explanatory.
SPINAL ACCESSORY NERVE, af.er passingover or under the internal jugular vein appears below the digastric, it pierces the deep surface of the sterno-mastoid muscle giving branches to it, crosses the posterior triangle, runs on the levator anguli scapulae to reach the trapezius which it supplies.
THE CERVICAL PLEXUS is formed by the anterior divisions of the upper four cervical nerves, the 2nd. 3rd. and 4th. nerves appear between the rectus capitis anticus major and the scalenus medius, lying under the sterno-mastoid. Each of the nerves communicates with the one above and below and gives off deep and superficial branches. The superficial have been already mentioned in the posterior triangle, the deep are communicating branches to the 9th., 10th., and 12th. cranial nerver and the sympathetic; muscular branches to the rectus capitis anticus major, minor and lateralis, the sterno-mastoid, levator anguli scapulae and scalenus medius with the trapezius, those to the trapezius and sterno-mastoid communicate withthe spinal accessory. The communicantes cervicis are a couple of small branches which enter intothe formation of the ansa hypoglossi. The PHRENIC NERVE is the most important from the plexus, it arises usually from the

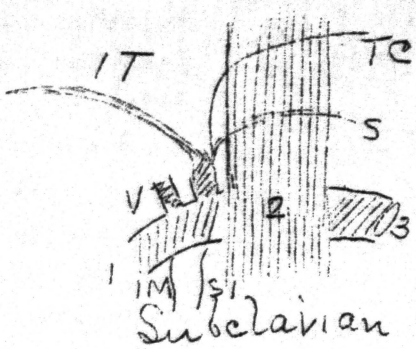

Page 98

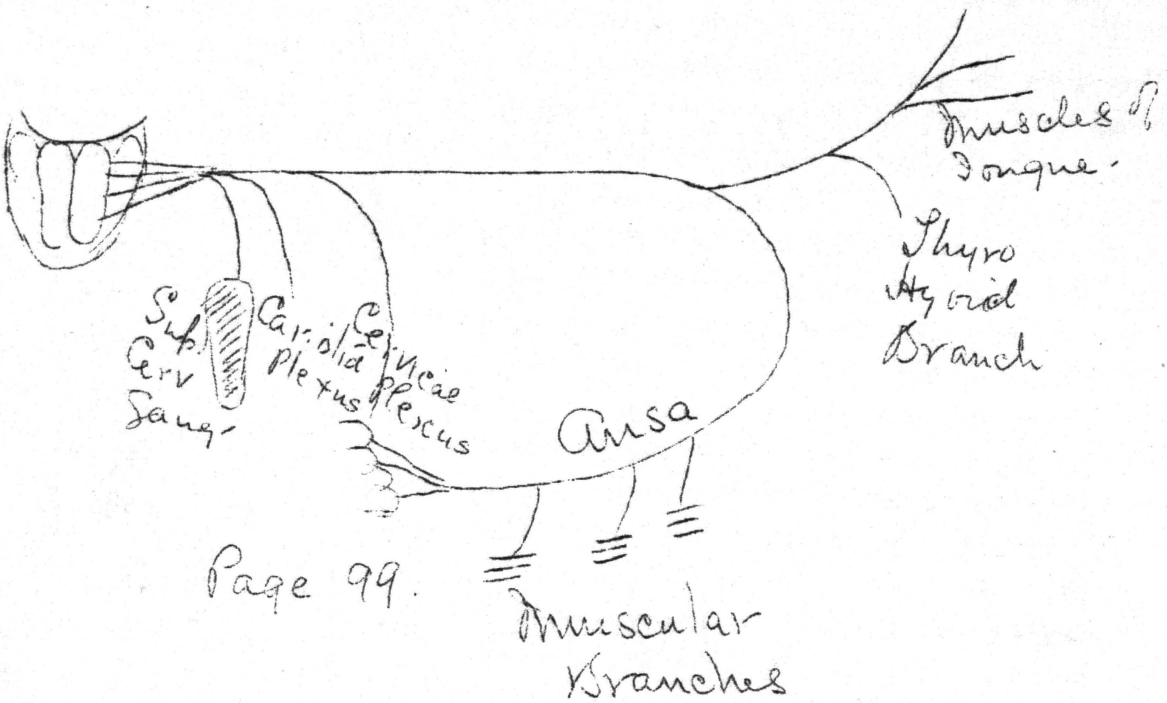

Page 99.

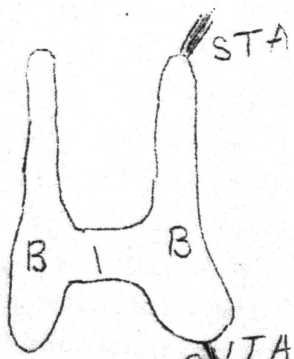

Thyroid Gland
Page 100.

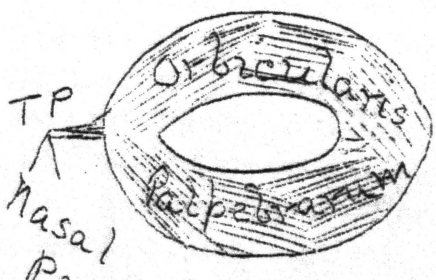

Page 100.

4th. nerve or else the 3rd. and 4th., it receives a branch of communication from the 5th., runs down on the scalenus anticus, crosses in front of the 1st. part of the subclavian artery and the commencement of the internal mammary artery and behind the inominate vein it enters the thorax. H's been seen in the thorax.

THE TRACHEA, is about 4½ inches in length, extends from the lower border of the 6th. cervical vertebra to the lower border of the 4th. dorsal, where it bifurcates into the bronchi. In front of it in the neck lie the isthmus and the pyramidal lobe of the thyroid, the thyro-hyoid and sterno-thyroid muscles, the cervical fascia and the remains of the thymus gland, the inferior thyroid veins and the thyroidea ima artery when present. Laterally it is in close relation with the lateral lobes of the thyroid body, and the recurrent laryngeal nerve runs between it and the oesophagus. Posteriorly it is attached to the anterior surface of the oesophagus by connective tissue. It has a connective tissue sheath.

THE OESOPHAGUS commences at the same point below the lower border of the inferior constrictor and passes into the thorax. In the neck it has in front the trachea, the thyroid body, the left recurrent laryngeal nerve and the left comm carotid artery. Behind are the vertebrae and the prevertebral region, on the lef in addition the thoracic duct.

THE THYROID BODY or gland is a solid ductless organ embracing the front and sid of the trachea. It is composed of two lobes united by an isthmus. This latter is about half an inch in depth, lies opposite the first dorsal vertebra. It is commonly surmounted by a little pyramidal body called the pyramidal lobe, occasionally receives a few muscular fibres from the hyoid bone. The lateral lobes are about two inches in length, apex up, and lie by the sides of the trachea and extend higher up than they do below the isthmus.. The blood supply of the gland is from the superior and inferior thyroid arteries, occasionally by the thyroide ima when it is present.

THE FACE, the skin is very thin and intimately attached to the subjacent structures. The muscles of expression are very pale in color and are unimportant with one or two exceptions. They differ from all the other muscles of the body in that while their origin is under the deep fascia their insertion is without it. The muscles are divided into 4 groups, Muscles of the Pinna, attrahens aurem, attollens aurem and retrahens aurem. Muscles of the Palpebral fissure, orbicularis palpebrarum, occipito-fronctalis, corrugator supercilii. Muscles of the Nostril, Pyramidalis nasi, levator communis and compressor narium. Muscles of the Oral fissure, levator communis, levator labii superioris, levator anguli oris, zygomaticus major and minor, risorius, platysma, depressor anguli oris, depress labii inferioris and orbicularis oris. Allthe muscles of expression are supplie by the facial nerve, of the pinna muscles the retrahens aurem alone is attached to bone. The orbicularis palpebrarum is nearly an inch broad, is in the form of a whole series of irregular meshes attached at only one point to bone, the nasal process of the superior maxilla by the tendo palpebrarum. The corrugator supercilii is a little mass of muscle under the last, if both muscles contract they produce a vertical furrow at the root of the nose. The pyramidalis nasi is in thuth a part of the occipito frontalis. Levator communis arises from the nasal process of the superior maxilla and is inserted into the alae of the nose and i

upper lip. It is the muscle of sneezing. The compressor nárium compresses the the cartilaginous nose, it is feebly developed in man, largely so in the seal. Levator labii superioris, origin from a line below the infraorbital foramen, Zygomaticus major is always behind the minor, both arise from the outer surface of the malar bone, inserted at the angle of the mouth. Risorius, a bundle of transverse fibres arising from the fascia lata and inserted into the angle of the mouth. N

NERVES OF THE FACE The facial nerve leaves the skull at the stylo-mastoic foramen and and at once gives off the posterior auricular (which supplies the retrahens aurem and the occipito frontalis) stylo-hyoid (which supplies the stylohyoid and the posterior belly of the digastric). The nerve then passes forward in the substance of the parotid gland and divides into two main portions, the tempore-facial and the cervico facial. Each division divides into three nerves, and these by their interlacement produce the appearance termed the pes anserinus. The temporo-facial division gives off the temporal which communicates with the temporal of the 5th., the malar with the subcutaneous malae of the 5th., the infraorbital with the infraorbital of the 5th. The cervico facial gives off buccal unites with the buccal of the 5th., the supraAmaxillary with the superficial malar while the infra-maxillary joins with the superficial cervical and supplies the platysma. The distribution is irregular but commonly the temporal supplies the muscles above the palpebral fissure, the infraorbital the muscles between the palpebral and labial fissures, the buccal supplies the buccinator while the supramaxillary is distributed to the muscles of the lower lip and the infra maxillary to the platysma.. The

THREE DIVISIONS OF THE 5TH. NERVE appear on the face, the first or ophthalmic appears as the supra-trochlear at the inner angle of the orbit, as the supra-orbital at and internal to the supra-orbital notch, as the lachrymal below the external angular process, as the infra-trochlear below the pulley of the superior oblique and as the nasal which emerges from the interspace between the nasal bone and the cartilage on the side of the nose. The second, or superior maxillary division appears as the infra-orbital at the infraorbital foramen, as the malar branch of the temporo-malar appearing through the malar bone after piercing ing the outer wall of the orbit and as the temporal branch of the temporo-malar nerve piercing the temporal fasciaimmediately above the zygoma.. The third, or inferior maxillary div isionappears as the mental nerve at the mental foramen, as the buccal nerve on the surface of the buccinator and as the auriculo temporal al nerve passing beneath the parotid gland..

THE PAROTID GLAND is the largest of the salivary glands and is placed in front of the ear, its superficial part overlaps the masseter reaching as high as the zygoma and as far back as the mastoid process, below it is separated from the submaxillary gland by the stylo-maxillary ligament. . An anterior lobe more or le s detached lies upon the masseter and is called the socia parotidis. The deep portion has three processes, one occupies the posterior part of the glanoid fossa, the second accompanies the internal maxillary artery beneath the lower jaw, the third passes back beneath the sterno-mastoid and reaches the root of the styloid process and the deep vessels and nerves of the neck. The duct of the gland is called the Duct of Stenson and is about 3 inches in length. It arises from the anterior part of the gland below the socia, receives a small

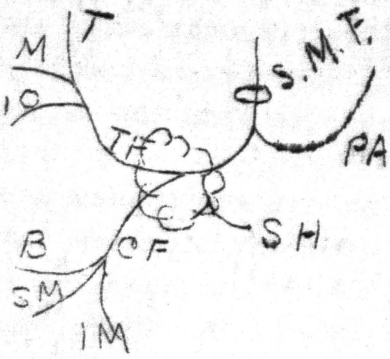

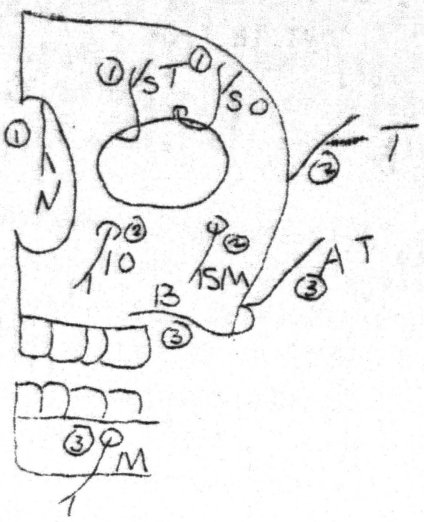

Page 101

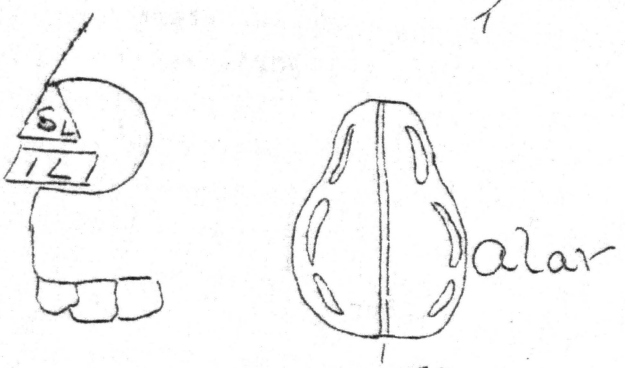

Nasal Cartilages

Page 103

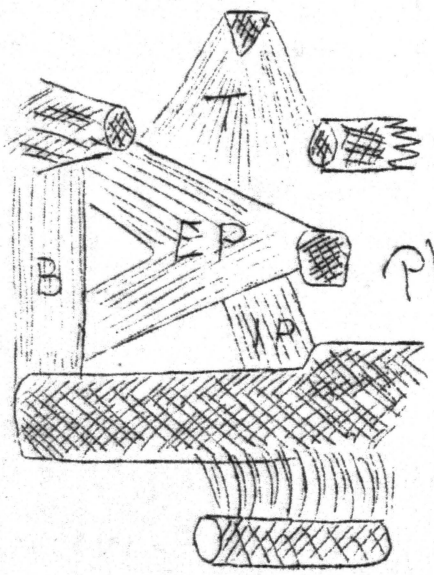

Pterygo-maxillary Region.

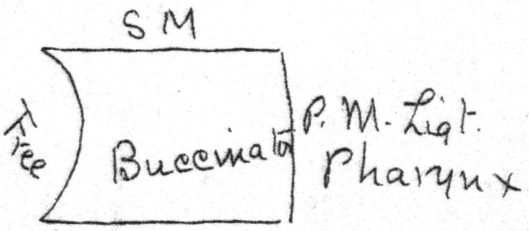

Page 104

receiving a small duct from the sociapasses transversely across the masseter tumns round in front of that muscle opens into the mouth through the bucoinator opposite the second molar tooth in the upper jaw. Just below the duct is a largebranch of the facial nerve and above below it the transverse facial artery. The external carotid artery, the transverse facial artery, the temporo-maxillary vein and the pes anserinus of the facial nerve pass through it.. Its arteries are from the temporal and external carotid and its special nerves are from the auriculo temporal and sympathetic as well as the facial and the great auricular;
THE FACIAL ARTERY, is very tortuous, it is found in the neck and on the face, the facial portion hasnot yet been mentioned while the cervical has been. The artery having crossed the jaw just in front of the masseter passes toward the inner canthus of the eye where it anastomoses with the opnthalmic. In the face it lies upon the muscles and side of the nose, being crossed by three of the facial muscles, the zygomatici and the levator labii superioris. The branches of the artery in the face are inferior labial which passes transversely beneath the depressor anguli oris, inferior and superior coronary which run near the margins of the lips supplying the mucous membrane also, and the superior giving a small branch to the septum of the nose, the lateral nasal passes beneath the levator communis to the ala and side of the nose and the artery terminates as the angular by anastomosing as mentioned. The branches from the outer side of the artery are muscular. The branches of the FACIAL VEIN do not correspond to the arterial branches.. Time is not expended on .hem, they being small and not of special importance.
TRANSVERSE FACIAL ARTERY arises from the temporal in the parotid gland, appears on face above the parotid duct, runs transversely in belor the zygoma toward the infra-orbital region, anastomosing with the facial, buccal and infra-orbital arteries. . Its vein terminates in the temporal or temporo-maxillary.
THE EYELIDS are covered with thin, freely moveable skin and are composed of a dense fibrous tissue and of muscle and fascia, they are lined internally with the conjunctiva continued from the surface of the eyeball. The points of junction of the lids are called the inner and outer canthi, along the free margins are seen the eyelashes which curve upward from the upper, downward from the lower lids. The inner extremities of the lids are attached to the nasal process of the superior maxilla by the tendo oculi, a similar but less distinct ligament is attached to the outer extremities and to the frontal process of the malar bone at the outer edge of the orbit.. The margins of the lids are so bevelled that when they are closed a small triangular canal is left between them and the anterior surface of the eye. On separating the lids a small depression is seen at the inner canthus, the lacus lachrymalis, on the free margin close to this on each lid a little eminence perforated by a minute hole, the punctum lachrymale. This communicates by a horizontal channel with the lachrymal sac, situated between the tendo oculi and the tensor tarsi muscle in the groove in the lachrymal bone. This is a delicate fibrous receptacle, continuous inferiorly with the nasal duct. The conjunctiva of the eye is reflected over the inner surface of the lids, on the eyeball it is loosely attached to the sclerotic but is adherent at the margin of the cornea.. On removing the thin palpebral fibres of the orbicularis the superior and inferior palpebral ligaments are exposed extending from the margins of the orbits; they are continuous with the periosteum of the

skull at the margin of the orbit. The tahsal bodies are formed of dense connective tissue, not cartilage. The upper eyelid consists of the following structures, skin, orbicularis palpebrarum, tahsal body (palpebral ligament and tendon of levator palpebrae) Meibomian glands, and conjunctiva. The lower lid is constituted the same except that it has no levator palpebrae.

CARTILAGES OF THE NOSE are arranged in three sets, lateral of which there are 2 on each side(superior and inferior), septal cartilages and alar cartilages. By the last the sides of the nose are kept bridged out. The skin over these cartilages is very closely adherent to them. The mucous membrane of the nose is soft, velvety and vascular, especially rich in veins. The arteries supplying the mucous membrane are derived from the internal maxillary (nasal and anterior palatine) ophthalmic,(ethmoidal) pharyngeal and facial.

THE PTERYGO-MAXILLARY REGIONThe facial nerves and vessels having been cleaned away witht the remains of the parotid gland, and the temporal fascia removed from the zygomatic arch, the arch is sawn through in front of and behind the masseter and, with it, thrown down. The coroniid process of the jaw is snipped off very obliquely and thrown upward with the temporal muscle, the neck of the jaw is then cut through and a saw cut made through theascending ramus, just abov the alveolar border, and the piece of bone excised. The floor of the region is formed of bone, ligament and muscle. Four bones enter into its formation, superior maxilla, malar, sphenoid and temporal. The ligament is the internal later of the jaw, three muscles are met with, the buccinator, and external and interr pterygoid.

THE MASSETER, is the most superficial muscle of mastication and is divisible into a superficial and a deep portion. Origin, lower border and inner surface of the zygomatic arch, Insertion, angle of jaw and lower half of the ramus, the insertion of the deeper portion which arises from the posterior part of the zygoma and the inner surface being into the outer surface of the upper half of th ramus of the jaw, including the root of the coronoid process.

THE TEMPORAL MUSCLE Origin, all of the temporal fossa except the wall formed by the malar bone, from the pterygoid ridge on the great wing of the sphenoid and from the under surface of the temporal fascia. Insertion, apex, anterior and posterior borders and inner surface of the coronoid process, extending along th ramus of the jaw almost as far as the last molar tooth.

EXTERNAL PTERYGOID MUSCLE, Origin, two heads, one from the outer surface of the external pterygoid plate ~~of the sphenoid~~ and the tuberosity of the maxilla, the other from the under surface of the great wing of the sphenoid below the pterygoid ridge. Insertion, hollow on the front of the neck of the lower jaw, the capsular ligament and the inter-articular cartilage of the joint.

THE TEMPORO MAXILLARY JOINT, is a double joint, one being on either side. It is a ginglymus joint, the bones involved being the glenoid fossa of the temporal and the condyle of the jaw. The ligaments are a capsule in which there is only one band, the external lateral ligament (short round band). The jointhas two accessory ligaments, the internal lateral which extends from the spine of the sphenoid to the posterior margin of the inferior dental canal. (called accessory because it does nit form a part of the capsule and is separated from it by the internal maxillary artery) the other is the stylo-maxillary ligament, a band passing from the styloid process to the angle of the jaw. On opening the joint a

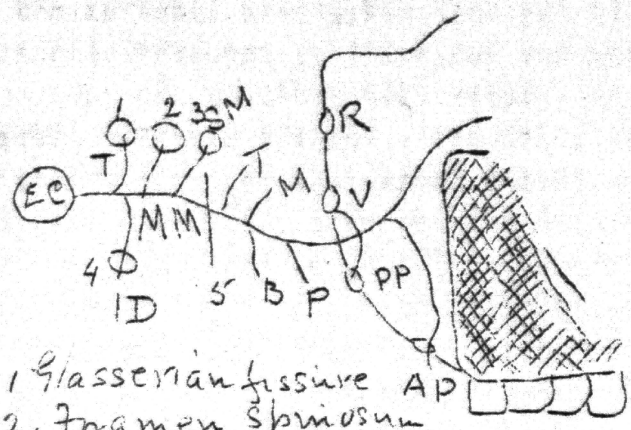

1 Glasserian fissure
2. Foramen Spinosum
3 Foramen Ovale
4 Inf. Dental foramen.
5 Int. lat Ligt.

Int. Maxillary Artery

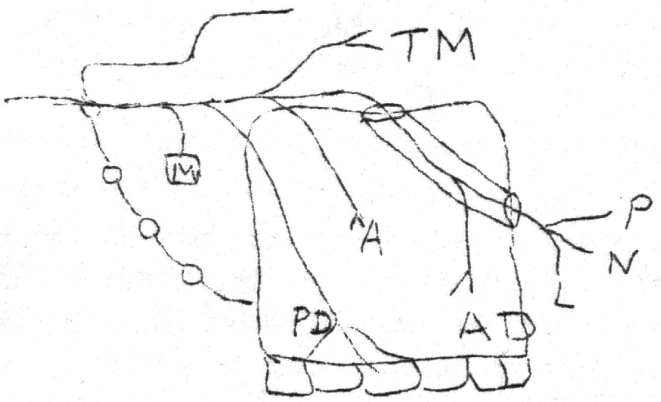

2nd Div. of V

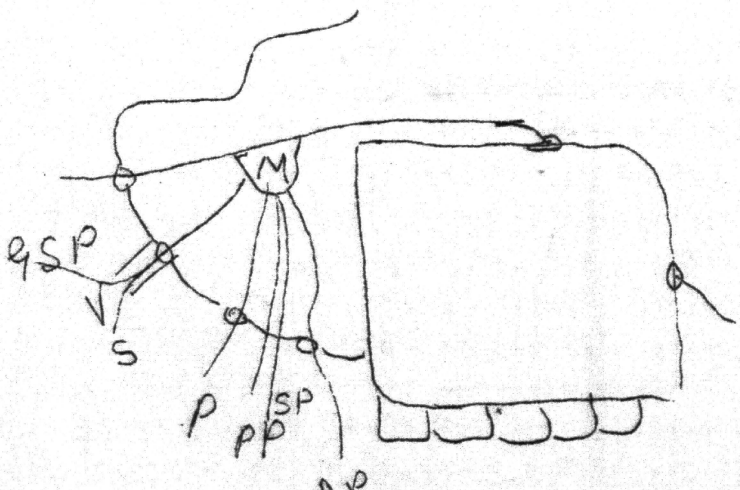

Meckel

perfect meniscus is found which separates the cavity into two parts, in consequence we have in this joint two synovial membranes. This menisous exists in order to allow the chewing of hard substances. The joint is supplied by the 5th. nerve. Movements, depression by the weight of the jaw aided by the muscles attached ho it and the sternum, hyoid, thyroid. Elevation, by the masseter, temporals internal pterygoids and buccinator, Protrusion by the external pterygoids and the anterior fibres of the temporals. In this last movement the condyle of the jaw articulates with the anterior root of the zygoma, the meniscus being at the same time pulled forward by the external pterygoids. Retraction, by the posterior fibres of the temporals (protrusion is the easier movement) The capsule is not specially weak in front although dislocation is most common in that direction. The alternating movements of hee muscles of the two sides while the other side has the condyle held steady in the glenoid fossa produces the grinding movement. THE INTERNAL PTERYGOID, lies under the internal lateral ligament. Orgin, internal surface of the external pterygoid plate, tuberosity of the palate and the adjacent surface of the superior maxilla. Insertion, inner surface of the angle of the lower jaw, fibres running parallel to the superficial portion ofthe masseter. BUCCINATOR, Origin, alveolar border of the superior maxilla opposite the molar teeth. between the jaws from the anterior margin of the pterygo-maxillary ligament. Insertion, lips and angles of the mouth, joining the orbicularis oris and probably continuous with the fellow muscle across the middle line. The fibres are perforated by the duct of Stenson. The princeple action is to keep the food between the teeth during mastication.

PTERYGO MAXILLARY LIGAMENT, an indistinct fibrous line which extends between the hamular process and the lower jaw close to the last tooth. Its anterior margin gives attachment to the buccinator, its posterior to the superior constrictor., it thus forms a boundary between the mouth and the pharynx. The muscles of mastication are all supplied by the motor portion of the third division of the 5th. nerve, except the buccinator which although receiving a filament from this nerve receives its motion from the facial nerve.

INTERNAL MAXILLARY ARTERY is seen in its first and second portions, the third lying in the spheno-maxillary fossa. It is one of the terminal branches of the external carotid artery and arises in the parotid gland. The first part passes forward between the neck of the jaw and the internal lateral ligament. It gives off a descending branch the inferior dental and three ascending the middle meningeal, the tympanic and auricular, sometimes also a small meningeal. The inferior dental passes goes through the inferior dental foramen, the tympanic through the Glasserian fissure, tha middle meningeal through the foramen spinosum, the small meningeal through the foramen ovale. All the branches of the first part of the artery thus going through bony foramina. The branches of the second partaare muscular, temporal, masseteric, bucoal and pterygoid. . The second part of the artery passes upward and forward to the pterygo-maxillary fissure, it is always intermuscular, but may lie between the temporal and external pterygoid on between the external and internal pterygoids.. Two of the branches of the third part of the artery can be now seen, the alveolar, ruuning over the body of the maxilla, giving off the posterior, superior dental which enters one of the foramina on the posterior surface of the superior maxilla, and second, the infra-orbital, running into the back apart of the spheno-maxillary fissure to reach t

the infra-orbital canal, it gives anterior dental to the incisors, canines and bicuspids and emerges on the face at the infra-orbital foramen, supplying muscles and integument. The Internal Maxillary Vain receives branches corresponding to those of the artery, finally enters the parotid gland to join with the temporal and form the temporo-maxillary.

THE INFERIOR MAXILLARY NERVE (3rd. division of the 5th.)emerges from the foramen ovale, lying in front of the middle meningeal vessels and external to the otic ganglion. It gives off a small recurrent bhanch which passes through the foramen spinosum with the middle meningeal artery and then breaks up into motor and sensory divisions, each of which, however, contains both motor and sensory fibres. The motor division is small, is distributed to the muscles of mastication. Its branches are anterior and posterior temporal (run out and up in the temporal muscle and supply it) A masseteric branch passes over the sigmoid notch to enter the deep surface of the muscle, it also gives branches to the pterygoids. The buccal branch, the only branch of this division which is not motor, is large and istinct. The sensory divisionbreaks up, close to the skull, into three branches, the lingual, most anterior, the inferior dental which has some motor fibres and the auriculo-temporal most posteriorly.

THE LINGUAL or gustatory nerve is found at the out angle of the jaw, it passes to the mucous membrane of the tongue supplying it anterior two-thirds, it is joined at an acute angle by the chorda tympani, a branch of the facial given off in the temporal bone, this junction taking place under cover of the internal pterygoid.

INFERIOR DENTAL NERVE, enters the substance of the jaw and supplies the lower teeth, most of it leaves as the dental nerve, although continued forward as an incisive branch. Before it enters the jaw it gives off a little branch the mylo hyoid nerve, which grooves the jaw and supplies the mylo-hyoid and the anterior belly of the digastric. .

THE AURICULO TEMPORAL NERVE has usually two roots of origin which embrace the middle meningeal artery, it passes behind the neck of the jaw and runs up in fr of the pinna, becoming cutaneous.. It communicates with the facial and the otic ganglion.

THE SUBMAXILLARY REGION.

This region has been already in part seen. It is bounded by the lower border of the jaw above, the middle line from symphysis to hyoid bone in front, the bo of the hyoid with the stylo-hyoid and digastric below. Its floor is formed by the anterior belly of the digastric, the mylo-hyoid, the hyo-glossus and the middle constrictor. This region contains part of the submaxillary gland, the facial artery giving off its cervical branches, the facial vein, the hypoglossa nerve and the mylo-hyoid nerve and vessels. It is covered by the five structur of the neck.

THE MYLO-HYOID, Origin, mylo-hyoid ridge on the inner surface of the lower jaw, Insertion, body of the hyoid, meeting its fellow in a median raphe. It forms the muscular floor for the mouth. Its contraction raises the whole tongue towar the floor of the mouth. Nerve, mylo-hyoid branch of the inferior dental.

THE SUBMAXILLARY GLAND consists of a superficial and a deep portion, the former lies in the angle between the two bellies of the digastric, under cover of a part of the lower jaw. The deep part is continuous with the superficial but is

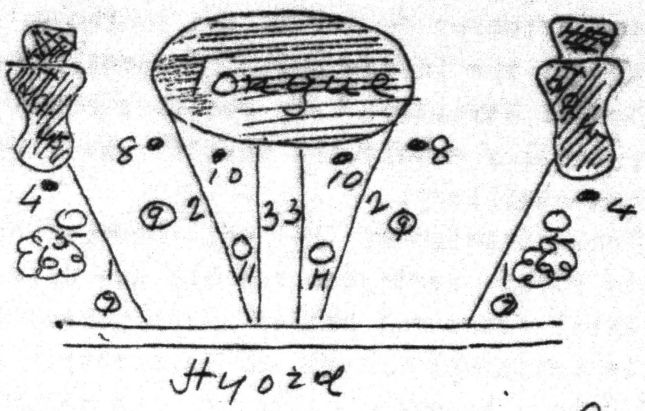

1 Mylohyoid
2 Hyoglossus
3 Geniohyoglossus
4 Inframaxillary N.
5 Submental Art.
6 Submaxillary Gland
7 Hyoid Br. of Lingual A.
8 Lingual N.
9 Wharton's Duct
10 Glyssopharyn. N
11 Lingual Art.

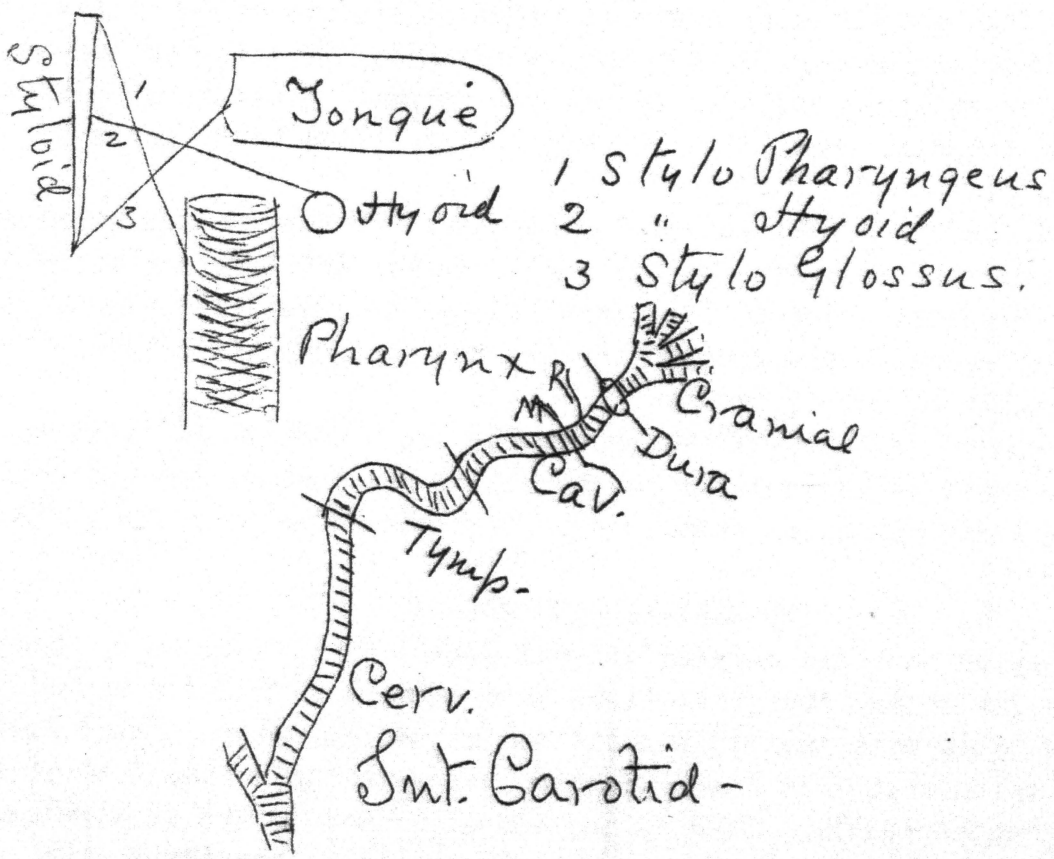

1 Stylo Pharyngeus
2 " Hyoid
3 Stylo Glossus.

situated below the mylo-hyoid which separates it from the superficial except at the posterior border of the muscle where they are continuous. The duct arises from the deep portion and is about two inches in length, Wharton's duct, it runs forw.rd on the hyo- and genio-glossus to open on the summit of a papilla close to the fraenum of the tongue. The
SUBLINGUAL GLAND is situated beneath the mucous membrane close to Wharton's duct, into which one of its ducts opens, the others opening into the mouth on the sublingual fold near the fraenum.
THE SUBMAXILLARY GANGLION is small and lies on the hyo-glossus below the lingual nerve. It has three roots, sensory from the lingual, motor from the facial by means of the chorda tympani and sympatnetic from the plexus on the facial artery
THE HYPOGLOSSAL NERVE has been seen hooking round the sterno-mastoid or occipital artery and passing under the submaxillary gland and posterior border of the mylo-hyoid. . It now lies on the hyo-glossus, communicates with the lingual and ends in the genio-glossus. It gives branches to the stylo, hyo and genio-glossi, and to the genio-hyoid, also to the intrinsic muscles of the tongue.
HE HYO-GLOSSUS, Origin, outer part of the body of the hyoid, upper margin of the whole length of the great cornu and the lesser cornu, Insertion, side of the dorsum of the tongue, blending with the stylo-glossus and lying outside the lingual is inferior. It has three attachmeots to the hyoid, its portions are therefore sometimes called basio, kerato and chondro glossus.. Relations of the hyo-glossus. On the outer side are --- well, the relations are well shewn in the diagram which is self-explanatory.
THE STYLO-GLOSSUS, Origin, near the tip of the styloid process and the stylo-hyoid ligament, Insertion, side of the tongueblending with the hyo-glossus posteriorly, the liogualis inferior anteriorly.
STYLO PHARYNGEUS, Origin, root of the styloid on its inner side, Insertion, posterior border of the thyroid cartilage.
THE LINGUAL ARTERY, has been described in its first stage extending from the external carotid to the posterior border of the hyo-glossus. It passes under the hyo-glossus, runs for a short distance above the greater cornu of the hyoid bone between the hyo- and genio glossus, its third rtage begins at the anterior border of the hyo-glossus and lies between the genio-glossus and the mucous membra terminating at the tip of the tongue. Its branches are four, Superior hyoid, arises in first stage, runs along upper border of hyoid bone, Dorsalis linguae, arises near posterior border beneath the hyo-glossus, ascends to the dorsum of the tongue. This branch is snmetimes large. The sublingual is also usually larg comes off under the hyo-glossus, runs forward between the genio-glossus and th sublingual gland, supplying both. The ramine is the termination of the artery, supplies the muscle and mucous membrane. The LINGUAL VEINS two venae comites accompany the artery and a ranine vein.
THE GENIO-HYOID Origin, lower of the genial tubercles, close to the symphysis menti, Insertion, body of the hyoid above the insertion of the mylo-hyoid.
GENIO-GLOSSUS, OriginUpper genial tubercle, Insertion, median line all along th under surface of the tongue.
STYLO-HYOID LIGAMENT a narrow band passing from the styloid process to the lesser cornu of the hyoid bone. It gives origin to some of the fibres of the stylo-

glossus above and to the fibres of the middle constrictor..
THE STYLO-MAXILLARY LIGAMENT is a process of deep cervical fascia passing from the styloid process to the inner surface of the angle of the jaw.. It lies between the parotid and submaxillary glands.
THE GLOSSOPHARYNGEAL NERVE emerges from between the jugular vein and the interna carotid artery, winds round the outer surface of the stylo-pharyngeus, passes under the stylo-glossus to the base of the tongue, divides into two branches, supplying gustatory filaments to the circumvallate papillae, common sensation to the back part of the mouth, fauces and pharynx and gives muscular supply to the stylo-pharyngeus and the pharynx.

DEEP DISSECTION OF THE SIDE OF THE NECK.

THE OTIC GANGLION, is a small pinkish body on the deep surface of the inferior maxillary nerve, it is situated below the foramen ovale, close to the cartilagin ous portion of the eustachian tube. Sensory root is derived from Jacobson's nerv (tympanic branch of the glosso-pharyngeal) through the small superficial petros The motor root comes from the internal pterygoid nerve of the inferior maxillary division of the 5th. the sympathetetic is from the plexus on the middle meninge artery. The communications of the ganglion are as follows, four with branches of the 5th., buccal, nerve to the internal pterygoid, auriculo-temporal, recurre meningeal, the fifth communication is with the chorda tympani, the 6th. is with the Vidian, probably ending in Meckel.
ASCENDING PHARYNGEAL ARTERY arises from the external carotid, runs between the internal carotid and the pharynx, near the base of the skull it divides into pal ato-pharyngeal and meningeal branches. The latter are very small, enter the skul by the foramen lacerum medium.
TENSOR PALATIOrigin, scaphoid fossa at the root of the internal pterygoid proces outer surface of the cartilaginous portion of the Eustachian tube., the tendon winds round the hamular process to its insertion into the hard and soft palate. It is supplied by a branch from the nerve to the internal pterygoid.
SUPERIOR CONSTRICTOR OF THE PHARYNX, Origin, inner surface of lower third of the internal pterygoid plate, hamular proce.s of sphenoid, from the pterygo-maxillar ligament, the inner surface of the lower jaw above the posterior extremity of th mylo-hyoid ridge and from the side of the soft palate above and the side of the tongue below. Insertion, the pharngeal spine and the median raphe of the pharynx
GLOSSO-PHARYNGEAL NERVE, leaves the jugular foramen in front of the pneumogastri arches forward over the internal carotid artery to the stylo-pharyngeus muscle . Will be seen later.
INTERNAL CAROTID ARTERY commences at the bifurcation of the common carotid at th level of the upper border of the thyroid gartilage. Its relation to the externa has been already given. The artery exists in four regions, cervical, petrous, cavernous and cerebral. The cervical part gives off no branches and lies external to the external carotid artery.. The cervical portion has lying anterior to it the 5 structures, the stylo-hyoid and glossus, the posterior belly of the digastric; the hypoglossal, glossopharyngeal and pharyngeal branches of the vagus; the occipital, external carotid , and a small meningeal arter... Posteriorly it rests upon the rectus capitis anticus major, the sympathetic nerve, the superior laryngeal nerve. Externally are the internal jugular vein, and the vagus, Inter-

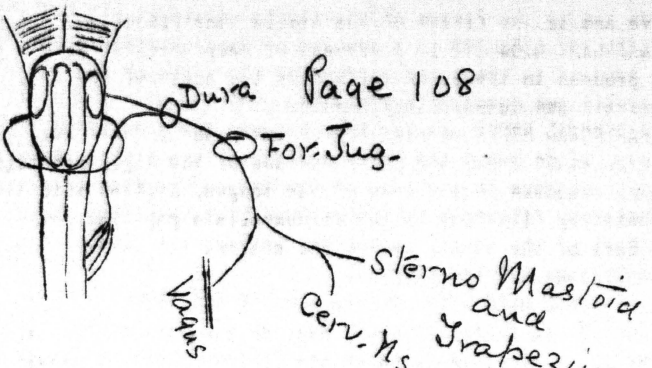

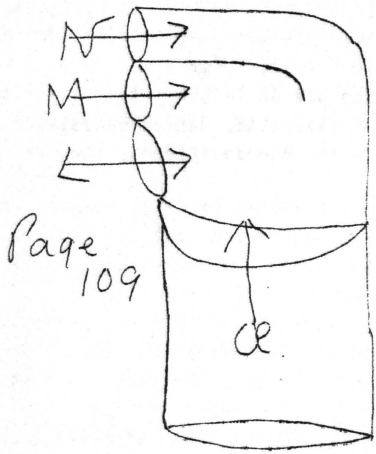

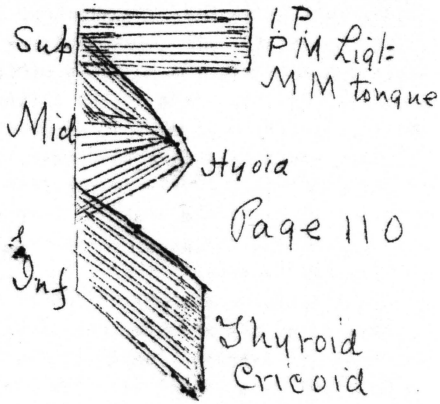

Sup
Mid Longus Colli.
Inf. Page 109

nally the pharynx, tonsil and ascending pharyngeal artery. The petrous portion of the artery passes through the petrous portion of thne temporal bone and gives off a tympanic branch, this portion having upon it a sigmoid curve. The cavernous portion lies in the cavernous sinus and is also sigmoid, gives off three sets of branches, two ~~large~~ small and one ~~small~~ large. The small are meningeal and recaptacular, the large is the ophthalmic. The artery then pierces the dura and has been seen in the interior of the skull, lies in relation to the base of the brain and divides into four terminal branches, the anterior and middle cerebral, the posterior communicating and the anterior choroidal. .

THE INTERNAL JUGULAR VEIN, is formed by the junction of the lateral and the inferior petrosal sinuses commences outside the skull at the posterior part of the jugular foramen in a dilatation called the sinus or bulb, the interval between the two formative vessels being occupied by the 9th. , 10th., and 11th. nerves. It at first lies behind the internal carotid artery in front of the rectus capitis lateralis, with these nerves and the 12th. between, then it descends on the outer side of the internal and common carotid arteries in the sheath. It receives no branch above the hyoid but below that bone receives the lingual, facial, pharyngeal and superior and middle thyroid veins, finally it joins the subclavian vein behind the inner end of the clavicle to form the innominate vein..

THE VAGUS leaves the skull at the jugular foramen, in front and to the inner side side of the jugular vein and in the same dural sheath as the spinal accessory. In In the neck it lies between the internal jugular vein and the internal carotid artery, then between that vein and the common carotid artery.. In the lower half od the neck it lies in the carotid sheath. In or near the jugular foramen there are two ganglia on the nerve, the upper is the smaller, it is called the ganglion of the root and gives branches of communication to other nerves and one of distribution, Arnold's nerve or the auricular branch, which passes through Arnold's foramen, traverses the substance of the petrous bone where it communicates with other nerves, leaves the temporal bone through auricular fissure and is distributed to the skin at the back of the pinna. The lower ganglion or ganglion of the trunk, gives off branches of communication to other nerves and a pharyngeal branch which passes to the pharyngeal plexus. Three cardiac nerves are given off by the vagus in the neck, their distribution was seen in relation with the superficial and deep cardiac plexuses. The superior laryngeal branchis given off close to the pharyngeal branchand passes inward and downwardsbehind both carotids to the thyro-hyoid membrane supplying sensation to the larynx. The superior laryngeal gives off two branches an external laryngeal which supplies the crico-thyroid and the inferior constrictor and a branch which sometimes supplies half the arytenoideus. .

THE SPINAL ACCESSORY NERVE, arises in two parts, spinal and medullary. The latter arises from a nucleus of gray matter in the floor of the 4th. ventricle, the spinal portion arises as low down in the neck as the 5th. cervical vertebra and can there be found to be connected with the gray matter of the cord between the cornua. The medullary portion appears on the surface of the medulla between the olivary and restiform bodies and joins with the spinal portion within the dura. the spinal portion having ascended through the foramen magnum to meet it. They become blended and as one nerve pierce the skull, leaving the skull by way of the jugular foramen. The nerve has hardly left the skull ere it divides into two parts, one joins the vagus and is called the pars accessorius, the other

pierces the sterno mastoid at an acute angle and crosses the posterior triangle of the neck obliquely, where it communicates with the cervical plexus and ends in the trapezius as already seen.

THE HYPOGLOSSAL NERVE emerges at the anterior condyloid foramen, comes down and forward between the vagus and the spinal accessory, being closely united with the ganglion of the trunk of the vagus. It passes out between the internal carotid and the internal jugular vein, crosses both internal and external carotidarteries. It has branches of communication with the vagus, superior cervical ganglion and the loop between the first and second cervical nerves, gives a recurrent branch to the dura through the anterior condyloid foramen.

RECTUS CAPITIS LATERALIS, Origin, upper surface of transverse process of atlas, Insertion, under surface of jugular process of occipital. Nerve, first cervical.

FIRST CERVICAL NERVE has a small anterior division which leaves the posterior on the posterior arch of the atlas. It gives branches to the rectus lateralis, the vagus and the hypoglossal and to the superior ganglion of the sympathetic. It forms a loop with the second nerve and gives twigs to the anterior recti.

SUPERIOR CERVICAL GANGLION, is a fusiform enlargement of the sympathetic nerve about an inch long, behind the internal carotid artery on the rectus capitis anticus major opposite the 1st., 2nd. and 3rd. cervical vertebrae. Its distribution has been shewn in a diagram.

THE PREVERTEBRAL REGION.

This region consists of bones, ligaments, vessels, nerves and muscles. The bones are the occipital and the ten vertebrae from the 1st. cervical to the 3rd. dorsal, also the first and second pairs of ribs. The ligaments are those uniting these bones, the vessels are chiefly the vertebral and the ascending cervical. The nerves are the cervical plexus the muscles are as follows,

SCALENUS ANTICUS, Origin, anterior transverse tubercles of the 3rd., 4th., 5th. and 6th. cervical vertebrae, Insertion, scalene tubercle of the first rib. Nerve a branch of the cervical plexus.

SCALENUS MEDIUS, Posterior transverse tubercles of the cervical vertebrae except the 7th., Insertion, first rib external to the supclavian artery. Nerve, same.

SCALENUS POSTICUS, is really a part of the last muscle which is inserted into the second rib.

RECTUS CAPITIS ANTICUS MAJOR, Origin, same as the scalenus anticus, Insertion, Occiput, Nerve, same as last.

RECTUS CAPITIS ANTICUS MINOR, lies under cover of the last muscle and stretches from the atlas to the occiput.

RECTUS CAPITIS LATERALIS Origin, transverse process of atlas, Insertion, occiput Nerve, same as all the others.

LONGUS COLLI is built upon the plan of being divisible into three parts of which the superior and inferior are oblique, the middle is vertical, it extends from the atlas to the 3rd. dorsal and is attached to the bodies and transverse processes of the vertebrae.

THE PHARYNX IS a fibrous bag which is slung on to the base of the skull, especially the occipital bone. Anteriorly it has the openings of the nostrils and the mouth, below the openings of the oesophagus and the larynx. It is really divided into two parts by a membranous partition (muscular) called the velum palati the part above which is called the naso-pharynx while that below is the pharynx

proper. In the nasopharynx are the openings of the Eustachian tubes. The wall of t'e pharynx is strengthened by muscles as follows.

SUPERIOR CONSTRICTOR, Origin, internal pterygoid plate, pterygo-maxillary ligament, mucous membrane of the mouth, side of tne tongue, Insertion, mesial raphe of pharynx posteriorly.

MIDDLE CONSTRICTOR, triangular in shape, overlaps the last, Origin, retrocession of tne hyoid bone, Insertion, mesial raphe.

INFERIOR CONSTRICOR, a very oblique muscle which overlaps the last, Origin, thyroid and cricoid cartilages, Insertion, mesial raphe.

STYLO PHARYNGEUS, Origin, base of styloid, Insertion, mesial raphe.

SALPINGO PHARYNGEUS, a few fibres arising from the Eustachian tube, inserted into the mesial raphe. All these muscles are supplied by the pharyngeal plexus which is formed by tne vagus, spinal accessory, glossopharyngeal and sympathetic. It lies in relation to the internal carotid artery..

THE INTERIOR OF THE PHARYNX HAS SEVEN OPENINGS, as follows in order from above down, tne two posterior nares separated by the vomer, the two Eustachian tubes, the Isthmus faucium or opening from the mouth bounded above by the soft palate below by the tongue, laterally by the anterior pillars of the fauces, the superior aperture of the larynx and the commencement of the oesophagus..

THE EUSTACHIAN TUBE is one inch and a half long, it passes from the cavity of the tympanum downward, forward and inward to the naso-pharynx, part of it is formed of bone, the petrous portion of the temporal, but the major part is formed on elastic cartilage, but even this is not complete the interspace being filled in with muscle. It is lined with ciliated epithelium and is only open during deglutition. Its mouth is trumpet shaped.

THE MOUTH has a muscular floor formed by the mylo-hyoids and upon this rests the tongue, the walls are formed by the cheeks, jaws and teeth. In front is the oral fissure and posteriorly the fauces, the roof is called the soft palate. T,e bony roof is called tne hard palate, but this is everywhere covered by mucous membrane which behind is strengthened by muscles and projects behind its free border as the velum palati. The tongue is formed of muscle and is everywhere covered by mucous memrane, o its under surface we find squamous epithelium while on its upper surface the epithelium is modified into papillae.. On the posterior 1-3 of the tongue are found the circumvallate papillae, supplied by the glosso-pharyngeal, and also the foramen coecum, the remains of a duct which once extended down to the thyroid gland. All round the sides and at the tip of the tongue are found filiform papillae, as also on the dorsum, while on the tip and sides are the fungiform supplied by the chorda tympani. .

LEVATOR PALATI, Origin, apex of petrous bone and the Eustachian tube, Insertion raphe of the velum, Nerve, stated by some to be from Meckell, by others to be the glossopharyngeal..

TENSOR PALATI, Origin, scaphoid fossa, Insertion, Raphe, Nerve, otic ganglion. This muscle works at a right angle round the hamular process which is coated with cartilage and provided with a bursa.

LEVATOR UVULAE, Origin, posterior palatal spine, Nerve, glossopharyngeal.

THE FAUCES are the gate of the throat and show three things, first, the tonsil which has a pillar (a fold of mucous membrane enclosing a muscle) on either side. The anterior pillar encloses the palato glossus, the posterior the palato

pharyngeus. Both arise from the soft palate and are inserted the one into the tongue the other into the pharynx. The tonsil is made up of adenoid tissue and resembles in structure a Peyer's patch in the intestine, it has a capsule and is broken up by trabeculae, it does not secrete and and is covered by a mucous membrane which is pitted. It is supplied by the facial and ascending pharyngeal. Round the back of the pharynx is a little ring of masses of adenoid tissue lying between the tonsils.

THE SUPERIOR MAXILLARY NERVE or second division of the 5th., leaves the cranium at the foramen rotundum, having crossed the upper extremity of the spheno-maxillary fossa traverses the infra-orbital canal and appears on the face at the infra-orbital foramen.. It gives off the following branches. A small recurrent filament to the dura mater close to its orgin from the Gasserian ganglion. The tempero-malar branch enters the orbit by the spheno-maxillary fissure, pierces the orbitalis and divides into two branches temporal and malar which have been already described. Spheno-palatine branches descend into the spheno-maxillary fossa to Meckel's ganglion and become continuous with the descending palatine nerves. Posterior dental branches supply the gums and adjacent portions of the cheek, then enter the canals on the posterior aspect of the upper jaw to supply the molar and bicuspid teeth and communicate with the anterior dental nerve. The anterior dental branch arises in the infra-orbital canal, descends in the wall of the antrum to the incisor and canine teeth, gives off a small nasal branch. . The facial branches have already been mentioned.

INFRA-ORBITAL ARTERY accompanies the superior maxillary nerve, it is a terminal branch of the internal maxillary, gives an orbital branch to anastomose with the ophthalmic and an anterior dental, ends like the nerve in twigs distributed to in the same way. The vein communicates with the facial and ends in the internal maxillary vein.

THE NOSE or NASAL CAVITY. is a quadrilateral cavity having a roof, floor, lateral walls also anterior and posterior orifices. The outer wall is very rough and irregular because of the openings of many foramina and also because there are three turbinated bones slung onto it. The anterior nares is pear-shaped , the posterior is quadrangular and shows the septum. The septum of the nose is partly bone and partly cartilage, is very commonly bent to one side. A meatus of the nose is defined as a bony passage formed by the wall of the nose and a turbinated bone, of them we have three, superior, middle and inferior. The superior is the shortest, most posterior and most oblique, the inferior is the . lowest, longest and most horizontal, the middle meatus bearing an intermediate position in all respects. Into the superior meatus open the sphenoidal sinus and superior ethmoidal sinus. Into the middle meatus open the anterior ethmoidal cells, the antrum of Highmore and the frontal cells through a little opening the infundibulum. Into the inferior meatus opens the nasal duct.

THE OLFACTORY NERVE is the special nerve of smell, and its branches whichare derived from the olfactory bulb reach the nasal cavity by piercing the cribriform plate of the ethmoid bone, on which the bulb lies, they are distributed on the olfactory mucous mebrane, the superior and upper half of the middle turbinated bones, and the upper third of the septum.

SPHENO-PALATINE or MECKEL'S GANGLION, is a minute pinkish body situated in the spheno-maxillary fossa opposite the spheno-palatine foramen. The spheno-maxillary fossa has in it two fissures and five foramina, and in every one of these

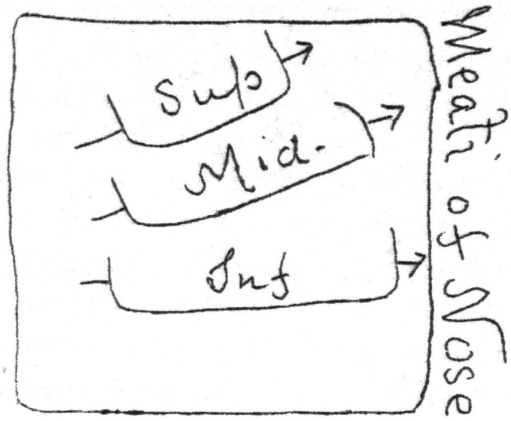

Page 111



Page 114

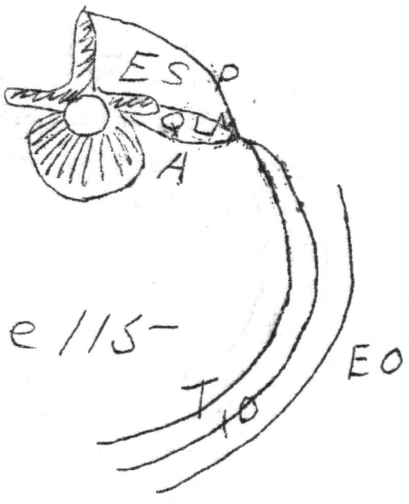

Page 115-

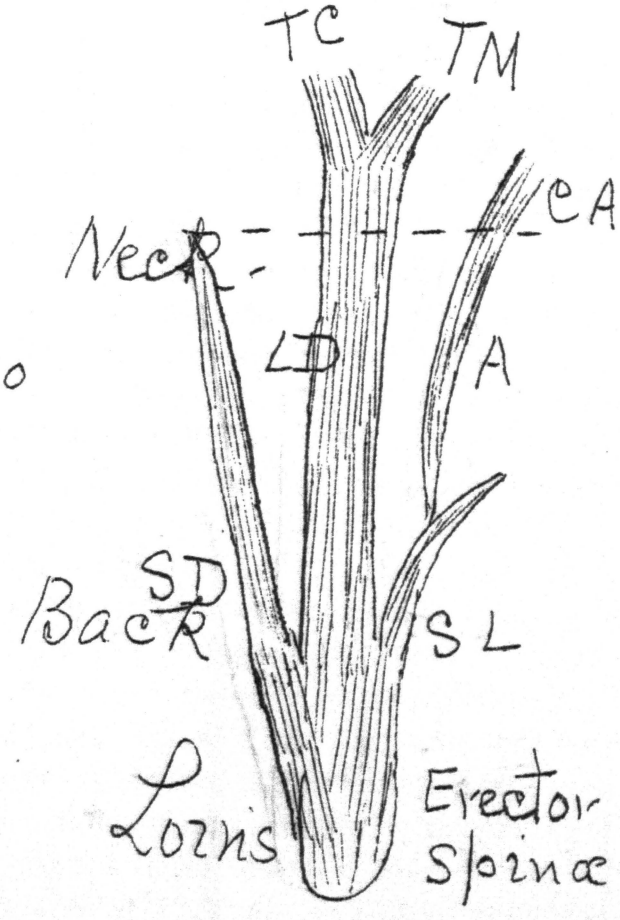

Page 115-

except the foramen rotundum t:ere is an artery. The ganglion is slugg to the under surface of t.e superior maxillary nerve from which it derives its sensory root, the motor root is from the facial through the vidian, and its sympathetic root is also from the vidian. The branches of distribution are divided into four sets, Ascending (orbital to the periosteum) Posterior, (pharyngeal to the pharyngeal plexus) Descending, (largest of all, in three sets, Posterior palatine, External palatine and Anterior palatine) Internal, (two in number, enter the the cavity of the nose through the spheno-palatine foramen, the smaller supplies the mucous membrane of the nose and is called the nasal, the larger having crossed the roof of the nose passes downward and forward on its septum and pierces the anterior palat.ne foramen. Meckel's ganglion is laregly trophic. The arteries given off in the spheno-maxillary fossa are branches from the internal maxillary, they are as follows with the foramina through which they pass. Descending palatine, goes through the posterior palatine canal, with the great palatine nerve. Vidian artery, accompanies the vidial nerve through the vidian canal. Pterygo-palatine artery runs back through the pterygo-palatine canal and the superior nasal or spheno-palatine artery enters the nose by the spheno-palatine foramen.

THE LARYNX, EYE, and EAR will not be described here, their description can be best obtained either in a systematic lecture with the model or from works on anatomy of a more pretentious nature than this.

THE JOINTS OF THE NECK are the atlo-axoid, Occipito-atloid and Occipito-axoid, The Atlo-axoid joint is found between the atlas and the axis, consists of two synovial membranes surrounded by capsules. The anterior atlo-axoid ligament is in two parts, a superficial cord and a deep membrane. The posterior atlo-axoid ligament is a broad membrane and a transverse ligament. Between the atlas and the axis we have four synovial membranes, two for the articular processes and two for the odontoid. The occipito atloid joint consists of two capsules uniting the articular processes with the condyles. The anterior occipito-atloid is a superficial cord and a deep membrane, the posterior occipito-atloid is a a broad membrane which is always pierced by the vertebral artery on its way to the brain.. A lateral ligament extends from the transverse process to the jugular process. This joint has two synovial membranes. The occipito axoid joint is a name given to a few ligaments which hold the odontoid to the skull, they are two check ligaments and one suspensory.

Here follows now a brief description of the 12 cranial nerves, thus arranged, Number, Name, point of superficial origin, point of emergence from the dura mater, bony foramen through which it escapes from the skull and its distribution.

1, Olfactory, Supl. origin, is found at the base of the brain as olfactory bulb, olfactory tract and olfactory roots. The roots are three in number and arise from the under surface of the frontal lobe. Dura mater, from the under surface of the bulb are given off fine nerves of smell, they pierce the dura over the cribriform plate of the ethmoid. Bony foramina are the foramina in the cribriform plate. Distribution, the nerves supply the mucous membrane of the upper two thirds of the nose ending in fine hair cells called olfactory cells.

2, Optic, Supl. origin, at the base of the brain are seen the nerve, the optic commissure, the optic tract. This last can be traced backward and outward, crossing the crus cerebri and is found to end deeply in two rounded knobs call-

ed the corpora geniculata, these are connected with the corpora quadrigemina, the occipital lobes and certain motor centers in the brain. Duha mater, over optic foramen, lying over the ophthalmic artery. Bony foramen, Optic. Distribution, having reached the eyeball with which it is apparently continuous, it pierces the sclerotic in a great many bundles called lamina cribrosa, then becomes expanded into a fine membrane, the retina.

3, Motor oculi. Supl. origin, internal to crus, in pront of pons. Dura mater, one-fourth inch external to ~~posterior~~ external clinoid process, and slightly in front of it. Bony foramen, Foramen lacerum anterius. Distribution, entering the orbit between the two heads of the rectus(external) it supplies all the muscles of the orbit except three, superior oblique, external rectus and orbitalis. Within the eyeball it supplies the dilator pupillae.

4, Trochlear. Supl. origin, in front of pons but external to osus upon which it lies. Bony foramen, foramen lacerum anterius. Distribution, supplies superior oblique on its orbital surface. (See NOTE with 5th. nerve)

5, Trifacial. Supl. origin, side of pons, divides into two parts, anterior is small, motor, posterior is large, sensory. Dura mater, (NOTE, IMPORTANT) the relation of the 4th. nerve to the dura was omitted, it is now supplied. The 4th nerve lies in a crest of dura mater which, passing backward from the posterior clinoid process, becomes the free edge of the tentorium cerebelli. About three quarters of an inch behind and external to the posterior clinoid process. The relation ofdura mater to the 5th. nerve is that the nerve pierces the dura about quarter of an inch directly below the last, under cover of the tentorium. Bony foramen, Foramen lacerum anterius, foramen rotundum and foramen ovale. Distribution, the first division is called the ophthalmic, runs along the outer wall of the cavernous sinus, enters the orbit through the foramen lacerum anterius and while supplying parts of the eyeball, mainly supplies the skin of the forehead, eyelid nose and the mucous membrane of the nose. The 2nd. division is called the superior maxillary, supplies palate, upper teeth and skin of the face the lower eyelid and the malar region. The 3rd. division, or inferior maxillary supplies the muscles of mastication, the lower teeth and sensation to the anterior two-thirds of the tongue, also the cheek and part of the face.

6, Abducens, Supl. origin, between the pons and medulla, lying on the pons. Dura mater, three-quarters of an inch directly behind the posterior clinoid process, appears to come out of basisphenoid. Bony foramen, foramen lacerum anterius. Distribution, Runs along cavernous sinus on the internal carotid artery, enters the orbit between the two heads of the external rectus and supplies that muscle

7, Facial. Supl. origin, between pons, cerebellum and olive. Dura mater, over the internal auditory meatus, immediately below the tentirium. Bony foramen, Passing down the internal auditory meatus, it leaves it near its end, and then passing along a bony canal, the acqueductus fallopii it appears at the base of the skull at the stylo-mastoid foramen. Distribution, supplies all the muscles of expression. Parotid salivation, supplies the stapedius muscle and influences the muscles of the palate. Supplies also the anterior two-thirds of the tongue with taste.

8. Auditory, same as last but just below it (supl. origin) Dura mater, same as the last. Bony foramen, internal auditory meatus, Distribution, internal ear cochlea, labyrinth.

9, Glossopharyngeal, Supl. origin, side of the medulla between the olive and restiform. Dura mater, almost half an inch below the last. Bony foramen, Jugular. Distribution, supplies posterior third of tongue with sense and special sense parotid gland, and is sensory to the tympanum and motor to the stylo-pharyngeus ? and in such case is a nerve of deglutition.

10, Pneumogastric or vagus. Supl. origin, same as last but below it. Bony foramen, Jugular. Distribution, found in neck, thorax and abdomen. In neck supplies pharynx, larynx, heart and back of pinna. In the thorax supplies the oesophagus and lungs and sends motor fibres to the larynx. In the abdomen supplies stomach, liver, spleen etc.

11th. Spinal accessory, Supl. origin, in two parts, first medullary same as last nerve but below it, second, spinal from the side of the cord as low down as the 5th. cervical. Dura mater, same as last, Bony foramen, Jugular. Distribution, probably supplies all the motor fibres to the vagus and supplies two muscles, sterno-mastoid and trapezius.

12th. Hypoglossal, Supl. orgin, side of medulla between olive and pyramid, (ant.) in two parts Dura mater, half an inch below last in two parts. Bony foramen, Anterior condyloid. Distrib tion motor to extrinsic and intrinsic muscles of tongue, also by the descendens hypoglossi branch it supplies the omo-hyoid, sterno-hyoid and sterno-thyroid, also the stylo-hyoid.

DISSECTION OF THE BACK OF THE NECK.

This may be done at any time, the muscles of the back of the neck not having been touched. An incision is made from the external occipital protuberance outward to the extremity of the superior curved line, another is made from the external occipital protuberance to the spine of the 7th. cervical vertebra, the extremities of the two being then connected and the flap of skin removed we come upon the great occipital, small occipital, 3rd. cervical and great auricular nerves, as also the posterior jugular vein. The great occipital nerve is the posterior division of the 2nd. cervical, the small occipital is a branch of the cervical plexus, anterior division. Reflect now the superficial fascia, fascia lata and the following muscles. Trapezius, already described in the arm, the o SPLENIUS, so called because of its strap like appearance, Origin, upper dorsal spines, spine of the 7th. cervical and ligamentum nuchae. As this muscle passes up it divides into two parts, one the capitis passing to the skull, the other the colli passing to the cervical transverse processes. Nerve, posterior cervical nerves.

COMPLEXUs or biventer cervicis, is pierced by the great occipital nerve. Origin transverse processes of the upper dorsals and th 7th. cervical, also the ligamentum nuchae. Insertion, occiput between the curved lines. On reflecting this muscle there is exposed the

SUBOCCIPITAL TRIANGLE. This is a triange at the base of the skull, the floor is formed by bones and ligaments. Bones, occipital, atlas and axis. Ligaments, the posterior ligaments. Contents, the vertebral artery on its way to the brain, and the suboccipital nerve, the posterior division of of the first cervical nerve which hooks round the artery and supplies the muscles which bound the space.

THE MUSCLES OF THE BACK.

are arranged in five layers, the first layer comprises the trapezius and latissimus dorsi-which have been seen together with those of the second layer, (the

levator anguli scapulae, and rhomboideus major and minor) which have also been described. The Third layer includes the splenius, the serratus posticus superior (a muscle of forced inspiration, passing from the spines of vertebrae above to the near the angles of ribs below), the serratus posticus inferior (a muscle of forced expiration) whose origin is from the lumbar fascia and whose insertion is into ribs above. Fourth layer, comprises the erector spinae with its divesions and the complexus. and the Fifth layer consists of many muscles which are divided into two groups, long and short muscles. First let us see the VERTEBRAL FASCIA, this is a sheet of fascia lata found in the dorsal region which extends from the spines of the vertebrae to near the angles of the ribs and binds down the 2nd. and 3rd. layers of muscles. On tracing this fascia up into the neck it is found to become continuous with the cervical fascia, on tracing it down it is found to become continuous with the lumbar fascia.

LUMBAR FASCIA is made up of fascia lata and is very strong and thick. Below it is attached to the sacrum, ilium and coccyx, above it is lost in the lower part of the dorsal region where it becomes continuous with the vertebral fascia. It is split into three laminae A posterior attached to the spines, a middle attached to the transverse processes and an anterior attached to the roots of the transverse processes in front. There three laminae then blend together externally and from this blending the internal oblique and the transversalis take their origin.. The external oblique has nothing to do with the lumbar fascia. Thus the lumbar fascia forms two compartments along side of the lumbar spinal column. one of these contains the erector spinae, the other the quadratus lumborum. Of the two serrati muscles the superior has nothing to do with the vertebral fascia, but the inferior is closely adherent to it.

THE ERECTOR SPINAE is a large muscular mass arising from the sacrum, ilium coccyx and their ligaments. This mass passes upwards into the back in the lower part of which it divides into three great columns. The internal is called the spinalis dorsi, the middle is called the longissimus dorsi while the external is called the sacro-lumbalis. The spinalis dorsi lies against the vertebral column and does not pass into the neck. The longissimus dorsi covers the transverse and articular processes and passing into the neck there splits into two parts, one of which goes to the mastoid process and is called the trachelo-mastoid, the other goes to the vertebrae and is called the transversus cervicis. The sacro-lumbalis lies just internal to the angles of the ribs and does not pass into the neck, it ends in the upper back in a fine series of tendons , on their inner aspect however these become re-inforced by a new muscle, the accessorius, which does pass into the neck and becomes attached to the vertebrae under the name of the cervicalis ascendens. The 5th. layer of the muscles of the back consists of many muscles which are divided into two groups, long and short. The long muscles comprise the multifidus spinae and the semispinalis, these last end above at the spine of the axis. The short include the levatores costarum, little triangular muscles of inspiration, arising from a transverse process above and inserted into a rib below, near its angle. It also includes the rotatores dorsi, the interspinales and the intertransversales which are, as a rule, double in the neck.

DISSECTIONS IN THE HEAD AND NECK.

SUPERFICIAL DISSECTION OF THE ORBIT, open the skull and remove the brain, stri

off the dura mater from the anterior cerebral fossa, saw a wedge out of this fossa, broad at its base, the apex of which is at the optic foramen, and throw it forward, reflect the periosteum of the orbit.

DISSECTION FOR THE LENTICULAR GANGLION, proceed as before, then reflect the frontal nerve, supra-orbital vessels, levator palpebrae and the superior rectus. Find the nasal nerve where it crosses the optic and trace from it a branch which runs along the outer side of the orbit, this leads you to the ganglion.

DISSECTION FOR INFERIOR RECUS, having got to the level of the optic nerve divide it and pull the eyeball well forward.

DISSECTION FOR INFERIOR OBLQUE, cut through lower eyelid from the face, the muscle will be found in the loose cellular tissue.

DISSECTION TO EXPOSE SUPERIOR THYROID ARTERY, pull out the sterno-mastoid and reflect the sterno-tyoid and thyroid and the omo-hyoid. (of course the roof of the anterior triangle must first be removed).

DISSECTION FOR LINGUAL ARTERY. Expose the anterior triangle by reflecting the structures forming the roof, find the great cornu of the hyoid bone which is the guide to the vessel, the artery lying a little above it. Reflect the digastric and stylo-hyoid, the myo-tyoid and the structures upon it, the hyo-glossus and the structures upon it, then is the artery exposed.

DISSECTION TO EXPOSE 12th. NERVE, reflect the structures (5) from the anterior triangle, pull back the sterno-mastoid, reflect the digastric and stylo-hyoid, reflect the mylo-hyoid and the structures on it, cut away the occipital artery.

DISSECTION FOR THE 11th. Nerve, reflect the five superficial structures from the anterior triangle, expose the posterior triangle, cut out the nerve from the substance of the sterno-mastoid, pull the trapezius well back.

DISSECTION FOR THE 9th. NERVE, reflect the five superficial structures from the anterior triangle expose the submaxillary triangle, saw the jaw at the symphysis and snip through the neck and reflect the jaw upward. Reflect the styloid process with its muscles, reflect the posterior belly of the digastric, the mylo-hyoid and the structures upon it, the external carotid and its branches.

DISSECTION FOR THE OTIC GANGLION, saw the head and neck in the mesial antero-posterior plane, strip off the mucous membrane from the posterior third of the mouth and thereby expose the internal pterygoid muscle, dissect that muscle away away piecemeal until you find in its substance its nerve of supply, on tracing this up to its connection with the inferior maxillary nerve the ganglion is found.

DISSECTION TO EXPOSE SUBMAXILLARY GANGLION. Reflect the roof of the anterior triangle of the neck, saw through the mandible in the middle line and turn it up, reflect the mylo-hyoid and the structures upon it.

DISSECTION FOR THE INFERIOR MAXILLARY NERVE, open the skull and remove its contents, open orbit and remove its contents, two saw-cuts are then to be made one vertical into the foramen rotundum from the side of the skull and a horizontal one forward below so as to cut away the outer wall of the orbit, the infraorbital canal must be chiselled open and the two muscles on the face reflected..

DISSECTION FOR MECKEL'S GANGLION. Make a sagittal mesial saw-cut through the head, not exactly mesial, a trifle to one side, take the half which does not have the nasal septum, strip off the mucous membrane from the posterior third of the nose and chisel away the vertical plate of the palate bone

END OF THE HEAD AND NECK

THE BRAIN
AND
SPINAL CORD.



Endothelioid Plate

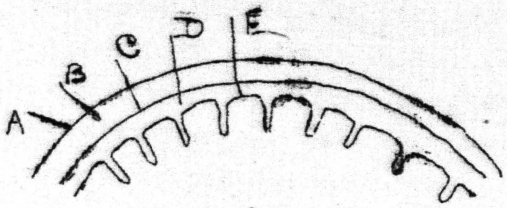

A = Dura Mater
B = Sub-dural space
C = Arachnoid Mater
D = Sub-arachnoid space
E = Pia Mater

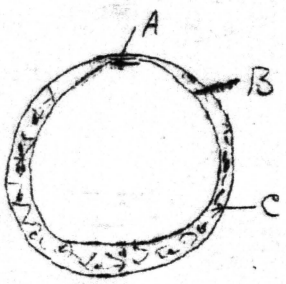

A = Posterior Common Ligament
B = Dura mater
C = Structures between Dura and bone in spinal canal

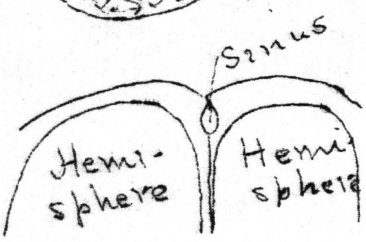



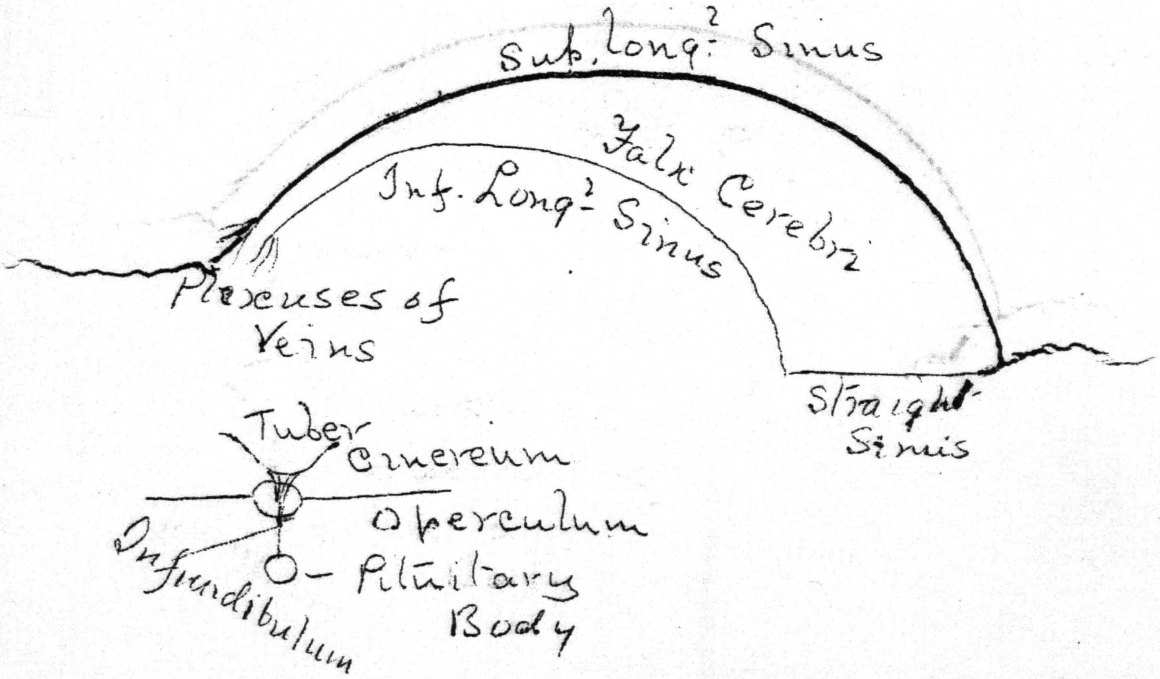

THE BRAIN AND SPINAL CORD.

The cerebro-spinal nervous system is concerned in various processes, thought, volition, sensation, motion, nutrition and in various reflex phenomena, the sytem comprises a central part composed of the brain and spinal cord, and a peripheral part which includes the nerves going to various parts of the body. The nerves of this system are all white nerves, as distinguished from those of the sympathecetic nervous system which is made up of ganglia and grey nerves.

MENINGES, the brain and spinal cord are enclosed within three membranes which are called the meninges, these are the dura mater, arachnoid and pia mater, to each belong certain functions. The DURA MATER or pachymeninx, is the most external of the meninges. It is a dense, thick and almost inelastic fibrous membrane, consists mostly of white fibrous tissue with a very small proportion of elastic fibres. Upon both of its surfaces are great flat cells called endothelioid plates Between the dura mater and the arachnoid is is a space, the subdural space, in most parts this is a mere slit and contains a small amount of lymph fluid. Between the pia mater and the arachnoid is another space, the subarachnoid space. The dura mater of the brain differs from that of the cord in three points, The cranial dura mater forms the internal periosteum of the skull, being specially attached along the sutures and round the margins of the foramina. The spinal portion of the dura nearly fills the canal but does not form its periosteum, being separated from it by areolar tissue, fat and veins. The spinal dura is attached at one part, along the posterior common ligament.

The cranial dura has venous sinuses in its substance, these are not veins inasmuch as they have no proper venous coats. They are formed by a splitting of the dura mater, lined by a layer of endothelium which is continuous with the intima of the veins. There are 15 of these sinuses as already described. The spinal dura has no sinuses but the veins lie outside of it. Further, the cranial dura sends in partitions which partially separate off portions of the brain, and no doubt afford a scaffolding tending to protect the brain from injury or shock. There are four of these partitions, the falx cerebri, the falx cerebelli, tentorium cerebelli and the operculum for the pituitary body. The falx cerebri is sickle-shaped and partially separates the two hemispheres of the brain, it is surmounted by the superiorlongitudinal sinus, at its posterior end lies the straight sinus, while along its lower border runs the inferi or longitudinal sinus.. At the narrow anterior end is a plexus of veins connected with the nose This falx cerebri lies nearer the corpus callosum behind and can never be said to quite touch it. The tentorium cerebelli is a horizontal process of dura in the form of a roof or tent for the cerebellum, it is somewhat raised in its middle. Its inner border is free and forms a shield-like opening through which passes the isthmus cerebri. Its attached border, the external, is attached to the occipital, petrous of temporal and the clinoid processes of the sphenoid bones. The falx cerebelli is very small and lies under cover of the last behind. It partially separates the hemispheres of the cerebellum and extends to the margins of the foramen magnum where it bifurcates. It contains the two occipital sinuses. The operculum for the pituitary body is a little horizontal process of the dura which covers over the pituitary fossa. It has a hole in its middle and through this passes a little stalk called the infundibulum, which connects the pituitary body with the tuber cinereum, a little mass of brain substance. The

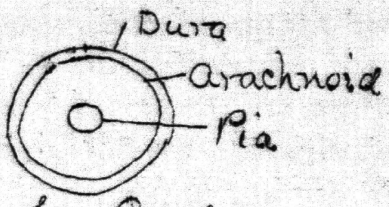

In Cord.

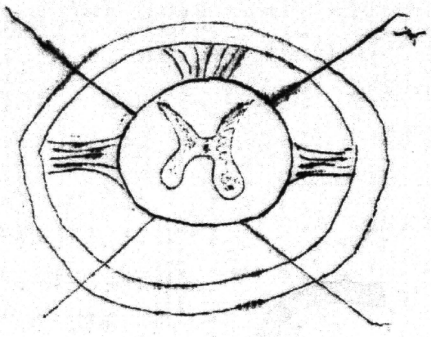

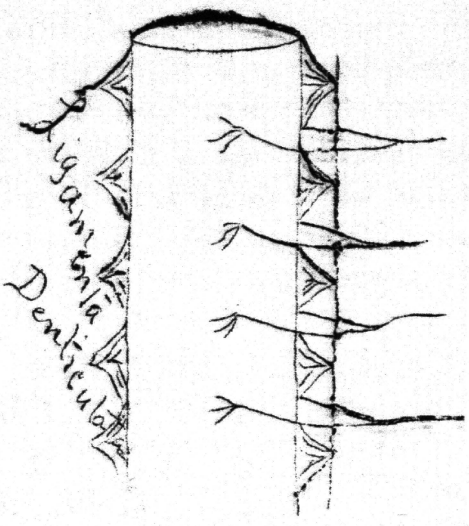



Enlargments
(See page 119)

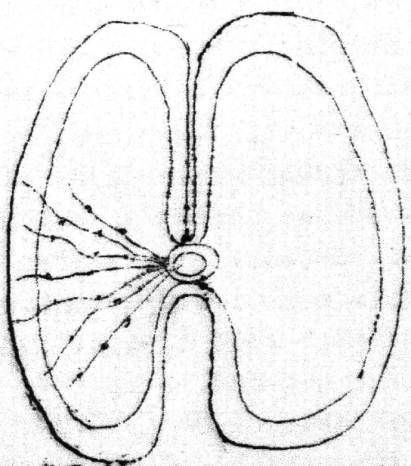

The "Cilia" according to His.

Spinal dura mater has no processes. The nerve supply of the cranial dura is mainly from the 5th., 10th. and 12th. cranial nerves and the sympathetic, the spinal is supplied by the spinal nerves and the sympathetic. The arteries for both run chiefly on the outer surface and supply not only the membrane but also the bones. The spinal dura extends from the foramen magnum to the second sacral vertebra and is sometimes called the theca vertebralis. The ARACHNOID is so called from its resemblance to a spider's web, it being a meshed membrane which lies very close to the pia mater in the brain, where, however, it does not dip into the fissures. In the cord it lies at a distance from the pia and is in special relation to the dura.. It consists of a series of delicate membranes laid one on the other, the interstices of the membrane being filled up with a fine glistening membrane composed of expanded cells. The subarachnoid space is largest in the following three regions, the interpeduncular space, at the bottom of the longitudinal fissure of the brain and in the spinal cord. The space in the brain is broken up by trabeculae called cesternae. Each trabecula is lined lined by a fine membrane, in the cord these trabeculae are practially absent, but their place is to a certain extent taken by the following structures, the septa posticum, the ligamenta denticulata and by the emergence of the nerve-roots. The subarachnoid space is everywhere continuous and it communicates with the ventricles of the brain in several regions, specially at the sides of the 4th. ventricle through the foramina of magendie.. The space contains cerebro-spinal. fluid, the function of which is to form a water-sheath for the cord and a water bed for the brain, at the same time equalising the internal and external pressure of the blood. The ligamentum denticulatum is a lateral fold which runs down either side of the cord from top to bottom. It is really derived from pia mater and presents along its free border 21 points on either side, these points are attached to the dura all the way down and they lie between the spinal nerves. They serve to fix the cord and are somewhat irregular at the lower end, they do not pierce the arachnoid but are covered by it. The first point lies between the hypoglossal nerve and the occipital artery.. The pacchionian glands are villous outgrowths of the arachnoid, in the neighborhood of the superior longitudinal sinus. They erode the bone by their presence and may even pierce it. At times they are found to project into the sinus. The PIA MATER, is a delicate fibrous vascular membrane, which covers the entire surface of the brain and spinal cord. In the brain it can be detached with a slight amount of laceration of the brain substance, but in the cord it adheres so closely that it cannot be removed without destroying the surface of the cord. On the inner surface of the pia when detached from the brain is seen a flocculent appearance, this is due to the many small blood vessels torn across in the process of removing it. The pia dips into the fissures of the brain forming double folds. In the brain this membrane passes into its interior at two parts, as the velum interpositum and as the tela choroidea inferior which passes into the 4th. ventricle. In the cord the adherent pia is sometimes spoken of as the neurilemma of the cord, it is is thicker, firmer and less vascular and dips into the anterior fissure but not not into the posterior, on the anterior surface of the cord it forms a great white line, the linea splendens. Structure of the pia, in the cord it consists of two layers, an extima which is fibrous, the fibres being mostly longitudinal

and an intima which is a fine network containing angular spaces and lined on both surfaces by endothelioid cells. These two layers are separated from each other by the blood vessels of the cord and lymphatic spaces. Pigment cells are sometimes found in the pia mater. The pia mater in the brain has no extima and therefore has its blood vessels on its surface. The last two membranes, the arachnoid and the pia mater sometimes spoken of as the leptomeninx.

THE SPINAL CORD is from one to one and a half ounces in weight, it is 18 inches long and extends from the foramen magnum to the lower border of the first lumbar vertebra, below this point the cord becomes rapidly narrowed and forms what is called the conus medullaris. At the end of this conus is a thin filament, the filum terminale. The spinal cord is a rounded, slightly flattened cylinder. It is fairly stationary but in forward flexion is always slightly raised in the canal. It is a bilateral organ whose symmetry is not always perfect, it has upon it two enlargments, a cervical which extends from the foramen magnum to the first or second dorsal vertebra and is always largest opposite the 7th. cervical, this enlargment is lateral, and a lumbar enlargment, which is from the 10th. dorsal to the 1st. lumbar, and at this enlargement the cord is nearly circular

FISSURES OF THE CORD the spinal cord has two fissures, the anterior is wide and shallow, penetrates the cord for about one-third of its extent. It contains a double fold of pia mater and this carries vessels passing to the centre of the cord. At the bottom of this fissure is the anterior commissure of the cord which is a white commissure. The posterior fissure extends to the middle of the cord, it is very narrow, at its bottom is the posterior commissure which is a grey commisaure. This fissure does not contain pia mater, but a small amount of connective tissue and some vessels. Each half of the cord shows no other fissure unless where the posterior nerve root emerges and this is sometimes called the postero-laheral fissure.

SPINAL NERVES are thirty one pairs in number, of these the following formula gives their position and relation to the cord.

C8, D12, L5, S5, Coc.1.

The upper few are horizontal, the lower become more and more oblique until at last they are quite vertical. The filum terminale lies in the midst of a great leash of nerves, the cauda equina, from which it is always recognised by its silvery hue. It extends from the conus medullaris to the second sacral where it pierces the dura and is prolonged outward to be attached to the coccyx. The part outside the dura receives a few fibres from the dura, the lowest part is often called the ligamentum centrale, the upper half of the filum contains the central canal and a small amount of grey matter, the lower half consists of fibrous tissue alone with a few vessels. From the sides of the filum terminale are usually seen three or four fibrous branches which are supposed to be rudiments of coccygeal nerves. A transverse section of the cord.

TRANSVERSE SECTION OF THE CORD shows two halves joined together by an isthmus which is made of two bands of fibres, an anterior forming the white commissure and a posterior, the grey commissure, the latter containing the central canal. Neuroglia is a delicate form of connective tissue which exists everywhere in the cord but is especially abundant on its free surface and also round the cen-

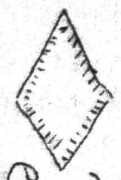



Central Canal

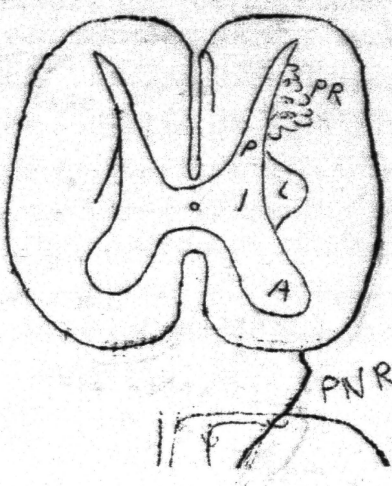

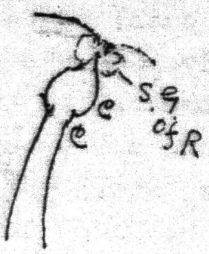

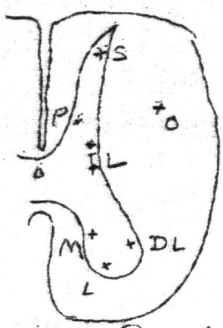

Cells in Cord

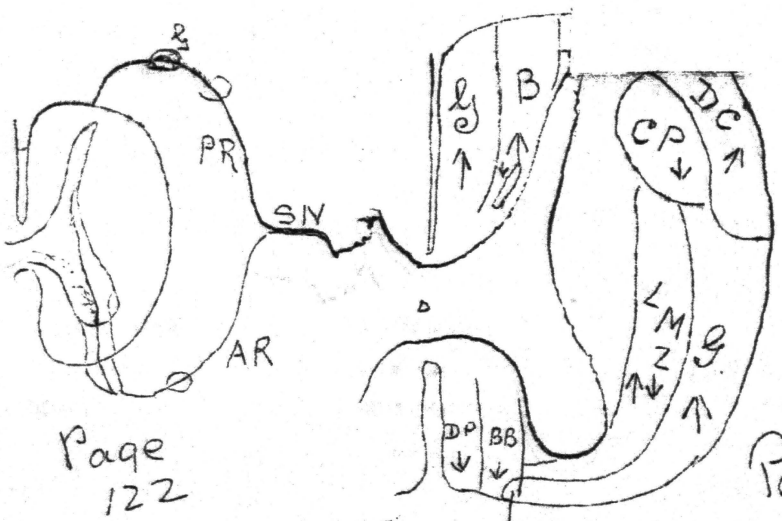

Page 122

Page 121

White Matter in Tracts

↓ descending

↑ Ascending

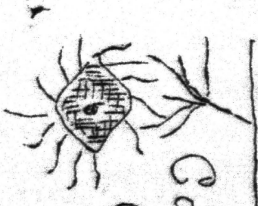

Nerve fibre

Coll aterals (Page 122)

tral canal where it constitutes the substantia gelatinosa centralis. it is easily made out in the white matter of the cord, less so in the grey where it is obscured by the nerve elemeeent. It shows four distinct elements, a homogeneous matrix which becomes granular on the addition of spirit, delicate fibrils, small branched cells and large branched cells, the cells of Deiters.

CENTRAL CANAL OF THE CORD extends the whole length of the cord, it opens above into the 4th. ventricle and in the greater part of the cord is lozenge shaped, in the lower part, however, it is T-shaped. Very rarely in the lower part of the cord this canal is ot closed but communicates with the posterior fissure. This deficiency exists in the region of an opening which persists for a long time in the foetus, called the Sinus Rhomboidalis. The canal is lined by ciliated cells in the foetus and in the child, but in the adult these are hard to make out and often the lumen of the canal is more or less completely filled with their debris. The canal contains cerebro-spinal fluid. His has shewn that the ciliated cells have not got so simple a structure as was formerly supposed but really extend as long filaments which reach the free surface of the cord. These processes he calls spongioblasts, as the cord grows they become swollen at various parts and broken up, from these the neuroglia is formed, and it is by no means improbable that the nerve cells have a similar origin.

GREY MATTER OF THE CORD never reaches the surface of the cord but is everywhere surrounded by the white matter unless it be at the bottom of the posterior fissure. The grey matter is most abundant in the lumbar enlargment of the cord and least so in the thoracic region. It increases in amount as we descend in the cord and consists of two crescents laid back to back and connected together by the grey commissure.. Each crescent shows the following parts,--. an anterior, posterior horn, intermediate grey substance, processus reticularis and a lateral horn.

THE ANTERIOR HORN, is blunt and rounded, is especially broad in the lumbar region, is everywhere traversed by nerve fibres.

POSTERIOR HORN is long and narrow although broad in the sacral region. It shows a caput, cervix and an apex. It approaches very near to the surface but is cut off from it by the tract of Lissauer. Its apex however is connected to the surface by the dipping in of the neuroglia. The substantia gelatinosa of Rolando fits like a cap on the apex of the horn and is probably largely composed of neuroglia.

PROCESSUS RETICULARIS is a mixture of white and grey matter and is best marked in the neck. The LATERAL HORN is just in front of the last and is practically found only in the upper thoracic and sacral regions. In all the other regions it is blended with the anterior.

MICROSCOPIC STRUCTURE OF THE CORD. The grey matter of the cord consists of three things, Neuroglia, multipolar cells which vary much in size and never join one another and a number of nerve fibres, white and grey in which the grey preponderate, and consists for the most part of axis cylinders alone. The nerve cells are specially found in certain parts of grey matter of the cord where they constitute the so-called columns.

COLUMNS OF GREY MATTER these are, 1, Anterior vesicular column, is found in the anterior cornu, its cells are large, motor and trophic in function, and are in three groups, a mesial, a lateral and a dorsi-lateral group. The mes-

ial set is probably connected with the muscles of the back, the lateral set with the muscles of the front and sides of the trunk and the dorsi-lateral, which are found only above and below, with the muscles of the limbs. In these columns subordinate groups exist which preside over groups of muscles. 2, Posterior vesicular column, called also the column of Clarke or the dorsal nucleus lies very far forward and is almost entirely confined to the thoracic part of the cord, especially its lower part. It probably receives the fibres of the direct cerebellar tract and its cells are sensory in function.. 3, Lateral vesicular column, is chiefly found in the dorsal region. The cells of the posterior horn are various indefinite cell-groups, some of them being quite solitary cells. Outlying cells are found in the white matter.

COMMISSURES OF THE CORD, the grey commissure contains the central canal and consists of white and grey nerve fibres and a large amount of neuroglia. The white commissure lies in front of the grey and consists of medullated nerve fibres. It is connected with the anterior columns and the anterior cornua. This commissure shows an oblique decoussation and is frequently displaced by blood-vessels passing through it to enter the grey matter.

WHITE MATTER OF THE CORD forms the cortex and consists of two things, medullated nerve fibres which vary in size and seldom shew either neurilemma or nodes of Ranvier. Between these nerve-fibres are minute processes of neuroglia. The white matter is apparently uniform and undifferentiated, in reality it is split up into a whole series of definite tracts having distinct functions and called descending or ascending according as they carry impulses to or from the brain. In the development of the cord the axis cylinders appear a considerable time before the white sheath which ultimately surrounds them. This sheath appears in different areas of the cord at different times. When the fibres undergo a peculiar form of disease they are transformed into fibrous tissue, sclerosis.

The white matter of the cord is quite artificially divided into three columns by the emergence from it of the nerve roots. Anterior, posterior and middle.

THE ANTERIOR COLUMN shows two distinct tracts, the antero-internal or direct-pyramidal tract, this is a descending tract and is therefore motor. It lessens as it descends and ends about the middle of the dorsal region. It probably decussates with its fellow throughout the whole of its length through the anterior commissure. The antero-external or basis bundle (Turner) appears to be largely concerned with the origin of the anterior nerve-roots. It extends the entire length of the cord..

MIDDLE COLUMN shows the following tracts, the comma shaped tract of Gowers, the head and body of this tract lie in the lateral column but the extremity of its tail lies in the anterior. By most this is taught as an ascending tract connected with the cerebellum. Probably in its tail there are some descending fibres from the same part of the brain. This tract is not found in the lower part of the cord. The direct cerebellar tract is an ascending tract passing upward through the pons and medulla along the inferior peduncles of the cerebellum and specially to that part of the cerebellum which is called the vermis. The Crossed pyramidal tract is a descending tract and is therefore chiefly motor, it gets smaller as it descends and in the lower cord where the last tract has disappeared it comes to the surface of the cord. It can be traced as low down as the 4th. sacral nerve. The Lateral mixed zone has a function

which is hard to determine, probably it is largely commisural, the area is divided into two parts, an anterior and posterior, he posterior being sometimes called the limiting layer.

POSTERIOR COLUMN Postero-internal tract, or column of Goll, also sometimes called the fasciculus gracilis, is ascending and sensory, it increases from below up and is best marked in the dorsal region. Postero-external tract, or column of Burdach, or fasciculus cuneatus, is ascencing and sensory. These tracts are not separated from one another in the adult although in the upper part of the cord there is a fine septum of pia mater between them. The fibres of both are derived from the posterior nerve roots. The tract of Lissauer, is a small ascending tract found between the posterior horn and the surface of the cord. It surrounds the posterior nerve root. The Comma tract is found in the upper part of the cord and lies in the center of the column of Burdach, it is a small comma-shaped tract of descending fibres.

COURSE OD THE TRACTS, the Direct and crossed pyramidal tracts can be traced to the motor area on the brain, they .re descencing tracts and are motor and trophic. Gower(s comma shaped tract is an ascending tract passing to the cerebellum. The direct cerebellar tract passes to the cerebellum as is the tract of Lissauer while the tracts of Goll and Burdach ascend to the cerebellum and cerebrum.

SPINAL NERVES AND THEIR ROOTS there are 31 pairs of spinal nerves, each has two roots which leave the cord at practically the same level. The posterior root is small, has a ganglion upon it and is sensory, the anterior root is large and motor in function. The roots pierce the dura separately and unite to form the spinal nerve outside it. Each root as it pierces the dura mater carries upon it for some little distance a prolongation of all three meninges. The orgins of the nerves from the cord are curiously related xxxxxxx to the spines of the vertebrae. The second cervical nerve corresponds with the atlas, the first dorsal nerve with the 8th. cervical vertebra, the sacral nerves correspond with the 11th. dorsal to the 1st. lumbar vertebrae. A spinal segment is a portion of the cord with a pair of nerves attached to it. The segments are quite continuous. On tracing the nerve roots into the substance of the cord they behave as follows. The anterior nerve root,-- its bundles pass in four ways, into anterior, posterior and lateral horns of grey matter and into the white matter of the opposite side forming largely the white commissure. The posterior nerve root, -- is quite single, on entering the cord it divides into two sets of fibres, a mesial, which passes up the column of Burdach toward the brain, but as it ascends its fibres sweep into the gr ey matter, a lateral set which enters the tract of Lissauer, ascends toward the brain and sends branches into the grey matter. Close examination of nerve fibres shows that (especially in main strands) the fibres do not end directly in nerve cells or centers but approach them by subsidiary branches with very complicated processes, these subsidiary branches are called collaterals.

FUNCTIONS OF THE CORD are two in number, first it is the great conductor of impulses to and from the brain. How do the impulses pass. Motor impulses travel along the same side of the cord, sensory mainly along the opposite one. Sensation of touch by Goll and Burdach, painful and vaso-motor impulses by the lateral mixed zone and also, probably, by the grey matter. The cord also

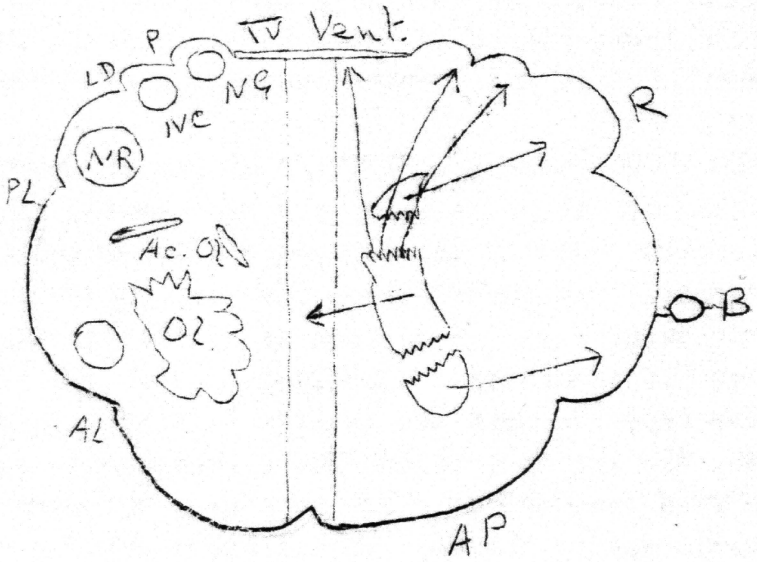

Medulla
Grey Matter

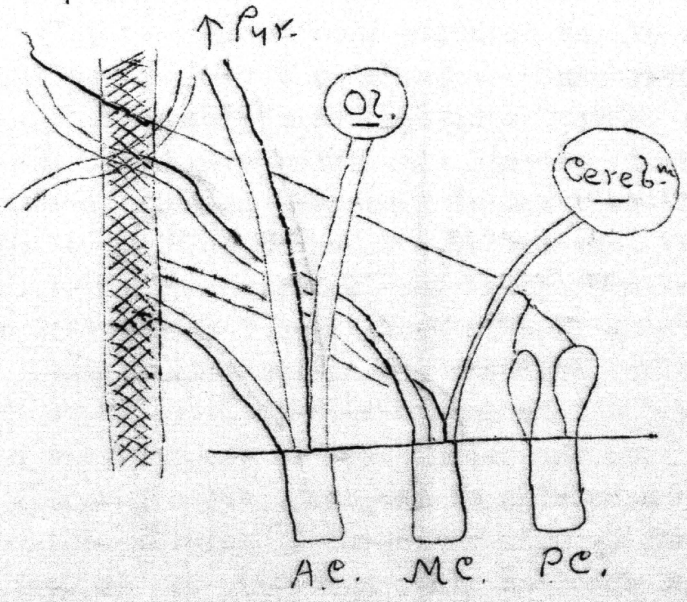

White Matter of Cord and Medulla

transmits sensations of temperature and muscular sense, the latter travelling by the columns of Goll and Burdach. The cord is , in the second place, the seat of inoepencent centers, such as vaso-motor, trophic, secretory, co-ordination of muscular movement, inhibition, and contains special centers formicturition, defecation, erection of the penis, etc.

DEVELOPMENT OF THE CORD. The surface of the epiblast in the foetus in the region of the back is at first unbroken. From it a great groove is formed running the entire length of the back. This becomes shut off from the surface epiblast and this again becomes continuous and unbroken and the mesoblast grows in between. The canal thus formed is at first oval but gradually its sides thicken enormously and nerves grow from them. By this thickening the canal at length becomes a slit, and its walls touch in the middle and grow together. The remaining anterior part of the orgginal cavity becoes the central canal of the cord while the posterior part opens out behind and becoes the posterior fissure. The anterior fissure is developed much later and is formed by the growing forward of the anterior columns of the cord. In early foetal life the cord fills the entire canal at birth it reaches as far as the 3rd. lumbar as from the 3rd. to the 8th. month the of foetal life the spinal canal and nerve roots grow more rapidly than the cord itself. The foetal cord is destitute of enlargments. After birth the thoracic portion lengthens more than the others.

THE MEDULLA OBLONGATA or spinal bulb, is one inch long, three-quarters of an inch broad and rather more than half an inch thick. Superiorly it is attached to the pons varolii, inferiorly itis continuous with the spinal cord, anteriorly it rests upon the basi-occiput and posteriorly it forms the floor, in great part, of the 4th. ventricle of the brain. The medulla like the cord is a bilateral organ whose two halvas are connected by a raphe in which are found nerve fibres and a few nerve cells. Each half shows on its lateral aspect certain swellings which are separated from each other by fissures.

FISSURES OF THE MEDULLA the anterior mesial fissure is continuous with the anterior fissure of the cord, but is somewhat obscured owing to the decussation in its lower part of the pyramidal tracts coming from the cord. It ends above at the lower border of the pons in a small foramen which lodges a minute process of dura mater, called the foramen caecum of Vic d'Azyr. There is no fissure in the cord to correspond with the posterior fissure of the cord because here here the fissure has become broadened out to form the floor and part of the cavity of the 4th. ventricle. The other fissures of the medulla are as follows, Antero-lateral, separates the anterior pyramid from the olivary body, gives origin to the 12th. cranial nerve. Postero-lateral, separates the olivary body from the tubercle of Rolando and gives origin to three nerves, the 9th. , 10th. and 11th. cranial nerves. By means of the lasttwo fissures the side of the medulla becomes broken off into three areas, . The

AREAS OF THE MEDULLA, Anterior area, or anterior pyramid, lies between the anterior mesial fissure and antero-lateral fissure. Lateral area, or olivary body bounded by the antero-lateral anf postero-lateral fissures. The posterior area shows upon its surface two subsidiary fissures, the lateral dorsal and the paramedian, by means of these last two three elevations are formed, first, the tubercle of Rolando having in its upper part the restiform body, second, the funiculus cuneatus which is derived from the column of Burdach. THis ends a-

bove in a little elevation, the cuneate tubercle which is only seen in chil
The Funiculus gracilis is conteouous with the column of Goll, and ends above in a rounded knob called the clava.
STRUCTURE OF THE MEDULLA, the medulla consists of white and grey matter. The grey is always internal to the white except on the floor of the 4th. ventricle. The grey matter of the medulla is exceedingly complicated for two reasons, in the first place because although continuous with the grey creseents of the cord the crescent here becomes broken up and scattered into various parts by the decussation and rearrangement of the white fibres on their way from the cord to the brain, secondly, new areas of grey matter make their appearance which have nothing to do with the cord at all. The crescent is split up as follows.

The anterior horn is cut off and pushed to the side forging the nucleus lateralis. The posterior horn becomes separated, pushed to the side and enormously enlarged and constitutes the nucleus of Rolando. From the stump of the remaining grey matter there grows out the nucleus cuneatus lying in the bundle of that name, also the nucleus gracilis lying in the clava and lastly the sheet of grey matter which appears on the floor of the 4th. ventricle and gives origin there to the posterior of the cranial nerves. The remainder of the horn becomes somewhat more mesial, very much scattered up and broken and constitutes Formatio Reticularis. The new grey matter , the chief collection of this constitutes the olivary nucleus which is very large and consists of a contorted sheet of grey matter enclosed in white and which, by the swelling caused by its presence, accounts for the olivary body seen on the surface of the medulla. Two lesser masses of new grey matter are called the inner and outer accessory olive The olives are intermediate stations between the cerebellum and cerebrum, have no connection whatever with the spinal cord.

WHITE MATTER OF THE MEDULLA, may be described under two headings, white matter derived from the spinal cord, and white matter which is confined to the medulla On tracing up the columns of the cord they are found to behave thus, ----

ANTERIOR COLUMN, splits up in the medulla into three bundles, the direct pyramidal tract passes to the pyramid of the same side; a tract passes to the olive on the same side and lies in relation to it, a third tract ends in the formatio reticularis.

THE LATERAL COLUMN also splits into three, the crossed pyramidal goes to the pyramid of the opposite side; the direct cerebellar tract goes to the cerebellum and a tract goes to the formatio reticularis..

POSTERIOR COLUMN in this the columns of Goll and Burdach end at the lower part of the medulla in rounded knobs called the clava and the cuneate tubercle.From the apices of these fibres are given off which pass to the cerebellum and also form a well edfined tract called the fillet which crosses the raphe of the medulla to the opposite side(a white tract) and on the opposite side becomes a vertical tract which as it ascends through the pons to the brain gives off fibres to the corpora quadrigemina, the optic thalamus, and lastly the cortex of the brain. This tract is often spoken of as the mesial fillet and in its course towards the brain it is reinforced by fibres from the olive called the lateral fillet. There are two decussations in the medulla, one is pyramidal, is motor and is produced by the crossed pyramidal tracts. Then there is a second, a sensory decussation, deeply in the medulla, of which the crossing of the [illegible]



A A Arciform Fibres

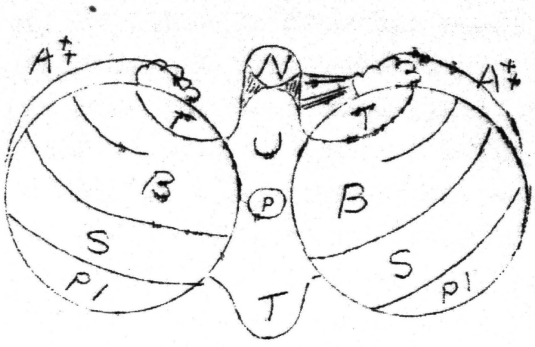

A* Part of Superior Surface

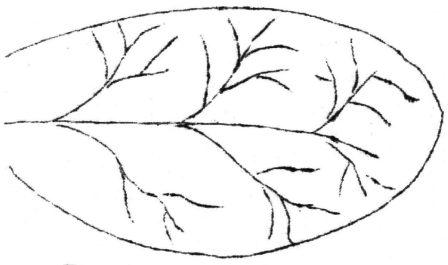

Arbor Vitae

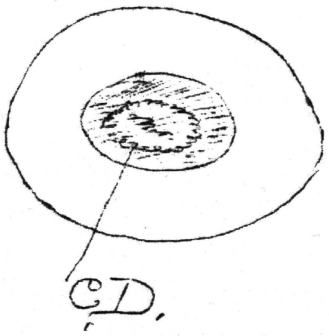

fillet forms the chief part.. The anterior pyramid of the medulla is composed of two bundles derived from the cord, the direct pyramidal tract of the same side and the crossed pyramidal of the opposite side.

THE OLIVARY BODY is formed mainly by the olivary nucleus, but has also fibres forming a tract in relation to it, derived from the anterior column of the cord.

NUCLEUS OF ROLANDO is only found in the lower part of the medulla and is mainly formed of neuroglia. In the upper half of the medulla its place is taken by the restiform body which comprises the following tracts all going to the cerebellum.direct cerebellar, comma tract of Gowers (probably), tract of Lissauer, (probably) fibres from Goll and Burdach and fibres proper to the medulla which are called arciform fibres. These latter begin on the opposite side of the medulla, they cross the anterior pyramids, lie on the surface of the olive and end in the restiform body. The deep arciform fibres begin on the opposite side of the medulla and pass deeply to the restiform body.

POSTERIOR PYRAMIDS OF THE MEDULLA comprising the clava and the cuneate tubercle are derived fromfrom the columns of Goll and Burdach. The fibres of the basis bundle as we saw and lateral mixed zone are chiefly commisural, but probably many of them reach the medulla and end in the formatio reticularis.. The raphe of the medulla is crossed by the followingsuperficial and deep arciform fibres, the fillet or lemniscus.

FUNCTIONS OF THE MEDULLA are three in number, it is a great switching center, it possesses many nerve centers and collections of grey matter, and it is the seat of many physiological centers, e.g.respiration, deglutition, etc.

THE PONS VAROLII is cuboidal in form and rests upon the dorsum sellae of the sphenoid. Superiorly it has the crura cerebri, inferiorly the medulla, anteriorly it rests upon the bone and shows a groove for the basilar artery, posteriorly it forms a large part of the floor of the 4th. ventricle. The lateral surfaces are connected to the cerebellum of which the form the middle peduncles. The pons varies in size in different individuals and also to a much greater extent in different mammals owing to the size and development of the cerebellum. It consists of white and grey matter and has a raphe very much like that of the medulla. On section it is divided into two parts, the pyramical portion containing the pyramids of the medulla and a ventral portion which lies near the 4th. ventricle and is the deep portion. The white matter of the pons, the great bulk of the fibres of the pons are transverse., they are divided into two sets superficial and deep. These two sets go to the cerebellum and form its middle peduncles; there are also longitudinal fibres which are also superficial and these consist of the anterior pyramids and lie between the superficial and deep transverse fibres, and the deep longitudinal which are mainly composed of the fillet and some vague tracts derived from the cord and the medulla. The GREY MATTER OF THE PONS is very much scattered but there are three distinct masses of it, the nucleus pontis, a little mass in the neighborhood of the pyramid between the superficial and deep transverse fibres, the superior olive and the nuclei of various cranial nerves especially found on the floor of the 4th. ventricle. The pons has also a formatio reticularis exactly like that of the medulla

THE CEREBELLUM is especially large in man and is usually completeln covered by the cerebrum. It consists of two hemispheres and a central part, the vermiform process. It has two incisurae or notches, one in front and one behind. It has

three pairs of peduncles, the superior connect it with the cerebrum, the middle with the pons and the inferior with the medulla. The functions of the cerebellum are those of co-ordination, it has also something to do with the higher mental faculties and is also undoubtedly connected with the generative functio Peduncles of the cerebellum, the inferior are mainly composed of the restiform tracts of and by these the cerebellum is connected with all three columns of the cord and to the medulla by its arciform fibres. The middle peduncles consi of the deep and superficial transverse fibres of the pons, while the superior pedunbles pass from the white matter of the cerebellum and end in the corpora quadrigemina.. There is only one named fissure in the cerebellum, the great hor izontal, it separates the upper and lower aspects of the hemispheres. There are many other unnamed fissures. The surface of the cerebellum is laminated, not co voluted. The superior surface of the cerebellum shows two hemispheres practically joined together, the vermiform process is scarcely seen at all but we always see a little lobe in front, the lingula, this surface is divided intotwo imaginary lobes, the supero-anterior and supero-posterior. The inferior surfac of the cerebellum shows not only the hemispheres but also the vermis. Each hemisphere is broken up by somewhat deeper fissures into the following parts, the flocculus, tonsil, biventral lobe, slender lobe, and the postero-inferior lobe. The vermis lies in a great hollow called the volecula or valley and from behind forward it shows the following parts, the tuber, pyramid, uvula and nodule. The valley also shows the furrowed band which is a thing plate of grey matter connecting the uvula with the tonsil. There is another plate of white matter between the nodule and the flocculus, the inferior medullary velum. On making sections of the cerebellum we find on sagittal mesial section that the white matter is arranged like a tree (the arbor vitae), lateral sections show the wtite matter muchincreased in amount and in its center is a contorted mass the corpus dentatum. This latter nucleus has a large white center or core. The structure of the cerebellum. On its surface it has a great layer of neuroglia and its grey matter which forms a thin covering more or less branched. All over its free surface this grey matter may be divided into three layers, the outer layer, or grey layer; the rust colored layer, and the layer of Purkinje's cells which lie between the other two. ~~In~~ The outer or geey layer which contains many curious processes connected with cells, many of them having knobs upon them while others are ~~T3~~- T-shaped, also contains bipolar or multipolar nerve cells and one set of these cells sends great branching processes inward, these are called the basket processes which embrace the cells of Purkinje. Purkinje' cells are enormous and are the feature of the cerebellum and are greht flask like cells with antler-like processes. . The rust-colored layer possesses small nerve cells also large cells, with enormous arborescence.

THE VENTRICLES of the brain are five little cavities in the interior of the brain, each of which is lined by an ependyma or special layer of neuroglia covered with ciliated epithelium, the cilia being lost in the adult. Of these five ventricles three are mesial, the 3rd. 4th. and 5th. while two are lateral.

THE 4TH- VENTRICLE is a lozenge-shaped cavity which lies under cover of the cerebellum. Below it communicates with the central canal of the spinal cord and above with the third ventricle through the aqueduct of Sylvius. Above it lie the superior peduncles of the cerebellum, below it are the restiform tract

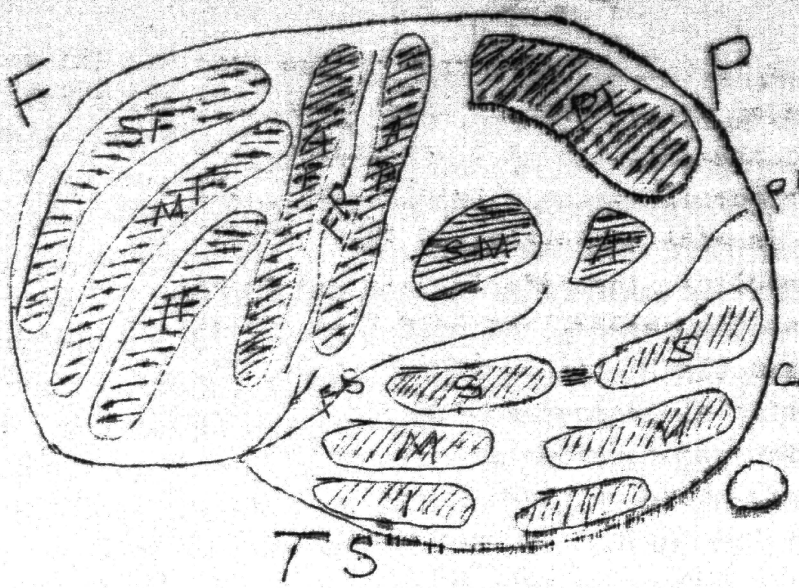
F
P
PO
SF
MF
IF
PC
SM
A
S
IP
TS
External aspect.

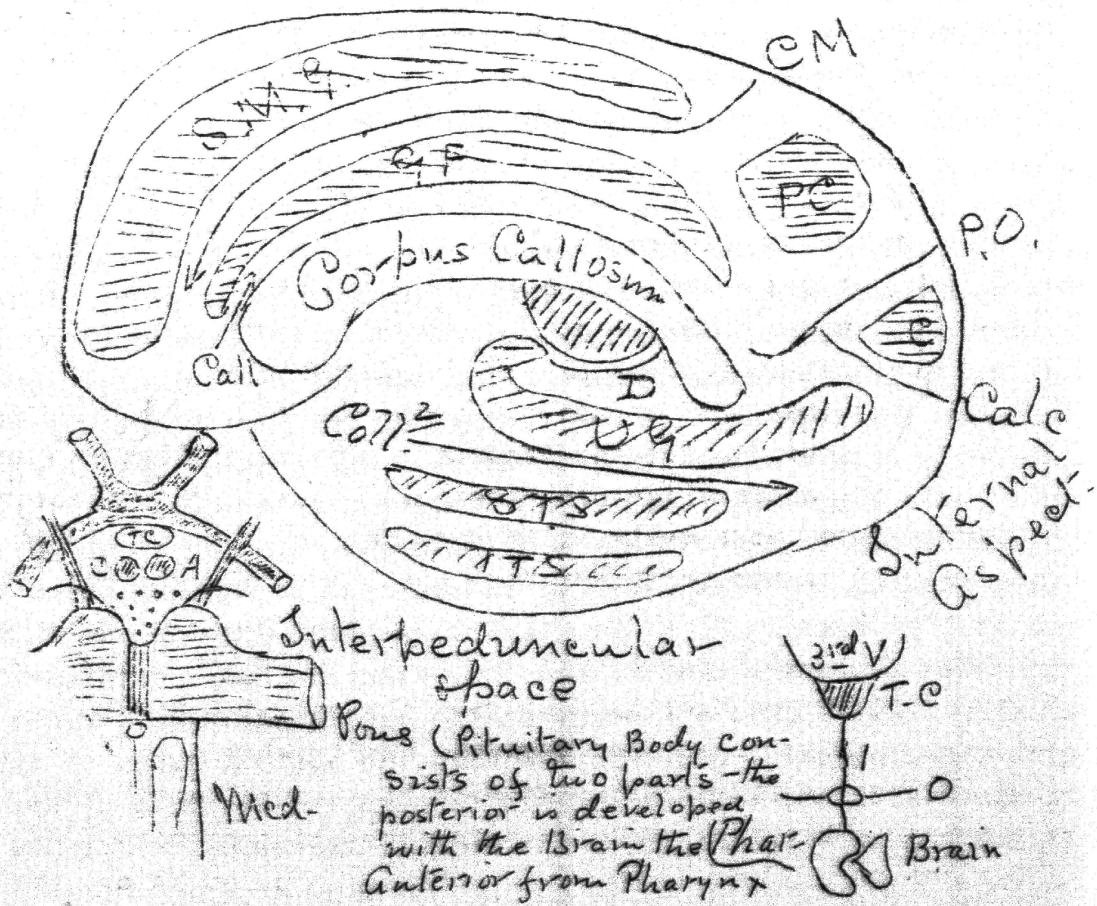
CM
SMF
IF
PC
P.O.
Corpus Callosum
Call
D
Coll²
STS
ITS
Calc
External Aspect.
TC
C
A
Interpedunculer space
Pons (Pituitary Body consists of two parts - the posterior is developed with the Brain the Anterior from Pharynx
Med-
3rd V
T.C
I
O
Brain

and posterior pyramids, its floor is formed by the pons and the medulla and shows a central groove on either side of which is an elevation called the fasciculus teres. At either angle we have a depression, the fovea, while in the posterior half is a series of fibres stretching out, the striae acousticae, near these is a little elevation called the tuber acousticum. The lower angle is acllee the calamus scriptorius, and to a little thickened mass of epithelium in the roof, just over the calamus, the name obex is applied. The roof of the 4th. ventricle is formed firstly of a sheet of grey matter stretching between the superior peaunoles of the cerebellum called the superiir medullary velum, but much more commonly is called the valve of Vieussens. Secondly it is formed by pia mater, of course covered on its under surface by the ependyma, and this posterior part of the roof is supported by fibrous bars called the ~~kkkkkkk~~ ligula, the lingula lies over the apex of the 4th. ventricle. There are three set of openings into this ventricle, t e central canal of the cord, the aquecuct of Sylvius and the foramina of Magendie which are holes through ~~kkkk~~ the pia matleading into the sub arachnoid space.

DISSECTION FOR THE 4th. VENTRICLE, cut through the crura cerebri and remove that portion of the brain consisting of the cerebellum, pons and medulla. Plac that segment with the medulla downwards, on cutting the cerebellum into two halves the roof of the ventricle is exposed, and on reflecting that we see the ventricle.

THE CEREBRUM is the largest division of the brain and forms a great ovoid mass which fills the entire skull cavity above the level of the tentorium cerebelli. It is split into two hemispheres by a great fissure called the great longitudinal fissure. These hemispheres are, however, connected together by various commissures and structures at the base of the brain. The surface of each hemisphere is very much convoluted and presents for examination fissures and convolutions. These are studied on three aspects of the brain, external, internal and basal. On the external surface we see three great fissures, the Fissure of Sylvius, the Fissure of Rolando and the parieto occipital fissure. The FISSURE OF SYLVIUS is the largest and widest and shows two limbs and these are an anterior which is small and a posterior which is large.

FISSURE OF ROLANDO begins near the great longitudinal fissure and terminates near the fissure of Sylvius.

PARIETO-OCCIPITAL FISSURE is freely seen on this surface. By means of these 3 fissures the external aspect of the brain is broken up into 4 lobes, the Frontal, Parietal, Temporo-sphenoical and the Occipital.

FRONTAL LOBE is bounded in front by the periphery of the brain, behind by the fissure of Rolando, above and internally by the great longitudinal fissure, below by the periphery of the brain and the fissure of Sylvius. By smaller intra lobular fissures the frontal lobe is broken up into four great convolutions, the ascending, superior, inferior and middle frontals, the last three lying so what obliquely.

TEMPORO SPHENOIDAL LOBE is well marked off from the frontal ~~by the~~ and the parietal but poorly so from the occipital because certain gyri called annectant gyri connect them. This lobe presents us with three convolutions, the superior middle and inferior temporo-sphenoidals. . Of the fissures which separate these only one is named, the parallel fissure. This lobe is bounded above by the fis

sure of Rolando, below, the periphery of the brain, in front by the periphery and behind by the occipital lobe.

OCCIPITAL LOBE, is poorly marked off on this aspect of the brain as the parieto occipital fissure is so small and secondly on account of the annectant gyri which tend to obscure its limits. It shows three convolutions, one over the other, superior, middle and inferior.

PARIETAL LOBE, has the following boundaries, anteriorly the fissure of Rolando posteriorly the parieto-occipital fissure, inferiorly the fissure of Sylvius and above and internally the great longitudinal.. The convolutions of this lobe are four in number, the ascending parietal, the parietal lobule, the supra-marginal gyrus and the angular gyrus. We have in this lobe the intra-parietal fissure. There are some four little inconstant gyri which connect this lobe with the occipital.

THE INTERNAL ASPECT OF THE BRAIN, on this aspect is seen the corpus callosum and certain nuclei, also the following fissures, the calloso-marginal, the callosal, the parieto-occipital, the calcarine, the collateral and the dentate. The convolutions are the supra-marginal gyrus, the praecuneus (or parietal lobule) the cuneus (or occipital lobule) and the gyrus fornicatus which is bounded above by the calloso-marginal and callosal, below and behind by the parieto-occipital fissures, also the uncinate gyrus, and the inferior temporo-sphenoidal. The dentate fissure separates the uncinate convolution from the hippocampal, and has at its bottom a little contorted grey matter which is called the dentate fascia.

THE BASAL ASPECT OF THE BRAIN shows the under surface of the frontal lobe and temporo-sphenoical lobe, the cerebellum, pons and medulla, the interpeduncular space, cranial nerves e&c. The basal convolutions. In the middle line of the base from before backward we see the great longitudinal fissure, the corpus callosum, the lamina cinerea, the optic commissure, tuber cinereum, corpora albicantia, posterior perforated spot, pons varolii, foramen caecum of Vic d'Azyr, and the anterior median fissure ofthe medulla. The lateral surface of the base shows the under surface of the frontal lobes, with two fissures (the triradiate and the straight) and one convolution (the gyrus rectus).

THE INTERPEDUNCULAR SPACE is a lozenge shaped space at the base of the brain. It is bounded anteriorly by the optic commissure, pisteriorly by the pons, late ally by the optic tract and the crus cerebri. The contents of the space are the tuber cinereum (a little tubercle of grey matter on the floor of the 3rd. ventricle, it as a stalk, the infundibulum, which again has attached to its under surface athe pituitary body). The corpora albicantia, (the twisted and upturned pillars of the fornix) the posterior perforated spot (stows a number of foramina for the passage of small arteries to the basal ganglia) 3rd. pair of nerves . In this space the subarachnoid fluid is most abundant and here it forms the water-bed for the brain. The lamina cineres is a sheet of grey matter found at the base of the brain in the middle line just in front of the optic commissure.

ISLAND OF REIL we have seen that the cerebrum consists as seen from the outside, inside or below of four lobes, but there is a 5th. which lies under cover of the temporo-sphenoidal and frontal lobes. It consists of 5 or 6 gyri which radiate from a central point the anterior perforated spot and these gyri


B
S
Pedunculus

The Fornix

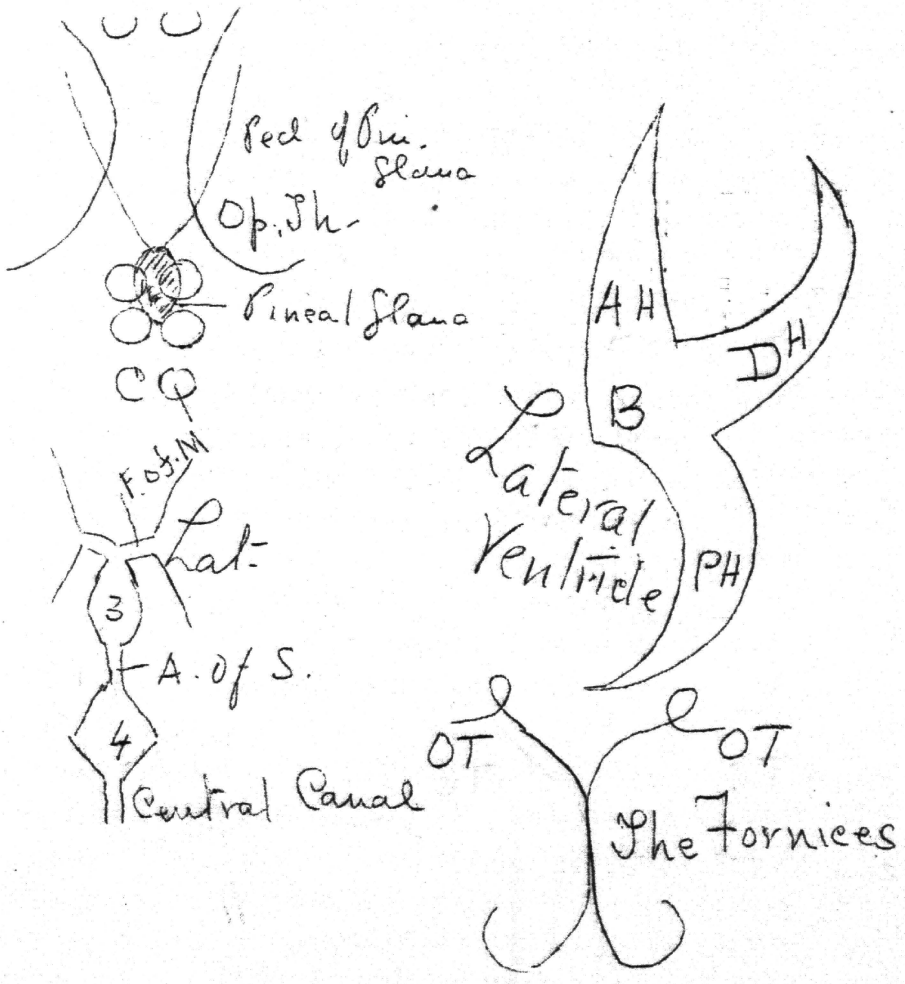
Ped of Pin. Glana
Op. Th.
Pineal Glana
CQ
F. of. M
Lat.
3
A. of S.
4
Central Canal
AH
DH
B
Lateral Ventricle
PH
OT
OT
The Fornices


Venae Galenae
Straight Sinus

are called the gyri operti(hidden). Below they are closed in by the temp... sphenoical lobe, laterally they are covered by the rest of the cerebrum, while externally three convolutions especially cover them and are called the operculum or lid, they are the ascending frontal and parietal and the inferior frontal.
DISSECTION FOR THE ISLAND OF REIL place the brain base upward,, open up the Sylvian fissure, the island is exposed. The brain is now placed on its base and horizontal slices are now made through its substance. On making a slice into one hemisphere it is seen to consistof a grey cortex and one large central white part, the centrum ovale minus. The centrum ovale majus is the two centra ovale minora with the corpus callosum joining them.
THE CORPUS CALLOSUM is the great transverse commissure of the brain, it is about four inches long and one inch wide, being specially broad behind. It joins the two hemispheres and lies somewhat nearer the front of the brain. Upon its upper surface are seen central lines, the striae longitudinales centrales, and external to these are other lines the striae longitudinales laterales, some of which are ofteo called the nerves of Lancisi. The corpus callosum is very thick and on section shows a splenium, body, genu, rostrum and peduncles, which last end in the white matter in the fissure of Sylvius.
THE 5th. VENTRICLE is a narrow vertical slit which exists in a sheet of grey matter called the septum lucidum. It is doubtfully lined by an ependyma and h s no communication with the other ventricles.
DISSECTION FOR THE 5th. VENTRICLE, place the brain on its base and slice from above downward horizontally till the corpus cal osum is reached, reflect this, separate the two laminae of the septum lucidum, then is exposed the ventricle.
DISSECTION FOR THE 3rd. VENTRICLE, place the brain on its base, slice from above downward horizontally until the corpus callosum is reached, reflect the corpus callosum, the fornix, the velum interpositum, and the ventricle is seen.
THE 3rd. VENTRICLE is really a narrow vertical slit, but owing to the softness of the brain substance when the brain is allowed to remain on its base after removal from the body it becomes broadened out. It lies between two great nuclei, the optic thalami. Relations, Anteriorly, the anterior pillars of the fornix, laterally, the optic thalami and the peduncles of the pineal gland, posteriorly the corpora quadrigemina and the pineal gland. The roof is formed by the velum interpositum the fornix and the corpus callosum, while its floor is formed by the structures which we saw in the interpeduncular space, the lamina cinerea, the optic commissure, the tuber cinereum, the corpora albicantia and the posterior perforated spot. The ventricle is crossed by three commissures an anterior, white, between the anterior pillars of the fornix, a middle which is broad and is formed of grey matter and by it the two optic thalami are connected, and a posterior which is white and lies just in front of the pineal gland.
DISSECTION FOR THE LATERAL VENTRICLE, brain on base, slice in the same manner as already mentioned until the level of the corpus callosum is nearly reached. On removing the white matter of the centrum ovale minus very carefully from one side together with the ependyma forming the roof the lateral ventricle is exposed..
THE LATERAL VENTRICLE consists of a body, anterior horn, posterior horn and a descending horn. The anterior horn is blunt and rounded, it passes forward downward and outward. The posterior horn passes backward and outward, then

inwards. The descending horn passes backwards, outwards, then downward, forward and inward. On the floor of the lateral ventricle the following are found, first a piece of the floor itself, the caudate nucleus of the corpus striatum, a white tract the taenia semicircularis next, the optic thalamus, the choroid plexus, posterior pillar of the fornix, the descending horn, the hippocampus major, the collateral eminence, the hippocampus minor. The descending horn has a fissure upon its inner aspect, in the adult this fissure is closed butin the foet us this communicates with the with the base of the brain and through it the pia mater sends a special process which is found as a fine fringe running down the horn. To expose this horn a large piece must be cut away from the side of the brain, chiefly from the temporo-sphenoidal lobe. This horn contains three things from before backward, the choroid plexus, the taenia hippocampi and the hippocampus major, and all follow the direction of the entire horn. THe hippocampus major traced to the bottom of the horn shows two or three little depressions giving it the appearance of a foot, t e pes hippocampi. The enminences are the hippocampus major and minor and the collateral eminence, all are due to the presence on the outside of the brain of fissures, namely, the hippocampal fissure, the calcarine fissure and the collateral fissure.. The lateral ventricle is lined by an ependyma. The aqueduct of Sylvius tunnels through the corpora quadrigemina and ends in the 4th. ventricle. The foramina of Magendie pierce the pia mater and connect the 4th. ventricle with the subarachnoid space. Each ventricle has a choroid plexus, each is a lymph space and by the presence in them of a choroid plexus there can be exuded into them the fluid of the blood.

THE FORNIX is a tract of white matter which lies under cover of the corpus callosum and upon the velum interpositum. It consists of a body which lies on the posterior part of the velum, a posterior pillar on either side which runs in the descending horn of the lateral ventricle, it is broad and flat; and an anterior pillar which passes downward and forward until it reaches the fsonh of the 3rd. ventricle when it passes vertically downward to the base of the brain when, appearing on the base it makes a sudden turn upward and outward and ends in the optic thalamus. The corpus albicans runs round the end of the anterior pillar of the fornix.

THE VELUM INTERPOSITUM is a double fold of pia mater found in the center of the brain into which it has passed through the great transverse fissure of the cerebrum. The transverse fissure of the brain lies between the cerebrum and cerebellum and consists of three parts, a central which is almost straight, lateral parts which are in the descending horns of the lateral ventricles. The relations of the central part are as follows, above are the corpus callosum, fornix and brain substance. Below are the corpora quadrigemina, pineal gland and brain substance. Through the transverse fissure passes the velum interpositum the edges of which are covered by a rich capillary plexus forming the choroid plexus of the lateral ventricle. Upon the surface runs a series of straight veins the veins of Galen, they open into the straight sinus. The choroid plexus of the 3rd. ventricle is furnished by a few vascular projections on the under surface of the velum.

CORTEX CEREBRI or the surface of the brain is also called the hemispherical ganglion, also the pallium. It is much indented by fissures leading to marked convolution of the surface. This cortex is made up of grey matter, the outer



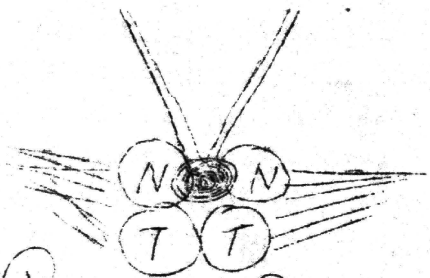

Corpora Quad.
and Pineal Gland



Crusta

free surface just under the pia mater is mainly made up of neuroglia, the grey matter may be divided into four layers, a molecular layer which consists of fibres and knobs and is mainly derived from the pyramidal nerve cells. Lying at a deeper level is a layer of small pyramids, then comes a layer of large pyramids then a somewhat composite layer the cells are polymorphous and golgi. Throughou all these layers run many fibres towards the free surface, many of them are derived from the cells, others from the white matter, many beginning in knobs wit in it.

AREAS IN THE BRAIN the motor area is the area in the region of the neighborhood of the fissure of Rolando. The temporo sphenoidal lobe is largely concerned in hearing, smell and taste. The occipital lobe is mainly concerned in the sense o sight. The area of sensations of touch, pain and temperature are probably clustered round the extremity of the fissure of Sylvius. The anterior part of the brain in its lowest convolution is the speech area, closely corresponding to th inferior frontal convolution. (unilateral) The remaining part of the frontal lobes is the probable area for the higher mental faculties..

THE BASAL GANGLIA. Corpus striatum, was formerly described as a single body, is now known to consist of two nuclei, the caudate and lenticular nuclei. The caudate nucleusconsists of white matter containing grey streaks. The lenticular nucleus is oval and is narrow in front and behind. Onsection this nucleus show three zones of grey matter alternating with white.

INTERNAL CAPSULE is the tract of white matter bounded internally by the caudate nucleus and optic thalamus and externally by the lenticular nucleus. It shows upon it a band or genu which divides it into an anterior and a posterior half. The posterior half is almost entirely composed of direct and crossed pyramidal h fibres which have come from the spinal cord, through the medulla and pons and are here seen passing on their way to the brain cortex. Of the posterior half two-thirds are motor, one third sensory.

OPTIC THALAMUS, consists of two parts, an anterior tubercle or intraventricular part and a posterior tubercle or extraventricular part, also called the pulvinar. The structure of the optic thalamus is white matter externally, mixed grey and white internally, althought the grey matter is stated to be in three distinct nuclei.

NUCLEUS AMYGDALUS a round knob in the end of the descending horn of the lateral ventricle which is r ally a part of the surface of the temporo-sphenoidal lobe.

CORPORA GENICULATA. On tracing the optic tract backwards it is found to be asso iated with two little swellongs at its posterior end, these are the corpora ger iculata externum and internu, they are connected with sight.

CORPORA QUADRIGEMINA are four little bodies which are joined together and rest on the pons, they bound the 3rd. ventricle posteriorly. The anterior pair are called the nates, the posterior the testes. These little lumps are white matter enclosing grey and there extend out on eithe sice from them white tracts, brachia. These corpora are connected with other nuclei especially the corpora geniculata and are directly connected with sight.

DISSECTION FOR THE CORPORA QUADRIGEMINA Same as for 3rd. ventricle.

THE PINEAL GLAND or conarium, is a reddish bodyperched upon the nates and extending forward from it are its two peduncles which lie upon the optic thalami It is invested by pia mater and in structure it consists of follicular matter

with a large number of crystals called brain sand. The pineal gland 182the developmental remnant of a third eye.

THE CRURA CEREBRI, or legs of the brain, extend upward from the upper border of the pons to the under surface of the cerebrum, passing upward, forward and outward. They are about 1½ inch long, ¾ inch broad. Each consists of two parts a superficial or ventral part, the crusta and the tegmentum. These two parts are separated from each other by a mass of grey matter containing pigment to which the name of locus niger has been given. The crusta is practically entirely made up of pyramidal fibres from the spinal cord, direct and crossed. The tegmentum has in its substance a mysterious body called the red nucleus, otherwise it consists of sensory tracts passing to the cortex, the chief being the fillet.

COURSE OF FIBRES FROM CORD TO BRAIN. The direct pyramidal tract of the right side passes up the same side to the medulla although probably it decussates with its fellow through the anterior commissure of the cord in its entire length Having reached the medulla it is joined by the crossed pyramidal tract of the left side and the two bundles become one in the upper part of the right side of the medulla. This pyramidal tract passes through the pons unbroken, lying between the superficial and deep transverse fibres. It then passes through the crus cerebri, forming the posterior limb of the crusta, passes through the internal capsule, spreading out as it goes. The fibres gradually branch out as they approach the cortex of the brain, finally they end in the motor area of the brain.

ARTERIES OF THE BRAIN. At the base of the brain lies the circle of Willis which surrounds the interpeduncular space. The circle is formed by the anterior communicating which connects the two anterior cerebrals, the middle cerebrals, the posterior communicating and the posterior cerebral. This circle gives by the the freedom of the anastomosis great freedom to the equalization of blood supply in the brain.. The anterior cerebral artery is a branch of the internal carotid. It runs forward and upward in the great longitudinal fissure and winds round on the corpus callosum, lying on it. It supplies the frontal lobe and the corpus callosum. The middle cerebral artery is the largest of all, also called the Sylvian artery because it lies in the fissure of Sylvius.. It supplies the frontal, parietal, and temporo-sphenoidal lobes and gives off three named branches posterior communicating which completes the circle of Willis, the anterior choroidal which goes to the velum interpositum and a series of nuclear arteries which go to the basal ganglia the largest of them being the lenticulo-striate, (the"artery of cerebral hemorrhage"according to Charcot) The posterior cerebral artery supplies the occipital and temporo sphenoidal lobes. The veins of the brain open into the sinuses, the veins of the ventricles are called the veins of Galen, as already mentioned they open into the straight sinus.

END OF THE BRAIN AND SPINAL CORD.

INDEX

Abdomen ---------- 59
cavity of, ---------- 84
Anastomosis of elbow, ------ 7
crucial, --- 28, 32
Arachnoid, ----------118
Areas of brain, ---------- 181
ARTERIES
Aorta, ---------- 75
arch of, ---------- 52
Abdominal, --------- 75
thoracic, --------- 56
Ascending cervical, ------- 98
Axillary, ---------- 3
Brachial, & branches, --- 7
Carotid, external, ------ 98
common, --------58-4
internal, 89, 98, 107
Carpal, ulnar, --------- 15
radial, ------- 15
Coeliac axis, ---------- 69
Dorsalis indicis, ----- 15
pedis, ---------40
pollicis, ----- 15
Epigastric, deep, ------ 67
Facial ---------- 98
Femoral, -- 28-7-8-
Gastric, ---------- 69
Gluteals, ---------- 22
Hepatic, ---------- 69
Iliac common, ---------- 73
external, --------76
internal, -------- 84
Ilio-lumbar, ---------- 85
Inominate, ---------- 58
Intercostal, ---------- 45
Internam mammary, -------47
Interosseous, ulnar, --- 14
Lingual, ---------- - 98
Internal maxillary, ---- 104
Meningeal, ---------- 90
Mesenteric, sup. & inf. 68
Obturator, ---------- 85
Occipital, ---------- 96
Plantar, ---------- 38-7
Perineal, --------- 80, 82
Popliteal, ---------- 31
ARTERIES. conta.
Posterior auricular, ---------- 98
Profunda femoris, ---------- 29
Pudic, deep external, ---------- 80-2
internal, ---------- 84-85
Radial, ---------- 10, 15
Radialis indicis, ---------- 15
Scapular, posterior, ---------- 1
Sciatic, ---------- 23
Splenic, ---------- 69
Subclavian, -------- 53, 93, 97, 98
Superior intercostal, ---------- 98
Superior thyroid, ---------- 93
Suprascapular, ---------- 5, 93, 98
Thyroid axis, ---------- 98
Thyroid, inferior, ---------- 99
superior, ---------- 93
Tibial anterior, ---------- 34, 39
posterior, ---------- 35
Transversalis colli, ---------- 93, 98
Ulnar, ---------- 11
Vertebral, ---------- 97
ARTICULATIONS.
Differeot forms of, ---------- 19
Acromio-clavicular, ---------- 19
Ankle, ---------- 43
Atlanto-axial, ---------- 112
Elbow, ---------- 20
Foot, ---------- 43-4
Hip, ---------- 41
Knee, ---------- 42
Hand, ---------- 21
Occipito-axial, ---------- 112
Radio-ulnar, sup. middle, inf. -----20
Shoulder, ---------- 19
Sterno-clavicular, ---------- 19
Temporo-maxillary, ---------- 103
Tibio-fibular, sup. mid. inf. ----- 43
Wrist, ---------- 20
AXILLA ---------- --------- 2
Back, muscles of first layer, & second 1
3rd. 4th. & 5th. layers, ----- 114
Bile duct. ---------- 73
Bladder, ---------- 82
Brain, ---------- 117
Bronchi, ---------- 54, --57

Bulb of urethra, ---------- 61
Cerebellum, ----------125
Cerebrum, ---------- 127
Colon, ---------- 71
Coropora genioulata, ---------- 131
Corpora quadrigemina, ---------- 131
Corpus callosum, ----------129
Crura cerebri, ---------- 132
Diaphragm, ---------- 74
Thoracic duct, ---------- 38
Duodenum, ---------- 70
Dura mater, ---------- 88, 117

DISSECTIONS.

FOR femoral artery, ---------- 26
Brachial artery, ---------- 7
Radial artery, ---------- 10
Radial recurrent artery, ------- 12
Ant. Ulnar recurrent art. -------- 12
Post. ulnar recurrent artery, --- 15
Posterior interros. Nerve------- 14
Sciatic artery, ---------- 24
Nerve to quadratus, ---------- 24
Great sciatic nerve, ----------24
Gluteal artery, ---------- 23
External popliteal nerve, -------31
Obturator nerve, ---------- 30
External circumflex artery, ----29
Profunda femoris artery, --------29-
Crucial anastomosis, ----------32
Peroneal artery, ---------- 34
Posterior tibial artery, ------ 34
Anterior tibial nerve, ------- 40
Anterior tibial artery, ------- 40
Supl. cardiac plexus, -------- 54
Deep cardiac plexus, -------- 54
Thoracic duct, ---------- 55
Coeliac axis, ---------- 99
Pancreas, ---------- 73
Pelvic fascia, ---------- 81
Back of neck, ---------- 114
Orbit, ---------- 115
Lenticular ganglion, ---------- 116
Inferior rectus, ---------- -- 116
Superior thyroid artery, -------- 116
Lingual artery, ---------- 116
12th. cranial nerve, ----------116
11th. cranial nerve, ---------- 116
9th. cranial nerve, ----------- 116
Otic ganglion, ---------- 116
submaxillary ganglion, ---- 116
Inf. maxillary nerve, ---- 116
Meckel's ganglion---------- 116
Island of Reil, ---------- 129
5th. ventricle, ---------- 129
4th. Ventricle, ---------- 129
Lateral ventricle, --------- 129
3rd. Ventricle, ----------129
Corpora quadrigemina, ------ 131
Eyelids, ---------- 102
Face, ----------100
Fallopian tube, ---------- 94
Fascia of arm, ---------- 8
leg, ---------- 32
Lumborum, --------- 115
palmar, ---------- 15
pelvic, ---------- 81
plantar, ---------- 35
of thigh, ---------- 24
deep, ----------26
transversalis, ------- 87
Fauces, ---------- 110
Gall bladder, ----------80
Ganglion, cervical ----------109
Gasserian, --------- 89
Meckel's ---------- 111
otic, ---------- 107
spheno palatine, --- 111
submaxillary, ------ 108
Genitals, male, ---------- 63
female, ---------- 63
Glands of Bartholine, -------- 62
Parotid, ----------101
sublingual, ----------106
submaxillary, ---------- 105
thyroid, ---------- 100

HAnd palm of, ---------- 15
Heart ---------- 49
Hunter's canal, ---------- 28
Ileum, ---------- 71
Intermuscular septa of arm, --- 6
Interpeduncular space, ------- 128
Intestine, large, 71
small, ----------70
Ischio- rectal fossa, --------59
Island of Reil, ----------128
Jejunum, ----------71

Kidney, ---------- 77
Ligamentum cuchae, ---------- 1
Linea alba, ----------34
Lineae semilunares, ---------- 34
Liver, ---------- 79
Lungs, ---------- 49
Lumbi, ---------- 45
Mediastinum, ---------- 47
Medulla oblongata, ---------- 123
Memorana, costo-coracoic, ------ 2
Meninges, ---------- 117
Mouth, ---------- 110
MUSCLES,
Abduct. minimi digiti, --------- 17
Abduct. minimi digiti, (foot)--- 35
Abductor pollicis, ---------- 17
Abductor hallucis, ---------- 35
Accessorius pedis, ---------- 33
Adductor brevis, ---------- 33
Adductor longus, ---------- 34
Adductor magnus, ---------- 30
Adductor obliquus pollicis, --- 18
transversus pollicis, - 18
Adductor obliquus hallucis, ---- 37
transversus ---- 37
Biceps, (ira) ---------- 3
Biceps, (leg) ---------- 31
Brachialis anticus, ---------- 7
Buccinator, ---------- 104
Complexus, ---------- 114
Compressor urethrae, ----------30
Constrictors of pharynx, ------ 110
Coraco-brachialis, ---------- 3
Crureus, ---------- 33
Deltoid, ---------- 4
Digastric, ---------- 95
Erector clitoridis, ---------- 32
Erector spinae, ----------115
External sphincter, ---------- 50
Extensor brev. digit. --------- 32
Exten. carpi. rad. brevior.---- 13
longior, -- 13
Extensor carpi ulnaris, ------- 13
Extensor communi.digit.-------- 13
Extensor indicis, ---------- 14
Extensor long. digit. --------- 33
Extensor minimi digiti--------- 13
Extensor ossis. ---------- 14
Extensor primi ---------- 14
Extensor secundi, ----------14
Extensor proprius hallucis, ------- 33
Flexor brev. minimi digiti, (hand) 12
(foot)--37
Flexor brevis hallucis, --------- 37
Flexor brevis digit. ---------- 35
Flexor brevis pollicis, --------- 17
Flexor carpi radialis, ---------- 9
ulnaris, ----------10
Flexor sublimis digitorum, --------10
Flexor longus digitorum, --------- 33
Flexor longus hallucis, --------- 34
Flexor longus pollicis, ---------- 10
Flexor profundus digitorum, ----- 11
Gastrocnemius, ---------- 32
Gemellus superior, ---------- 28
Gemellus inferior, ---------- 28
Genio-hyo-glossus, ---------- 103
Genio-hyoid, ---------- 103
Gluteus maximus, ---------- 22
Gluteus medius, ---------- 23
Gluteus minimus, ---------- 23
Gracilis, ---------- 32
Hyo-glossus, ---------- 103
Iliacus, ----------29, 30
Infraspinatus, ---------- 5
Intercostals, ---------- 45
Interossei, (foot) ---------- 41
(hand)---------- 19
Latissimus dorsi, ---------- 1
Levator anguli scapulae, ------- 1
Levator palati, ----------110
Longus colli, ----------109
Lumbricales, (hand) ---------- 11
(foot) ---------- 36
Masseter, ---------- 103
Mylo-hyoid, ---------- 105
Oblique, external, ---------- 34
internal, ---------- 35
Obturator externus, ----------28,- 30
internus, ---------- 28
Occipito frontalis, ---------- 97
Omo-hyoid, ---------- 95
Opponens minimi digiti, --------- 17
Opponens pollicis, ---------- 17
Palmaris brevis, ---------- 11
Palmaris longus, ---------- 9
Pectineus, ----------.29
Pectoralis major, ---------- 2

MUSCLES contd.

Pectoralis Minor, ---------- 2
Peroneus brevis, ---------- 40
Peroneus longus, ---------- 40
Peroneus tertius, ---------- 39
Plantaris, ---------- 38
Platysma myoides, ---------- 99
Popliteus, ---------- 38
Pronator quadratus, ---------- 11
Pronator radii teres, ---------- 9
Psoas magnus, ---------- 29
parvus, ---------- 78
Pterygoid, external, ---------- 103
internal, ---------- 104
Pyramidalis abdominis, ---------- 33
Pyriformis, ---------- 33
Quadratus femoris, ---------- 33
lumborum, ---------- 78
Rectus abdominis, ---------- 33
Rectus capitis ant. maj.& min. ---- 109
Rectus femoris, ---------- 27
Rectus lateralis, ---------- 109
Recti of eye, ---------- 91
Rhomboideus major and minor, -- 1
Sartorius, ---------- 27
Scaleni, ---------- 109
Semimembranosus, ---------- 31, 32
Semitendinosus, ---------- 31, 32
Serratus magnus, ---------- 4
Soleus, ---------- 38
Splenius, ---------- 114
Sterno-mastoid, ---------- 94
Sterno-hyoid, ---------- 95
Sterno-thyroid, ---------- 95
Stylo -glossus, ---------- 103
Stylo-hyoid, ---------- 95
Stylo-pharyngeus, ---------- 106
Subscapularis, ---------- 5
Supinator brevis, ---------- 18
longus, ---------- 12
Supraspinatus, ---------- 4
Temporal, ----------99, 103
Tensor-palati, ----------107, 110
Tensor vaginae femoris, ------ 27
Teres major and minor, ------ 5
Thyro-hyoid, ---------- 95
Tibialis anticus, ---------- 38
postibus, ---------- 33
Transversalis abdominis, ----- 65
Transversus perinei, ---------- 61
Trapezius, ---------- 1
Triangularis sterni, ---------- 47
Triceps, ---------- 9
Vastus external, ---------- 30
internus, ---------- 29

NERVES

Cardiac, ---------- 99
Cervical, ---------- 99, 104
Cranial, ---------- 112
Crural, anterior, ---------- 27
Dental, inferior, ---------- 105
Descendens hypoglossi, -------- 95
Fifth, ---------- 101
Glosso-pharyngeal, ---------- 107
Gluteal, inferior, ---------- 32
superior, ---------- 33
Hemorrhoidal, inferior, -------- 30
Hypoglossal, ----------95, 103, 109
Intercostal, ---------- 45
Laryngeal, recurrent, --------- 99
superior, --------- 99
Lingual, ---------- 105
Maxillary, inferior, ---------- 105
superior, ---------- 111
Median, ---------- 8, 11, 17
Musculo cutaneous, (arm) ----- 8
(leg,) 39, 41
Musculo spiral, ---------- 9
Obturator, ---------- 30
Perineal, ---------- 30
superficial, -------- 32
Phrenic, ---------- 49, 99
Plantar, external, ----------34, 37
internal, ---------- 36
Popliteal, external, ---------- 41
Internal, ---------- 41
Pudic, ---------- 24, X, 31
Radial, ---------- 18
Saphenous, ----- long, ------- 39
short, -- ---32, 34
Sciatic, -----great, ---------- 24
small, ---------- 34
Spinal accessory, ------- 99, 109
Splanchnics, ---------- 57
Nerve to quadratus, ---------- 24
Sympathetic, abdomen, ---------- 74
thorax, ------- 56, 79
Thoracic anterior, ---------- 4

NERVES, contc.
Thoracic, posterior, ---------- 4
Tibial, anterior, ---------- 39, 40
Tibial, posterior, ---------- 34
Ulnar, ---------- 7, 13, 17, 13
Vagus, ---------- 56, 98, 108
Ulnar collateral, ---------- 9

NOSE, ----------111
cartilages of, ---------- 108
Nucleus amygdalae, ---------- 181
Oesophagus, ---------- 54, 100
Olfactory nerve, ---------- 111
Olivary body, ---------- 125
Orbit, ---------- 90
Ovary, ---------- 84
Pancreas, ---------- 79
Pelvis, ---------- 80
Pericardium, ---------- 48
Perineum, ---------- 59
Peritoneum, ---------- 87
Pharynx, ---------- 102
Pineal gland, ---------- 131
Pleurae, ---------- 47
Plexus, brachial, ---------- 94
cardiac, ---------- 54
cervical, ---------- 93
lumbar, ---------- 79
Pons varolii, ---------- 125
Prostate gland, ---------- 89
Pterygo-maxillary fossa, ---------- 103
Quadrilateral space, ---------- 5
Receptaculum chyli, ---------- 79
Ring, abdominal, int. and ext. ------ 85
Saphenous opening, ---------- 25
Scalp, ---------- 97
Scarpa's triangle, ---------- 26
Sheath, femoral, ---------- 29
Sola of foot, muscles of, ---------- 35
Space, popliteal, ---------- 30
Spermatic cord, ---------- 85
Spinal cord, ---------- 117
Spinal nerves, ---------- 112
Spleen, ---------- 73
Stomach, ---------- 69
Suprarenal capsule, ---------- 77
Testicle, ---------- 85
Thoracic duct, ---------- 85
Thyroid gland, ---------- 100
Trachea, ----------54, 57
Tracts in cord, ----------121
Triangle at elbow, -------- 9
Hesselbach's, ----- 37
of neck, ant. ----- 91
post. ---- 92
Occipital, -------- 93
suboccipital, ----- 114
Triangular space, ---------- 5
Uncilicus, ---------- 84
Ureters, ---------- 77
Urethra, male, ---------- 88
female, ---------- 95
Uterus, ---------- 88
Vagina, ---------- 88
VEINS, azygos, ---------- 55
Femoral, ---------- 27
Iliac, ---------- 73
Cava inferior, ----------74 58
superior, ---------- 58
Ilominate, ---------- 58
Intercostal, superior, ----- 45
Jugular, internal -----97,---107
Popliteal, ---------- 31
Portal, ---------- 73
Profunda femoris, ---------- 30
Pulmonary, ---------- 52
Saphenous, ----------28, 32
Subclavian, ----------98
Suprascapular, ---------- 93
Of arm, ----------5, 12
Velum interpositum, -------- 130
Ventricles of brain, --------123
Ventricle, fourth, --------- 127
third, ---------- 128
fifth, ---------- 129
lateral, -------- 129
Vesiculae seminales, ------- 88

****
****
****
****
*****
*