

**Anatomy in a Nut Shell
or
Questions and Answers
with
Explanatory Notes**

William Ross Laughlin, M.S, D.O.

**Copyrighted by Publishers
1899**

©Museum of Osteopathic Medicine, Kirksville, MO [RZ 321.L37]

May not be reproduced without permission of the Museum of Osteopathic
Medicine

ANATOMY

IN A NUT SHELL

—OR—

QUESTIONS AND ANSWERS WITH

EXPLANATORY NOTES

—BY—

WILLIAM ROSS LAUGHLIN, M. S., D. O.

Professor of Descriptive Anatomy in the American School of Osteopathy.

KIRKSVILLE, MISSOURI,

SEPTEMBER FIRST,

—1899—

DEMOCRAT PRINT, KIRKSVILLE, MISSOURI

POOR HUMANITY.

The following poetry was found in the pocketbook of the late G. H. Laughlin.

More than half a century since the following lines were found in the Royal College of Surgeons, London, beside a skeleton, remarkable for its symmetry of form. They were subsequently published in the London *Morning Chronicle*, and a vain effort made to ascertain the author, even offering a reward of fifty guineas.

"Behold this ruin! 'Twas a skull
Once of ethereal spirit full.
This narrow cell was life's retreat,
This space was thought's mysterious seat.
What beauteous visions filled this spot
With dreams of pleasures long forgot!
Nor hope, nor joy, nor love, nor fear,
Have left one trace of record here.

"Beneath this moulding canopy
Once shone the bright and busy eye.
But start not at the dismal void!
If social love that eye employed;
If with no lawless fire it gleamed;
But thro' the dew of kindness beamed—
That eye shall be forever bright,
When sun and stars are sunk in night.

"Avails it whether bare or shod,
These feet the path of duty trod?
If from the bowers of ease they fled,
To seek affliction's humble shed;
If grandeur's guilty bribe they spurned,
And home to virtue's cot returned—
These feet with angel's wings shall rise,
And tread the palace of the skies."

"Within this hollow cavern hung
The ready, swift and tuneful tongue.
If falsehood's honey it disdained,
And when it could not praise was chained;
If bold in virtue's cause it spoke,
Yet gentle concord never broke—
That silent tongue shall plead for thee,
When time unveils eternity.

"Say, did these fingers delve the mine,
Or with the envied ruby shine?
To hew the rock or wear the gem,
Can little now avail to them.
But if the page of truth they sought,
Or comfort to the mourner brought—
These hands a richer meed shall claim
Than all who wait on weal or fame

He who every morning plans the transactions of the day, and follows out that plan, carries on a thread which will guide him through the labyrinth of the most busy life.—BLAIR.

PREFACE.

THIS book is not intended to take the place of any standard text-book in anatomy but is to be used as an aid for the student. The origin and insertion of the muscles have not been given, as that is out of the province of this book. In preparing this book, several authorities have been consulted, as A. T. Still, Gray's Anatomy, Morris' Anatomy, Gerrish's Anatomy, Century Dictionary, etc.

*Dedicated to him (A. T. Still)
whose life has been spent to know
something of the philosophy of life,
disease, cause and cure.*

W. R. LAUGHLIN.

Copyright, 1899, by W. R. Laughlin.

42039

POOR HUMANITY.

The following poetry was found in the pocketbook of the late G. H. Laughlin.

More than half a century since the following lines were found in the Royal College of Surgeons, London, beside a skeleton, remarkable for its symmetry of form. They were subsequently published in the *London Morning Chronicle*, and a vain effort made to ascertain the author, even offering a reward of fifty guineas.

"Behold this ruin! 'Twas a skull
Once of ethereal spirit full.
This narrow cell was life's retreat,
This space was thought's mysterious seat.
What beauteous visions filled this spot
With dreams of pleasures long forgot!
Nor hope, nor joy, nor love, nor fear,
Have left one trace of record here.

"Beneath this moulding canopy
Once shone the bright and busy eye.
But start not at the dismal void!
If social love that eye employed;
If with no lawless fire it gleamed;
But thro' the dews of kindness beamed—
That eye shall be forever bright,
When sun and stars are sunk in night.

"Within this hollow cavern hung
The ready, swift and tuneful tongue.
If falsehood's honey it disdained,
And when it could not praise was chained;
If bold in virtue's cause it spoke,
Yet gentle concord never broke—
That silent tongue shall plead for thee,
When time unveils eternity.

"Say, did these fingers delve the mine,
Or with the envied ruby shine?
To hew the rock or wear the gem,
Can little now avail to them.
But if the page of truth they sought,
Or comfort to the mourner brought—
These hands a richer meed shall claim
Than all who wait on weal or fame

"Avails it whether bare or shod,
These feet the path of duty trod?
If from the bowers of ease they fled,
To seek affliction's humble shed;
If grandeur's guilty bribe they spurned,
And home to virtue's cot returned—
These feet with angel's wings shall rise,
And tread the palace of the skies."

He who every morning plans the transactions of the day, and follows out that plan, carries on a thread which will guide him through the labyrinth of the most busy life.—BLAIR.

PREFACE.

THIS book is not intended to take the place of any standard text-book in anatomy but is to be used as an aid for the student. The origin and insertion of the muscles have not been given, as that is out of the province of this book. In preparing this book, several authorities have been consulted, as A. T. Still, Gray's Anatomy, Morris' Anatomy, Gerrish's Anatomy, Century Dictionary, etc.

*Dedicated to him (A. T. Still)
whose life has been spent to know
something of the philosophy of life,
disease, cause and cure.*

W. R. LAUGHLIN.

Copyright, 1899, by W. R. Laughlin.

42039

Contents.

Explanatory terms.....	4-9
An Explanation of the Upper Extremity.....	9-32
An Explanation of the Lower Extremity.....	32-60
Questions and Answers on Trunk and Head.....	61-94
Questions and Answers on the Viscera—	
Sub-division—Alimentary Canal.....	94-115
Subdivision—The Organs of Voice and Respiration.....	116-127
Subdivision—Urinary System.....	128-135
Subdivision—Spinal Cord and Brain.....	136-147
Miscellaneous.....	148-150

ANATOMY.

Anatomy is concerned with the form and structure and connections of the parts of the body. It has the following divisions:

1. Osteology, the anatomy of bones
2. Syndesmology, of the joints.
3. Myology, of the muscles.
4. Angiology, of the vessels.
5. Neurology, of the nerves.
6. Splanchnology, of viscera.
7. Adenology, of the glands.
8. Dermatology, of the skin.
9. Genesiology, of the generative organs.

Aponeurosis (ap''-ō-nu-ro'-sis); pl. Aponeuroses (sez) is the end of a muscle where it becomes a tendon.

In Anat., any fascia or fascial structure; especially the tendon of a muscle when broad, thin, flat and of a glistening whitish color, or the expansion of a tendon covering more or less of the muscle, or a broad, thin, whitish ligament.

The name was given to these structures when they were supposed to be expansion of nerves, any hard whitish tissue being then considered nervous. In present usage aponeurosis is nearly synonymous with fascia, but is oftener applied to the fascia-like tendons of muscles; as, the aponeurosis of the oblique muscle of the abdomen.

Fascia is a sheet or layer of condensed connective tissue.

The general contour of the body is invested just beneath the skin with a thin light fascia, as distinguished from the thicker, tougher, and more distinctly fibrous deep fascia, which invests and forms sheaths for muscles, and dips down among the muscles and bundles of muscular fibres, forming fibrous intermuscular septa.

Tendon is a band or layer of dense fibrous tissue at the end of a muscle for attachment to a hard part.

A very hard flat tendon is called fascia and aponeurosis. Tendons are directly continuous at one end with the periosteum, at the other end with the fascial tissue which invests the muscle.

A sinus means a cavity in bone or other tissue.

The sinus of the dura mater are synonymous with vein.

All processes on bones are either apophyses or epiphyses.

An apophysis is a process that has grown from the bone, and has no separate ossific center.

An epiphysis has a separate ossific center, and is joined to another bone by cartilage; this cartilage becomes ossified, but this change does not make the epiphysis an apophysis. Once as epiphysis always an epiphysis.

There are 200 bones in the body. They are divided into long, short, flat and irregular ones. 90 of the bones are long ones, and they are found in the extremities. In reality a long bone may not be as long as a flat or irregular bone. The long bones act as levers, and have a medullary canal in the centre of each, a shaft called "diaphysis," and two extremities. They are developed by osseous deposit in cartilage. In each upper extremity there is a clavicle, humerus, ulna, radius, 5 metacarpals, 14 phalanges, making 23 bones in each upper extremity, then in both extremities there are $2 \times 23 = 46$ long bones. In each lower extremity there is a femur, tibia, fibula, 5 metatarsals, 14 phalanges, making 22 long bones in each lower extremity, then in both lower extremities there are $2 \times 22 = 44$ long bones. The 46 long ones in the upper and 44 long ones in the lower extremities make the 90 long bones.

There are 30 short bones. They also are developed by osseous deposit in cartilage, and are found in the extremities, they are found where strength but not much motion is required. In each carpus there are 8 bones, scaphoid, semilunar, cuneiform pisiform, trapezium, trapezoid, os magnum, unciform, making the 8 bones. $2 \times 8 = 16$, the number of short ones in the two upper extremities. In each ankle there are 7 bones, os calcis, astragalus, navicular or scaphoid, cuboid, external cuneiform, middle cuneiform, internal cuneiform, making 7 short bones in each tarsus, then in the two tarsi there are $2 \times 7 = 14$ short bones. Then these 14 short bones in lower extremities, and the 16 short ones in the upper extremities make the $30 = 14 + 16$, short bones.

There are 40 flat bones, all of which are found in the trunk except 4, and these are in the extremities. They are the 2 patellae, 2 scapulae. The flat bones in the trunk protect the viscera. They are developed by osseous deposit in membranes and consist of two dense layers, separated by cellular or cancellated osseous tissue, the diploe. They are the 2 parietal, frontal, occipital in cranium. In face there are 2 nasal, 2 lacrymal, and vomer. In thorax 24 ribs and sternum, then there are 2 innominata, 2 patellae, 2 scapulae, making 40 flat bones in the body. There are 40 irregular bones. They are found in the trunk. They are the 24 vertebrae

sacrum, coccyx, 2 temporal, ethmoid, and sphenoid, and all the bones of the face except 2 nasal, 2 lacrymal and vomer. Then the hyoid.

There are 8 bones in the cranium. 4 flat ones are the frontal, 2 parietal and occipital, 4 irregular ones are 2 temporal, sphenoid and ethmoid.

There are 14 bones in the face, 5 flat ones are 2 nasal, 2 lacrymal and vomer, 9 irregular are 2 superior maxillary, 2 malar, 2 palate, 2 inferior turbinated, and the inferior maxillary.

Then in the cranium and the face together there are $8 + 14$ making 22. In the trunk there are 75 bones. The trunk without the head there are 53 bones which are 24 vertebrae, 24 ribs, sternum, sacrum, coccyx and 2 innominata.

In the extremities there are 124 bones, 64 in the upper and 60 in the lower.

In the pelvis there are 4 bones, 2 innominata, sacrum and coccyx.

Not counting the vertebrae in the cranium there are 33; 7 cervical, 12 thoracic, 5 lumbar, 5 in the sacrum, and 4 in the coccyx.

There are 12 pairs of ribs, 7 of which are true ribs and 5 false, 2 of which are floating.

Besides the 200 bones mentioned there are sesamoid bones which are developed in tendons such as the patellae, but these on account of their size and shape are called flat ones; and the wormian bones, these are found in the sutures of the skull; and the malleus, incus and stapes found in the middle ear. 32 teeth. In each jaw there are 1 pair of canine, 2 pairs of incisors, 2 pairs of bicuspids, 3 pairs of molars.

Name eight eminences on bones.

- 1 Apophyses.
- 2 Condyles.
- 3 Epiphyses.
- 4 Heads—smooth and convex, found in joints.
- 5 Spines—sharp and slender.
- 6 Trochanters—for turning joints.
- 7 Tubercles—small tuberosities.
- 8 Tuberosities—broad prominences.

Name 14 other prominences on bones.

- 1 Azygos—without a fellow.
- 2 Clinoid—like a bed.
- 3 Coracoid—like a crow's beak.
- 4 Coronoid—like a crown.
- 5 Hamular—hook-like.
- 6 Malleolar—mallet-like.

- 7 Mastoid—nipple-like.
 8 Odontoid—tooth-like.
 9 Pterygoid—wing-like.
 10 Rostrum—a beak.
 11 Spinous—thorn-like.
 12 Squamous—scaly, or scale-like.
 13 Styloid—pen-like.
 14 Vaginal—ensheathing.
- Name 5 articular cavities in bones.
 1 Alveolar—socket-like.
 2 Cotyloid—cup-like.
 3 Facet—if smooth, (fr. *facette* dim. of face)
 4 Glenoid—shallow.
 5 Trochlear—pulley-like.
- Name 10 non-articular cavities.
 1 Aqueducts, 6 Foramina,
 2 Canals, 7 Fossae,
 3 Cells, 8 Grooves,
 4 Depressions, 9 Notches,
 5 Fissures, 10 Sinuses.

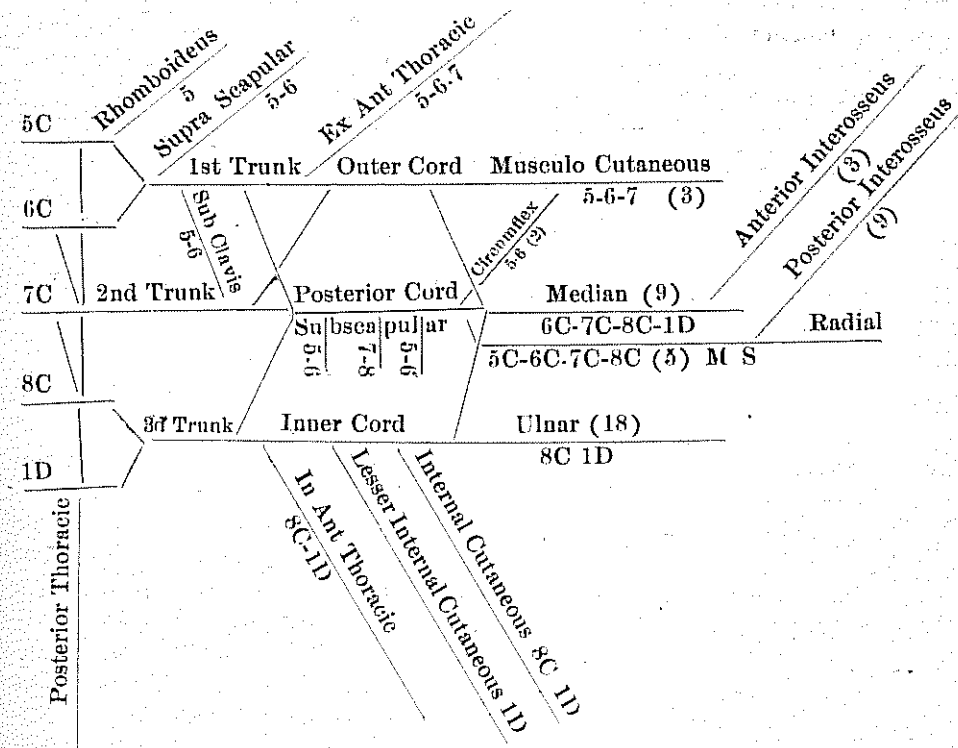
Radius—spoke	Cuboid—cube
Carpus—wrist	Cranium—helmet
Scaphoid—boat	Frontal—forehead
Semilunar—half moon	Occipital—against the head
Cuneiform—wedge-like	Parietal—wall
Pisiform—pea	Ethmoid—sieve
Trapezium—table	Sphenoid—wedge
Trapezoid—on account of shape	Temporal—time
Os Magnum—large bone	Nasal—nose
Unciform—hook.	Superior Maxillary—jaw bone
Meta carpus—beyond the wrist	Inferior Maxillary—mandible
Phalanges—fingers and toes	Lachrymal—tear
Pelvis—basin	Malar—cheek
Femur—thigh	Palate—palate
Patella—small pan	Turbinated—whirl
Tibia—flute	Vomer—ploughshare
Fibula—clasp	Vertebra—to turn
Obturator—closed	Sternum—chest
Thyroid—shield	Thorax—breast plate
Glenoid—shallow	Sacrum—sacred

Cotyloid—cup-like	Coccyx—cuckoo
Tarsus—ankle	Innominata—without a name
Os Calcis—heel	Clavicle—key
Astragalus—die	Scapula—spade
Navicular or scaphoid—boat	Humerus—arm
Cuneiform—wedge-like	Ulna—elbow

AN EXPLANATION OF THE UPPER EXTREMITY.

A plexus is a net work. The Brachial Plexus is a network of nerves situated in the axilla. It is called brachial because its branches supply the muscles of the arm, or brachium.

BRACHIAL PLEXUS.



The Brachial Plexus is formed by the anterior branches of the 5-6-7 8C and first D nerves. The 5th and 6th unite to make first trunk, 7 continues as the second trunk. The anterior of 8C and 1D make 3rd trunk. Each

trunk divides into an anterior and a posterior division. The anterior divisions of first and second trunk make the outer cord. The anterior of third one makes inner cord. The posterior of all three trunks make posterior cord. They are called outer, inner and posterior cords because they are external, internal and posterior to the second part of the axillary artery. The outer cord gives off the ex., ant., thoracic nerve and continues as the musculo cutaneous. A branch from the inner cord and a branch from the outer cord make the median nerve. The figures 6-7-8C and 1D on the median nerve mean that the fibres in the median may be traced to the 6-7-8C and 1D nerve roots. The figure (9) in parenthesis means that the median nerve supplies 9 muscles. The other nerves in similar manner.

There are thirty-one spinal nerves on each side of the spinal column, making thirty-one pairs of spinal nerves. Each nerve has two roots, an anterior one which is motor, a posterior one which is sensory. The two roots unite to form the nerve which then contains both motor and sensory fibres. Each nerve as it leaves the foramen divides into an anterior and a posterior division.

The rule is this—that the anterior branches are larger than the posterior branches in all cases except the first and second cervical nerves. The posterior branches divide into an internal and external division in all cases except first cervical, fourth and fifth sacral and the coccygeal nerves. The posterior nerve roots are larger than the anterior roots with the single exception of the first cervical. They are from one and a half to three times as large.

IN FOREARM.

There are twenty muscles in the forearm, eight in the anterior (radio ulnar) region arranged in four layers; in the first layer there are four—the Pronator radii teres, Flexor carpi radialis, Palmaris longus and Flexor carpi ulnaris. The first three of these are supplied by the median nerve, which comes from the outer and inner cords of the brachial plexus and its fibres may be traced to the 6th, 7th, 8th cervical and 1st dorsal nerves. The Flexor carpi ulnaris is supplied by the ulnar nerve, which comes from inner cord—its fibres may be traced to 8th C and 1st dorsal nerves.

In the second layer there is one muscle, the Flexor sublimis digitorum. It is supplied by the median nerve. In the third layer there are two muscles, Flexor longus pollicis and the Flexor profundus digitorum. The first is supplied by the anterior interosseus, which is a branch of the median from 8 C and 1 D. The second one by the anterior interosseus and the ulnar. In the fourth layer there is one muscle, the Pronator quadratus, and it is supplied by the anterior interosseus nerve. In the radial region

there are three, the Brachio-radialis (Supinator longus); Extensor carpi radialis longior; and the Extensor carpi radialis brevior. The first two are supplied by the musculo-spiral nerve which comes from 5th, 6th, 7th and 8th cervical nerves. The last one by the posterior interosseus nerve which is a branch of the musculo-spiral nerve, and comes from 6th and 7th cervical nerves. In the posterior radio ulnar region there are nine muscles, four in the superficial layer and five in the deep layer.

The four in the superficial layer are the Extensor communis digitorum; Extensor minimi digiti; Extensor carpi ulnaris, and the Anconeus. The first three are supplied by the posterior interosseus nerve, the Anconeus by the musculo-spiral nerve. The five muscles in the deep layer are supplied by the posterior interosseus—they are the Supinator brevis, Extensor ossis metacarpi pollicis, Extensor brevis pollicis, Extensor longus pollicis, and the Extensor indicis.

THE HAND.

In the hand there are twenty muscles, when a part of the Flexor brevis pollicis is called the Abductor obliquus pollicis. The muscles of the thumb are five in number, viz.: Abductor pollicis; Opponens (flexor ossis metacarpi) pollicis; Flexor brevis pollicis; Adductor obliquus pollicis and the Adductor transversus pollicis. The first two get the median nerve. The third one gets both the median and the ulnar nerves, while the last two get the ulnar nerve.

On the ulnar side of the hand there are the Palmaris brevis and the three muscles of the little finger, viz.: the Abductor minimi digiti; the Flexor brevis minimi digiti; and the Opponens (Flexor ossis metacarpi) minimi digiti. All these muscles are supplied by the ulnar nerve.

In the middle palmar region there are four Lumbricales; four Dorsal interossei, and three Palmar interossei. The two outer Lumbricales are supplied by the median nerve, the two inner ones and the seven interossei by the ulnar nerve.

QUESTIONS AND ANSWERS ON UPPER EXTREMITY.

1 Bound the Axilla.

The Axilla is in the form of a pyramid, and is situated between the upper and lateral part of the chest and the inner side of the arm. Its apex, which is directed upward toward the root of the neck, corresponds to the interval between the first rib, the upper part of scapula, and the clavicle, through which the axillary vessels and nerves pass. The base is directed downward, and is formed by integument and fascia extending between the lower border of Latissimus dorsi behind; and Pectoralis major

in front; it is broad internally at the chest, but narrow externally at the arm. The anterior boundary is formed by the Pectoralis major and minor muscles. The posterior boundary which extends a little lower than the anterior one is formed by the Sub-scapularis above, and the Teres major and Latissimus dorsi below. On the inner side are the first four ribs and the corresponding inter-costal muscles, and part of the Serratus Magnus. The outer side which is narrow is bounded by the humerus, the Coraco-brachialis and Biceps muscles.

2 Bound the Quadrilateral Space.

It is bounded above by the Teres minor, below by the Teres major, on the outer side by the humerus, on the inner side by the long head of Triceps.

3 What pierces the Costo-coracoid Membrane?

Two arteries, two nerves and two veins. The arteries are the superior thoracic and acromial thoracic. The nerves are the external and internal anterior thoracic. The veins are the acromial thoracic and the cephalic.

4 Describe the Costo-coracoid Membrane.

The fascia covering the Subclavius muscles extends downward until it reaches the Pectoralis minor, here it divides and covers this muscle. It extends toward the sternum and outward over the axilla. This fascia is called the costo-coracoid membrane. The outer portion is thicker than the other portion and is called the costo-coracoid ligament.

5 What structures lie in the Axilla?

Axillary vessels, brachial plexus, branches of intercostal nerves, lymphatic glands, all connected by a quantity of fat and loose areolar tissue.

6 What structures pass through the Quadrilateral Space?

The posterior circumflex artery and the circumflex veins and nerve.

7 Describe the brachial plexus.

See page 9.

8 What nerves branch from each cord?

See page 9.

9 What and how many muscles are supplied by the musculo-cutaneous?

The musculo-cutaneous supplies three muscles, the Coraco-brachialis, Brachialis anticus and Biceps.

10 What and how many muscles are supplied by the median?

The median nerve goes to nine muscles; the Pronator radii teres, Flexor carpi radialis, Palmaris longus, Flexor sublimus digitorum (perforatus), the two outer Lumbricales, Abductor pollicis, Flexor brevis pollicis,

and the Opponens (Flexor ossismetacarpi) pollicis.

11 What and how many muscles are supplied by the circumflex?

Two—Teres minor and Deltoid.

12 What and how many muscles are supplied by the musculo-spiral?

The musculo-spiral supplies five muscles. The Triceps, Brachialis anticus, Supinator longus (Brachio-radialis) Extensor carpi radialis longior and Anconeus. If we substitute Deltoid for Anconeus will have the five muscles attached to the external inter-muscular septum.

13 What and how many muscles are supplied by the ulnar?

The ulna goes to eighteen muscles. The Flexor carpi ulnaris, Flexor profundus digitorum, two inner Lumbricales, Adductor obliquus pollicis, and Adductor transversus pollicis, Flexor brevis pollicis, Abductor minimi digiti, Flexor brevis minimi digiti, Opponens (Flexor ossis metacarpi) minimi digiti, the seven Interossei and the Palmaris brevis.

14 What and how many muscles are supplied by the Subscapular nerves?

The Subscapular nerves supply three muscles. The Subscapularis muscle gets the first and third nerves. The Latissimus dorsi gets the middle or long Subscapular nerve, and the Teres major gets the third Subscapular nerve.

15 The Rhomboid nerves come from which one?

From the fifth cervical nerve.

16 The Posterior Thoracic comes from which one?

From 5th, 6th, 7th cervical nerves.

17 What is another name for this nerve?

External respiratory of Bell.

18 The Supra-scapular comes from which ones?

From 5th and 6th cervical nerves.

19 Give the nerve supply of integument of hand.

All the integument on the ulnar side of the middle line of the ring finger on both palmar and dorsal surfaces of the hand is supplied by the ulnar nerve. All on the radial side of this line on palmar surface is supplied by the median, on the dorsal surface by the radial. The radial nerve extends to base of the thumb nail, to the distal interphalangeal joint of index, and not quite to the proximal interphalangeal joint of middle finger, and send a few twigs to the skin of the metaphalangeal articulation of ring finger. The parts of the dorsal of the thumb, index, middle and ring fingers not supplied by the radial get the median.

20 Give the nerve supply of Lumbricales.

Two radial get the median, two ulnar get the ulnar.

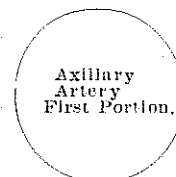
21 Give the nerve supply of Interossei.

- They all get the ulnar.
- 22 Group the muscles on forearm; give nerve supply.
See page 10.
- 23 What muscles are attached to the External Lateral Ligament?
Supinator brevis and Extensor carpi radialis brevis.
- 24 What muscle is attached to the Internal Lateral Ligament?
Flexor sublimis digitorum.
- 25 What muscles are attached to the Internal Inter-muscular Septum?
There are three—the Coraco-brachialis, Brachialis anticus and Triceps, sometimes a fourth one, the Pronator radii teres.
- 26 What muscles are attached to the External Inter-muscular Septum?
See answer to question 12.
- 27 What three muscles are attached to the common aponeurosis?
The Extensor carpi ulnaris, Flexor carpi ulnaris and Flexor profundus digitorum.
- 28 What passes under the Anterior Annular Ligament?
Tendons of the Flexor sublimis and Profundus digitorum, the Flexor longus pollicis and the median nerve.
- 29 What passes through the Anterior Annular Ligament?
Flexor carpi radialis.
- 30 What passes over the Anterior Annular Ligament?
The ulnar vessels and nerve and the cutaneous branches of median and ulnar nerves.
- 31 What muscles are attached to Anterior Annular Ligament?
Abductor pollicis, Opponens (Flexor ossis metacarpi) pollicis, Flexor brevis pollicis, Adductor obliquus pollicis, making all the muscles of the thumb, except Adductor transversus pollicis. The Palmaris brevis, Flexor brevis minimi digiti, Opponens (Flexor ossis metacarpi) minimi digiti, making all the muscles of the little finger except Abductor minimi digiti. Also Palmaris longus and the Flexor carpi ulnaris.
- 32 What muscles pass through the six openings in Posterior Annular Ligament?
Through the first opening passes the Extensor ossis metacarpi pollicis and Extensor brevis pollicis. (2) Extensor carpi radialis longior and brevior. (3) Extensor longus pollicis. (4) Extensor communis digitorum and Extensor indicis. (5) Extensor minimi digiti. (6) Extensor carpi ulnaris.
- 33 Give the three divisions of Axillary Artery.
The Pectoralis minor passes over the middle of the axillary artery, thus dividing it into three portions.
- 34 Give the relations of the first part Axillary Artery.

In Front.

Pectoralis major.
Costo-coracoid membrane.
External anterior thoracic nerve.
Acromio thoracic and Cephalic veins.

Outer Side.
Brachial plexus.



Inner Side.
Axillary vein.

Behind.

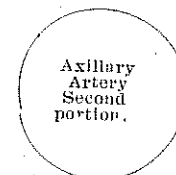
First Intercostal space, and Intercostal muscle.
Second and third serrations of Serratus magnus.
Posterior and internal anterior thoracic nerve.

- 35 Give the relations of the second part Axillary Artery.

In Front.

Pectoralis major and minor.

Outer Side.
Outer cord of plexus.



Inner Side.
Axillary vein.
Inner cord of plexus.

Behind.

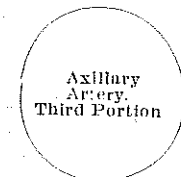
Subscapularis.
Posterior cord of plexus.

- 36 Give the relations of the third part Axillary Artery?

In Front.

Integument and fascia.
Pectoralis major.
Inner head of median nerve.

Outer Side.
Coraco-brachialis.
Median nerve.
Musculo cutaneous nerve.



Inner Side.
Ulnar nerve.
Internal cutaneous nerves.
Axillary veins.

Behind.

Subscapularis.
Tendons of Latissimus dorsi and Teres major.
Musculo-spiral and circumflex nerves.

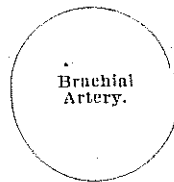
37 Give the branches of each part of Axillary?

- Branches of the first part { Superior Thoracic.
Acromial Thoracic.
- Branches of the second part { Long Thoracic.
Alar Thoracic.
- Branches of the third part { Subscapular.
Anterior Circumflex.
Posterior Circumflex.

38 Give relations of Brachial Artery?

In Front.
Integument and fascia.
Bicipital fascia, median basilic vein.
Median nerve.

Outer Side.
Vena comes.
Median nerve (above).
Coraco-brachialis.
Biceps.



Inner Side.
Vena comes.
Internal cutaneous and ulnar nerve.
Median nerve (below).
Basilic vein (upper half).

Behind.
Triceps.
Musculo-spiral nerve.
Superior profunda artery.
Coraco-brachialis (insertion).
Brachialis anticus.

39 Name the branches of Brachial Artery?

Superior profunda, Inferior profunda, Nutrient, Anastomotica magna, Muscular.

40 Describe Cervical Plexus?

Cervical plexus is formed by the anterior divisions of the four upper cervical nerves. It is situated opposite the four upper cervical vertebrae, resting upon the Levator anguli scapulae and Scalenus medius muscles and covered in by the Sterno-cleido-mastoid. Its branches may be divided into "superficial" and "deep," which may be thus arranged:

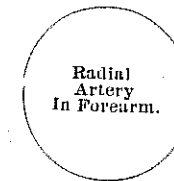
- Superficial { Ascending { Occipitalis minor.
Auricularis magnus.
Superficialis colli.
- Descending. { Supra-claviular { Supra-sternal.
Supra-claviular.
Supra-acromial.

- Deep. { Internal { Communicating.
Muscular.
Communicans hypoglossi.
Phrenic.
- External { Communicating.
Muscular.

41 Give the relations of Radial Artery.

In Front.
Skin, superficial and deep fascia.
Supinator longus.

Inner Side.
Pronator radii teres.
Flexor carpi radialis.



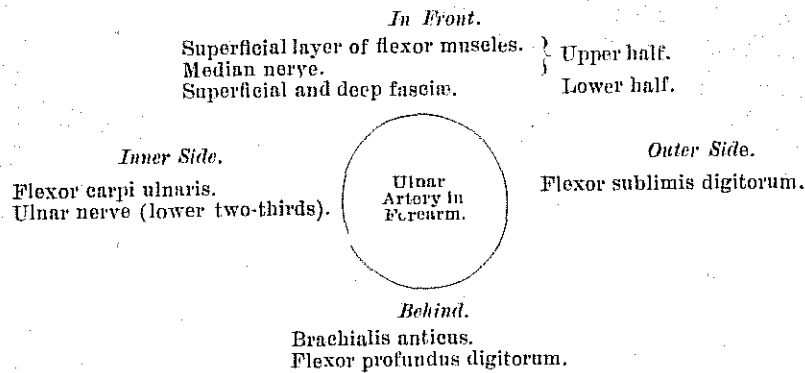
Outer Side.
Supinator longus.
Radial nerve (middle third).

Behind.
Tendon of Biceps.
Supinator brevis.
Flexor sublimis digitorum.
Pronator radii teres.
Flexor longus pollicis.
Pronator quadratus.
Radius.

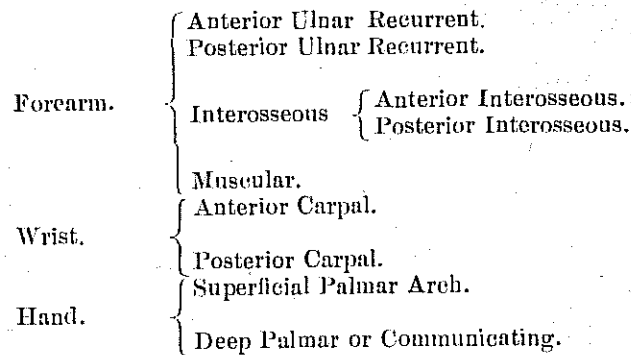
42 Name the branches of the Radial artery?

- In the Forearm { Radial Recurrent.
Muscular.
Anterior carpal.
Superficialis volae.
- Wrist { Posterior carpal.
Metacarpal.
Dorsalis pollicis.
Dorsalis indicis.
- Hand { Princeps pollicis.
Radialis indicis.
Perforating.
Interosseous.
Palmar recurrent.

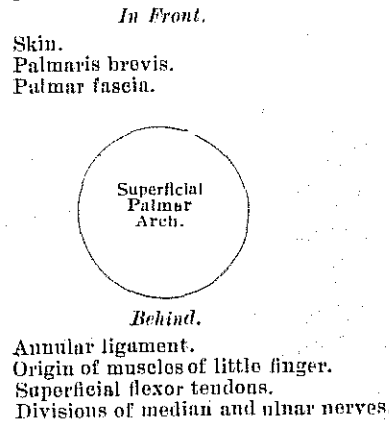
43 Give relations of Ulnar Artery?



44 Give the branches of Ulnar Artery?



45 Give relations of Superficial Palmar Arch.



46 What pierces Coraco-brachialis?

Musculo-cutaneous nerve.

47 What passes between the two heads of the Pronator radii teres?

Median nerve.

48 What passes between the two heads of Flexor carpi ulnaris?

Ulnar nerve and posterior ulnar recurrent artery.

49 What pierces the Internal intermuscular septum?

The ulnar nerve and the inferior profunda and anastomotic arteries.

50 What pierces the External intermuscular septum?

Musculo-spiral nerve and superior profunda artery.

51 Describe the Cubital fossa?

The Cubital fossa is triangular in shape and situated at the bend of the elbow. It is bounded externally by the Supinator longus, internally by the Pronator radii teres, above by an imaginary line connecting these two muscles. Its floor is formed by the Brachialis anticus and Supinator brevis. It is called cubital because the arm from the elbow to the tips of the fingers was used as a unit of measure called a cubit.

51a What passes through the Cubital fossa?

It contains the brachial artery with its accompanying veins, the radial and ulnar arteries, the median and musculo-spiral nerves, and the tendon of the Biceps.

52 Name the bones of the Carpus?

Those of the upper row are scaphoid, semilunar, cuneiform and pisiform; those of the lower row are trapezium, trapezoid, os magnum and unciform.

53 Give articulation of each bone?

Scaphoid articulates with five bones, radius above, trapezium and trapezoid below, os magnum and semilunar internally.

The semilunar articulates with five bones; the radius above, os magnum and unciform below, scaphoid and cuneiform on either side.

Cuneiform articulates with three bones, semilunar externally, pisiform in front, unciform below, and with triangular interarticular fibro-cartilage which separates it from the lower end of the ulna.

Pisiform articulates with one bone, the cuneiform.

Trapezoid articulates with four bones, the scaphoid above, second metacarpal below, trapezium externally, os magnum internally. Os magnum articulates with seven bones, scaphoid and semilunar above, second, third and fourth metacarpal below, trapezoid on the radial side, and the unciform on the ulnar side.

Unciform with five, semilunar above, fourth and fifth metacarpal below.

** Trapezium articulates with four bones: the scaphoid above, trapezoid and second metacarpal internally, first metacarpal below.*

low, cuneiform internally, and os magnum externally.

54 Which ones have muscles attached to them?

The pisiform in the first row, and all in the second row except the trapezoid have muscles attached to them. The scaphoid and the trapezoid often have muscles attached to them.

55 What muscles are attached to the Trapezium?

It has three muscles attached to it, the Flexor brevis pollicis, Flexor ossis metacarpi pollicis, and Abductor pollicis.

56 What muscles are attached to the Os magnum?

Os magnum has one muscle attached, the Adductor obliquus pollicis, which is sometimes called a part of the Flexor brevis pollicis.

57 What muscles are attached to the Unciform?

The unciform has three muscles attached, all Flexor muscles, the Flexor carpi ulnaris, Flexor ossis metacarpi minimi digiti, and the Flexor brevis minimi digiti.

58 What muscles are attached to the Pisiform?

The Pisiform has two muscles attached, the Flexor carpi ulnaris and the Abductor minimi digiti and to the anterior annular ligament.

59 What muscles are attached to the Metacarpal (each bone)?

To the fourth three: the Third and Fourth dorsal and Second palmar interosseous.

To the metacarpal bone of the thumb, four: the Flexor ossis metacarpi pollicis, Flexor brevis pollicis, Extensor ossis metacarpi pollicis, and First dorsal interosseous.

To the fifth, five: the Extensor carpi ulnaris, Flexor carpi ulnaris, Flexor ossis metacarpi minimi digiti, Fourth dorsal and Third palmar interosseous.

To the third, six: the Extensor carpi radialis brevis, Flexor carpi radialis, Adductor transversus pollicis, Adductor obliquus pollicis, and Second and Third dorsal interosseous.

To the second metacarpal bone, seven: the Flexor carpi radialis, Extensor carpi radialis longior, Adductor transversus pollicis, Adductor obliquus pollicis, First and Second dorsal interosseous, and First palmar interosseous.

60 What muscles are attached to the Phalanges of the thumb?

To the base of the first phalanx of the thumb, five muscles: the Extensor brevis pollicis, Flexor brevis pollicis, Abductor pollicis, Adductor transversus and obliquus pollicis. To the second phalanx, two: the Flexor longus pollicis and the Extensor longus pollicis.

61 What muscles are attached to the Phalanges of the fingers?

To the base of the first phalanx of the index finger, the First dorsal and the First palmar interosseous; to that of the middle finger, the Second and Third dorsal interosseous; to that of the ring finger, the Fourth dorsal and the Second palmar interosseous; and to that of the little finger, the Third palmar interosseous, the Flexor brevis minimi digiti, and Abductor minimi digiti. To the second phalanges, the Flexor sublimis digitorum, Extensor communis digitorum, and, in addition, the Extensor indicis to the index finger, the Extensor minimi digiti to the little finger. To the third phalanges, the Flexor profundus digitorum and Extensor communis digitorum.

62 How many bones in hand?

Twenty-seven in hand.

63 Give ligaments of clavicle.

Anterior and Posterior Sterno-clavicular, Interclavicular, Costo-clavicular (rhomboid), Superior and Inferior Acromio-clavicular, Coraco-clavicular and Interarticular Fibro-cartilage.

64 Give ligaments of scapula.

Coraco-acromial and Transverse.

65 Give ligaments of shoulder.

Capsular, Glenoid, Coraco-humeral, Transverse humeral, long tendon of origin of Biceps.

66 Give the ligaments of elbow.

Anterior, Posterior, Internal lateral and External lateral.

67 Give ligaments of forearm.

Orbicular, Oblique, Interosseous, Anterior radio-ulnar, Posterior radio-ulnar, and Interarticular fibro-cartilage.

68 Give ligaments of wrist.

External lateral, Internal lateral, Anterior, Posterior.

69 What kind of joint is Sterno-clavicular?

Arthrodiar.

70 What kind of joint is Acromio-clavicular?

Arthrodiar.

71 What kind of joint is shoulder?

Enarthrodial.

72 What kind of joint is elbow?

Ginglymus.

73 What kind of joint is wrist?

Condyloid

74 From what do cords of Brachial plexus take names?

From their position to the second part of the Axillary artery.

- 75 What converts the Supra-scapular notch into a foramen?
Transverse ligament.
- 76 What vessels pass above the Transverse ligament?
Suprascapular vessels.
- 77 What structure passes below the Transverse ligament?
Suprascapular nerve.
- 78 What structures go through the Musculo-spiral groove?
Musculo-spiral nerve and Superior profunda artery.
- 79 What holds the arm in position?

The capsular, glenoid, coraco-humeral ligaments; atmospheric pressure; the Deltoid, Supraspinatus, Infraspinatus, Teres minor, ^{axillary} Subscapularis, Latissimus dorsi, Pectoralis major, Biceps, Triceps, Coraco-brachialis.

- 80 What forms the Superficial palmar arch?

The Superficial ulnar and the Radialis indicis or the Superficialis volæ.

- 81 What forms the deep palmar arch?

The deep palmar or communicating branch of the ulnar passes deeply inward between the Abductor minimi digiti and Flexor brevis minimi digiti near their origin; it anastomoses with the termination of the radial artery, completing the deep palmar arch.

- 82 Give the Anastomosis of elbow joint.

The vessels engaged in this anastomosis may be conveniently divided into those situated *in front* and *behind* the internal and external condyles. The branches anastomosing *in front* of the internal condyle are the anastomotica magna, the anterior ulnar recurrent and the anterior terminal branch of the inferior profunda. Those *behind* the internal condyle are the anastomotica magna, the posterior ulnar recurrent, and the posterior terminal branch of the inferior profunda. The branches anastomosing *in front* of the external condyle are the radial recurrent and one of the terminal branches of the superior profunda. Those *behind* the external condyle (perhaps more properly described as being situated between the external condyle and the olecranon) are the anastomotica magna, the interosseous recurrent, and one of the terminal branches of the superior profunda. There is also a large arch of anastomosis above the olecranon, formed by the interosseous recurrent, joining with the anastomotica magna and posterior ulnar recurrent.

- 83 How many muscles are attached to the clavicle?
Six and often seven.
- 84 How many muscles are attached to the scapula?
Seventeen.

- 85 How many muscles are attached to the humerus?
Twenty-four, often 25.
- 86 How many muscles are attached to the ulna?
Fourteen.
- 87 How many muscles are attached to the radius?
Nine.
- 88 Name the muscles lacking origin or insertion into bone.
The Lumbricales and Palmaris brevis.
- 89 Describe the deep fascia of arm.

The deep fascia of the arm is continuous with that covering the shoulder and front of the great Pectoral muscle by means of which it is attached, above, to the clavicle, acromion, and spine of the scapula; it forms a thin, loose, membranous sheath investing the muscles of the arm, sending down septa between them, and composed of fibres disposed in a circular or spiral direction, and connected together by vertical and oblique fibres. It differs in thickness at different parts, being thin over the Biceps, but thicker where it covers the Triceps, and over the condyles of the humerus: it is strengthened by fibrous aponeuroses, derived from the Pectoralis major and Latissimus dorsi on the inner side and from the Deltoid externally. On either side it gives off a strong *intermuscular septum*, which is attached to condyloid ridge and condyle of the humerus. These septa serve to separate the muscles of the anterior from those of the posterior brachial region. The external intermuscular septum extends from the lower part of the external bicipital ridge, along the external condyloid ridge, to the outer condyle; it is blended with the tendon of the Deltoid, gives attachment to the Triceps behind, to the Brachialis anticus, Supinator longus, and Extensor carpi radialis longior, in front; and is perforated by the musculo-spiral nerve and superior profunda artery. The internal intermuscular septum, thicker than the preceding, extends from the lower part of the internal lip of the bicipital groove below the Teres major, along the internal condyloid ridge to the inner condyle; it is blended with the tendon of the Coraco-brachialis, and affords attachment to the Triceps behind, and the Brachialis anticus in front. It is perforated by the ulnar nerve and the inferior profunda and anastomotic arteries. At the elbow the deep fascia is attached to all the prominent points around the joint—viz, the condyles of the humerus and the olecranon process of the ulna—and is continuous with the deep fascia of the forearm. Just below the middle of the arm, on its inner side, in front of the internal intermuscular septum, is an oval opening in the deep fascia which transmits the basilic vein and some lymphatic vessels. On the removal of this fascia the muscles, vessels and nerves of the an-

terior humeral region are exposed.

90 Describe the deep fascia of forearm.

The deep fascia of the forearm, continuous above with that enclosing arm, is a dense, highly glistening aponeurotic investment, which forms a general sheath enclosing the muscles in this region; it is attached, behind, to the olecranon and posterior border of the ulna, and gives off from its inner surface numerous intermuscular septa, which enclose each muscle separately. Below it is continuous in front with the anterior annular ligament, and forms a sheath for the tendon of the Palmaris longus muscle, which passes over the annular ligament to be inserted into the palmar fascia. Behind, near the wrist-joint, it becomes much thickened by the addition of many transverse fibres, and forms the posterior annular ligament. It consists of circular and oblique fibres, connected together by numerous vertical fibres. It is much thicker on the dorsal than on the palmar surface, and at the lower than at the upper part of the forearm, and is strengthened by tendinous fibres derived from the Brachialis anticus and Biceps in front, and from the Triceps behind. Its inner surface gives origin to muscular fibres, especially at the upper part of the inner and outer sides of the forearm, and forms the boundaries of a series of conical-shaped cavities, in which the muscles are contained. Besides the vertical septa separating each muscle, transverse septa are given off both on the anterior and posterior surfaces of the forearm, separating the deep from the superficial layer of muscles. Numerous apertures exist in the fascia for the passage of vessels and nerves; one of these, of large size, situated at the front of the elbow, serves for the passage of a communicating branch between the superficial and deep veins.

91 Describe the Anterior and Posterior Annular ligaments.

The Anterior Annular ligament is a strong, fibrous band which arches over the carpus, converting the deep groove on the front of the carpal bones into a canal, beneath which pass the flexor tendons of the fingers. It is attached internally to the pisiform bone and unciform process of the unciform bone, and externally to the tuberosity of the scaphoid and to the inner part of the anterior surface and the ridge on the trapezium. It is continuous, above, with the deep fascia of the forearm, of which it may be regarded as a thickened portion, and, below, with the palmar fascia. It is crossed by the ulnar vessels and nerve and the cutaneous branches of the median and ulnar nerves. At its outer extremity is the tendon of the Flexor carpi radialis, which lies in the groove on the trapezium between the attachments of the annular ligament to the bone. It has inserted into its anterior surface the tendon of the Palmaris longus and part of the tendon

of the Flexor carpi ulnaris, and has arising from it, below, the small muscles of the thumb and little finger. Beneath it pass the tendons of the Flexor sublimis and profundus digitorum, the Flexor longus pollicis, and the median nerve.

The Posterior Annular ligament is a strong fibrous band extending transversely across the back of the wrist, and consisting of the deep fascia of the back of the forearm, strengthened by the addition of some transverse fibres. It forms a sheath for the extensor tendons in their passage to the fingers, being attached, internally, to the styloid process of the ulna, the cuneiform and pisiform bones; externally to the margin of the radius; and, in its passage across the wrist, to the elevated ridges on the posterior surface of the radius. It presents six compartments for the passage of tendons, each of which is lined by a separate synovial membrane. These are, from without inward—1. On the outer side of the styloid process, for the tendons of the Extensor ossis metacarpi pollicis, Extensor brevis pollicis; 2, Behind the styloid process, for the tendons of the Extensor carpi radialis longior and brevior; 3, About the middle of the posterior surface of the radius, for the tendon of the Extensor longus pollicis; 4, To the inner side of the latter, for the tendons of the Extensor communis digitorum and Extensor indicis; 5, Opposite the interval between the radius and ulna, for the Extensor minimi digiti; 6, Groove in the back of the ulna, for the tendon of the Extensor carpi ulnaris. The synovial membranes lining these sheaths are usually very extensive, reaching from above the annular ligament, down upon the tendons for a variable distance on the back of the hand.

92 Describe synovial membranes of wrist.

The synovial membranes of the wrist and carpus are five in number. The *first*, the *membrana sacciformis*, passes from the lower end of the ulna to the sigmoid cavity of the radius, and lines the upper surface of the interarticular fibro-cartilage. The *second* passes from the lower end of the radius and interarticular fibro-cartilage above to the bones of the first row below. The *third*, the most extensive, passes between the contiguous margins of the two rows of carpal bones—between the bones of the second row to the carpal extremities of the four inner metacarpal bones. The *fourth*, from the margin of the trapezium to the metacarpal bone of the thumb. The *fifth*, between the adjacent margins of the cuneiform and pisiform bones.

93 Name principal Flexor and Extensor muscles of hand.

Flexor sublimis digitorum, Flexor profundus digitorum, and Extensor communis digitorum.

- 94 What muscles attached to greater tuberosity?
Supraspinatus, Infraspinatus and Teres minor.
- 95 What muscle attached to the lesser tuberosity?
Subscapularis.
- 96 The pulse is felt between what two tendons?
Supinator longus and Flexor carpi radialis.
- 97 How does the radial artery get into the palm of the hand?
Between the two heads of the first Dorsal interosseous.
- 98 How many muscles from elbow to wrist?
Twenty. See page 10.
- 99 What nerve lies in the substance of the Supinator brevis?
Posterior interosseous.
- 100 Pronators and flexors are attached to which condyle of humerus?
Inner condyle.
- 101 Extensors and supinators to which condyle?
External condyle.
- 102 What muscles attached to external or anterior bicipital ridge?
Pectoralis major.
- 103 To the posterior or internal bicipital ridge?
Teres major.
- 104 What one is inserted in the groove?
Latissimus dorsi.
- 105 The Musculo-spiral nerve divides into what branches?
Posterior interosseous and radial nerves.
- 106 What kind of nerve is the radial?
Purely cutaneous.
- 107 Give Anterior carpal arch.
Anterior carpal from the radial and the anterior carpal from the ulnar unite to make the anterior carpal arch.
- 108 Give Posterior carpal arch.
Posterior carpal from the radial and the posterior carpal from ulnar unite to make posterior carpal arch.
- 109 How does the posterior interosseous artery get to the back of the forearm?
Between the radius and ulna below the oblique ligament and above the interosseous membrane.
- 110 How many muscles in the hand?
See page 11.
- 111 What relation does the posterior interosseous artery bear to the deep layer of muscles of the forearm.

- Between the superficial and deep layers of muscles.
- 112 Describe the humerus.
The humerus has two extremities and a shaft which has three borders, so it is somewhat triangular in shape. The upper extremity has a head which articulates in the glenoid fossa. The head is separated from the two tuberosities by the anatomical neck. The tuberosities join the shaft by the surgical neck. The great tuberosity has three muscles attached to it—Supraspinatus, Infraspinatus and Teres minor. The lesser tuberosity has one, the Subscapularis. Between the tuberosities is the bicipital groove, in which is the long tendon of the Biceps. There are 24 and often 25 muscles attached to the humerus. The lower extremity has two condyles, the inner for the pronators and flexors to be attached, the outer one for supinators and extensors. The olecranon fossa for the olecranon process of ulna, coronoid fossa for coronoid process of ulna, trochlear for articulation with ulna and capitellum for articulation with radius.
- 113 With what does it articulate?
With glenoid cavity of scapula, and the radius and ulna.
- 114 How many and what muscles attached to humerus, ulna and radius?
Three: Pronator radii teres, Flexor sublimis digitorum, Supinator brevis
- 115 What is the longest muscle inserted on the humerus?
Latissimus dorsi.
- 116 What muscles have attachment to both ulna and radius?
Supinator brevis, Flexor sublimis digitorum, Pronator radii teres, Flexor longus pollicis and Pronator quadratus. *Extensor carpi metacarpi pollicis*
- 117 With how many bones does the radius articulate?
With four: humerus, ulna, scaphoid and semilunar.
- 118 With how many bones does the ulna articulate?
With two, radius and humerus.
- 119 What are the two principal veins of the arm?
Cephalic and Basilic.
- 120 Which passes through the Axilla?
The Cephalic pierces the Costo-coracoid membrane, thus it passes in the axilla. The Basilic continues as the Axillary vein, which lies in the Axilla.
- 121 What veins form each?
The Basilic vein is formed by the coalescence of the common ulnar vein with the median basilic. The Cephalic is formed by the median cephalic and the radial.
- 122 What is the longest nerve in the arm?

The Ulnar.

123 How many openings in the capsular ligament of the shoulder joint?

The capsular ligament usually presents three openings; one at its inner side, below the coracoid process, partially filled up by the tendon of the Subscapularis; it establishes a communication between the synovial membrane of the joint and a bursa beneath the tendon of that muscle. The second, which is not constant, is at the outer part, where a communication sometimes exists between the joint and a bursal sac belonging to the Infraspinatus muscle. The third is seen in the lower border of the ligament, between the two tuberosities, for the passage of the long tendon of the Biceps muscle.

124 Where are the greater and lesser sigmoid cavities?

They are on the Ulna.

125 With what does each articulate?

The greater articulates with the humerus, the lesser with the radius.

126 Why is the cephalic vein so called?

Cephalic means, pertaining to the head.

127 Why are the Lymphatics so called?

From *lymph*, meaning water.

128 What is lymph?

Lymph is a colorless or yellow fluid containing a large proportion of water. It resembles blood, when that fluid is deprived of its red corpuscles.

129 What else are lymphatics called?

They are also called Absorbents.

130 What does the lymphatic system include?

It includes lymphatic vessels and gland, and lacteals or chyloferous vessels.

131 Over how much of the body does it extend?

Nearly every part of the body is permeated by a second series of capillaries, closely interlaced with the blood vessels, collectively termed the LYMPHATIC SYSTEM. Their origin is not known, but they appear to form a plexus in the tissues, from which their converging trunks arise. They are composed of minute tubes of delicate membrane, and from their network arrangement they successively unite and finally terminate in two main trunks, called the Great Lymphatic Veins. The lymphatics, instead of commencing on the intestinal walls, as do the lacteals, are distributed through most of the vascular tissues as well as the skin. The lymphatic circulation is not unlike that of the blood; its circulatory apparatus is, however, more delicate, and its functions are not so well understood.

132 How many coats have the lymphatics?

They have three coats, like the arteries and veins. They are transparent.

133 The lymphatic glands of the arm are divided into how many sets?

Two sets: Superficial and deep.

134 The lymphatic vessels how divided?

They are divided into two sets, Superficial and deep.

135 Give blood supply and ossification of clavicle.

The nutrient artery is from the supra-scapular. The acromial end receives branches from the acromial thoracic artery, and twigs from the arteries in the muscles attached to it. Ossification from two centers. The first one appears about the sixth week and the second one about the seventeenth year. Consolidation is complete about the twentieth year.

136 The same of Scapula.

Subscapular artery, and the subscapular branch of supra-scapular enter bone on anterior surface. The supra-scapular fossa, the spine and the infraspinous fossa, and glenoid fossa are supplied by the supra-scapular artery; the infraspinous fossa also gets the dorsal artery, which is a branch of the subscapular of the third part of the axillary. The acromion is supplied by branches from the acromio-thoracic. It ossifies from seven centers.

137 The same of Humerus.

Blood supply is derived from the supra-scapular and the anterior and posterior circumflex. Branches from these arteries enter foramina which cluster around the circumference of the head and tuberosities. At the top of the bicipital groove there is a large nutrient foramen, which transmits a branch from anterior circumflex artery. The nutrient artery of the shaft is derived from a muscular branch of the brachial; it enters the bone near the middle of the inner border, immediately below the insertion of the coracobrachialis and is directed to the distal end. The lower extremity is nourished by numerous twigs derived from anastomatic, superior and inferior profunda and recurrent branches of radial, ulnar and interosseous arteries. Ossification from seven centers.

138 The same of Radius.

The nutrient artery is derived from anterior interosseous trunk; it enters shaft near the middle of anterior surface, and runs towards the proximal end of bone. The head of the bone is supplied by the radial recurrent and interosseous recurrent arteries. The lower end is supplied by anterior and posterior interosseous arteries and numerous twigs from carpal arches. Ossification from three centers.

139 The same of Ulna.

The nutrient vessel enters shaft near the middle of the anterior surface; it is derived from the anterior interosseous trunk, and is directed towards proximal end. The upper extremity receives branches from the anterior and posterior ulnar recurrent and from the interosseous recurrent. The lower end receives twigs from the anterior and posterior interosseous arteries. Ossification from three centers.

140 The same of Carpus.

The arterial twigs to the carpal bones are derived from the anterior and posterior carpal branches of the radial and ulnar arteries. A large branch from the anterior interosseous is also distributed to the carpus, and twigs are furnished to it from the posterior interosseous artery.

Ossification: At birth the carpal elements are cartilaginous, and the nucleus for each bone appears in the following order:

- 1 Magnum—First year.
- 2 Uneiform—Second year.
- 3 Cuneiform—Third year.
- 4 Semilunar—Fourth year.
- 5 Trapezium—Fifth year.
- 6 Scaphoid—Sixth year.
- 7 Trapezoid—Eighth year.
- 8 Pisiform—Twelfth year.

141 The same of Metacarpus.

Blood supply of the first metacarpal bone is derived from the princeps pollicis artery; it enters on the ulnar side, and is directed towards the head of the bone.

For the second metacarpal bone, the nutrient artery is derived from first palmar interosseous. It enters on the ulnar side, and is directed towards the proximal end or base of the bone.

For the third metacarpal bone the nutrient artery is derived from the interosseous; it enters as a rule, on the radial side and is directed towards the base.

For the fourth metacarpal bone the nutrient artery is furnished by the second interosseous; it enters on radial side of shaft, and is directed towards the proximal end.

For the fifth metacarpal bone the nutrient artery is derived from the third interosseous; it enters the shaft on the radial side, and is directed towards the proximal end.

Ossification of each metacarpal bone is from two centers.

142 The same of Phalanges.

Ossification of each phalanx is from two centers.

143 What is the largest nerve of Brachial plexus?

The Musculo-spiral.

144 What separates median basilic vein from brachial artery?

Bicipital fascia.

145 Give another name for Supinator longus.

Brachio-radialis.

146 Give another name for Extensor brevis pollicis.

Extensor primi internodi pollicis.

147 Give another name for Extensor longus pollicis.

Extensor secundi internodi pollicis.

148 Give another name for first dorsal interosseous.

Abductor indicis.

149 { Give Acromial rete.

{ Deep branch of ulna passes between what muscles?

The anterior and posterior circumflex of the third part of axillary, the supra-capular from the thyroid axis, and the acromial branches from the acromo-thoracic of the first part of the axillary make the Acromial rete.

It passes between the Abductor minimi digiti and the Flexor brevis minimi digiti.

150 Describe nails.

A nail, technically called unguis, consists of horny substance, which is condensed and hardened epidermis, the same as that forming the horns, hoofs and claws of various animal. A claw is a sharp curved nail, a hoof is a blunt nail large enough to inclose the end of a digit. The white mark at the base of the human nail is called the lunula. The back part of nail fits behind into a furrow of the dermis and is called its root. The visible part consists of a body, fixed to the dermis beneath (which forms the bed of the nail), and of a free edge. The portion of the corium on which the nail is formed is called the matrix.

151 Give another name for lesser internal cutaneous nerve.

Nerve of Wrisberg.

152 Give another name for the long thoracic artery.

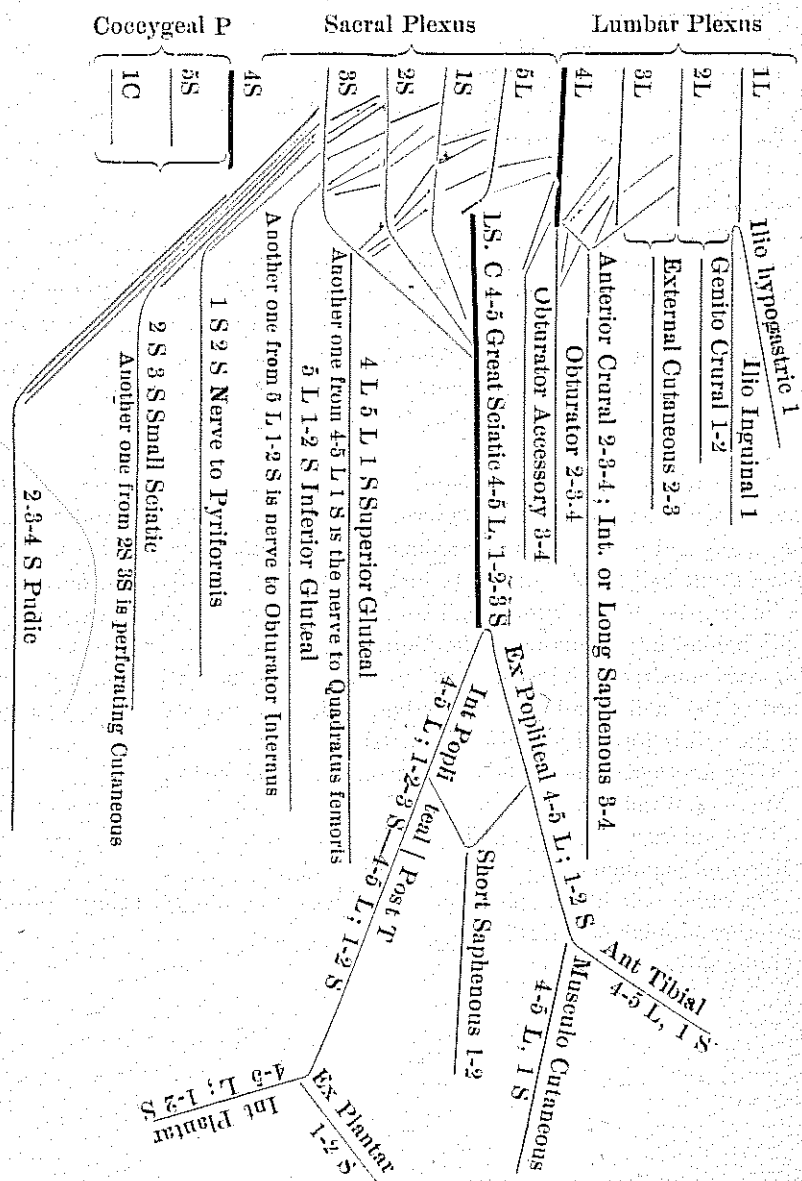
External mammary.

153 On which side of the pisiform bone does the ulnar artery cross the anterior annular ligament?

Outer side.

AN EXPLANATION OF THE LOWER EXTREMITY.

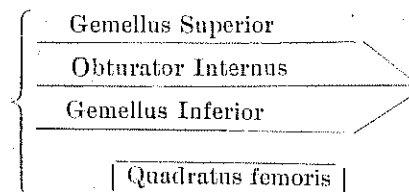
The Lumbar Plexus is made from the anterior branches of the 1-2-3 and part of the 4th lumbar nerves. The remaining part of the fourth nerve and the fifth nerve make the lumbo sacral cord. This cord together with the anterior branches of the 1-2-3 and part of the 4 sacral nerves makes the Sacral Plexus. The remaining part of the 4 nerve with the 5 and the coccygeal make the Coccygeal Plexus. The Lumbo-sacral cord which is made from the 5 lumbar and part of the 4 lumbar nerves belongs to the sacral plexus.



GLUTEAL REGION.

In the gluteal region there are nine muscles, eight of which are attached to the great trochanter—the muscles are the Gluteus maximus, Gluteus medius, Gluteus minimus, Gemellus superior, Gemellus inferior, Obturator externus, Obturator internus, Piriformis and Quadratus femoris. The Gluteus maximus is supplied by the inferior gluteal nerve which comes from the 5L, 1S-2S nerve. The small sciatic also goes to this muscle.

The Gluteus medius and minimus get the superior gluteal nerve, which comes from the 4L, 5L, 1S nerves. The Obturator externus gets the obturator nerve, which comes from 2-3-4L nerves. The Piriformis from 1-2S nerves.



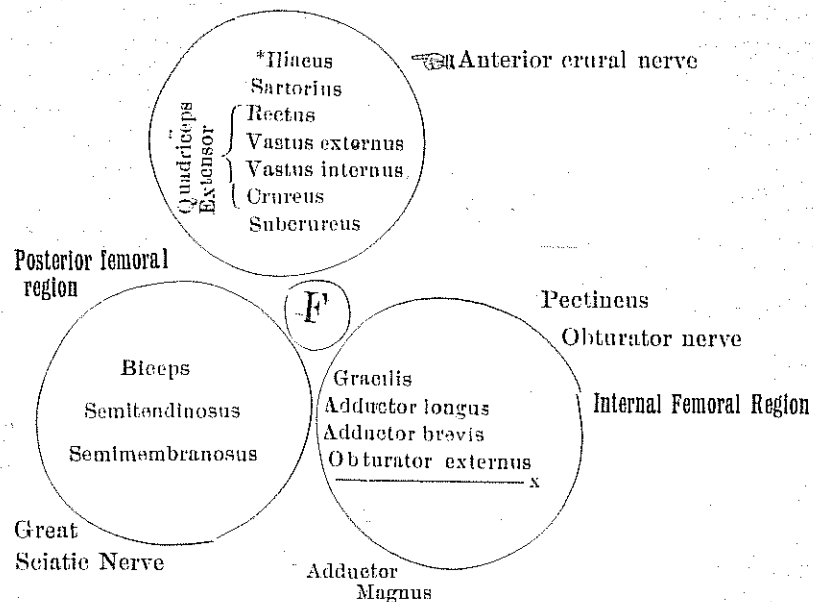
The nerve to Obturator internus comes from 5L, 1 and 2S, and also supplies Gemellus superior. The nerve to Quadratus femoris comes from 4-5L, 1S and also supplies the Gemellus inferior.

FEMORAL REGION.

In the femoral regions there are fifteen muscles. There are seven in the anterior femoral region—Tensor vaginae femoris, Rectus, Vastus externus, Vastus internus, Crureus, Suberureus, Sartorius. All these are supplied by the anterior crural nerve except the first one and in its place is the Iliacus. The anterior crural nerve comes from 2-3-4L nerves. It also helps to supply the Pectineus. In the internal femoral region there are five—Adductor longus, Adductor brevis, Adductor magnus, Gracilis, and Pectineus. All these are supplied by the obturator nerve which comes from 2-3-4L nerves. This nerve also goes to the Obturator externus which is in the gluteal region.

In the posterior femoral region there are three muscles—Biceps, Semitendinosus, Semimembranosus. These muscles are supplied by the great sciatic nerve which comes from 4-5L, 1-2-3S nerves. It also goes to help supply the Adductor magnus.

ANTERIOR FEMORAL REGION.



*This muscle belongs to the deep muscles of the abdomen.

xThe Obturator externus does not belong to this region, but has the same nerve supply. It belongs to the gluteal region. The Pectineus and Adductor magnus are out of the circle to show that they receive another nerve as well as obturator nerve. The Pectineus gets the anterior crural, in addition, and the Adductor magnus gets the great sciatic.

In the crus, or part of the leg from the knee to the ankle there are thirteen muscles; four in the anterior region, two in the external region, seven in posterior region. The four in the anterior are the Tibialis anticus, Extensor proprius hallucis, Extensor longus digitorum, Peroneus tertius, and they are all supplied by the anterior tibial nerve which comes from the external popliteal or peroneal and is traced to 4-5L and 1S nerves. This nerve also supplies the only muscle on the back of the foot which is the Extensor brevis digitorum.

The two in the external region are the Peroneus longus and the Peroneus brevis. They are supplied by the musculo-cutaneous nerve which comes from external popliteal and is traced to 4-5L, 1S nerves.

The seven in the posterior region are the Gastrocnemius, Soleus, Plantaris, Popliteus, Flexor longus hallucis, Flexor longus digitorum, and Tibialis posticus.

The first four are supplied by the internal popliteal which comes from G. S. and is traced to 4-5L, 1-2-3S. The last three are supplied by the posterior tibial which is a continuation of the internal popliteal, and it comes from 4-5L, 1-2S nerves. The Soleus muscle also receives this nerve.

THE FOOT.

In the foot there are twenty muscles. One on the dorsum of the foot and nineteen on the plantar surface. The one on the dorsum is the Extensor brevis digitorum, it is supplied by the anterior tibial nerve. Those on the plantar surface are arranged in four layers—three muscles in the first layer, five in the second layer, four in the third layer, and seven in the fourth layer.

Those in the first layer are: Abductor hallucis, Flexor brevis digitorum, Abductor minimi digiti. The first two are supplied by the internal plantar nerve, the fibres of which may be traced to the 4, 5L, and 1-2S nerve roots.

Those in the second layer are the Flexor accessorius and the four Lumbricales. The two inner Lumbricales are supplied by the internal plantar, the other muscles of this layer by the external plantar. Those in the third layer are the Flexor brevis hallucis, Adductor obliquus hallucis, Flexor brevis minimi digiti and the Adductor transversus hallucis. The first one is supplied by the internal plantar. The others by the external plantar. In the fourth layer there are four Dorsal interossei and three Palmar interossei. They are all supplied by the external plantar. *Plantar*

QUESTIONS AND ANSWERS ON THE LOWER EXTREMITY.

- 1 How many muscles in the Gluteal region?
There are nine.
- 2 How many of them are attached to the great trochanter?
Eight.
- 3 Name the muscles in the Gluteal region?
Gluteus maximus, Gluteus medius, Gluteus minimus, Gemellus superior, Gemellus inferior, Obturator internus, Obturator externus, Piriformis and Quadratus femoris.
- 4 What nerve supplies the Gluteus maximus?
The inferior gluteal and the small sciatic. The small sciatic, by some, is considered as a cutaneous nerve, but we have good authority for saying it helps to supply the Gluteus maximus.
- 5 What nerve supplies the Gluteus minimus and medius?

- The superior gluteal.
- 6 What other muscle does this nerve supply?
The Tensor vaginae femoris
- 7 Nerve to the Quadratus femoris comes from which ones?
It comes from the 4-5 Lumbar and 1 Sacral.
- 8 What other muscle does it supply?
This nerve also supplies the Gemellus inferior.
- 9 Nerve to Obturator internus comes from which ones?
It comes from 5 Lumbar, 1 - 2 Sacral nerves.
- 10 What other muscle does it supply?
It supplies the Gemellus inferior. *superior*
- 11 What ligaments make the greater and lesser Sacro-sciatic foramina?
The greater and lesser Sacro-sciatic ligaments.
- 12 What muscle goes through the Greater?
Pyriformis.
- 13 What goes through above the Pyriformis muscle?
The gluteal vessels and the superior gluteal nerve.
- 14 What passes through below the Pyriformis muscle?
Inferior gluteal nerve, sciatic vessels and nerves, internal pudic vessels and nerve, muscular branches from sacral plexus.
- 15 What muscle passes through the lesser Sacro-sciatic foramen?
Obturator internus, its nerve and the internal pudic vessels and nerve.
- 16 The Obturator internus is supplied from what plexus?
Sacral plexus, and its fibres are traced to the 5th Lumbar, 1-2 Sacral nerves.
- 17 The 5th lumbar nerve belongs to what plexus?
It belongs to the Sacral plexus. This nerve and a part of the 4th lumbar nerve unite to make the lumbo sacral cord, which helps to form the Sacral plexus.
- 18 The Obturator externus is supplied from what plexus?
Lumbar plexus, and this nerve is traced to 2-3-4 Lumbar nerves.
- 19 How many muscles are attached to the Ilium?
Sixteen.
- 20 How many muscles are attached to the Ischium?
Fourteen.
- 21 How many muscles are attached to the Os Pubis?
Sixteen.
- 22 How many bones in the pelvis?
Four.
- 23 Name them.

- Two innominate, sacrum and coccyx.
- 24 Name the divisions of the Innominate.
Ilium, ischium and os pubis.
- 25 What bones form the acetabulum?
The same three that make the innominate.
- 26 Name the ligaments of the hip joint.
Capsular, ilio-femoral, teres, cotyloid and the transverse.
- 27 How many muscles are attached to the femur?
Twenty-three.
- 28 What nerve supplies the muscles in the Anterior Femoral Region?
Anterior crural.
- 29 What nerve supplies the muscles in the Internal Femoral Region?
Obturator.
- 30 What nerve supplies the muscles in the Posterior Femoral Region?
Great sciatic.
- 31 The anterior crural and obturator nerves come from what plexus?
Lumbar plexus, each one from 2-3-4 nerves.
- 32 All the muscles on the posterior part of femur and from knee down are supplied by what nerve and its branches?
Great sciatic and its branches.
- 33 How many muscles are there from the knee to the ankle?
Thirteen.
- 34 How many on the anterior tibio-fibular region?
Four.
- 35 How many in the outer fibular region?
Two.
- 36 How many in the posterior region?
Seven.
- 37 How many layers in the posterior region?
Two.
- 38 What separates these two layers?
Deep transverse fascia.
- 39 Name the seven muscles.
Gastrocnemius, Soleus, Plantaris, Popliteus, Flexor longus hallucis, Flexor longus digitorum and Tibialis posticus.
- 40 Name the deep layer.
The last four just named.
- 41 Give nerve supply.
The nerve supply to the muscles in the deep layer is the posterior tibial for all but the Popliteus and it is supplied by the internal popliteal.

- 42 Name those in superficial layer.
Gastrocnemius, Soleus and Plantaris.
- 43 Give nerve supply.
The internal popliteal to all of them, and the Soleus in addition gets the posterior tibial.
- 44 Which muscles are attached to the tibia and fibula.
Extensor longus digitorum, Biceps, Tibialis posticus and Soleus.
- 45 What long bone has the insertion of only one muscle?
Fibula.
- 46 What is that muscle:
Biceps.
- 47 Name the outer ham string.
It is the Biceps muscle.
- 48 Name the inner hamstrings.
Semitendinosus, Semimembranosus, Gracilis, and Sartorius.
- 49 Bound Scarpa's triangle.
On the outer side by the Sartorius, on the inner side by the Adductor longus, above by Poupert's ligament.
- 50 Who was Scarpa?
Italian Anatomist. 1747-1832. He was physician to Napoleon.
- 51 Give the floor of Scarpa's triangle from without inward.
Iliacus, Psoas, Pectineus, Adductors brevis and longus.
- 52 What structure passes through the center of this triangle?
Femoral vessels and anterior crural nerve from within outward, vein, artery, nerve. "V A N"
- 53 How long is the common femoral artery?
About an inch and a half or two inches.
- 54 It gives off what branch?
Profundus.
- 55 Passes through what canal?
Hunter's canal.
- 56 Then through what space.
Popliteal space.
- 57 Then gives off what branches?
Anterior and posterior tibial.
- 58 Where does this division take place?
Lower border of Popliteus muscle.
- 59 Anterior tibial passes to the front of the leg between the two heads of what muscle?
Tibialis posticus.

- 60 Anterior tibial continues below the ankle as what artery?
Dorsalis pedis.
- 61 The Posterior tibial artery gives off what large branch?
Peroneal.
- 62 The posterior artery divides into what as it passes into the Plantar surface of the foot?
Internal and External plantar.
- 63 Describe the Anterior Annular ligament.
The Anterior Annular Ligament consists of a superior or vertical portion, which binds down the extensor tendons as they descend on the front of the tibia and fibula, and an inferior or horizontal portion, which retains them in connection with the tarsus, the two portions being connected by a thin intervening layer of fascia. The vertical portion is attached externally to the lower end of the fibula, internally to the tibia, and above is continuous with the fascia of the leg; it contains only one synovial sheath, for the tendon of the Tibialis anticus, the other tendons and the anterior tibial vessels and nerve passing beneath it, but without any distinct synovial sheath. The horizontal portion is attached externally to the upper surface of the os calcis, in front of the depression for the interosseous ligament; it passes upward and inward as a double layer, one lamina passing in front, and the other behind, the Peroneus tertius and Extensor longus digitorum. At the inner border of the latter tendon these two layers join together, forming a sort of loop or sheath in which the tendons are enclosed, surrounded by a synovial membrane. From the inner extremity of this loop two bands are given off: one passes upward and inward to be attached to the internal malleolus, passing over the Extensor proprius hallucis and vessels and nerves, but enclosing the Tibialis anticus and its synovial sheath by a splitting of its fibres. The other limb passes downward and inward to be attached to the navicular and internal cuneiform bones, and passes over both the tendon of the Extensor proprius hallucis and the Tibialis anticus, and also the vessels and nerves. These two tendons are contained in separate synovial sheaths situated beneath the ligament. It will thus be seen that the horizontal portion of the ligament is like the letter Y, the foot of the letter being attached to the os calcis, and the two diverging arms to the tibia and navicular and internal cuneiform respectively.
- 64 Describe Internal annular ligament.
The Internal Annular Ligament is a strong fibrous band which extends from the inner malleolus above to the internal margin of the os calcis below, converting a series of grooves in this situation into canals for the passage of the tendons of the Flexor muscles and vessels into the sole of the

foot. It is continuous by its upper border with the deep fascia of the leg, and by its lower border with the plantar fascia and the fibres of origin of the Abductor hallucis muscle. The three canals which it forms transmit, from within outward, first, the tendon of the Tibialis posterior; second, the tendon of the Flexor longus digitorum; then the posterior tibial vessels and nerve, which run through a broad space beneath the ligament; lastly, in a canal formed partly by the astragalus, the tendon of the Flexor longus hallucis. Each of these canals is lined by a separate synovial membrane.

65 Describe the External annular ligament.

The External Annular Ligament extends from the extremity of the outer malleolus to the outer surface of the os calcis: it binds down the tendons of the Peronei muscles in their passage beneath the outer ankle. The two tendons are enclosed in one synovial sac.

66 Describe the Plantar fascia.

The Plantar Fascia, the densest of all the fibrous membranes, is of great strength, and consists of dense pearly-white glistening fibres, disposed, for the most part, longitudinally; it is divided into a central and two lateral portions.

The *central portion*, the thickest, is narrow behind and attached to the inner tubercle of the os calcis, behind the origin of the Flexor brevis digitorum, and, becoming broader and thinner in front, divides near the heads of the metatarsal bones into five processes, one for each of the toes. Each of these processes divides opposite the metatarso-phalangeal articulation into two strata, superficial and deep. The superficial stratum is inserted into the skin of the transverse sulcus which divides the toes from the sole. The deeper stratum divides into two slips which embrace the sides of the flexor tendons of the toes, and blend with the sheaths of the tendons, and laterally with the transverse metatarsal ligament, thus forming a series of arches through which the tendons of the short and long flexors pass to the toes. The intervals left between the five processes allow the digital vessels and nerves and tendons of the Lumbricales muscles to become superficial. At the point of division of the fascia into processes and slips numerous transverse fibres are superadded, which serve to increase the strength of the fascia at this part by binding the processes together and connecting them with the integument. The central portion of the Plantar fascia is continuous with the lateral portions at each side, and sends upward into the foot, at their point of junction, two strong vertical intermuscular septa, broader in front than behind, which separate the middle from the external and internal plantar group of muscles; from these, again,

thinner transverse septa are derived, which separate the various layers of muscles in this region. The upper surface of this fascia gives attachment behind to the Flexor brevis digitorum muscle.

The *lateral portions* of the plantar fascia are thinner than the central piece, and covers the sides of the foot.

The *outer portion* covers the under surface of the Abductor minimi digiti; it is thick behind, thin in front, and extends from the os calcis, forward to the base of the fifth metatarsal bone, into the outer side of which it is attached; it is continuous internally with the middle portion of the plantar fascia, and externally with the dorsal fascia.

The *inner portion* is very thin, and covers the Abductor hallucis muscle; it is attached behind to the internal annular ligament, and is continuous around the side of the foot with the dorsal fascia, and externally with the middle portion of the plantar fascia.

67 Name the muscles the Great Sciatic supplies on posterior part of the leg.

Biceps, Semitendinosus, Semimembranosus.

68 It divides into what branches?

Internal and external popliteal.

69 The External popliteal nerve divides into what branches?

Anterior tibial and musculo-cutaneous.

70 The Anterior Tibial supplies what muscles?

Tibialis anterior, Extensor proprius hallucis, Extensor longus digitorum, Peroneus tertius, and the Extensor brevis digitorum.

71 What else does it supply besides these five muscles?

The integument between great and second toes.

72 Musculo-cutaneous nerve supplies how many muscles?

Two.

73 Name them.

Peroneus longus and Peroneus brevis.

74 What else does it supply beside these muscles?

The integument on dorsum of foot.

75 What nerve supplies the integument on external border of the foot?

Short saphenous.

76 From what plexus?

The short saphenous comes from the internal and external popliteal nerves, which are branches of the great sciatic from sacral plexus.

77 How is the short saphenous formed?

By branches from internal and external popliteal.

78 The internal Popliteal nerve supplies how many muscles?

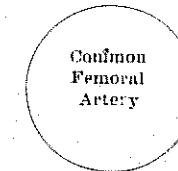
- It supplies three and a part of another.
- 79 The posterior Tibial supplies how many?
This one also supplies three and a part of another. The one they supply in common is the Soleus.
- 80 The posterior Tibial divides into how many branches?
Two: internal and external plantar.
- 81 How many muscles does the internal plantar supply?
It supplies five.
- 82 Name those it supplies in the 1st, 2nd and 3rd layers.
In the first layer, the Abductor pollicis, Flexor brevis digitorum; in the second layer, the two inner Lumbricales; in the third layer, the Flexor brevis pollicis.
- 83 Name those supplied by the external plantar.
In the first layer, the Abductor minimi digiti; in the second layer, the two outer Lumbricales and the Accessorius; in the third layer, the Adductor obliquus hallucis, Adductor transversus hallucis, Flexor brevis minimi digiti; in the fourth layer, the seven Interossei.
- 84 Give the cutaneous nerve supply of the foot.
The anterior tibial nerve supplies the skin between great and second toes. The musculo-cutaneous on dorsum of foot; short saphenous on outer border of foot; long saphenous on inner border of foot. The plantar surface and tips of toes are supplied by the internal and external plantar; the heel by the calcanean, which is a branch of the posterior tibial.
- The cutaneous nerve supply of the foot all comes from the Sacral plexus, except the internal or long saphenous which comes from the Lumbar plexus.
- 85 What muscle arises just below the insertion of the Gluteus maximus?
Short head of Biceps.
- 86 The small sciatic comes from what nerves?
From 2nd and 3rd sacral nerves.
- 87 The pudic comes from what nerves?
From 2nd, 3rd and 4th sacral nerves.
- 88 The great sciatic comes from what nerves?
From 4th and 5th lumbar, 1st, 2nd and 3rd sacral nerves.
- 89 The superior gluteal comes from what nerves?
From the 4th and 5th lumbar and 1st sacral nerves.
- 90 The inferior gluteal comes from what nerves?
From the 5th lumbar, 1st and 2nd sacral nerves.
- 91 What other nerve comes from the same?
Nerve to Obturator internus.

- 92 What other one comes from the same one as the superior gluteal? Nerve to Quadratus femoris.
- 93 Give the relations of the common femoral artery

In front.

Skin and superficial fascia.
Superficial inguinal glands.
Iliac portion of fascia lata.
Prolongation of transversalis fascia.
Crural branch of genito-crural nerve.
Superficial circumflex iliac vein.
Superficial epigastric vein.

Inner side.
Femoral vein.



Outer side.
Anterior crural nerve.

Behind.


Prolongation of fascia covering Iliacus muscle.
Iliac portion of fascia lata.
Nerve to Pectineus.
Psoas muscle.
Pectineus muscle.
Capsule of hip-joint.

- 94 Give the relations of the superficial femoral artery.

In front.

Skin, superficial and deep fascia.
Internal cutaneous nerve.
Sartorius.
Aponeurotic covering of Hunter's canal.
Internal saphenous nerve.

Inner side.
Adductor longus.
Adductor magnus.
Sartorius.



Outer side.
Long saphenous nerve.
Nerve to vastus internus.
Vastus internus.
Femoral vein (below).

Behind.

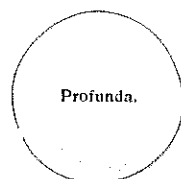
Femoral vein.
Profunda artery and vein.
Pectineus muscle.
Adductor longus.
Adductor magnus.

- 95 Give the relations of the profunda artery.

In front.

Femoral and Profunda veins.
Adductor longus.

Outer side.
Vastus internus.



Inner side.
Pectineus.

Behind.

Iliacus.
Pectineus.
Adductor brevis.
Adductor magnus.

- 96 What are the divisions of the abdominal aorta?
Right common iliac and left common iliac.
- 97 The common iliac divides into what branches?
External iliac and internal iliac.
- 98 The internal iliac divides into what?
Anterior and posterior trunks.
- 99 Name the branches of the anterior trunk.
Superior vesical, middle vesical, inferior vesical, middle hæmorrhoidal obturator, internal pudic, sciatic; in female, uterine and vaginal.
- 100 Name the branches of the posterior trunk.
Ilio-lumbar, lateral sacral and gluteal.
- 101 The external iliac continues as what?
As common femoral.
- 102 What structures pass out of the Greater and into the Lesser sacro-sciatic foramen?
Internal pudic vessels and pudic nerve, and nerve to obturator internus.
- 103 What passes through the obturator foramen?
Obturator vessels and nerve.
- 104 What is inserted into the digital fossa?
Obturator externus muscle.
- 105 Name the ligaments of the knee joint.
External Ligaments: Anterior or ligamentum patella, posterior or ligamentum posticum Winslowii, internal lateral, two external lateral, capsular.
- Internal Ligaments: Anterior or external crucial, posterior or internal crucial, two semilunar fibro-cartilages, transverse, coronary, ligamentum mucosum, ligamenta alaria.
- 106 What structures pass under Poupart's ligament?
Anterior crural nerve, femoral vessels, crural branch of genito-crural

external cutaneous nerves, Iliacus and Psoas muscles.

107 Who was Poupart?

Was French. Lived 1661-1709.

108 What structures pass through Hunter's canal?

Femoral artery and vein, and internal or long saphenous nerve.

109 Who was Hunter?

Was British, 1728-1793.

110 Bound Hunter's canal.

It is bounded, externally, by the vastus internus; postero-internally by the Adductors longus and magnus; and antero-internally by the aponeurosis which extends transversely from Vastus internus across the femoral vessels to Adductor longus and magnus muscles, lying on which aponeurosis is the Sartorius muscle.

111 Bound the popliteal space.

The popliteal space is lozenge-shaped, widest at the back part of the knee-joint. It is bounded externally, above the joint, by the Biceps, and, below the joint by the Plantaris and external head of the Gastrocnemius; internally, above the joint, by the semimembranosus and Semitendinosus, the latter, however, lying on (*posterior to*) the former, whose *edge* is the real boundary; below the joint by the inner head of the Gastrocnemius.

112 Why called popliteal?

From *popes*, meaning ham or back of knee.

113 Give contents.

It contains the popliteal vessels and their branches, together with the termination of the external saphenous vein, the internal and external popliteal nerves and some of their branches, the lower extremity of the small sciatic nerve, the articular branch from the obturator nerve, a few small lymphatic glands, and a considerable quantity of loose adipose tissue.

114 Name the ligaments of the ankle.

Anterior, posterior, internal lateral, external lateral.

115 What forms the crucial anastomosis?

Internal circumflex, external circumflex, sciatic, and superior perforating arteries. The sciatic is a branch of the anterior trunk of internal iliac, and the other three arteries are branches of the profunda.

116 What muscles form the tendo Achillis?

Gastrocnemius and Soleus.

117 Why is the Plantaris so called?

Because it sometimes goes to the plantar surface of the foot.

118 How many bones in foot?

Twenty-six.

119 Describe the fascia lata.

The deep fascia of the thigh is exposed on the removal of the superficial fascia, and is named, from its great extent, the *fascia lata*; it forms a uniform investment for the whole of this region of the limb, but varies in thickness in different parts; thus, it is thicker in the upper and outer parts of the thigh, where it receives a fibrous expansion from the Gluteus maximus muscle, and the Tensor vaginae femoris is inserted between its layers: it is very thin behind, and at the upper and inner part where it covers the Adductor muscles, and again becomes stronger around the knee, receiving fibrous expansions from the tendon of the Biceps externally, and from the Sartorius internally, and Quadriceps extensor cruris in front.

120 Describe the deep fascia of the leg.

The deep fascia of the leg forms a complete investment for the muscles, but is not continued over the subcutaneous surfaces of the bones. It is continuous above with the fascia lata, receiving an expansion from the tendon of the Biceps on the outer side, and from the tendons of the Sartorius, Gracilis, and Semitendinosus on the inner side; in front it blends with the periosteum covering the subcutaneous surface of the tibia, and with that covering the head and external malleolus of the fibula; below it is continuous with the annular ligaments of the ankle. It is thick and dense in the upper and anterior part of the leg, and gives attachment, by its deep surface, to the Tibialis anticus and Extensor longus digitorum muscles, but thinner behind, where it covers the Gastrocnemius and Soleus muscles. Over the popliteal space it is much strengthened by transverse fibres which stretch across from the inner to the outer hamstring muscles, and it is here perforated by the external saphenous vein. Its deep surface gives off, on the outer side of the leg, two strong intermuscular septa which enclose the Peronei muscles, and separate them from the muscles on the anterior and posterior tibial regions and several smaller and more slender processes which enclose the individual muscles in each region; at the same time a broad, transverse intermuscular septum, called the *deep transverse fascia of the leg*, intervenes between the superficial and deep muscles in the posterior tibio-fibular region.

121 Describe the ilio-tibial band.

The portion of the fascia lata arising from the front part of the crest of the ilium, corresponding to the origin of the Tensor vaginae femoris, passes down the outer side of the thigh as two layers, one superficial and the other beneath this muscle: these at its lower end become blended together into a thick and strong band, having first received the insertion of the muscle. This band is continued downward under the name of the *ilio-tibial*

band, to be inserted into the external tuberosity of the tibia.

122 What muscles compose the Quadriceps extensor cruris?

Rectus, vastus internus, Vastus externus and crureus.

123 The tendon of what long muscle passes directly across the sole of the foot?

Peroneus longus.

124 Describe the saphenous opening.

The saphenous opening is an oval-shaped aperture measuring about an inch and a half in length and half an inch in width. It is situated at the upper and inner part of the front of the thigh, below Poupart's ligament, and is directed obliquely downward and outward.

Its *outer margin* is of a semilunar form, thin, strong, sharply defined, and lies on a plane considerably anterior to the inner margin. If this edge is traced upward, it will be seen to form a curved elongated process, the *fulciform process* or *superior cornu*, which ascends in front of the femoral vessels, and, curving inward, is attached to Poupart's ligament and to the spine of the os pubis and pectineal line, where it is continuous with the pubic portion. If traced downward, it is found continuous with another curved margin, the concavity of which is directed upward and inward: this is the *inferior cornu* of the saphenous opening, and is blended with the pubic portion of the fascia lata covering the Pectineus muscle.

The *inner boundary* of the opening is on a plane posterior to the outer margin and behind the level of the femoral vessels; it is much less prominent and defined than the outer, from being stretched over the subjacent Pectineus muscle. It is through the saphenous opening that a femoral hernia passes after descending along the crural canal.

125 Why called saphenous?

The word saphenous means manifest. This word is a misnomer, as the opening is not apparent.

126 Describe the external abdominal ring.

Just above and to the outer side of the crest of the os pubis an interval is seen in the aponeurosis of the External oblique, called the *external abdominal ring*. This aperture is oblique in direction, somewhat triangular in form, and corresponds with the course of the fibres of the aponeurosis. It usually measures from base to apex about an inch, and transversely about half an inch. It is bounded below by the crest of the os pubis; above by a series of curved fibres, the intercolumnar, which pass across the upper angle of the ring, so as to increase its strength; and on either side, by the margins of the opening in the aponeurosis, which are called the columns or pillars of the ring.

127 Describe Poupart's ligament.

Poupart's ligament, or the crural arch, is the lower border of the aponeurosis of the External oblique muscle, which extends from the anterior superior spine of the ilium to the spine of the os pubis. From this latter point it is reflected outward to be attached to the pectineal line for about half an inch, forming Gimbernat's ligament. Its general direction is curved downward toward the thigh, where it is continuous with the fascia lata. Its outer half is rounded and oblique in direction; its inner half gradually widens at its attachment to the os pubis, is more horizontal in direction, and lies beneath the spermatic cord.

128 Describe Gimbernat's ligament.

Gimbernat's ligament is that portion of the External oblique muscle which is reflected downward and outward from the spine of the os pubis to be inserted into the pectineal line. It is about half an inch in length, larger in the male than in the female, almost horizontal in direction, in the erect posture, and of a triangular form, with the base directed outward. Its base or outer margin is concave, thin, and sharp, and lies in contact with the crural sheath, forming the inner boundary of the crural ring. Its apex corresponds to the spine of the os pubis. Its posterior margin is attached to the pectineal line, and is continuous with the pubic portion of the fascia lata. Its anterior margin is continuous with Poupart's ligament.

129 Describe Petit's triangle.

Petit's triangle is bounded in front by the External oblique, behind by the Latissimus dorsi, below by the crest of the ilium, while its floor is formed by the Internal oblique.

130 Describe the triangular ligament of the abdomen.

The triangular ligament of the abdomen is a band of tendinous fibres, of a triangular shape, which is attached by its apex to the pectineal line, where it is continuous with Gimbernat's ligament. It passes inward beneath the spermatic cord, and expands into a somewhat fan-shaped fascia, lying behind the inner pillar of the external abdominal ring and in front of the conjoined tendon, and interlaces with the ligament of the other side at the linea alba.

131 What muscles are attached to the intermuscular septa of fascia lata?

From the inner surface of the fascia lata are given off two strong intermuscular septa, which are attached to the whole length of the linea aspera and its prolongations above and below: the external and stronger one, which extends from the insertion of the Gluteus maximus to the outer condyle, separates the Vastus externus in front from the short head of the Biceps behind, and gives partial origin to these muscles; the inner one, the thinner of the two, separates the Vastus internus from the Adductor and Pectineus muscles.

132 Describe internal abdominal ring.

The internal or deep abdominal ring is situated in the transversalis fascia, midway between the anterior superior spine of the ilium and the symphysis pubis, and about half an inch above Poupart's ligament. It is of an oval form, the extremities of the oval directed upward and downward; it varies in size in different subjects, and is much larger in the male than in the female. It is bounded above and externally by the arched fibres of the Transversalis muscle, below and internally by the deep epigastric vessels. It transmits the spermatic cord in the male and the round ligament in the female. From its circumference a thin, funnel-shaped membrane, the *infundibuliform fascia*, is continued around the cord and testis, enclosing them in a distinct pouch. When the sac of an inguinal hernia passes through the internal or deep abdominal ring, the infundibuliform process of the transversalis fascia forms one of its coverings.

133 What does the word hernia mean?

Literally, a branch.

134 What muscles make the external rotators?

All the muscles which form the floor of Scarpa's triangle, all the muscles in the gluteal region except the Gluteus minimus and half the medius, also the Sartorius and the Adductor magnus.

135 What muscles make the internal rotators?

There are three muscles, supplied by the superior gluteal nerve. They are the Gluteus medius, Gluteus minimus and the Tensor vaginæ femoris. All these muscles, except half of the Gluteus medius are internal rotators.

136 Show how the external popliteal nerve gets to the front of leg.

It passes between the tendon of Biceps and outer head of the Gastrocnemius muscle, winds round neck of fibula, pierces origin of the Peroneus longus and divides beneath that muscle into anterior tibial and musculocutaneous nerve.

137 The length of the femur is what part of the length of the body?

One-fourth. In a man six feet high the length of the femur is eighteen inches.

138 Describe the linea aspera and what muscles are attached to it?

The linea aspera is a prominent longitudinal ridge or crest, on the middle third of the bone, presenting an external lip, an internal lip, and a rough intermediate space. Above, this crest is prolonged by three ridges. The most external one is very rough, and is continued almost vertically upward to the base of the great trochanter. It is sometimes termed the gluteal ridge, and gives attachment to part of the Gluteus maximus muscle;

its upper part is often elongated into a roughened crest, on which is a more or less well-marked, rounded tubercle, a rudimental third trochanter. The middle ridge, the least distinct, is continued to the base of the trochanter minor, and the internal one is lost above in the spiral line of the femur. Below, the *linea aspera* is prolonged by two ridges, which enclose between them a triangular space, the *popliteal surface*. Of these two ridges, the outer one is more prominent, and descends to the summit of the outer condyle (external supracondylar line). The inner one (internal supracondylar line) is less marked, especially at its upper part, where it is crossed by the femoral artery. It terminates, below, at the summit of the internal condyle, in a small tubercle, the Adductor tubercle, which affords attachment to the tendon of the Adductor magnus.

To the inner lip of the *linea aspera* and its inner prolongation above and below is attached the *Vastus internus*, and to the outer lip and its outer prolongation above is attached the *Vastus externus*. The Adductor magnus is attached to the *linea aspera*, to its outer prolongation above and its inner prolongation below. Between the *Vastus externus* and the Adductor magnus are attached two muscles—viz. the *Gluteus maximus* above, and the short head of the *Biceps* below. Between the Adductor magnus and the *Vastus internus* four muscles are attached: the *Iliacus* and *Pectineus* above (the latter to the middle of the upper divisions); below these, the Adductor brevis and Adductor longus. The *linea aspera* is perforated a little below its center by the nutrient canal, which is directed obliquely upward.

139 At what angle does the neck join with shaft of femur?

About 130°.

140 Function and location of patella.

It serves to protect the knee joint, and increases the leverage of the Quadriceps extensor by making it act at a greater angle.

141 Describe knee joint.

The knee-joint was formerly described as a *ginglymus* or hinge-joint but is really of a much more complicated character. It must be regarded as consisting of three articulations together: one between each condyle of the femur and the corresponding tuberosity of the tibia, which are condyloid joints, and one between the patella and the femur, which is partly arthrodial, but not completely so, since the articular surfaces are not mutually adapted to each other, so that the movement is not a simple gliding one. This view of the construction of the knee-joint receives confirmation from the study of the articulation in some of the lower mammals, where three synovial membranes are sometimes found, corresponding to these

three subdivisions, either entirely distinct or only connected together by small communications. This view is further rendered probable by the existence of the two crucial ligaments within the joint, which must be regarded as the external and internal lateral ligaments of the inner and outer joints respectively. The existence of the *ligamentum mucosum* would further indicate a tendency to separation of the synovial cavity into two minor sacs, one corresponding to each joint.

The bones entering into the formation of the knee-joint are the condyles of the femur above, the head of the tibia below, and the patella in front. The bones are connected together by ligaments, some of which are placed on the exterior of the joint, while others occupy its interior.

142 What passes through the Obturator foramen? Why so called?

Obturator vessels and nerve. Obturator means closed.

143 Give dimensions of pelvic cavity.

It has three principal diameters: antero-posterior (sacro-pubic), transverse and oblique. The antero-posterior extends from the sacro-vertebral angle to the symphysis pubis; its average measurement is four inches in the male, four and three-quarters in the female. The transverse extends across the greatest width of the inlet, from the middle of the brim on one side to the same point on the opposite; its average measurement is four and a half in the male, five and a quarter in the female. The oblique extends from the margin of the pelvis, corresponding to the ilio-pectineal eminence on one side, to the sacro-iliac symphysis on the opposite side; its average measurement is four and a quarter in the male, and five in the female.

144 Describe the lumbar fascia.

The lumbar fascia occupies the interval between the last rib and crest of the ilium. It is attached internally to the spinous process of the lumbar and sacral vertebrae; above, to the last rib and to the cartilage of the eleventh rib; below to the posterior third of the crest of the ilium. The posterior layer of this fascia blends with and is practically the same thing as the aponeurosis of the *Latissimus dorsi* and *Serratus posticus inferior*. It gives attachment to the Internal oblique muscle of the abdomen. The anterior or deep surface gives off two layers: one lies between the *Erector spinae* and *Quadratus lumborum*, and is attached to the tips of the transverse processes of the lumbar vertebrae (posterior aponeurosis of the *Transversalis* muscle); the other lies on the anterior or internal surface of the *Quadratus lumborum*, and is attached to the front part of the same transverse processes (*transversalis* fascia). The upper portion of this layer, which extends from the transverse process of the first lumbar vertebra to

the apex and lower border of the last rib, constitutes the ligamentum arcuatum externum. Therefore these three layers of the lumbar fascia form two spaces: between the posterior and middle layer is situated the Erector spinae and the Multifidus spinae; between the middle and anterior layers is situated the Quadratus lumborum.

145 Describe the sacral plexus.

The sacral plexus is formed by the anterior branches of first, second, third and part of the fourth sacral nerves, together with the lumbo-sacral cord which is formed from the anterior branches of the fifth and a portion of the fourth lumbar nerves. Thus you can see that this cord, which is formed by lumbar nerves, belong to the sacral plexus.

146 The sacral plexus continues as what?

The great sciatic nerve.

147 Great sciatic divides into what nerves?

Internal and external popliteal nerves

148 Name four kinds of hernia.

Femoral, Inguinal, Umbilical, and Pirenic.

149 Name the different kind of joints found in the body.

Synarthrosis, or immovable joint.

Amphiarthrosis, mixed articulation.

Diarthrosis, movable joint

150 Why does the arm admit of greater motion than the leg?

Because it is placed in a shallow cavity and the neck is short.

151 What is the sustentaculum tali? The receptaculum chyli?

A process on the os calcis.

Receptaculum chyli is at the second lumbar vertebra.

152 Where are the anterior and posterior circumflex arteries?

Branches of the third portion of the axillary.

153 Where are the internal and external circumflex arteries?

Branches of the profunda.

154 What is the biceps cubiti?

It is the Biceps of the arm.

155 What muscle is attached to all tarsal bones but one?

Tibialis posticus.

156 Name the muscles attached to each tarsal bone.

Os calcis: to eight: part of the Tibialis posticus, the tendo Achillis, Plantaris, Abductor hallucis, Abductor minimi digiti, Flexor brevis digitorum, Flexor accessorius, and Extensor brevis digitorum.

Cuboid: part of the Flexor brevis hallucis and a slip from the tendon of the Tibialis posticus.

Navicular: Part of the Tibialis posticus.

Internal cuneiform: Tibialis anticus and posticus, and Peroneus longus.

Middle cuneiform: A slip from the tendon of the Tibialis posticus is attached to this bone.

External cuneiform: To two: part of the Tibialis posticus, and Flexor brevis hallucis.

Astragalus has no muscles attached.

157 Give articulation of each tarsal bone.

Os calcis: With two bones: the astragalus and cuboid.

Astragalus: With four bones: tibia, fibula, os calcis, and navicular.

Cuboid: With four bones: the os calcis, external cuneiform, and the fourth and fifth metatarsal bones; occasionally with the navicular.

Navicular: With four bones: astragalus and three cuneiform; occasionally with cuboid.

Internal-cuneiform: with four bones: navicular, middle cuneiform, first and second metatarsal bones.

Middle cuneiform: with four bones: navicular, internal and external cuneiform, and second metatarsal bone.

158 Name the spinous processes of the ilium.

1. Anterior superior spinous process.

2. Anterior inferior spinous process.

3. Posterior superior spinous process.

4. Posterior inferior spinous process.

159 What is attached to each?

No. 1 gives attachment on its outer border to the fascia lata and the origin of the Tensor vaginae femoris; its inner border to the Iliacus, whilst its extremity affords attachment to Poupert's ligament and the origin of the Sartorius.

No. 2 gives attachment to the straight tendon of the Rectus femoris and the ilio-femoral ligament.

No. 3 gives attachment to the oblique portion of the sacro-iliac ligaments and the Multifidus spinae.

No. 4 corresponds with the auricular portion which articulates with sacrum.

160 Give meaning of trochanter.

Means turning.

161 Give blood supply, ossification, articulation and attachment of muscles to the os innominatum.

The ilium receives on its anterior surface, twigs from the ilio-lumbar,

deep circumflex iliac, and obturator arteries. On the dorsum arteries enter it from the gluteal and sciatic trunks.

The ischium is supplied by the obturator, internal and external circumflex.

The pubes receives twigs from the obturator, internal and external circumflex, deep epigastric, and pubic branches of the common femoral artery.

These three bones form the innominate. Ossification from eight centers.

Articulates with its fellow of the opposite side, the sacrum and femur.

Attachment of muscles: to ilium, sixteen: To the outer lip of crest, the Tensor vaginae femoris, Obliquus externus abdominis, and Latissimus dorsi; to the internal lip, the Iliacus, Transversalis, Quadratus lumborum, and Erector spinae; to the interspace between the lips, the Obliquus internus. To the outer surface of the ilium, the Gluteus maximus, Gluteus medius, Gluteus minimus, reflected tendon of the Rectus; to the upper part of the great sacro-sciatic notch, a portion of the Piriformis; to the internal surface, the Iliacus; to that portion of the internal surface below the linea ilio-pectinea, the Obturator internus, and the Multifidus spinae to the internal surface of the posterior superior spine; to the anterior border, the Sartorius and straight tendon of the Rectus.

To the ischium, fourteen: To the outer surface of the ramus, the Obturator externus and Adductor magnus; to the internal surface, the Obturator internus and Erector penis. To the spine, the Gemellus superior, Levator ani, and Coccygeus. To the tuberosity, the Biceps, Semitendinosus, Semimembranosus, Quadratus femoris, Adductor magnus, Gemellus inferior, Transversus perinaei, Erector penis.

To the os pubis, sixteen: Obliquus externus, Obliquus internus, Transversalis, Rectus, Pyramidalis, Psoas parvus, Pectineus, Adductor magnus, Adductor longus, Adductor brevis, Gracilis, Obturator externus and internus, Levator ani, Compressor urethrae, and occasionally a few fibres of the Accelerator urinae.

162 Same for femur.

Blood supply: The head and neck of the femur receive branches from the sciatic, obturator and circumflex arteries. The trochanter receives twigs from the circumflex arteries. The nutrient vessel for the shaft is derived from the second perforating; it enters near the linea aspera and is directed towards the head of the bone. Condyles are nourished by articular branches from the popliteal and the anastomotic of femoral.

Ossification: from five centers.

Articulates: with three bones: os innominatum, tibia and ~~fibula~~ ^{patella}.

Attachment of muscles: to twenty-three: to the great trochanter, the Gluteus medius, Gluteus minimus, Piriformis, Obturator externus, Obturator Internus, Gemellus superior, Gemellus inferior, and Quadratus femoris. To the lesser trochanter, the Psoas magnus and the Iliacus below it. To the shaft, the Vastus externus, Gluteus maximus, short head of Biceps, Vastus internus, Adductor magnus, Pectineus, Adductor brevis, Adductor longus, Crureus, and Subcrureus. To the condyles: the Gastrocnemius, Plantaris and Popliteus.

163 Same for tibia.

The tibia is a very vascular bone. The nutrient artery for the shaft is furnished by the posterior tibial, it enters the bone near the interosseous border at the junction of the upper and middle thirds, and is directed downwards. The head of the bone receives numerous branches from the inferior articular arteries of the popliteal, and the recurrent branches of the anterior and posterior tibial arteries. The lower extremity receives twigs from the posterior and anterior tibial, the anterior peroneal, and the internal malleolar arteries.

Ossification: from three centers.

Articulation: with three bones: femur, fibula and astragalus.

Attachment of muscles: to twelve: to the inner tuberosity, the Semimembranosus; to the outer tuberosity, the Tibialis anticus and Extensor longus digitorum and Biceps; to the shaft, its internal surface, the Sartorius, Gracilis, and Semitendinosus; to its external surface, the Tibialis anticus; to its posterior surface, the Popliteus, Soleus, Flexor longus digitorum, and Tibialis posticus; to the tubercle, the ligamentum patellae.

164 Same for fibula.

Blood supply: The fibula receives the nutrient artery of its shaft from the peroneal branch of the posterior tibial. The head is nourished by branches from the inferior external articular branch of the popliteal artery, and the malleolus is supplied mainly by the peroneal and external malleolar arteries.

Ossification: from three centers.

Articulation: with two bones, the tibia and astragalus.

Attachment of muscles: to nine: to the head, the Biceps, Soleus, and Peroneus longus; to the shaft, its anterior surface, the Extensor longus digitorum, Peroneus tertius, and Extensor proprius hallucis; to the internal surface, the Tibialis posticus; to the posterior surface, the Soleus and Flexor longus hallucis; to the external surface, the Peroneus longus and brevis.

The fibula is a vestigial bone in man, and survives mainly on account of the excessive development of its malleolus. This accounts for the fact that the lower epiphysis, though appearing first, unites with the shaft before the upper epiphysis. In birds, the head of the bone is large, and enters into the formation of the knee-joint, whilst the lower end atrophies. The rule is this: Those epiphyses which are the last to form are first to join the bone. The fibula is an exception.

165 Same for tarsus.

Astragalus, supplied by dorsalis pedis. One or two centers of ossification.

Os calcis, supplied by posterior tibial, internal and external malleolar. Two centers of ossification.

Cuboid, one center of ossification.

Navicular, one center of ossification.

Internal cuneiform, one

Middle cuneiform, one.

External cuneiform one.

(For articulations, and attachment of muscles see answers to questions 156 and 157.)

166 Same for metatarsus.

Blood supply: they all have small nutrient branches.

Ossification: each metatarsal bone has two centers.

Articulation: each bone articulates with the tarsal bones by one extremity, and by the other with the first row of phalanges. The number of tarsal bones with which each metatarsal articulates is one for the first, three for the second, one for the third, two for the fourth, and one for the fifth.

Attachment of muscles: to the first metatarsal bone, three, part of the Tibialis anticus, the Peroneus longus, and First dorsal interosseous. To the second, four, the Adductor obliquus hallucis and First and Second dorsal interosseous, and a slip from the tendon of the Tibialis posticus, and occasionally a slip from the Peroneus longus. To the third, five, the Adductor obliquus hallucis, Second and Third dorsal, and First plantar interosseous, and a slip from the tendon of the Tibialis posticus. To the fourth, five, the Abductor obliquus hallucis, Third and Fourth dorsal, and Second plantar interosseous, and a slip from the tendon of the Tibialis posticus. To the fifth, six, the Peroneus brevis, Peroneus tertius, Flexor brevis minimi digiti, Adductor transversus hallucis, Fourth dorsal and Third plantar interosseous.

167 Same for phalanges.

Blood supply:

Ossification: from two centers.

Articulation: the first row, with the metatarsal bones behind and second phalanges in-front; the second row of the four outer toes, with the first and third phalanges; of the great toe, with the first phalanx; the third row of the four outer toes, with the second phalanges.

Attachment of muscles: to the first phalanges. Great toe, five muscles; innermost tendon of Extensor brevis digitorum, Abductor hallucis, Abductor obliquus hallucis, Flexor brevis hallucis, Adductor transversus hallucis. Second toe, three muscles: First and Second dorsal interosseous and First lumbrical. Third toe, three muscles: Third dorsal and First plantar interosseous and Second lumbrical. Fourth toe, three muscles: Fourth dorsal and Second plantar interosseous and Third lumbrical. Fifth toe, four muscles: Flexor brevis minimi digiti, Abductor minimi digiti, and Third plantar interosseous, and Fourth lumbrical.—Second phalanges. Great toe: Extensor longus hallucis, Flexor longus hallucis. Other toes: Flexor brevis digitorum, one slip of the common tendon of the Extensor longus and brevis digitorum.—Third phalanges: two slips from the common tendon of the Extensor longus and Extensor brevis digitorum, and the Flexor longus digitorum.

168 Same for patella.

Blood supply: the patella receives twigs from the superficial branch of the anastomotica, anterior tibial recurrent, and the inferior articular of the popliteal.

Ossification: one center.

Articulation: with two condyles of femur.

Attachment of muscles: to four: the Rectus, Crureus, Vastus internus, and Vastus externus. These muscles, joined at their insertion, constitute the Quadriceps extensor cruris.

169 Same for sacrum.

Blood supply:

Ossification: 35 centers.

Articulation: with four bones: the last lumbar vertebra, coccyx, and the two ossa innominata.

Attachment of muscles: to eight pairs: in front, the Piriformis and Coccygeus, and a portion of the Iliacus to the base of the bone; behind, the Gluteus maximus, Latissimus dorsi, Multifidus spinæ, and Erector spinæ, and sometimes the Extensor coccygis.

170 Same for coccyx.

Blood supply:

Ossification: four centers.

Articulation: with the sacrum.

Attachment of muscles: to four pair and one single muscle: on either side, the Coccygeus; behind, the Gluteus maximus and Extensor coccygeus, when present; at the apex, the Sphincter ani; and in front, the Levator ani.

171 Give branches of femoral artery.

Superficial Epigastric.
Superficial Circumflex Iliac.
Superficial External Pudic.

Profunda { External Circumflex.
Internal Circumflex.
Three Perforating.

Muscular.

Anastomotica Magna.

172 Give branches of popliteal artery.

Muscular { Superior.
Inferior or Sural.

Superior Internal Articular.
Azygos Articular.

Cutaneous.

Inferior External Articular.

Superior External Articular.

Inferior Internal Articular.

173 Give branches of anterior tibial artery.

Posterior Recurrent Tibial.

Muscular.

Superior Fibular.

Internal Malleolar.

Anterior Recurrent Tibial.

External Malleolar.

174 Give branches of dorsalis pedis.

Tarsal.

Dorsalis hallucis.

Metatarsal—Interosseous.

Communicating.

175 Give branches of posterior tibial.

Peroneal.

Nutrient.

Muscula

Communicating.

Internal Calcanean.

176 Give branches of peroneal.

Muscular.

Communicating.

Nutrient.

Posterior Peroneal.

Anterior Peroneal.

External Calcanean.

177 Give plantar arch.

The external plantar artery anastomosing with the communicating branch from the dorsalis pedis makes the plantar arch.

178 This arch gives off what branches?

The plantar arch, besides distributing numerous branches to the muscles, integument and fascia in the sole, gives off the following branches:

Posterior Perforating.

Digital—Anterior Perforating.

179 Which is the larger—external or internal plantar artery?

The external plantar artery is the larger.

180 Which is the larger—the external or internal plantar nerve?

The internal plantar nerve.

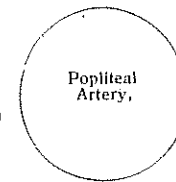
181 Give relation of popliteal artery.

In front.

Femur.
Ligamentum posticum.
Popliteus.

Inner side.

Semimembranosus.
Internal condyle.
Gastrocnemius (inner head)
Internal popliteal nerve-
(below)



Outer side.

Biceps.
Outer condyle.
Gastrocnemius (outer head)
Plantaris.
Internal popliteal nerve.
(above)

Behind.

Semimembranosus.
Fascia.
Popliteal vein.
Internal popliteal nerve.
Gastrocnemius.
Plantaris.
Soleus.

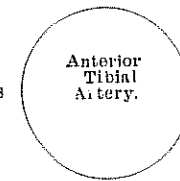
182 Give relation of anterior tibial artery.

In Front.

Integument, superficial and deep fasciae.
Anterior tibial nerve.
Tibialis anticus (overlaps it in the upper part of the leg.)
Extensor longus digitorum } (overlap it slightly).
Extensor proprius hallucis }
Anterior annular ligament.

Inner Side.

Tibialis anticus.
Extensor proprius hallucis
(crosses it at its lower part).



Outer Side.

Anterior tibial nerve.
Extensor longus digitorum.
Extensor proprius hallucis

Behind.

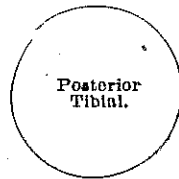
Interosseous membrane.
Tibia.
Anterior ligament of ankle-joint.

183 Give relation of posterior tibial artery.

In Front.

Tibialis posticus.
Flexor longus digitorum.
Tibia.
Ankle-joint.

Inner Side.
Posterior tibial nerve,
upper third.




Outer Side.
Posterior tibial nerve,
lower two-thirds.

Behind.
Integument and fascia.
Gastrocnemius.
Soleus.
Deep transverse fascia.
Posterior tibial nerve.

184 Give relation of peroneal artery.

In Front.
Tibialis postleus.
Flexor longus hallucis.



Outer Side.
Fibula.
Flexor longus hallucis.

Inner Side.
Flexor longus hallucis

Soleus.
Deep transverse fascia.
Flexor longus hallucis.

185 Give the relations of dorsalis pedis artery.

In front.
Integument and fascia.
Anterior annular ligament.
Innermost tendon of Extensor brevis digiterum.



Tibial Side.
Extensor proprius hallucis.

Fibular Side.
Extensor longus digitorum.
Anterior tibial nerve.

Behind.
Astragalus.
Navicular.
Internal cuneiform,
and their ligaments.

QUESTIONS AND ANSWERS ON TRUNK AND HEAD.

1 How many vertebrae in the spinal column?

Thirty-three in number, exclusive of those which form the skull, and have received the names cervical, dorsal, lumbar, sacral and coccygeal, according to the position which they occupy; seven being found in the cervical region, twelve in the dorsal, five in the lumbar, five in the sacral, and four in the coccygeal.

This number is sometimes increased by an additional vertebra in one region, or the number may be diminished in one region, the deficiency being supplied by an additional vertebra in another. These observations do not apply to the cervical portion of the spine, the number of bones forming which is seldom increased or diminished.

2 Names the divisions, giving the peculiar ones of each.

Seven cervical, twelve dorsal five lumbar, five sacral and four coccygeal.

The peculiar vertebrae in the cervical region are the first or atlas; the second or axis, and the seventh or vertebra prominens. The great modifications in the form of the atlas and axis are designed to admit of nodding and rotatory movements of the head. In the dorsal region the first, ninth, tenth, eleventh and twelfth are the peculiar ones.

In the lumbar region the fifth one is peculiar.

3 Describe each of the peculiar vertebrae.

The atlas has a small spinous process, large lateral processes and no body. The axis has an odontoid process which is in reality the body of the atlas. It has a large spinous process which is bifid.

The vertebra prominens has a long and prominent spinous process which ends in a tubercle for the ligamentum nuchae.

Peculiar dorsal vertebrae—the first has one facet and a demifacet.

The ninth has a demifacet only. The tenth has but one facet on the body and one on the transverse process.

The eleventh and twelfth have each but one facet on the body, and none on the transverse process.

The twelfth resembles a lumbar vertebra in size and shape.

The fifth lumbar is much deeper in front than behind; its spinous process is small, but its transverse processes are large and thick, and point slightly upwards.

4 Give a general description of the vertebra.

Each vertebra consists of a body and an arch, the latter being formed by 2 pedicles and 2 laminae, which support 7 processes.

Body is thick and spongy, convex in front from side to side, concave vertically, and on the upper and lower surfaces, which are surrounded by a bony rim. Anteriorly are small foramina for nutrient vessels, posteriorly a large foramen for the exit of the *vena basis vertebrarum*.

Pedicles project backwards from the body, inclining outwards. They are notched above and below, thus forming, with the adjacent notches, the Intervertebral Foramina for the entrance of vessels and the exit of the spinal nerves.

Laminae, are 2 broad plates, meeting in the spinous process behind, and rough on their upper and lower borders for the attachment of the *ligamentum subflava*.

Transverse Processes one on each side, projecting outwards.

Articular Processes, two on each side, superior and inferior, project from the junction of the laminae and pedicles, and articulating above and below with the articular processes of the adjacent vertebrae. Their superior facets look upwards in the cervical region, outwards in the dorsal, and inwards in the lumbar.

Spinous Process, projects backwards from the junction of the laminae with each other, sometimes very obliquely.

Spinal Foramen, is the space enclosed by the body, pedicles and laminae; and which, when the vertebrae are articulated, forms part of the spinal canal.

5 Give ligaments of vertebral column.

1. The ligaments of the body are (a) Anterior common ligament, (b) Posterior common ligament, (c) Intervertebral substance.

2 Ligaments connecting the laminae (a) *Ligamenta subflava*.

3 Ligaments connecting articular processes (a) capular.

4 Ligaments connecting the spinous processes (a) supraspinous (b) interspinous.

5 Ligaments connecting transverse processes (a) intertransverse.

6 Give a general description of a rib.

Each rib has the following points:

Head is divided by a ridge into 2 facets, which articulate with the facets on the bodies of the dorsal vertebrae; the ridge giving attachment to the interarticular ligament.

Neck, about an inch long, having attached to its upper border the anterior costo-transverse ligament, to its posterior surface the middle costo-transverse ligament; its anterior surface is smooth.

Tuberosity, at the junction of the neck with the shaft, has a facet for articulation with the transverse process of the next lower vertebra, and a

rough surface for the posterior costo-transverse ligament.

Shaft, twisted on itself, is concave internally, convex externally, its upper border round and smooth, its lower border grooved for the intercostal vessels and nerves. At its external extremity is an oval depression for the insertion of the costal cartilage.

Angle, just in front of the tuberosity, is marked by a rough line, to which are attached the muscles of the deep layer of the back.

How are they developed? Each rib has three centers, one each for the head, shaft and tuberosity. The last two ribs, having no tuberosity, are developed each by two centers.

7 Name the peculiar ribs.

They are the 1st, 2d, 10th, 11th and 12th.

They respectively present the following peculiarities, viz—

First Rib is broad, short, not twisted, has no angle, only one facet on the head, but on its upper surface are seen two grooves for the subclavian artery and vein, and between them a tubercle for the *Scalenus anticus* muscle.

Second Rib is not twisted, its tuberosity and angle are very close together, and its upper surface presents rough surfaces for the *Serratus magnus* and *Scalenus posticus* muscles.

Tenth Rib has but one facet on its head.

Eleventh Rib has no neck, no tuberosity, and but one facet on its head.

Twelfth Rib has neither neck, angle, tuberosity nor groove, and but one facet.

8 How many layers of muscles in the back.

The muscles in the back are arranged in five layers. The *Erector spinae* which is in the fourth layer gets both the internal and the external divisions of the posterior branches of the spinal nerves. The external divisions supply those in the third layer. The internal divisions together with the sub-occipital and great occipital supply those in the fifth layer.

9 Name muscles in 1st layer and give nerve supply.

MUSCLES OF THE BACK.

FIRST LAYER.	NERVES.
Trapezius	Spinal accessory; 3x4 cervical.
Latissimus dorsi	Middle or long subscapular
10 Name the muscles in 2nd layer and give nerve supply.	
SECOND LAYER.	
Levator angulae scapulae	3x4 cervical

Rhomboideus minor 5 cervical
 Rhomboideus major 5 cervical

11 Name muscles in 3rd layer and give nerve supply.

THIRD LAYER.

Serratus posticus superior External divisions of posterior
 Serratus posticus inferior branches of of the spinal nerves, in
 Splenius capitis their respective regions.
 Splenius colli

12 Name muscles in 4th layer and give nerve supply.

FOURTH LAYER.

Sacral and Lumbar Regions
 Erector spinae

DORSAL REGION.

Ilio-costalis
 Musculus accessoris ad iliocostalem

Longissimus dorsi
 Spinalis dorsi

CERVICAL REGION.

Cervicalis ascendens
 Transversalis colli
 Tracheo-mastoid
 Complexus
 Biventer cervicis
 Spinalis colli

13 Name muscles in 5th layer and give nerve supply.

FIFTH LAYER.

Semispinalis dorsi
 Semispinalis colli
 Multifidus spinae
 Rotatores spinae
 Supraspinalis
 Interspinalis
 Extensor coccygis
 Intertransversalis
 Rectus capitis posticus major
 Rectus capitis posticus minor
 Obliquus capitis superior
 Obliquus capitis inferior

All the muscles in the fourth layer get the external divisions of posterior branches except the spinalis dorsi, and spinalis colli and the complexus.

They get the internal divisions of the posterior branches. The Complexus also gets the suboccipital and the great occipital nerves.

All these muscles in the fifth layer are supplied by the internal divisions of the posterior branches of the spinal nerves in their respective regions, except the recti and obliqui, and are supplied by the suboccipital. The inferior oblique also takes the great occipital.

14 Give a general description of the diaphragm.

The word diaphragm is a Greek word meaning a partition wall. It is a musculo-fibrous septum, situated between the upper one-third and the lower two-thirds of the trunk. It separates the thoracic cavity from the abdominal cavity. It is the floor of the former and the roof of the latter, its general shape is somewhat like that of an umbrella or an irregular dome. The upper surface of it is covered with the right and left pleura, between the two pleurae it is covered with the pericardium. Its circumference is elliptical in form, highest at the ensiform cartilage. The highest part of all the diaphragm is on the right side immediately above the liver. This is a little higher than the left side, the lowest part of it is the right crus which reaches to the fourth lumbar vertebra. The under surface is covered with peritoneum. It is one of the so-called double bellied muscles. It has its origin in front from the ensiform cartilage, from the sides, from the under surfaces of the cartilages and bony portion of the six or seven lower ribs interdigitating with the transversalis muscle, also from the two aponeurotic arches called the ligamentum arcuatum externum et internum. The first one is the covering of the Psoas magnus, the other is the covering of the Quadratus lumborum. Behind it connected to the spine by two crura or legs, the right one is the longer extending from the anterior surface of the bodies and inter-vertebral substance of the three or four upper lumbar vertebrae; the left one from the anterior surface of the two upper ones. From this origin it passes to the central or cordiform tendon which consists of three leaflets, the right one is the largest, the left one the smallest and the middle is intermediate in size. On each side of the ensiform attachment there is a weak place which may be broken; then we may have what is called a phrenic or diaphragmatic hernia. Some of the contents of the abdomen may protrude into the chest, or pus in the mediastinum may descend through it into the abdominal cavity. The diaphragm has three large and several small natural foramina. The one most posterior is really not in the diaphragm but between the two crura which are joined posteriorly by a tendinous band. This is called the aortic opening, and transmits the aorta, vena azygos major, the thoracic duct and sometimes the left sympathetic nerve, when this nerve does not pass through this opening it goes through the left crus. The vena azygos major occasionally goes through the right crus. The second large opening is in front and little to the left of the aortic opening, it transmits the oesophagus and the pneumogastric nerves. The left pneumogastric passes in front of the oesophagus. The right one which passes behind it goes into the solar plexus which is situated behind the stomach. The third large opening is farther in front than the others

and lies in the central tendon. It is somewhat quadrilateral in form and is called the foramen quadratum, the inferior vena cava passes through it.

The smaller openings are through the crura. Those in the right crus transmit the greater and lesser splanchnics and the sympathetic nerves of the right side, occasionally the vena azygos major. The left crus transmits the vena azygos minor, the greater or lesser splanchnic nerves of the left side and the sympathetic nerve of the left side when it does not pass through the aortic opening. The blood supply of the diaphragm is derived from the two phrenic, the internal mammary and the lower intercostal arteries. The phrenic arteries are two small arteries which may arise separately from the aorta above the coeliac axis or by a common trunk which may come either from the aorta or coeliac axis. Often one is derived from the aorta and the other from the renal arteries. They very rarely arise as two separate vessels from the aorta. The nerve supply is the phrenic which comes from the 3rd, 4th and 5th cervical nerves. The phrenic plexus also helps to supply it. This plexus is made by the phrenic nerve and branches from the semilunar ganglion of the solar plexus. The laity call the diaphragm the midriff which comes from two Saxon words which mean the middle of the belly. Not long since I was reading a piece where a pugilist was telling how he intended to dispose of his opponent. He said: "I will him in the midriff, that will get his wind." The solar plexus or abdominal brain and the phrenic plexus are situated near the diaphragm. The former behind the stomach and the latter formed by branches from it. These plexus or plexuses belong to the great sympathetic system, which governs the involuntary actions. A severe blow upon the head may knock a man senseless but he still lives. His heart and lungs still act, being governed by the sympathetic system, but if he receives a severe blow upon the diaphragm it may produce instant death. The pugilist has learned this much about anatomy and if he were not trained to the hour more would be killed than are by this so-called solar plexus blow. The diaphragm is the chief muscle of respiration. The lower ribs may fall down thus drawing the diaphragm out of its natural position, in this way somewhat obstructing the passing of the blood through the aorta. I have known of one case in which the diaphragm was pulled down by the lower ribs causing an irregular action of the heart. As soon as they were replaced the heart acted in a natural manner. Tight lacing or any cause whatsoever which will impair the natural action of the diaphragm will cause much pain. Man is the only animal in which the transverse diameter of the diaphragm is greater than the antero-posterior. It begins to be developed about the ninth week of foetal life and grows from the circumference to the central tendon. All mammals or

milk-giving animals have a diaphragm. Man and the horse are examples of land animals, the whale and the sea cow are examples of water animals which have diaphragms. Birds possess a rudimentary form, which is best shown in the albatross.

15 How many large openings are in it?

Three.

16 What passes through the aortic opening?

Aorta, vena azygos major, the thoracic duct and sometimes the left sympathetic nerve, when this nerve does not pass through this opening it goes through left crus. Vena azygos major occasionally goes through right crus.

17 What passes through the oesophageal opening?

Oesophagus and the pneumogastric nerves. The left pneumogastric passes in front of the stomach.

The right one which passes behind it goes into the solar plexus which is situated behind the stomach.

18 What passes through the other large opening in diaphragm?

The inferior vena cava.

19 What passes through the right crus?

The greater and lesser splanchnics and the sympathetic nerves of the right side, occasionally the vena azygos major.

20 What passes through the left crus?

Vena azygos minor, greater and lesser splanchnic nerves of left side, and the sympathetic nerve of left side when it does not pass through the aortic opening.

21 Give nerve supply of diaphragm.

Phrenic nerve and phrenic plexus.

22 Give blood supply of same.

The blood supply of the diaphragm is derived from the two phrenic, the internal mammary and lower intercostal arteries.

23 What is the meaning of thorax?

Literally a breast plate.

24 How formed?

By 24 ribs, 12 thoracic vertebrae, and the sternum.

25 What muscles pass through the upper opening in the thorax?

Sterno-thyroid, sterno-thyroid and longus colli muscles of each side.

26 What arteries?

Innominate, left common carotid and left subclavian, internal mammary and superior intercostal arteries.

27 What nerves?

Pneumogastric, phrenic, cardiac and sympathetic nerves, the anterior branch of first dorsal nerve, and the recurrent laryngeal nerve of left side.

28 What veins?

Right and left innominate and the inferior thyroid veins.

29 What unclassified structures?

Remains of thymus gland, trachea, œsophagus, thoracic duct, apex of each lung.

30 The sternum is divisible into what parts?

Manubrium, gladiolus and ensiform or xiphoid appendix.

31 Name muscles attached to it.

Nine pairs and one single muscle: the Pectoralis major, Sterno-cleido-mastoid, Sterno-hyoid, Sterno-thyroid, Triangularis sterni, aponeuroses of the Obliquus externus, Obliquus internus, Transversalis, Rectus muscles and Diaphragm.

32 What bones enter into the formation of the anterior lacerated foramen?

The foramen lacerum anterius, or sphenoidal fissure, is formed above by the lesser wing of the sphenoid, below by the greater wing; internally by the body of the sphenoid, and sometimes completed externally by the orbital plate of the frontal bone.

33 What bones form the middle lacerated foramen?

Sphenoid and temporal.

34 What bones form the posterior lacerated foramen?

Occipital and temporal.

35 What are the other names for these foramina?

The anterior one is called the sphenoidal fissure, the middle one is called sphenotic, the posterior one is called the jugular

36 What structures pass through the anterior lacerated?

Third, fourth, three divisions of the ophthalmic division of the fifth, and the sixth cranial nerves. Filaments of cavernous plexus, ophthalmic vein, orbital branch of the middle meningeal, and recurrent branch of the lachrymal artery to dura mater.

37 What structures pass through the middle lacerated?

Carotid artery, and plexus; vidian nerve and meningeal branch of the ascending pharyngeal artery.

38 What structures pass through the posterior lacerated?

This opening is divided into three compartments, through the anterior one passes the inferior petrosal through the middle one the ninth, tenth and eleventh cranial nerves, through the posterior one the lateral sinus and meningeal branches of the ascending pharyngeal and occipital arteries.

39 The temporal bone is divisible into how many portions?

Three.

40 Name each part.

Squamous, mastoid and petrous.

41 The zygoma has how many roots, what are they called?

It has three roots. They are called anterior middle and posterior. The anterior one terminates in a rounded eminence, the eminentia articularis. The middle (post-glenoid) forms the posterior boundary of the mandibular portion of the glenoid fossa, while the posterior root, which is strongly marked, runs from the upper border of the zygoma, in arched direction, upward and backward, forming the posterior part of the temporal ridge (supramastoid crest).

42 The petrous bone presents for inspection how many points on its anterior, posterior and inferior surfaces?

The petrous portion has six points on the anterior surface, three on its posterior and eleven on its inferior.

43 Name each point on anterior surface.

1 An eminence near the center, which indicates the situation of the superior semicircular canal.

2 On the outer side of this eminence a depression indicating the position of the tympanum; here the layer of bone which separates the tympanum from the cranial cavity is extremely thin, and is known as the tegmen tympani.

3 A shallow groove, sometimes double, leading outward and backward to an oblique opening, the hiatus Fallopii, for the passage of the petrosal branch of the Vidian nerve and the petrosal branch of the middle meningeal artery.

4 A small opening, occasionally seen external to the latter, for the passage of the smaller petrosal nerve.

5 Near the apex of the bone, the termination of the carotid canal, the wall of which in this situation is deficient in front.

6 Above this canal a shallow depression for the reception of the Gasserian ganglion.

44 Name each point on posterior surface.

1 About its center, a large orifice, the meatus auditorius internus, whose size varies considerably; its margins are smooth and rounded, and it leads into a short canal, about four lines in length, which runs directly outward and is closed by a vertical plate, the lamina cribrosa, which is divided by a horizontal crest, the crista falciformis, into two unequal portions; the lower presenting three foramina or sets of foramina; one, just below the posterior part of the crest, consisting of a number of small open-

ings for the nerves to the sacculæ; a second, below and posterior to this for the nerve to the posterior semicircular canal; and a third, in front and below the first, consisting of a number of small openings which terminate in the canals centralis cochleæ and transmits the nerve to the cochlea; the upper portion, that above the crista, presents behind a series of small openings for the passage of filaments to the vestibule and superior and external semicircular canal, and, in front, one large opening, the commencement of the aquæductus Fallopii, for the passage of the facial nerve.

2 Behind the meatus auditorius, a small slit, almost hidden by a thin plate of bone, leading to a canal, the aquæductus vestibuli, which transmits a small artery and vein and lodges a process of the dura mater.

3 In the interval between these two openings, but above them, an angular depression which lodges a process of the dura mater. and transmits a small vein into the cancellous tissue of the bone.

45 Name each point on inferior surface.

Passing from the apex to the base, this surface presents eleven points for examination:

1 A rough surface, quadrilateral in form, which serves partly for the attachment of the Levator palati and Tensor tympani muscles.

2 The large, circular aperture of the carotid canal, which ascends at first vertically, and then, making a bend, runs horizontally forward and inward; it transmits the internal carotid artery and the carotid plexus.

3 The aquæductus cochleæ, a small, triangular opening, lying on the inner side of the latter, close to the posterior border of the petrous portion; it transmits a vein from the cochlea which joins the internal jugular.

4 Behind these openings a deep depression, the jugular fossa, which varies in depth and size in different skulls; it lodges the lateral sinus, and, with a similar depression on the margin of the jugular process of the occipital bone, forms the foramen lacerum posterius or jugular foramen.

5 A small foramen for the passage of Jacobson's nerve (the tympanic branch of the glosso-pharyngeal); this foramen is seen in front of the bony ridge dividing the carotid canal from the jugular fossa.

6 A small foramen on the outer wall of the jugular fossa, for the entrance of the auricular branch of the pneumogastric (Arnold's) nerve.

7 Behind the jugular fossa a smooth, square-shaped facet, the jugular surface; it is covered with cartilage in the recent state, and articulates with the jugular process of the occipital bone.

8 The vaginal process, a very broad, sheath-like plate of bone, which extends backward from the carotid canal and gives attachment to part of the Tensor palati muscle; this plate divides behind into two laminae, the

outer of which is continuous with the auditory process, the inner with the jugular process; between these laminae is the 9th point for examination, the styloid process, a long, sharp spine, about an inch in length; it is directed downward, forward, and inward, varies in size and shape, and sometimes consists of several pieces, united by cartilage; it affords attachment to three muscles, the Stylo-pharyngeus, Stylo-hyoideus, and Stylo-glossus, and two ligaments, the stylo-hyoid and stylo-maxillary.

10 The stylo-mastoid foramen, a rather large orifice, placed between the styloid and mastoid processes; it is the termination of the aquæductus Fallopii, and transmits the facial nerve and stylo-mastoid artery.

11 The auricular fissure, situated between the auditory and mastoid processes, for the exit of the auricular branch of the pneumogastric nerve.

46 What forms the external ear?

First it consists of that portion commonly called "the ear," but which is in fact only the portal of that organ, and secondly of the external auditory meatus.

47 What forms the middle ear?

The middle ear or tympanum consists of an irregular shaped chamber about one-fourth of an inch from side to side and half an inch long. It contains air. It has three bones: Malleus, incus and stapes.

48 What forms the internal ear?

The internal ear or labyrinth. This portion is hollowed out in dense bone, and consists of three parts: the vestibule or ante-chamber, which is connected with the other two; cochlea or snail's shell, and the three semicircular canals. The manner in which the nerve of hearing is distributed is remarkable, and is peculiar to this nerve. In the vestibule and the canals its fibres are spread out over the inner surface, not of the bony cavity, but of a membranous bag, which conforms to and partially fills the cavity, and which floats in it, being both filled and surrounded with a clear, limpid fluid.

49 What is sound?

Sound is that form of motion which is capable of affecting the auditory nerve.

50 How is this effect produced?

The sound waves which traverse the external ear strike the tympanic membrane, this is set in vibration which in turn set the malleus, incus and stapes in motion, this set the limpid fluid which is in the labyrinth in motion, thus the nerve-fibres are excited, and an impression is conducted to the brain, and we say sound is heard.

51 What fluids are in the ear?

Endolymph and perilymph.

52 Describe the ear stones.

Within the membranous bag of the labyrinth there are two small stones, and a quantity of fine powder of a calcareous nature, which is called "ear sand." When examined under the microscope these sandy particles are seen to lie scattered upon and among the delicate filaments of the auditory nerve, and it is probable that, as the sound-wave traverses the fluid of the vestibule, the sand rises and falls upon the nerve filaments, and thus intensifies the sonorous impression.

53 Eustachian tube is for what purpose? How long is it? Who was Eustachius?

For letting air to the middle ear to equalize the pressure upon the membrane. An inch and a half long. Eustachius was an Italian anatomist. He died in 1574. He was physician to the pope.

54 Name the cranial nerves.

First olfactory, second ^{optic} auditory, third motor oculi, fourth pathetic or Trochlear, fifth Trifacial or Trigeminus, sixth Abducent, seventh Facial (Portio dura), eighth Auditory (Portio mollis), ninth Glosso-pharyngeal, tenth Pneumogastric (Par vagum), eleventh Spinal accessory, twelfth Hypoglossal.

55 How does the 1st cranial nerve get out of the cranium?

Through the cribriform plate of the ethmoid.

56 How does the 2nd cranial nerve get out of the cranium?

Through the optic foramen.

57 How do the 3rd, 4th, 6th and part of 5th?

Through the Sphenoidal fissure.

58 How does the 2nd division of the 5th?

Foramen rotundum.

59 How does the 3rd division of the 5th?

Foramen ovale

60 How does the 7th and 8th nerve get out of cranial cavity?

Internal auditory meatus.

61 How do the 9th, 10th and 11th nerve get out of cranium?

Through the middle compartment of jugular foramen.

62 How does the 12th nerve get out of the cranium?

Through anterior condyloid foramen.

63 Give difference between the American and English division.

The American division gives twelve nerves, while the English gives nine, calling the 7th, 8th the 7th, and 9th, 10th and 11th the 8th, and the 12th the 9th.

64 Which are the nerves of special sense?

First, or olfactory; 2nd, or optic; and 8th, or auditory.

65 Which are purely motor?

Third, or motor oculi; and 4th or pathetic; 6th or abducent; and 7th or facial; and 12th or hypoglossal.

66 Which are mixed?

{ 5th, or trifacial.

{ 9th, or glosso-pharyngeal.

{ 10th, or pneumogastric.

{ 11th, or spinal accessory.

TABLE OF CRANIAL NERVES.

Classification of Soemmering.	Other Names.	Distribution.	Function.
First	Olfactory	Upper third of nasal cavity.	Spec'l Sense smell
Second	Optic	Retina	Spec'l Sense sight
Third	Oculomotor	Muscles of eyeball except External rectus and Superior oblique.	Motor
Fourth	Trochlear	Superior oblique of eyeball.	Motor
Fifth	Trifacial	{ Sensory part to face, forehead, scalp, external ear, eye, teeth, gum, cheek, fore part of tongue. Motor part to muscles of mastication	Ordinary Sense & Motor
Sixth	Abducent	External muscle of eyeball.	Motor
Seventh	Facial	{ Superficial muscles of face, Frontalis, Platysma, Stylo-hyoid, and posterior belly of Digastric.	Motor
Eighth	Auditory	Membranous labyrinth of ear.	Special sense (Hearing) & Equilibrium.
Ninth	Glosso-pharyngeal	{ Pharynx and hind part of tongue, some motor fibres.	Special sense (taste). Ord'y sense, Motor
Tenth	Pneumogastric or Vagus	{ Sensory to external ear, motor and sensory to pharynx, larynx, trachea, lungs, oesophagus, stomach, heart, sometimes to liver.	Ordinary sense & Motor
Eleventh	Spinal Accessory	{ Motor to Trapezius and Sternomastoid muscles. Rest is accessory to the pneumogastric.	Motor & Ordinary sense
Twelfth	Hypoglossal	Muscles of tongue.	Motor

- 67 The internal meatus extends how far? Is intercepted by what?
About one-third of an inch. By the lamina cribrosa.
- 68 What divides the Cribrosa?
A horizontal crest, the crista falciformis.
- 69 How many openings above? How many below?
Two sets of foramina above the crest, and three sets below it.
- 70 The Mastoid cells are filled with what?
Air and marrow.
- 71 What passes through above the crista falciformis?
Through one opening filaments to the vestibule and superior and external semicircular canals, in front of this opening is the commencement of the aquaeductus Fallopii, for the passage of the facial nerve.
- 72 What passes through below the crista falciformis?
The opening just below the posterior part of the crest is for the nerve to the sacculle, the second one below and external to this is for the nerve to the posterior semicircular canal; the third opening in front and below this for the nerve to the cochlea.
- 73 What structures passes between the external and internal carotid arteries?
Stylo-glo-sus, stylo-pharyngeus muscles, and the glosso-pharyngeal nerve, and pharyngeal branch of pneumogastric.
- 74 Where are the superficial and deep cardiac plexuses situated?
The cardiac plexus is situated at the base of the heart, and is divided into a superficial part, which lies in the concavity of the arch of the aorta, and a deep part which lies between the trachea and aorta.
- 75 How are they formed?
The deep cardiac plexus is formed by the cardiac nerves derived from the cervical ganglia of the sympathetic and the cardiac branches of the recurrent laryngeal and pneumogastric. The only cardiac nerves which do not enter into the formation of this plexus are the left superior cardiac nerve and the left inferior cervical cardiac branch from pneumogastric. The superficial cardiac plexus is formed by those cardiac branches which do not go into the deep plexus, together with filaments from the deep plexus. Occasionally the right inferior cervical cardiac branches of pneumogastric go into this plexus.
- 76 Where is the solar plexus situated and what are its other names?
Solar or epigastric plexus, or abdominal brain. It is situated behind the stomach and in front of the aorta and crura of the diaphragm.
- 77 How is the solar plexus formed?
This plexus, and the ganglia connected with it, receive the great splan-

- nie nerve of both sides, and some filaments from the right pneumogastric. The semi-lunar ganglia of the solar plexus, two in number, one on each side, are the largest ganglia in the body.
- 78 What plexuses are formed from the solar?
From the solar plexus are derived the following:
Phrenic or Diaphragmatic plexus.
Suprarenal plexus.
Spermatic plexus.

Cœliac plexus.	{ Gastric. Splenic. Hepatic.
----------------	------------------------------------

 Superior mesenteric plexus.
 Aortic plexus.
- 79 What nerves enter the cranium before passing out of it?
Nasal, which is a branch of the ophthalmic division of the 5th nerve; spinal accessory or 11th cranial nerve.
- 80 Where is the foramen cœcum?
Is an aperture formed between the frontal bone and the crista galli of the ethmoid, which, if pervious, transmits a small vein from the nose to the superior longitudinal sinus.
- 81 Name the coats of the spinal cord.

{	Dura mater.
{	Arachnoid.
{	Pia mater.
- 82 Name the sinuses in cranium.
The sinuses of the dura mater are venous channels analogous to veins, their outer coat being formed by the dura mater; their inner, by a continuation of the lining membrane of the veins. They are fifteen in number and are divided into two sets: 1st, those at the upper and back part of the skull; 2nd, those at the base of the skull.
The former are:

{	Superior Longitudinal.
{	Inferior Longitudinal.
{	Straight sinus.
{	Lateral sinuses.
{	Occipital sinus.

 The sinuses at base of the skull are:
Cavernous, Circular, Superior Petrosal, Inferior Petrosal, and Transverse.
- 83 Where is the falx cerebri?
The falx cerebri is a fold of the dura mater between the superior and inferior longitudinal sinuses. It is situated in the longitudinal fissure of the brain.
- 84 Where is the falx cerebelli?

Falx cerebelli extends from the tentorium to foramen magnum, and is between the lateral lobes of the cerebellum.

85 Where is the tentorium?

The tentorium cerebelli is a process of the dura mater supporting the posterior lobes of the brain and covering the upper surface of the cerebellum. It encloses the lateral and superior petrosal sinuses.

86 How long, about, is the spinal cord?

About 17 inches.

87 About how long is the thoracic duct?

About 15 inches.

88 From how much of the body does it collect lymph?

From all the body except the right half of the head, the right half of the thorax, with its contents, the upper surface of the liver and the right arm.

89 Where does it empty?

It empties into the left subclavian vein.

90 How long is the right thoracic duct. Where does it empty?

About half an inch in length. It empties into the right subclavian vein.

91 What and where is the torcular Herophili?

The torcular Herophili is the dilated extremity of the superior longitudinal sinus. It is of irregular form, and is lodged on one side (generally the right) of the internal occipital protuberance. From it the lateral sinus of side to which it is deflected is derived. It receives also the blood from the occipital sinus.

92 How many and what muscles are attached to the atlas?

To the atlas are attached nine pairs: the Longus colli, Rectus capitis anticus minor, Rectus lateralis, Obliquus capitis superior and inferior, Splenius colli, Levator anguli scapulae, First intertransverse, and Rectus capitis posticus minor.

93 Same of axis.

To the axis are attached eleven pairs: the Longus colli, Levator anguli scapulae, Splenius colli, Scalenus medius, Transversalis colli, Intertransversales, Obliquus capitis inferior, Rectus capitis posticus major, Semispinalis colli, Multifidus spine, Interspinales.

94 Give blood supply, ossification, articulation, and attachment of muscles of the occipital.

Blood supply: Occipital, posterior auricular, middle meningeal, vertebral and ascending pharyngeal arteries.

Ossification: Varying from 4 to 11 centers.

Articulation: With six bones: two parietal, two temporal, sphenoid, and atlas.

Attachment of muscles: To twelve pairs: to the superior curved line are attached the Occipito-frontalis, Trapezius and Sterno-cleido-mastoid. To the space between the curved lines, the Complexus, Splenius capitis, and Obliquus capitis superior; to the inferior curved line and space between it and the foramen magnum, the Rectus capitis posticus, major and minor; to the transverse process, the Rectus capitis lateralis; and to the basilar process, the Rectus capitis anticus, major and minor, and Superior constrictor of pharynx.

95 Same of parietal.

Blood supply: Middle meningeal, occipital, and supraorbital arteries.

Ossification: One center.

Articulations: With five bones: opposite parietal, occipital, frontal, temporal, and sphenoid.

Attachment of muscles: Only one, the Temporal.

96 Same of frontal

Blood supply: Middle and small meningeal on cerebral surface, frontal and supraorbital on outer surface. The horizontal plate receives twigs from the ethmoidal and other branches of ophthalmic artery.

Ossification: From two centers, one for each lateral half.

Articulation: With twelve bones; two parietal, the sphenoid, the ethmoid, two nasal, two superior maxillary, two lachrymal, and two malar.

Attachment of Muscles: To three pairs: the Corrugator supercillii, Orbicularis palpebrarum and Temporal on each side.

97 Same of Temporal.

Blood Supply: Stylo-mastoid from posterior auricular; it enters the stylo-mastoid foramen.

Tympanic: From internal maxillary; it passes through Glasserion fissure.

Petrosal: From middle meningeal, transmitted by the hiatus Fallopii.

Tympanic: From internal carotid whilst in the carotid canal.

Auditory: From basilar, it enters internal auditory meatus, and is distributed to cochlea and vestibules.

Ossification: Ten centers.

Articulations: With five bones—occipital, parietal, sphenoid, inferior maxillary and malar.

Attachment of Muscles: To fifteen—To the squamous portion, the

Temporal; to the zygoma, the Masseter; to the mastoid portion, the Occipito-frontalis, Sterno mastoid, Splenius capitis, Trachelo-mastoid, Digastricus and Retractus aurem; to the styloid process, the Stylo-pharyngeus, Stylo-hyoideus, and Stylo-glossus; and to the petrous portion, the Levator palati, Tensor tympani, Tensor palati and Stapedius.

98 Same of Sphenoid.

Blood Supply: Middle and small meningeal, anterior deep temporal and other branches of internal maxillary such as Vidian, pterygo-palatine and sphero-palatine. The body receives twigs from internal carotid.

Ossification: Fourteen centers.

Articulation: The sphenoid articulates with all the bones of the cranium, and five of the face—the two malar, two palate, and vomer.

Attachment of Muscles: To eleven pairs: the Temporal, External pterygoid, Internal pterygoid, Superior constrictor, Tensor palati, Levator palpebrae, Obliquus oculi superior, Superior rectus, Inferior rectus, External rectus, Internal rectus.

99 Same of Nasal.

Blood Supply: Nasal branch of ophthalmic, the frontal, the angular, and anterior ethmoidal arteries.

Ossification: One center.

Articulations: With four bones: two of the cranium, the frontal and ethmoid, and two of the face, the opposite nasal and the superior maxillary.

Attachment of Muscles: A few fibres of the Occipito-frontalis muscle.

100 Same of Superior Maxillary.

Blood Supply: Infra orbital, alveolar, descending palatine, ethmoidal, frontal, nasal and facial arteries.

Ossification: Seven centers.

Articulations: With nine bones: two of the cranium, the frontal and ethmoid, and seven of the face—viz., the nasal, malar, lachrymal, inferior turbinated, palate, vomer, and its fellow of the opposite side. Sometimes it articulates with the orbital plate of the sphenoid, and sometimes with its external pterygoid plate.

Attachment of Muscles: To twelve: the Orbicularis palpebrarum, Obliqui oculi inferior, Levator labii superioris alaeque nasi, Levator anguli oris, Compressor nasi, Depressor alae nasi, Dilator naris posterior, Masseter, Buccinator, Internal pterygoid, and Orbicularis oris, Levator labii superioris proprius.

101 Same of Lachrymal.

Blood Supply: Infraorbital, nasal branch of ophthalmic, anterior ethmoidal.

Ossification: One center.

Articulations: With four bones: two of the cranium, the frontal and ethmoid, and two of the face, the superior maxillary and the inferior turbinated.

Attachment of Muscles: To one muscle, the Tensor tarsi.

102 Same of Malar.

Blood Supply: Infra orbital, lachrymal branches of ophthalmic, transverse facial, and deep temporal arteries.

Ossification: Two or three centers.

Articulations: With four bones: three of the cranium, frontal, sphenoid and temporal; and one of the face, the superior maxillary.

Attachment of Muscles: To five: The Levator labii superioris proprius, Zygomaticus major and minor, Masseter and Temporal.

103 Same of Palate.

Blood Supply: Descending palatine, spheno-palatine, and pterygo-palatine.

Ossification: One center.

Articulations: With six bones: the sphenoid, ethmoid, superior maxillary, inferior turbinated, vomer, and opposite palate.

Attachment of Muscles: To four: the Tensor palati, Azygos uvulae, Internal pterygoid and Superior constrictor of the pharynx.

104 Same of Inferior Turbinated.

Blood Supply: —————

Ossification: One center

Articulation: With four bones: one of the cranium, the ethmoid, and three of the face, the superior maxillary, lachrymal, and palate.

Attachment of Muscles: None.

105 Same of Vomer.

Blood Supply: Anterior and posterior ethmoidal, naso-palatine through Stenson's canal.

Ossification: One center.

Articulations: With six bones: two of the cranium, the sphenoid and ethmoid; and four of the face, the two superior maxillary and the two palate bones; and with the cartilage of the septum.

Muscles: None.

106 Same as Inferior Maxillary.

Blood: Branches from internal maxillary.

Ossification: Six centers for each lateral half.

Articulation: With the glenoid fossae of the two temporal bones.

Attachment of Muscles: To fifteen pairs: to its external surface,

commencing at the symphysis, and proceeding backward: Levator menti, Depressor labii inferioris, Depressor anguli oris, Platysma myoides, Buccinator, Masseter; a portion of the Orbicularis oris, (Accessorii orbicularis inferioris) is also attached to this surface. To this internal surface, commencing at the same point: Genio-hyoglossus, Genio-hyoideus, Mylo-hyoideus, Digastric, Superior constrictor, Temporal, Internal pterygoid, External pterygoid.

107 Same of Ethmoid.

Blood Supply: Anterior and posterior ethmoidal, and from nasal or sphero-palatine branch of internal maxillary artery.

Ossification: Three centers.

Articulation: With fifteen bones: the sphenoid, two sphenoidal turbinated, the frontal, and eleven of the face - the two nasal, two superior maxillary, two lachrymal, two palate, two inferior turbinated, and the vomer. No muscles are attached to this bone.

Muscles: None.

108 How many elements in the body?

Of the many elements discovered by the chemists, only sixteen have been found in the healthy human body. Very few exist in it uncombined. Some oxygen is dissolved in the blood; and that gas is also found, mixed with nitrogen in the lungs.

109 Name them.

Of the sixteen elements found in the body, seven are metallic and eight non-metallic, and H has an intermediary place in the list. It is a constituent of both acids and bases, and of the neutral substance, water.

ORDER. --	Negative or Non-metallic elements, Acid-forming with H (usually OH).	{ Carbon Nitrogen Oxygen Sulphur Phosphorus Chlorine Fluorine Silicon
ORDER. - -	Positive or Metallic elements, base-forming with OH.	{ Hydrogen Sodium Potassium Calcium Magnesium Iron Lithium Manganese

110 Name the double-bellied muscles.

Occipito-frontalis, Biventes cervicis, Digastric, Omo-hyoid, and the Diaphragm.

111 What does meatus mean?

A passage.

112 Describe those of the nose.

The superior meatus, the smallest of the three, is situated at the upper and back part of each nasal fossa, occupying the posterior third of the outer wall. It is situated between the superior and middle turbinated bones, and has opening into it two foramina, the spheno-palatine at the back of its outer wall, and the posterior ethmoidal cells at the front part of the outer wall. The opening of the sphenoidal sinus is at the upper and back part of the nasal fossa immediately behind the superior turbinated bone and into a groove, the spheno-ethmoidal recess. The middle meatus is situated between the middle and inferior turbinated bones, and occupies the posterior two-thirds of the outer wall of the nasal fossa. It has two apertures: in front that of the infundibulum, by which the meatus communicates with the anterior ethmoidal cells, and through these with the frontal sinuses; near the center is the orifice of the antrum, which varies somewhat as to its exact position in different skulls. The inferior meatus, the largest of the three, is the space between the inferior turbinated bone and the floor of the nasal fossa. It extends along the entire length of the outer wall of the nose, is broader in front than behind, and presents anteriorly the lower orifice of the canal for the nasal duct.

113 Name all the foramina in the base of the skull and tell what passes through them.

There are numerous foramina at the base of the skull extending from the foramen caecum to the foramen magnum. There are three large fossae in the base of the skull called anterior fossa, middle fossa and posterior fossa. The foramina in the anterior fossa are foramen caecum which transmits a vein to the superior longitudinal sinus and often one from the frontal sinus. This is a single foramen, while the others of this fossa are in pairs; (1) Ethmoidal fissure which transmits the nasal nerve and the anterior ethmoidal vessels; (2) Olfactory—olfactory nerves and nasal branches of the ethmoidal arteries; (3) Anterior ethmoidal—anterior ethmoidal vessels and nasal nerve; (4) Posterior ethmoidal—posterior ethmoidal vessels; (5) Optic foramen—optic nerve and ophthalmic artery.

The middle fossa is on a lower level than the anterior one. It has eight pairs of foramina. (1) Foramen lacerum anterius, or spheroidal fissure; 3rd, 4th, three divisions of the ophthalmic division of the 5th. and 6th cranial nerves; filaments of the cavernous sympathetic plexus; ophthal-

mic vein; recurrent branch from lachrymal artery, orbital branch of middle meningeal artery, and a process of dura mater; (2) foramen rotundum—superior maxillary division of fifth nerve; (3) foramen Vesali—a small vein; (4) Ovale—inferior maxillary division of fifth, small petrosal nerve, and the small meningeal artery, which is a branch of the internal axillary artery; (5) foramen spinosum—middle meningeal artery, meningeal veins, filaments from cavernous plexus; (6) foramen lacerum medium—vidian nerve, a branch from ascending pharyngeal artery, carotid artery and carotid plexus; (7) hiatus Fallopii, for the transmission of the petrosal branch of the Vidian nerve and the petrosal branch of the middle meningeal artery; (8) small foramen, for the passage of the lesser petrosal nerve.

Posterior fossa is on a deeper level than either of the other two. It contains the foramen magnum and six pairs of foramina. (1) Meatus auditorius internus, facial and auditory nerves and the auditory artery; (2) aqueductus vestibuli—small artery and vein, process of dura mater; (3) foramen lacerum posterius, or jugular foramen. In this foramen there are three compartments, through the anterior one passes the inferior petrosal sinus, through the posterior the lateral sinus and some meningeal branches from occipital and ascending pharyngeal arteries; through the middle one the glossopharyngeal, pneumogastric and spinal accessory nerves; (4) mastoid foramen (often absent) small vein, and occasionally the mastoid artery; (5) anterior condyloid—hypoglossal nerve, meningeal branch of ascending pharyngeal artery; (6) posterior condyloid (often absent) posterior condyloid vein; (7) foramen magnum—medulla oblongata and its membranes; spinal accessory nerves; vertebral arteries; anterior and posterior spinal arteries, and the occipito-axial ligaments.

114 Give course of facial nerve.

The facial nerve passes in the internal auditory meatus for about one-fourth of an inch, then passes through the lamina cribrosa above the crista falciformis, then through the aqueductus Fallopii, which opens into the stylo-mastoid foramen. From here its branches are distributed to the muscles of the face.

115 The processus cochleariformis is between what structures?

The Eustachian tube and the canal for the Tensor tympani muscle.

116 What is in the Glasserian fissure?

In the Glasserian fissure—Levator tympani muscle, tympanic artery and the processus gracilis of the malleus.

117 What is in the canal of Huguier?

Chorda tympani nerve, which is a branch of the facial.

118 Give the fractional parts of the ilium that have aponeurosis of muscles attached.

The External oblique forms Poupart's ligament and is attached to the anterior one-half of the outer lip of the crest of the ilium. Internal oblique is attached to one-half of the ligament and the anterior one-third of the middle lip of the crest of the ilium. The Transversalis is attached to one-third of the ligament and to the anterior three-fourths of the internal lip of the crest of the ilium.

119 Name the muscles the aponeurosis of which pass either behind or in front of the Rectus muscle.

The aponeurosis of the External oblique passes in front of the Rectus muscle. That of the Internal oblique passes in front of the lower one-fourth of the Rectus, and divides for the upper three-fourths. That of the Transversalis passes in front for the lower one-fourth, behind for the upper three-fourths.

120 Name and give nerve supply of the muscles attached to the clavicle.

1. Sterno-cleido-mastoid—Nerve { Spinal accessory and
2-3 cervical nerves.
 2. Trapezius —Nerve { Spinal accessory and
3-4 cervical nerves.
 3. Pectoralis major—Nerve, external and internal anterior thoracic.
 4. Deltoid—Nerve, circumflex.
 5. Subclavius—Nerve, 5-6 cervical.
 6. Sterno-hyoid—Nerve { Loop between descendens, and
communicans hypoglossi.
- Sometimes the Sterno-thyroid—Nerve, same as above.

121 Those attached to scapula.

To the scapula there are seventeen: Supraspinatus and Infraspinatus are supplied by the suprascapular nerve; the Deltoid by the circumflex; Trapezius by the spinal accessory and the 3-4 cervical nerves; Subscapularis by the 1st and 3rd subscapular nerves; Serratus magnus by the posterior thoracic nerve; Biceps by the musculo-cutaneous; Triceps by the musculo-spiral; Teres major by the 3rd subscapular; Teres minor by the circumflex; Levator anguli scapulae by the 3rd and 4th cervical; Rhomboideus major and minor by the nerves to the Rhomboidei, which comes from the 5th cervical; Latissimus dorsi by the middle or long subscapular; the Coraco-brachialis by the musculo-cutaneous; Pectoralis minor by the internal anterior thoracic; Omo-hyoid by the branches from the loop of communication between the descendens and communicans hypoglossi.

122 Those attached to the humerus, except those attached to internal and external condyles.

To the greater trochanter—Supraspinatus, Infraspinatus and Teres minor. The first two get the suprascapular nerve, the last one gets the circumflex. To the lesser trochanter the supscapularis, which gets the 1st and 3d suprascapular nerves.

On the external bicipital ridge, the Pectoralis major, which gets the external and internal anterior thoracic nerves.

On the internal bicipital ridge, the Teres major, which gets the third subscapular nerve. In the bicipital groove is the Latissimus dorsi, which gets the middle or long subscapular nerve

On the posterior portion of the humerus is the Triceps which gets the musculo-spiral.

On the lower anterior surface is the Brachialis anticus, which gets the musculo-spiral and the musculo-cutaneous. On the outer side of the shaft about the middle is the Deltoid which gets the circumflex.

On the inner side about the middle is the Coraco brachialis which gets the musculo-cutaneous.

123 Those in superficial layer of anterior radio ulnar region.

See page 10 of this book.

124 Those in deep layer of same.

See page 10 of this book.

125 Those in radial region.

See page 10 of this book.

126 Those in superficial layer of posterior radio ulnar region.

See page 11 of this book.

127 Those in deep layer of same.

See page 11 of this book.

128 Those of the thumb.

See page 11 of this book.

129 Those of little finger.

See page 11 of this book.

130 Those of middle palmar region.

See page 11 of this book.

231 Those supplied by anterior crural nerve.

See page 33 of this book.

132 Those supplied by great sciatic nerve.

See page 33 of this book.

133 Those supplied by obturator nerve.

See page 33 of this book.

134 Those in the superficial layer of posterior tibio-fibular region.

See page 35 of this book.

135 Deep layer of same.

See page 35 of this book

136 Those in anterior tibio fibular region.

See page 34 of this book.

137 Those in fibular or external region.

See page 34 of this book.

138 Describe the temporal fossa.

The temporal fossa is bounded above and behind by the temporal ridge, which extends from the external angular process of the frontal upward and backward across the frontal and parietal bones, curving downward behind to terminate in the posterior root of the zygomatic process. This ridge is generally double—at all events in front, where it is most marked. In front it is bounded by the frontal, malar, and great wing of the sphenoid: externally by the zygomatic-arch, formed conjointly by the malar and temporal bones; below it is separated from the zygomatic fossa by the pterygoid ridge, seen on the outer surface of the great wing of the sphenoid. This fossa is formed by five bones, part of the frontal, great wing of the sphenoid, parietal, squamous portion of the temporal, and malar bones, and is traversed by six sutures, part of the transverse facial, spheno-malar, coronal, spheno-parietal, squamo-parietal and squamo-sphenoidal. The point where the coronal suture crosses the temporal ridge is sometimes named the stephanion; and the region where the four bones, the parietal, the frontal, the squamous, and the greater wing of the sphenoid, meet at the anterior inferior angle of the parietal bone, is named the pterion. This point is about on a level with the external angular process of the frontal bone and about one and a half inches behind it. This fossa is deeply concave in front, convex behind, traversed by grooves which lodge branches of the deep temporal arteries, and filled by the Temporal muscles.

139 Describe the Zygomatic fossa.

The Zygomatic fossa is an irregularly shaped cavity, situated below and on the inner side of the zygoma; bounded, in front, by the tuberosity of the superior maxillary bone and the ridge which descends from its malar process; behind, by the posterior border of the pterygoid process and the eminentia articularis; above, by the pterygoid ridge on the outer surface of the great wing of the sphenoid and the under part of the squamous portion of the temporal; below, by the alveolar border of the superior maxilla; internally by the external pterygoid plate; and externally, by the zygomatic arch and ramus of the lower jaw. It contains the lower part of the Temporal, the External and Internal pterygoid muscles, the internal maxillary artery, and inferior maxillary nerve and their branches. At its

upper and inner part may be observed two fissures, the sphenomaxillary and pterygomaxillary.

140 Describe the sphenomaxillary fossa.

The Sphenomaxillary fossa is a small, triangular space situated at the angle of junction of the sphenomaxillary and pterygomaxillary fissures, and placed beneath the apex of the orbit. It is formed above by the under surface of the body of the sphenoid and by the orbital process of the palate bone; in front, by the superior maxillary bone; behind, by the anterior surface of the base of the pterygoid process and lower part of the anterior surface of the great wing of the sphenoid; internally, by the vertical plate of the palate. This fossa has three fissures terminating in it—the sphenoidal, sphenomaxillary and pterygomaxillary; it communicates with three fossae, the orbital, nasal and zygomatic, and with the cavity of the cranium, and has opening into it five foramina. Of these, there are three on the posterior wall: the foramen rotundum above; below and internal to this, the Vidian; and still more inferiorly and internally, the pterygopalatine. On the inner wall is the sphenopalatine foramen, by which the sphenomaxillary communicates with the nasal fossa; and below is the superior orifice of the posterior palatine canal, besides occasionally the orifices of the accessory posterior palatine canals. The fossa contains the superior maxillary nerve and Meckel's ganglion, and the termination of the internal maxillary artery.

141 Describe the sphenomaxillary fissure.

The Sphenomaxillary fissure, horizontal in direction, opens into the outer and back part of the orbit. It is formed above by the lower border of the orbital surface of the great wing of the sphenoid; below, by the external border of the orbital surface of the superior maxilla and small part of the palate bone; externally, by a small part of the malar bone; internally, it joins at right angles with the pterygomaxillary fissure. The fissure opens a communication from the orbit into three fossae—the temporal, zygomatic, and sphenomaxillary; it transmits the superior maxillary nerve and its orbital branch, the infraorbital vessels, and ascending branches from the sphenopalatine or Meckel's ganglion.

142 Describe the Pterygomaxillary fissure.

The Pterygomaxillary fissure is vertical, and descends at right angles from the inner extremity of the preceding; it is a V-shaped interval, formed by the divergence of the superior maxillary bone from the pterygoid process of the sphenoid. It serves to connect the sphenomaxillary fossa with the zygomatic fossa, and transmits branches of the internal maxillary artery. It forms the entrance from the zygomatic fossa to the sphenomaxillary fossa.

143 Describe the Orbits.

The Orbits are two quadrilateral pyramidal cavities, situated at the upper and anterior part of the face, their bases being directed forward and outward, and their apices backward and inward, so that the axes of the two, if continued backward, would meet over the body of the sphenoid bone. Each orbit is formed of seven bones, the frontal, sphenoid, ethmoid, superior maxillary, malar, lacrymal and palate; but three of these, the frontal, ethmoid and sphenoid, enter into the formation of both orbits, so that the two cavities are formed of eleven bones only. Each cavity presents for examination a roof, a floor, an inner and an outer wall, four angles, a circumference or base and an apex. The roof is concave, directed downward and forward, and formed in front by the orbital plate of the frontal; behind by the lesser wing of the sphenoid. This surface presents internally the depression for the cartilaginous pulley of the Superior oblique muscle; externally, the depression for the lacrymal gland; and posteriorly, the suture connecting the frontal and lesser wing of the sphenoid.

144 Describe the nasal fossa.

The nasal fossae are two large, irregular cavities situated on either side of the middle line of the face, extending from the base of the cranium to the roof of the mouth, and separated from each other by a thin vertical septum. They communicate by two large apertures, the anterior nares, with the front of the face, and by the two posterior nares with the pharynx behind. These fossae are much narrower above than below, and in the middle than at the anterior or posterior openings; their depth, which is considerable, is much greater in the middle than at either extremity. Each nasal fossa communicates with four sinuses, the frontal above, the sphenoidal behind, and the maxillary and ethmoidal on the outer wall. Each fossa also communicates with four cavities: with the orbit by the lacrymal groove, with the mouth by the anterior palatine canal, with the cranium by the olfactory foramina, and with the sphenomaxillary fossa by the sphenopalatine foramen; and the occasionally communicate with each other by an aperture in the septum. The bones entering into their formation are fourteen in number: three of the cranium, the frontal, sphenoid and ethmoid, and all the bones of the face, excepting the malar and lower jaw. Each cavity is bounded by a roof, a floor, an inner and an outer wall.

The ethmoid bone with all the bones it articulates with make the nasal fossae. The frontal, sphenoid and ethmoid are common to the nasal fossae and the orbits.

145 Describe the Hyoid bone.

The hyoid ('like Greek letter epsilon') or lingual bone is a small

V-shaped bone which may be felt at the base of the tongue, between the chin and the thyroid cartilage. It has a body and two pairs of cornua. The oblong body has a smooth, concave posterior surface, looking backward and downward toward the epiglottis. Its convex anterior surface, looking upward and forward, is divided by a transverse and sometimes a median vertical ridge into depressions for muscular attachment. The superior border attaches the thyro-hyoid membrane. The great cornua taper backward and upward from the sides of the body, ending in rounded tubercles to which the thyro-hyoid ligaments are attached.

The cornua are flattened above and afford attachment to muscles. The small cornua are small conical pieces of bone, often partly and sometimes wholly, cartilaginous which project upward and backward from the junction of the great cornua and the body. Their extremities attach the stylo-hyoid ligaments, which suspend the hyoid bone from the styloid processes of the temporal bones. There is a center of ossification for each corau and for each lateral half of body.

Attachment of Muscles: Sterno-hyoid, Thyro hyoid, Omo-hyoid, aponeurosis of the Digastric, Stylo-hyoid, Mylo-hyoid, Genio-hyoid, Genio-hyo-glossus, Chondro-glossus, Hyo-glossus, Middle constrictor of the pharynx, and occasionally a few fibres of the Lingualis. It also gives attachment to the thyro-hyoidean membrane and the stylo-hyoid, thyro-hyoid and hyo-epiglottic ligaments.

146 Describe the vidian canal

The vidian canal is one of the ten openings which open external to base of skull. It is for the passage of the vidian nerve and vessels. It is in the pterygoid process of the sphenoid. The vidian nerve is formed by the great superficial petrosal from the facial and the great deep petrosal from the carotid plexus.

147 Describe the Otic ganglion.

The Otic (ear) ganglion is a small, reddish gray, oval body, compressed from side, and about one-sixth of an inch in its longest diameter. It is closely attached to, or may surround, the nerve to the internal pterygoid muscle, lying on the inner side of the mandibular trunk close to the foramen ovale. Behind it is the middle meningeal artery, and on its inner side are the Eustachian tube and Tensor palati muscle. Its motor and sensory roots reach it through the nerve to the internal pterygoid muscle; but it is also connected with the facial and glosso-pharyngeal nerve through the small superficial petrosal nerve. From the plexus round the middle meningeal artery it receives its sympathetic root. It distributes branches to join the auriculo-temporal, by which route the parotid gland is supplied from

the glosso-pharyngeal nerve, also muscular twigs to the Tensor palati and Tensor tympani, and a communicating filament to the Chorda tympani nerve. Of the muscular fibres most may be traced to the trunk of the mandibular division of the fifth nerve, without interruption in the ganglion cells.

148 Describe Meckel's ganglion.

The spheno-palatine ganglion (Meckel's), the largest of the cranial ganglia, is deeply placed in the spheno-maxillary fossa, close to the spheno-palatine foramen. It is triangular or heart-shaped, of a reddish-gray color, and is situated just below the superior maxillary nerve as it crosses the fossa.

Like the other ganglia of the fifth nerve, it possesses a motor, a sensory, and a sympathetic root. Its sensory root is derived from the superior maxillary nerve, through its two spheno-palatine branches. These branches of the nerve, given off in the spheno-maxillary fossa, descend to the ganglion. Their fibres, for the most part, pass in front of the ganglion, as they proceed to their destination, in the palate and nasal fossa, and are not incorporated in the ganglionic mass; some few of the fibres, however, enter the ganglion, constituting its sensory root. Its motor root is derived from the facial nerve through the large superficial petrosal nerve, and its sympathetic root from the carotid plexus, through the large deep petrosal nerve. These two nerves join together to form a single nerve, the Vidian, before their entrance into the ganglion.

149 Describe the ligaments of Zinn.

The ligament of Zinn is attached around the circumference of the optic foramen, except its upper and outer part.

150 Name and give nerve supply of the muscles in the cranial region.

Cranial region: Occipito-frontalis—facial nerve.

151 Auricular region.

Attollens aurem }
 Attrahens aurem } Facial nerve.
 Retrahens aurem }

152 In palpebral region.

Orbicularis palpebrarum }
 Corrugator supercili } Facial nerve.
 Tensor tarsi }

153 In orbital region.

The Levator palpebrae, Rectus superior, Rectus inferior, Rectus internus, and Obliquus inferior are supplied by the 3rd nerve; the Rectus externus, by the 6th; Obliquus superior, by 4th.

154 In nasal region.

- Pyramidalis nasi
 Levator labii superioris alaeque nasi
 Dilatator naris posterior
 Dilatator naris anterior
 Compressor nasi
 Compressor narium minor
 Depressor alae nasi
- } Facial nerve.
- 155 In superior maxillary region.
- Levator labii superioris
 Levator anguli oris
 Zygomaticus major
 Zygomaticus minor
- } Facial nerve.
- 156 In inferior maxillary.
- Levator labii inferioris
 Depressor labii superioris
 Depressor anguli oris
- } Facial nerve.
- 157 In intermaxillary region.
- Buccinator, by facial and by buccal branch of inferior maxillary.
 Risorius, by facial.
 Orbicularis oris, by facial.
- 158 In temporo-maxillary region.
- Masseter } Inferior maxillary
 Temporal } nerve.
- 159 In pterygo-maxillary region.
- Pterygoideus externus } Inferior max-
 Pterygoideus internus } illary nerve.
- 160 Muscles of neck.
- (a) Superficial region :
- Platysma myoides, facial and superficial branch of cervical plexus.
 Sterno-cleido-mastoid, spinal accessory and deep branch of cervical plexus.
- (b) Infra-hyoid region :
- Depressors of the os hyoides and larynx.
 Sterno-hyoid } These by the loop of communication between
 Sterno-thyroid } the descendens and communicans hypoglossi.
 Thyro-hyoid, by the hypoglossal.
- Omo-hyoid { By the loop of communication between
 } the descendens and communicans hypoglossi.
- (c) Supra-hyoid region :
- Elevators of the os hyoides and larynx.
 Digastric { anterior belly, by mylo-hyoid branch of inferior dental.
 } posterior belly, by the facial.

- Stylo-hyoid, by the facial.
 Mylo-hyoid, by mylo-hyoid branch of the inferior dental.
 Genio-hyoid, by the hypo-glossal.
- (d) Lingual region :
- Muscles of the tongue.
 Genio-hyo-glossus }
 Stylo-glossus } Hypoglossal
 Hyo-glossus }
 (Chondro-glossus) }
 Lingualis }
- Palato-glossus, probably innervated by spinal accessory nerve, through the pharyngeal plexus.
 Inferior lingualis, according to some authors, by the chorda tympani.
- (e) Muscles of the pharynx :
- Constrictor inferior }
 Constrictor medius } Branches from pharyngeal plexus.
 Constrictor superior }
- Palato-pharyngeus, internal branch of spinal accessory.
 Stylo-pharyngeus, by glosso-pharyngeal nerve.
 Constrictor inferior is also supplied by an additional branch from the external laryngeal nerve and by the recurrent laryngeal.
- (f) Muscles of the soft palate :
- Tensor palati, by a branch from the otic ganglion.
 Levator palati }
 Azygos uvulae } Internal branch
 Palato-glossus } of
 Palato-pharyngeus } spinal accessory.
 Salpingo-pharyngeus }
- (g) Muscles of the anterior vertebral region :
- Rectus capitis anticus major } First cervical nerve, and
 Rectus capitis anticus minor } from loop formed be-
 Rectus lateralis } tween it and the second.
- Longus colli, by branches from the anterior divisions of the lower cervical nerves (5th, 6th, 7th, and 8th) before they form the brachial plexus.
- (h) Muscles of the lateral vertebral region.
- Scalenus anticus }
 Scalenus medius } Same as Longus colli.
 Scalenus posticus }
- Scalenus medius also receives a filament from the deep external branches of the cervical plexus
- (i) Muscles of the larynx.
- Included in the description of the larynx.
- 161 Superficial muscles of abdomen.

Obliquus externus }
 Obliquus internus }
 Transversalis } Lower intercostal nerve.
 Rectus }
 Pyramidalis }
 (Cremaster) }

Internal oblique also gets fibres from the ilio-inguinal nerve.

162 Deep muscles of abdomen.

Psoas parvus }
 Psoas magnus } *The Iliacus by anterior crural nerve.
 *Iliacus }
 Quadratus lumborum } Anterior branches of lumbar nerves.

163 What is the longest anastomosis in the body?

That between the subclavian and the external iliac by the anastomosis of the superior epigastric, which is a branch of internal mammary, with the deep epigastric, which is a branch of the external iliac.

164 What is the circle of Willis?

An anastomosis at the base of the brain, between the branches of the internal carotid and vertebral arteries to equalize the cerebral circulation. The two vertebral arteries join to form the basilar which ends in the two posterior cerebral. These are connected with the internal carotid by the two posterior communicating.

The circle is completed by the connection of the two anterior cerebral branches of the internal carotid through the short anterior communicating artery.

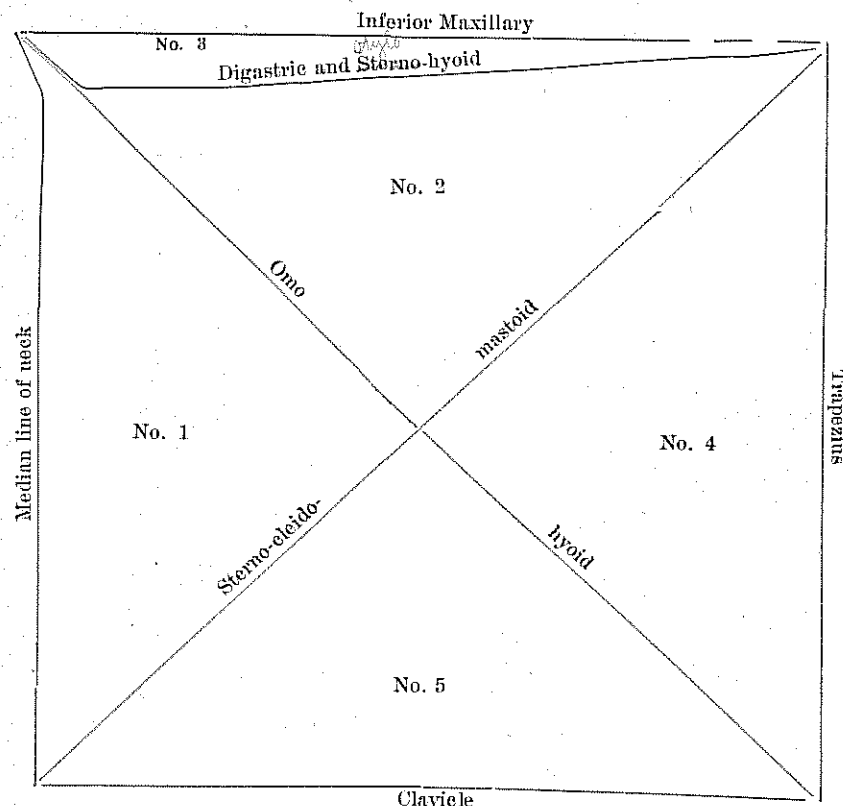
165 What important relations have the 3d and 5th cervical and 2nd lumbar vertebra?

The 3d cervical corresponds to—the bifurcation of the common carotid artery, and the superior cervical ganglion.

The 5th cervical, to—the junctions of the larynx with the trachea, and the pharynx with the œsophagus, and the middle cervical ganglion of the sympathetic.

The 2d Lumbar, to—the junction of the duodenum with the jejunum, the commencement of the thoracic duct and the portal vein, the origin of the superior mesenteric artery, the lower margin of the pancreas, the opening of the ductus communis choledochus, the lower end of the spinal cord, and the crura of the diaphragm.

166 { Draw the rectangle of the neck.
 { Divide it into its triangles and name them.



No. 1 Is the inferior carotid triangle.

No. 2 Is the superior carotid triangle.

No. 3 Is the sub-maxillary triangle.

No. 4 Is the occipital triangle.

No. 5 Is the sub-clavian triangle.

167 Name ten pairs of openings external to base of skull.

1 For the Eustachean tube, letting air to the middle ear

2 For tensor Tympani muscle.

3 Vidian canal, the vidian nerve and vessels.

4 Glasserian Fissure, Laxator tympani muscle, tympanic artery and the processus gracilis of the malleus.

5 Opening of the canal of Huguier, Chorda tympani nerve.

6 Opening for Jacobson's nerve, tympanic branch of 9.

7 Opening of the aqueductus cochleae, vein to cochlea.

8 Foramen for Arnold nerve, auricular branch of 10.

- 9 Stylo-mastoid Foramen, facial nerve, stylo-mastoid artery.
 10 Auricular fissure, exit of Arnold's nerve.

168 Name those on the face.

- 1 Supraorbital Foramen or notch for supraorbital vessels and nerve.
- 2 Infraorbital Foramen, for infraorbital vessels and nerve.
- 3 Mental Foramen for mental vessels and nerve.

In the malar bone we have malar foramina for the passage of vessels and nerves.

169 Name those in roof of mouth.

In each half there are:

- 1 Incisive foramina for nerves and vessels to incisor teeth.
- 2 In the middle of the roof of the mouth there are two anterior palatine foramina, for anterior palatine vessels and naso palatine nerves.
- 3 Posterior palatine for posterior palatine and anterior or large descending palatine nerve.
- 4 Accessory palatine, for posterior palatine nerve.
- 5 Pterygo-palatine, for pterygo-palatine vessels.

170 Name and give nerve supply of the muscles that are exclusively connected to bones of thorax.

- 1 External intercostal.
- 2 Internal intercostal.
- 3 Infracostales.
- 4 Triangularis sterni.
- 5 Levatoris costarum.

Nerve supply is intercostal nerves.

QUESTIONS AND ANSWERS ON THE VISCERA.

SUB-DIVISION—ALIMENTARY CANAL.

1 What does the word Viscus mean?

Any internal organ of the body is a viscus.

2 Where are the viscera situated?

They are situated in the cranium, thorax, abdomen and pelvis.

3 What is the Alimentary Canal?

It is a musculo-membranous tube about 30 feet long, lined throughout with mucous membrane. It extends from the mouth to the anus.

4 Name its different parts.

Mouth, pharynx, oesophagus, stomach, small intestine, which has three divisions—duodenum, jejunum and ileum, and large intestine, which

has three divisions—caecum, colon and rectum. The diaphragm lies immediately above the stomach.

5 What are the accessory organs to this canal?

They are the teeth, salivary glands, which are three—the parotid, sub-maxillary, sub-lingual—Liver, Pancreas and Spleen.

6 How many tunics has the alimentary canals?

All of the canal above the diaphragm has three coats, which are from within outward the mucous membrane, the areolar tissue, and muscular. That portion of the canal which lies below the diaphragm has a fourth coat called the serous membrane.

7 What are the teeth and how many are there?

The teeth are dense, white structures, firmly implanted in sockets in the alveolar processes of the jaw bones. Each consists of three portions—a root or fang, a neck and a crown.

The teeth grow in two sets one in infancy the other in childhood and youth.

The first set are called temporary, milk, deciduous teeth and are twenty in number, there being five in each lateral half jaw, namely two incisors, one canine, and two molars. In this set there are no bicuspid and no third molar. The bicuspid of the permanent set take the place of the temporary molars.

In the second or permanent set there are thirty-two teeth; eight in each half jaw, two incisors, one canine, two bicuspid and three molars.

8 Give blood and nerve supply of teeth.

The arteries are derived from the inferior dental, and from the alveolar and infraorbital branches of the internal maxillary. The nerves are from the inferior dental branch of the inferior maxillary division of the 5th, and also from the anterior and posterior dental branches of the superior maxillary division of the same nerve.

9 What is the greatest number of teeth at one time in the jaws?

Just before the six-year molars are erupted from the gum forty-eight teeth in various stages of formation and retrogression can be recognized in the two jaws—twenty of the temporary set and twenty-eight of the permanent. The four wisdom teeth at this time are only embryonic buds.

10 What kind of muscles are found in the tongue?

Two kinds—intrinsic and extrinsic. The intrinsic muscles are the Superior lingualis, Inferior lingualis, Transverse lingualis and Vertical lingualis.

They are all supplied by the hypoglossal nerve. Some say the Inferior

lingualis gets the Chora-tympani.

The extrinsic muscles are the Genioglossus, Hyoglossus, Stylo-glossus and Chondroglossus. Nerve to these is the hypoglossal.

11 What does papilla mean and what ones are found on the tongue?

It means a bud, a nipple, a teat, a pimple. The lingual mucous membrane of the dorsum of the tongue is peculiar in several respects. It consists of a layer of connective tissue forming a corium supporting special papillae covered with epithelium. The corium is a network in which ramify numerous vessels and nerves. The papillae are of three kinds:

1 Large circumvallate ("walled around") papillae, seven in number, set in a **A** at the back of the tongue, shaped like truncated cones set on end in cup-like depressions, whence the name.

2 Middle-sized fungiform ("mushroom shaped") papillae scattered irregularly over the surface, forming rounded red eminences like mushrooms, whence their name.

3 Small conical or filiform ("thread-shaped") papillae covering the anterior two-thirds of the surface, each ending in a number of little processes. It is these that are concerned in the whitish coating or furring of the tongue. Besides these papillae there are several other simple ones.

12 What are taste-buds?

Occupying the entire thickness of the epithelium of the lateral surface of the papillae is a multitude of flask-shaped bodies, called taste-buds. They are composed of two kinds of epithelial cells gustatory and sustentacular, packed together closely. The microscopic structure of some papillae include certain bodies called taste-buds. Taste-buds are scattered also over the dorsal surface independently of papillae, and are especially numerous in posterior part.

13 Give nerve supply of tongue.

The nerves of the tongue are in four pairs

The hypoglossal is the motor nerve to the tongue.

The lingual (gustatory) or trifacial is distributed to the anterior two-thirds of the dorsum of tongue and also to sides of tongue. This nerve is one of sensation.

The lingual branch of glosso-pharyngeal is specially concerned in gustation (taste) and is distributed to the posterior one-third of dorsum and sides of tongue.

The function of the lingual branch of the facial (Chorda-tympani) is still in question. Its distribution is about the same as the lingual branch of the fifth. Some say it is a nerve of taste for the anterior two-thirds of the tongue. Others that it supplies the Inferior lingualis muscle,

Some authorities say that the anterior two thirds of tongue is supplied by the glosso-pharyngeal through the chorda-tympani.

14 Give blood supply of tongue.

The arteries of the tongue are derived chiefly from the lingual, the facial and ascending pharyngeal.

The veins of the tongue accompany the arteries.

15 How many kinds of glands has the tongue?

Two—mucous and serous.

The mucous glands are found all over the surface of the mucous membrane of the tongue. The serous are found only at the back of the tongue.

16 What is the fraenum lingual—foramen caecum?

The fraenum lingual is a fold of the mucous membrane of the mouth, which binds down the under surface of the tongue, and sometimes requires to be cut from too great restriction or from extension too far forward, causing the subject to be tongue-tied. Fraenum lingual means bridle of tongue.

The dorsum of the tongue is convex, marked along the middle line by a raphe, which divides it into symmetrical halves; this raphe terminates behind, about an inch from the base of the organ, in a depression, the foramen caecum.

17 Is the tongue the only organ of taste?

The tongue is not the only organ of taste as taste-buds are found on the back part of hard palate, on anterior part of soft palate, and to some extent in other parts of the pharynx

18 Tell about the lymphatics of the tongue.

The lymphatic vessels from the tongue pass to one or two small glands situated on the Hyo-glossus muscle in the sub-maxillary region, and from thence to the deep glands of the neck.

19 What is the pharynx?

The throat, technically the joint opening of the gullet and the wind-pipe. It is a musculo-membranous pouch situated at the back of the nasal cavities, mouth and larynx and extending from base of skull to the cricoid cartilage.

20 What does it communicate with below?

The oesophagus.

21 It communicates above with what?

Nasal cavities, Eustachean tube, mouth and larynx.

22 What are the dimensions of the pharynx?

About five inches long. It is widest (nearly one inch and a half) in upper laryngeal portion, and narrow above and below, having it least

diameter (half an inch) at its junction with the gullet.

Ventro-dorsally its measurement is everywhere small, only opposite the mouth being more than four-fifths of an inch. It is a cavity situated in front of the upper five cervical vertebrae.

23 What other system does the pharynx belong to besides the alimentary?
The respiratory system

The middle segment of the pharynx is common to the alimentary and respiratory systems, and the tracts followed by the food and air cross obliquely in it.

24 What tunics has the pharynx?

It has the mucous, areolar and muscular.

25 Name the muscles of the pharynx.

Superior constrictor.

Middle constrictor.

Inferior constrictor.

Stylo-pharyngeus.

Palato-pharyngeus

The constrictors are supplied by branches from the pharyngeal plexus, Stylo-pharyngeus by the glosso-pharyngeal nerve, and the Inferior constrictor gets in addition a branch from the external laryngeal nerve and by the recurrent laryngeal.

The ~~Glosso~~^{Palato}-pharyngeus probably gets its nerve supply from the internal branch of the spinal accessory, whose fibres are distributed along with certain branches of the pneumogastric through the pharyngeal plexus.

26 How is the Pharyngeal plexus formed?

This plexus is formed by branches of the vagus, sympathetic and glosso-pharyngeal. It supplies the muscles and mucous membrane of the pharynx.

27 Give blood supply of the pharynx.

Superior thyroid branches, Ascending pharyngeal, Pterygo-palatine, Descending palatine. First two are branches of External carotid, last two are branches of Internal maxillary.

28 What is the sinus of Morgagni?

This sinus is a space at the upper and back part of the Superior constrictor of the pharynx, just under base of skull, where the muscular fibres of the constrictor are deficient, the pharynx being consequently walled in behind by its own aponeurosis. Here the Eustachian tube opens into pharynx on each side.

29 What and where are the tonsils?

They are two prominent oval bodies, situated in the recesses formed

one on each side of the fauces, between the anterior and posterior palatine arches. They are composed of lymphoid follicles, surrounded by less dense lymphoid tissue, arranged around the walls of crypts.

They lie near the internal carotid artery.

30 Give blood supply of the tonsils.

Dorsalis lingual from the lingual; ascending pharyngeal from external carotid; ascending palatine from facial; tonsillar from facial; descending palatine from internal maxillary. The veins of the tonsil form a plexus which lies upon the outer side of the gland, and opens externally into the pharyngeal plexus.

31 Give nerves of the tonsils.

The nerves come from the fifth by means of Meckel's ganglion and from glosso-pharyngeal.

32 Where is Steno's duct?

This is a duct of the parotid gland, conveying saliva into the mouth; so named from the Danish anatomist, Nicholas Steno, of Copenhagen, (1638-86); also called parotid duct.

33 Where is Wharton's duct?

Named for Thomas Wharton, an English physician, 1656. The duct of the submaxillary gland, conveying saliva into the mouth, about two inches long, opening on a papilla at the side of the frenum linguae, or bridle of the tongue.

34 Where are the ducts of Rivinus?

Those ducts of the sublingual gland which open apart from one another and from Wharton's duct.

35 Where is the duct of Bartholin?

One of the ducts of the sublingual gland, running alongside of Wharton's duct, and opening into it or close to its orifice into the mouth.

36 What is the hard palate?

It is in the roof of the mouth and is formed by the palate processes of the superior maxillary and palate bones.

37 What is the soft palate?

It is a movable fold suspended from the posterior border of the hard palate, forming an incomplete septum between the mouth and pharynx.

38 Name muscles of soft palate and give nerve supply to them.

Levator palati,

Tensor palati,

Azygos uvulae,

Palato-glossus,

Palato-pharyngeus.

Tensor palati is supplied by the Otic ganglion. The remaining muscles of this group are in all probability supplied by the internal branch of

the spinal accessory, whose fibres are distributed along with certain branches of the pneumogastric through the pharyngeal plexus.

39 What is the gullet or œsophagus?

The œsophagus (carrying eatables) is a tube connecting the pharynx and stomach. It is about ten inches long, extending from the upper border of the sixth cervical vertebra to that of the eleventh thoracic.

40 How many tunics has the œsophagus?

Three: internal, or mucous; middle, or areolar; and external or muscular.

41 Give blood supply of œsophagus.

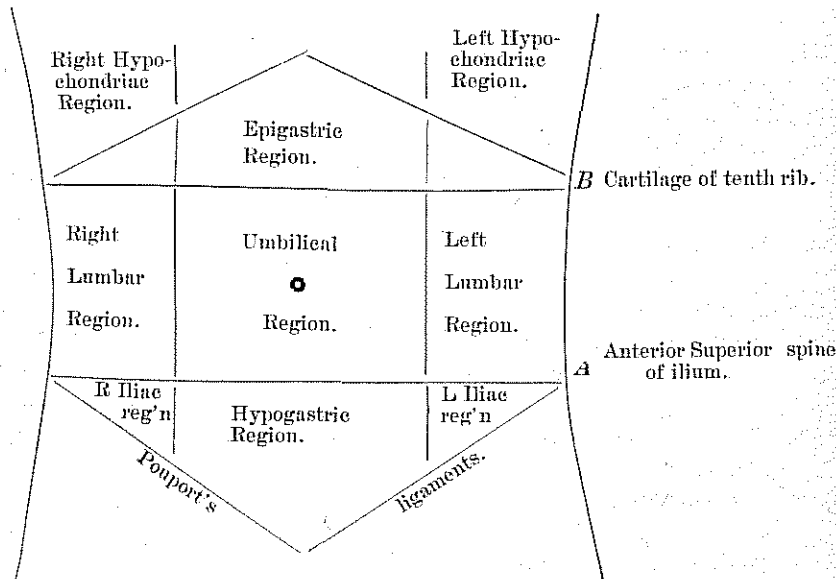
Inferior thyroid, which comes from the thyroid axis of the subclavian; branches from descending thoracic aorta; and from the gastric branch of coeliac axis of abdominal aorta.

42 Give nerve supply.

From the pneumogastric and sympathetic. They form a plexus in which are groups of ganglion-cells between the two layers of the muscular coats, and also second plexus in the submucous tissue.

43 Name the regions of the abdomen.

There are nine regions of the abdomen. Draw a line connecting the two anterior superior spines of the ilium; another parallel to this at the lowest part of the tenth costal cartilage. These two lines divide the abdomen in three divisions. Now draw two vertical lines from the middle of the two Poupart's ligaments. These lines will divide each of the three regions of the abdomen into three other divisions, thus making nine divisions of the abdomen.



Epigastric ("upon the stomach")
Hypochondriac ("under the cartilage")
Hypogastric ("under the stomach").

44 What is the mediastinum?

Medius, the middle; and sto, I stand.

In man the pleural folds do not meet, and the term mediastinum is extended to the space between them.

45 What does it contain?

It contains all of the thoracic viscera, except the lungs.

46 Give the divisions with contents.

Anterior mediastinum, the space between the sternum and the pericardium, contains the Triangularis sterni muscle, parts of other muscles, areolar tissue, lymphatic glands, etc.

The Middle mediastinum, nearly the same as the pericardiac cavity, contains the heart, ascending aorta, pulmonary artery, and superior vena cava, which are within the pericardium, and the phrenic nerves, roots of the lungs and lymphatic glands.

The Posterior mediastinum, the space between the spine and the pericardium, contains the descending aorta, azygos veins, thoracic duct, œsophagus, pneumogastric and splanchnic nerves.

The Superior mediastinum, is the space corresponding to the upper part of the sternum, extending from the manubrium in front to spine behind. It contains the trachea, œsophagus, thoracic duct, arch of aorta and the origin of the large arteries, the large veins, phrenic and pneumogastric nerves, thymus gland, etc.

47 What is the stomach?

The stomach is the most dilated and most distensible part of the alimentary canal.

48 Where is it situated, and what is its form and weight?

It occupies parts of the left hypochondriac and epigastric regions of the abdomen, immediately within the abdominal walls below the diaphragm and partly under the liver, to the right of the spleen and above the transverse colon. In form it is irregularly conoidal, and curved upon itself. When moderately distended it is about 12 inches long and 4 inches wide; it weighs 3 or 4 ounces. The size, shape and, hence, anatomical relations differ greatly in different states of distention.

The stomach is somewhat like a pear with the large end up and the small end bent sidewise to the right.

49 Name some of the principal points of the stomach.

First, the Fundus or splenic end is connected to the spleen by the gastro-splenic omentum. We might mention that an omentum is a special mesentery connecting the stomach with the liver, spleen and colon, respectively. The one that connects it to the spleen is called gastro-splenic

omentum. The one that connects it to the liver is called the gastro-hepatic omentum, and the one to the colon is called the gastro-colic omentum.

Second, the Pylorus, or lesser end, lies near the cartilage of the eighth rib, in contact with the under surface of the liver.

Third, the stomach has two curves a greater and lesser. The greater is convex and is connected to the colon by the gastro-colic omentum. The lesser one is concave and is connected to the liver by the gastro-hepatic omentum, and to the diaphragm by the gastro-phrenic ligament

Fourth, the oesophageal or cardiac orifice is situated between the fundus and the lesser curvature

The pyloric (janitor) is situated at the extreme right, and is more anterior in position than the cardiac orifice.

50 How many tunics has the stomach?

It has four: Serous, muscular, areolar or sub-mucous, and mucous.

51 Describe the serous coat.

The serous coat (peritoneum) encloses the stomach between two layers, derived from the lesser omentum.

The lesser omentum, omentum minus, or gastro-hepatic, is a single fold (two layers) of peritoneum, extending between the transverse fissure of the liver and the lesser curvature of the stomach. It might be well to explain the greater omentum, omentum magnus or gastro-colic omentum, also called epiploön. It is the largest of all peritoneal duplications, and consists of four layers of peritoneum attached to the greater curvature of the stomach and to the transverse colon, whence it is looped down freely upon the intestines, forming a great flap or apron.

52 Describe the muscular coat.

The muscular coat has two distinct layers—an outer, longitudinal, and an inner, circular. Besides these two distinct layers some oblique fasciculi are found, internal to the circular.

53 Describe the areolar coat.

The areolar, submucous, also called vascular, is loose, and its meshes are largely occupied with the vessels and nerves going to and from the coats between which it lies.

54 Describe the mucous coat.

The mucous coat is thrown into irregular longitudinal folds called (rugae). The rugae invade the mucous and submucous coats.

55 Name the glands of the stomach.

They are of two kinds. The cardiac, or proper gastric glands, also called peptic (digest); and the pyloric glands.

55a Give nerve supply of stomach.

Right and left pneumogastric, and branches from the solar plexus of sympathetic nerves.

56 Give blood supply of stomach.

From the coeliac axis there is the gastric artery, which runs along the lesser curve from left to right, anastomosing with the pyloric branch of the hepatic. Along the greater curve run the right and left gastro-epiploic arteries, anastomosing at the middle of the border, the left being a branch of the splenic, the right a branch of the hepatic through the gastro-duodenalis artery. The stomach also receives branches from the splenic (vasa brevia) at the fundus. The blood of the stomach is returned into the portal vein; the right gastro-epiploic vein opens into the superior mesenteric, the left into the splenic.

57 Give lymphatics of stomach.

The lymphatics are numerous; they consist of a superficial and deep set, which pass through the lymphatic glands forward along the two curvatures of the stomach.

58 What is the peritoneum?

It is a strong, uncolored, transparent, serous membrane, with a smooth, moist, shining surface, attached to the subjacent structures by the sub-peritoneal areolar tissue, and forming a closed sac, except in the female, where it is continuous with the mucous membrane of the Fallopian tubes, or oviducts.

59 Give the reflections of the peritoneum.

From the walls of the abdominal and pelvic cavities it is reflected at various places over the viscera, which it serves to invest and at the same time hold in position by its folds or duplicatures. These folds or duplicatures are of various kinds. Some of them constituting the mesenteries, connect certain parts of the intestinal canal with the posterior abdominal walls, others form the so-called ligaments of the liver, spleen, stomach, and kidneys, the broad ligaments of the uterus, the suspensory ligament of the bladder; still others from the omenta, folds attached to the greater and lesser curvatures of the stomach.

60 Give external and internal peritoneum.

That part which lines the abdominal and pelvic walls is called the parietal or external peritoneum; that which more or less completely invests the viscera, the visceral or internal.

61 Where is Winslow's foramen?

The communication between the greater and lesser cavities of the peritoneum is called the foramen of Winslow.

The cavity of the peritoneum is divided into two unequal parts by the constriction at Winslow's foramen; of these, the upper posterior one, lying back of and below the stomach and liver, is called the lesser cavity; the greater cavity lies in front and below.

62 What passes through the foramen of Winslow?

Nothing.

63 Give location and dimensions of small intestine (*intestinum tenui*).

The small intestine extends between the stomach above and the large intestine below. Its average length is about 22 feet. It may be as many as 34 feet or as few as 8 feet in length.

Its diameter diminishes in size from about two inches above to less than one inch below. It is to a large extent within the area bounded by the colon, occupying the umbilical and hypogastric regions and the adjacent portions of the lumbar.

64 How many coats has it?

It has four coats, which correspond in general arrangement and character to those of the stomach. They are the serous, muscular, areolar, and mucous.

65 What are the divisions of the small intestine?

They are the duodenum (12 finger intestine), jejunum (empty intestine), and ileum (curved or twisted intestine).

66 What are the villi?

They are small projections on the mucous membrane of the small intestines, which are so numerous as to give it a velvety appearance. They are from four to ten millions in number. They collectively constitute the beginning of the absorbent or lacteal vessels of the intestine.

67 What are the *valvulae conniventes*?

They are transverse folds of the mucous membrane and underlying tissues found throughout a large extent of the small intestine. Their use is probably to retard somewhat the passage of the alimentary mass, and at the same time to offer a greater surface for absorption.

68 What glands are found in the small intestine?

Lieberkühn glands, crypts, are the simple or solitary glands of the intestine, also in large intestine and stomach. Brunner glands [so called from J. K. Brunner (1653-1727)], sometimes called duodenal glands are small compound glands of the duodenum and upper part of the jejunum, embedded in the submucous tissue, opening by minute orifices into the lumen of the intestine.

Then there are the solitary lymph-nodes, which are more frequently called solitary glands, though no more entitled to the name than the nodes,

which occur in the course of lymphatic vessels, having no secreting apparatus.

Peyer's Patches are found in the lower ileum. They are oval, are from one-half to three inches in length, and about an inch in breadth. They are placed the long axis of the bowel. These patches were named after J. K. Peyer, a Swiss anatomist (1653-1712). A lesion of these patches is one of the most constant signs of typhoid fever.

69 Give blood supply of small intestine.

The small intestine receives the blood from the superior mesenteric artery, and a branch coming indirectly from the hepatic, the superior pancreatico-duodenal. The superior mesenteric runs between the layers of the mesentery, and gives off 12 or 15 branches running downwards and to the left (*vasa intestini tenuis*), which break up and form a series of arches, finally encircling the intestine as small branches. It also gives off a small branch at the beginning, the inferior pancreatico-duodenal, which with the superior pancreatico-duodenal, forms an arch, which lies in the concavity of the duodenum, and which supplies it. The blood is returned by means of the superior mesenteric vein which, with the splenic, forms the portal vein.

70 Give lymphatics of small intestine.

The lymphatics form a continuous series, which is divided into two sets—that of the mucous membrane and that of the muscular coat. The lymph-vessels of both sets form a copious plexus and end in the mesenteric lacteals.

71 Give nerve supply of small intestine.

The small intestine is supplied by means of the superior mesenteric plexus, which is continuous with the lower part of the solar plexus. The branches follow the blood-vessels, and finally form the two plexuses, one (Ouerback's) which lies between the muscular coats; and another (Meissner's) in the submucous coat.

72 What glands are found in the stomach and the large and small intestine?

The follicles of Lieberkühn.

73 How long is the large intestine (*intestinum crassum*)?

About a quarter as long as the small intestine. It is called large on account of its diameter, being about two and a half inches in its broadest part.

74 What is its location?

It begins at the right and lower portion of the abdomen, passes upward and backward to the under surface of the liver, thence across the

belly to the spleen, from this point downward and forward to the left and lower part of the abdomen, here makes a number of curves, and finally plunges into the pelvis at its back part, and ends close to the perineum, near the inner opening of the anal canal.

75 What divisions has it?

The caecum; ascending, transverse, descending colon, sigmoid flexure, and rectum.

The caecum lies in the right iliac fossa; from this point the ascending colon passes to the liver. Here it forms the hepatic flexure, then passes transversely across the belly below the stomach, and here the splenic flexure is formed, then it passes downward, forming the descending colon. In the left iliac fossa it forms the sigmoid flexure, and then passes through the pelvis as the rectum.

76 How many coats has large intestine?

It has four coats, with the same arrangement as the stomach and small intestine: serous, muscular, areolar, mucous.

77 What glands has the large intestine?

It has the crypts of Lieberkühn and solitary glands. It has no villi, no valvulae conniventes, no glands of Brunner, no patches of Peyer.

78 What is the vermiform appendix?

It is a blind process given off from the caecum, varying in man from 3 to 6 inches.

79 What is the ilio-caecal valve?

The opening of the small intestine into the large is provided with prominent lips, which project into the cavity of the latter, and oppose the passage of matter from it into the small intestine, while they readily allow of a passage the other way. This is the ileo-caecal valve or valve of Bauhini.

80 Give blood supply of large intestine.

The large intestine is supplied with blood by the branches of the superior mesenteric and inferior mesenteric arteries, while it also receives a blood supply from the internal iliac at the rectum. The vessels form a continuous series of arches from the caecum, where the vasa intestini tenuis anastomosis with the ileo-colic, the first branch of the superior mesenteric given to the large intestine. The blood supply of the rectum is from the inferior mesenteric by the superior haemorrhoidal from the internal iliac by the middle haemorrhoidal, and from the internal pudic by the inferior haemorrhoidal. The vessels at the lower end of the rectum assume a longitudinal direction, communicating freely at the anus and less freely above

The blood of the large intestine is turned into the portal vein by means of the superior mesenteric and inferior mesenteric veins. At the rectum a communication is set up between the systemic and portal system of veins, since some of the blood of that part of the intestine is returned into the internal iliac veins. In the lower end of the rectum the veins, like the arteries, are arranged longitudinally. This arrangement is called the haemorrhoidal plexus.

81 Give nerves and lymphatics of large intestine.

They differ in no particular from those of the small intestine.

82 What is the rectum (intestinum rectum)?

The rectum extends from the sacro-iliac joint to the anus. It better deserves the name rectum (straight), when we say it begins at the front of the the third sacral vertebra, for then it is nearer straight.

83 How many coats has the rectum?

It has the same four coats that the intestine has. Its walls are thicker than those of the colon. The muscular coat and mucous coat differ from those of the other portions of the canal.

84 What are the appendices epiploicae?

The peritoneum of the upper part of the rectum is thrown into folds called appendices epiploicae.

85 What are the folds of Houston?

There are three semilunar transverse folds, one in the upper part of the rectum on the right side, another about the middle on the left side, and a third in front, opposite the base of the bladder. They are called the folds of Houston.

86 Give the muscles of rectum.

Sphincter ani, Internal sphincter and Sphincter tertius of Hyrtl.

87 How is the rectum supported?

It is supported by proper duplications of peritoneum, the mesorectum and other fasciae.

88 What is the liver (hepar)?

It is the largest gland in the body, and weighs 50 or 60 ounces.

89 What is a gland?

A gland is an organ which secretes and pours forth a liquid from one or more ducts or orifices, opening on the surface of the skin or mucous membrane.

90 Where is the liver situated?

It is situated in the right ^{subphrenic} hypogastric, the epigastric and partly in the left ^{subphrenic} hypogastric regions.

91 What are the functions of the liver?

It secretes bile and sugar and performs other important metabolic functions.

92 What surrounds the liver?

It is surrounded by a fibrous coat which is continuous at the transverse fissure with the capsule of Glisson.

93 What is the capsule of Glisson?

It is the sheath of connective tissue enveloping the branches of the portal vein, hepatic artery, and hepatic duct as they ramify in the liver.

94 How many surfaces and borders has the liver?

It has three surfaces: an upper or superior, an under or inferior, and a hind or posterior. It has three borders: an anterior, a postero-superior, and postero-inferior and two extremities, a right and a left.

95 How many and what fissures has the liver?

It has five fissures: umbilical, gall-bladder, portal or transverse fissures which are on the under surface. The ductus-venous and vena-cava fissures are on the hind surface.

96 How many lobes has the liver?

It has five lobes: the left lobe, the right lobe, which is sub-divided into Quadrate and Caudate lobes on the inferior surface. The Spigelian lobe is on the hind surface.

97 Name the ligaments of liver.

It has five ligaments: Suspensory, Broad or Falciform, Coronary, Right lateral or Right triangular, Left lateral or Left triangular. These four ligaments are peritoneal folds. The fifth one, the Round ligament, is the obliterated Umbilical vein.

98 Name the vessels of the liver.

There are five sets: branches of portal vein, branches of hepatic artery, radicals of hepatic veins, bile ducts, lymphatics. Thus it is seen that the liver is supplied with blood by the portal vein and hepatic artery, and discharges it by the hepatic veins.

99 Give nerve supply of the liver.

The nerve supply is from the hepatic plexus, which is an offset from the coeliac plexus and receives filaments from the left pneumogastric and right phrenic.

100 How may the portal veins be told from the hepatic.

The portal veins remain closed, because they are surrounded by the capsule of Glisson. The hepatic veins gape open, being adherent to the liver substance.

101 Give the relations of the liver.

ABOVE.
Diaphragm and anterior wall of abdomen.

BEHIND.
Tenth and eleventh thoracic vertebrae, crura of diaphragm, lower end of the oesophagus, right supra-renal capsule, great vessels.

General relations
of the liver.

BELOW.

Cardiac end of stomach, hepatic flexure of colon, right kidney, first and second portions of duodenum.

102 Where is the gall bladder situated?

It retains the bile and is situated between the right and quadrate lobes on the under surface of the liver.

It is of pyriform outline and when full is seen projecting beyond the anterior border of the liver, coming in contact with abdominal wall opposite ninth costal cartilage. It extends as far back as the transverse fissure.

103 How long is the gall bladder and what is its capacity?

About 3 or 4 inches long and will hold about 1½ ounces.

104 Give vessels of gall bladder.

Cystic artery from right branch of hepatic. Two cystic veins usually empty into the right branch of the vena portal, twelve or fifteen from the fundus go directly into the liver.

105 Give nerves of gall bladder.

The nerves are from the coeliac plexus.

106 How is the hepatic duct formed?

It is formed by the right and left bile ducts descending from the liver.

107 What are the biliary ducts?

They are the cystic which comes from the neck of the gall bladder. It joins the hepatic forming the ductus communis choledochus. These three are called the biliary ducts. The ductus communis choledochus empties

into the descending duodenum about three inches from the pyloric end of stomach.

108 What is the meaning of pancreas and where is it located?

It means "all flesh." In some of the lower animals it is known as the sweetbread. On account of closely resembling the parotid glands it is called the abdominal salivary gland. It is situated in front of the first and second lumbar vertebrae and behind the stomach.

109 Give divisions, dimensions and weight.

It has a head, a neck, a body and a tail. It varies considerably in size, it is about six inches long, from half an inch to one inch in thickness. It weighs about 3 ounces.

110 Where does the pancreatic duct empty?

This duct also called the duct of Wirsung extends the whole length of the pancreas and opens into the duodenum about three inches below the pylorus, often in common with the ductus communis choledochus.

111 The head or right extremity is surrounded by what structures?

By the curve of the duodenum, ductus communis choledocus, and the pancreatico-duodenal arteries.

112 What is the situation of the tail or left extremity?

It lies above the left kidney and in contact with the lower end of the spleen.

113 Give blood supply of pancreas

The pancreas receives blood from the splenic artery through its pancreatic branches, and from the superior mesenteric and hepatic by the inferior and superior pancreatico-duodenal arteries, which form a loop running round, below and to the right of its head. The blood is returned into portal vein by means of the splenic and superior mesenteric veins.

114 Give lymphatics of pancreas.

The lymphatics terminate in two glands which lie on the superior mesenteric veins

115 Give nerve supply of pancreas.

The nerves are branches of the solar plexus which accompany the arteries entering the gland.

116 What is the lesser pancreas?

Sometimes a lobe of the head is detached, and has a duct of its own opening into the duodenum about an inch above the pancreatic duct. This lobe is called the lesser pancreas.

117 What are the ductless glands?

They are the spleen, supra-renal capsules, thyroid and thymus glands. They have no excretory ducts and their functions are unknown.

The words ductless glands involve a seeming paradox, for the word "gland" implies the capacity to form a product known as a secretion, and no one has ever seen a secretion from one of these organs, but the absence of a channel of exit strengthened the idea that there was no such material to be discharged.

Investigations in recent years have shown that some of these organs have a profound influence upon nutritive changes in the body, and have established the fact of internal secretion. Though ductless they are really glands.

118 What is the spleen and where is it situated?

It is a non-glandular, highly vascular organ which is situated in the abdomen, on the left side, in connection with the digestive organs, and in which the blood, probably, undergoes certain modifications in respect to its corpuscles.

The spleen has no proper secretion and no excretory duct. It lies in the left hypochondriac region, capping the cardiac end of the stomach. The spleen has been supposed to be the seat of various emotions.

119 Give dimensions and weight of spleen.

Its dimensions are 1x3x5 inches, and weighs about five ounces.

120 Give general relations of the spleen.

In Front.

Stomach: Splenic flexure of colon.

Outer Side.

Diaphragm, ninth to eleventh rib. between axillary line.

General relations of the Spleen.

Inner Side.

Stomach: Pancreas, left kidney and capsule.

Behind.

Diaphragm.

120a Give blood supply of spleen.

The spleen receives its blood from the splenic artery, which is very large in proportion to the body it is going to supply, and it divides before entering into about six branches. The artery is very tortuous. The vein, on the other hand, is straight and lies below the artery.

121 Give lymphatics of spleen.

They are divided into superficial and deep set. The former forms a

plexus beneath the peritoneum. The latter are derived from fine perivascular spaces in the adenoid tissue around the vessels. They join at the hilum, and pass between the layers of the gastro-hepatic omentum to the glands in that neighborhood.

122 Give nerves of spleen.

The nerves are from the solar plexus. They pass along the splenic artery.

123 What and where is the thyroid gland?

It is a large and very vascular body, consisting chiefly of a congeries of blood vessels, but not provided with a duct or known to furnish any secretion, saddled upon the larynx and upper part of trachea. Its functions, if it has any, are unknown, it takes no part in respiration, though associated with the windpipe, and is apparently a vestigial organ or the remains of some undermined functional homologue of the lower vertebrates. It is the seat of the disease known as bronchocele or goiter.

124 Give the dimensions, weight and divisions.

It has two lateral lobes and an isthmus. The lobes are pyriform in shape, with their broad ends below, and measures about two inches in length, three-quarters of an inch in breadth, and about an inch in thickness near the middle.

It weighs from one to two ounces, but is larger in female, and is often increased in size during menstruation.

125 Give blood and nerve supply.

The arteries which are relatively large and frequently anastomose—are the two superior thyroids, the two inferior thyroids, and an occasional one which ascends on the front of the trachea, the thyroidea ima. This latter is derived either from the innominate artery or from the arch of the aorta. The superior thyroid arteries descend to supply the apices and inner and foreparts of the lateral lobes, whilst the inferior ascends to supply their outer and hinder portions below. The veins are the superior, middle and inferior thyroid. The first two join the internal jugular vein, and the last one the innominate of corresponding side.

The nerves are derived from the middle cervical ganglion of the sympathetic.

126 What and where is the thymus gland?

It is a fatal structure, vestigial in the adult, and has no known function, situated inside the thorax, behind the sternum, near the neck. The thymus of the sheep and veal is called sweetbread and more fully throat or neck-sweetbread, to distinguish it from the pancreas or stomach-sweetbread.

It reaches its highest development about the second year, and its weight is six drachms.

127 Give blood and nerve supply.

The arteries are derived from the internal mammary and from superior and inferior thyroids. The veins join the left innominate and thyroid veins. The nerves are very minute and proceed from the sympathetic and pneumogastric.

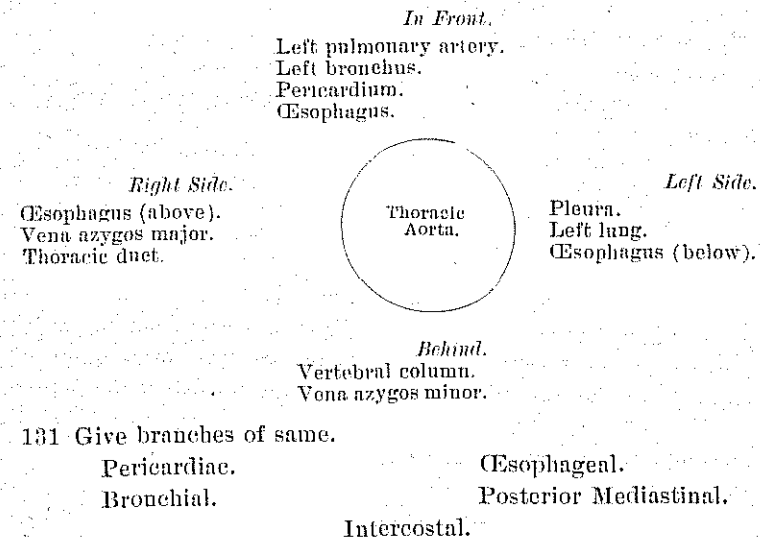
128 What are the supra-renal bodies?

They are two solid viscera resting each upon the upper extremity of the corresponding kidney

129 Give blood and nerve supply.

It is richly supplied with vessels and nerves. Its arteries are derived from three sources: the aorta, the phrenic and the renal, and pierce the organ in various places, but chiefly on the anterior surface along a furrow sometimes called the hilum. The veins terminate on the right side in the vena cava and sometimes by means of small branches in the phrenic and renal trunks: on the left side, in the left renal vein. The lymphatics pass to the renal glands, which, like the supra-renal bodies, themselves contain a good deal of pigment. The nerves form a rich and complex interlacement, and are derived chiefly from the solar and renal plexuses, but include filaments from the splanchnics, and according to some authors from the phrenic and vagus also

130 Give relations of Thoracic aorta



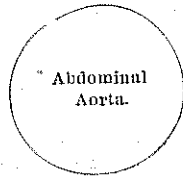
132 Give relations of Abdominal aorta

In front.

Lesser omentum and stomach.
Branches of the coeliac axis and solar plexus.
Splenic vein.
Pancreas.
Left renal vein.
Transverse duodenum.
Mesentery.
Aortic plexus.

Right side.

Right crus of Diaphragm.
Inferior vena cava.
Vena azygos major.
Thoracic duct.
Right semilunar ganglion.

*Left Side.*

Sympathetic nerve.
Left semilunar ganglion.

Behind.

Left lumbar veins.
Receptaculum chyli.
Thoracic duct.
Vertebral column.

133 Give branches of same.

Phrenic.

Coeliac Axis.

{ Gastric.
Hepatic.
Splenic.

Superior Mesenteric.
Suprarenal.
Renal.
Spermatic in male.

Ovarian in female.
Inferior Mesenteric.
Lumbar.
Sacra Media

The branches may be divided into two sets: 1. Those supplying the viscera. 2. Those distributed to the walls of the abdomen.

Visceral Branches—

Coeliac Axis { Gastric.
Hepatic.
Splenic.

Superior Mesenteric.
Inferior Mesenteric.
Supra-renal

Renal
Spermatic or Ovarian.

Parietal Branches—
Phrenic.
Lumbar.
Sacra Media.

134 What is the Coeliac Axis?

It is a short thick trunk, about half an inch in length, which arises from the aorta opposite the margin of the diaphragm, and, passing nearly horizontally forward (in the erect posture) divides into three large branches, the gastric, hepatic and splenic, occasionally giving off one of the phrenic arteries.

135 Give branches of the hepatic artery.

Pyloric.

Gastro-duodenalis. { Gastro-epiploica Dextra.
Pancreatico-duodenalis Superior.

Cystic.

136 Give branches of Splenic artery.

Pancreaticæ Parvæ.

Pancreatica Magna.

Gastric (Vasa Brevia).

Gastro-epiploica Sinistra.

137 Give branches of Superior Mesenteric artery.

Inferior Pancreatico-duodenal.

Vasa Intestini Tenuis

Ileo-colic.

Colica Dextra.

Colica Media.

138 Give branches of inferior mesenteric artery.

Colica Sinistra.

Sigmoid.

Superior Hæmorrhoidal

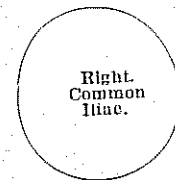
139 Give relation of the common iliac arteries.

In front.

Peritoneum.
Small intestines.
Sympathetic nerves.
Ureter.

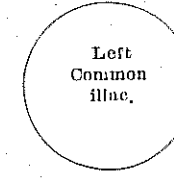
In front.

Peritoneum, small intestines.
Sympathetic nerves.
Superior hæmorrhoidal artery.
Ureter.



Outer side.
Vena cava.
Right common iliac vein.
Psoas muscle.

Inner Side.
Left common iliac vein.



Outer Side.
Psoas muscle.

Behind.

Last two lumbar vertebrae.
Right and left common iliac veins.

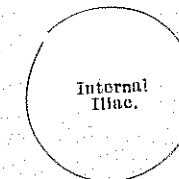
Behind.

Last two lumbar vertebrae.
Left common iliac vein.

140 Give relations of internal iliac artery.

In front.

Peritoneum.
Ureter.



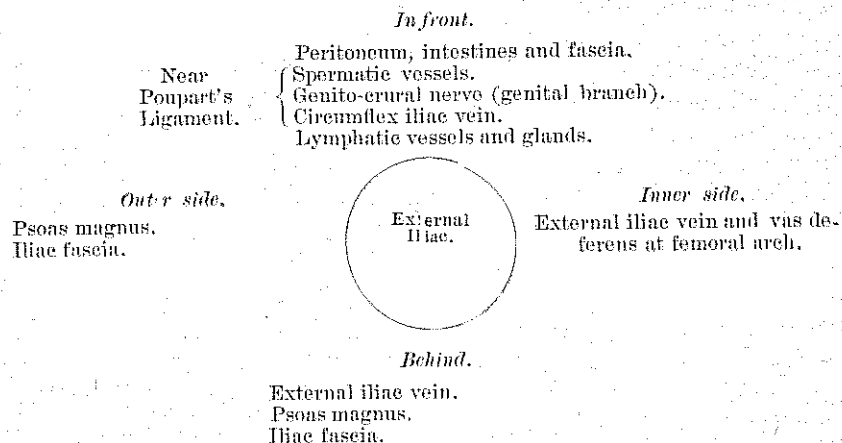
Outer side.
Psoas magnus.

Inner side.
Internal iliac vein.
Peritoneum.

Behind.

External iliac vein (above).
Internal iliac vein.
Lumbo-sacral nerve.
Sacrum.

141 Give relations of external iliac artery.



142 What does the word *Cœliac* mean?

Literal meaning belly, hollow.

Pertaining to the cavity of the abdomen, abdominal or ventricular, now chiefly used in the phrase *cœliac axis*.

QUESTIONS AND ANSWERS ON VISCERA. Continued.

SUBDIVISION—THE ORGANS OF VOICE AND RESPIRATION.

1 What and where is the larynx?

The part of the windpipe in which vocal sound is made and modulated; the organ of phonation. It is the enlarged and modified upper end of the trachea, with some associate parts, as the epiglottis. It opens by the glottis into the pharynx; below, its cavity is directly continuous with that of the trachea or windpipe. It causes the protuberance of the throat called Adam's apple or *pomum Adami*.

2 What is the relative size of the larynx in men and women?

The larynx is larger in men than in women and boys by about one-third. In various animals the larynx may be situated anywhere along the windpipe, or even in the bronchial tube. It is generally at the top of the trachea. In birds there are two larynges, one at the top, the other at the bottom of the trachea. The latter is called the *syrix*.

3 What is the glottis?

It is the mouth of the windpipe; the opening at the top of the larynx;

the fissure between the vocal cords. It is also applied to the opening with the contiguous limiting structures, as in the expression 'oedema of the glottis,' much as the term 'mouth' is used to include the lips. The ventral or anterior portion of the glottis, called *glottis vocalis*, is bounded by the true vocal cords; the dorsal or posterior part, *glottis respiratoria*, by the internal margins of the arytenoid cartilages.

4 What is the epiglottis?

A valve-like organ which helps to prevent the entrance of food and drink into the larynx during deglutition.

5 What are the true and false vocal cords?

The superior or false vocal cords, so-called because they are not directly concerned in the production of the voice, are two folds of mucous membrane, each enclosing a delicate rounded band, the superior thyro-arytenoid ligaments. The inferior or true vocal cords, so called from their being concerned in the production of sound, are two strong fibrous bands (inferior thyro-arytenoid ligaments), covered on their surface by a thin layer of mucous membrane.

Between the true and false vocal cords on each side there is a recess called a ventricle or sinus of the larynx, which leads into a pouch, the *sacculus laryngitis*, which is also called the sinus of Morgagni.

6 Name the cartilages of the larynx.

They are nine in number, three single and three pairs:

Single cartilages—

Thyroid.

Cricoid.

Epiglottis.

Paired cartilages—

Two arytenoid.

Two cornicula laryngis.

Two cuneiform.

From their general structure they are arranged as follows:

Hyaline—

Thyroid.

Cricoid.

Arytenoid (the tip of
this one is yellow elastic).

Yellow elastic—

Epiglottis.

Cornicula laryngis.

Cuneiform.

7 Name the ligaments of the larynx.

They are 19 in number—3 extrinsic ligaments, connecting the larynx to the hyoid bone; and 16 intrinsic, binding its several cartilages together, viz.—

Extrinsic ligaments (3) are the—

Thyro-hyoid membrane, bounded laterally by—

2 lateral thyro-hyoid ligaments, each contain a nodule of cartilage,

the cartilago triticea.

Intrinsic ligaments (16) are the—

Crico-thyroid membrane.

2 crico-thyroid capsular ligaments.

2 crico-arytenoid ligaments.

2 crico-arytenoid capsular ligaments.

2 superior thyro-arytenoid (situated in the false vocal cords).

2 inferior thyro-arytenoid (situated in the true vocal cords).

Hyo-epiglottic ligament.

Thyro-epiglottic ligament.

3 glosso-epiglottic folds.

8 Name and give nerve supply of the muscles of the larynx.

There are eight pairs of muscles of the larynx, three of which belong to the epiglottis. They are the crico-thyroid, crico-arytenoideus posterior, Crico-arytenoideus lateralis, Thyro-arytenoideus, Arytenoideus, Thyro-epiglottideus, Aryteno-epiglottideus superior, and Aryteno-epiglottideus inferior.

The superior laryngeal nerves supply the mucous membrane of the larynx and the Crico-thyroid muscles. The inferior laryngeal nerve supplies the remaining muscles. The Arytenoideus gets both nerves.

9 Give blood supply of larynx.

The arteries of the larynx are the laryngeal branches derived from the superior and inferior thyroid. The veins accompany the arteries; those accompanying the superior laryngeal artery join the superior thyroid vein which opens into the internal jugular vein; while those accompanying the inferior laryngeal artery join the inferior thyroid vein which opens into the innominate vein. The lymphatics terminate in the deep cervical plexus.

10 What is the trachea?

The trachea (from Greek word, rough) or windpipe is the air passage of the body, beginning at the larynx and ending at the bronchial tubes. It is a musculo-membranous tube, stiffened and held open by a series of many (16 to 20) cartilages or osseous rings, the first of which is usually specialized (cricoid) and the last one or more of which are variously modified to provide for the forking of the single tracheal tube into a pair of right and left bronchial tubes (pessulas), this is a bony bar across the lower end of the windpipe, at the point where the trachea forks into the right and left bronchi. Through the larynx the trachea communicates with the mouth and nose and so with the exterior, and through the bronchial tubes with the lungs; the air passing through it with each inspiration and expiration. The trachea exists in all vertebrates which breathe air with lungs,

and is subject to very little variation in character. It is about four and one-half inches long, extending from the sixth cervical to the fourth dorsal where it branches into the bronchi, lying along the spinal column, the oesophagus interposing between it and the vertebrae. Its average diameter is four-fifths of an inch in the cadaver, the antero-posterior a trifle less, but both are smaller during life.

11 Give blood and nerve supply of trachea.

By the inferior thyroid arteries. The veins terminate in the thyroid venous plexus. The nerves from pneumogastric, and its recurrent branches from the sympathetic.

12 Describe the right bronchus (throat).

The right bronchus is about one inch in length. It is shorter and wider than the left, and in direction more horizontal in its passage to the root of the lung. It gives three branches to its lung.

13 Describe the left bronchus.

The left bronchus is smaller, longer and more oblique than the right, being nearly two inches in length. It enters the root of the left lung opposite the sixth dorsal vertebra, about an inch lower than the right bronchus. It passes beneath the arch of the aorta, crosses in front of the oesophagus, the thoracic duct and descending aorta, and has the left pulmonary artery lying at first above and then in front of it. It divides into two branches for this lung.

14 What are the lungs?

The lungs (Latin, pulmones, from which comes "pulmonary") are two large organs, which occupy a great part of the chest cavity, one in each side of it, and separated from each other by the heart, the gullet, the great blood-vessels, and other structures in the mediastinal space. They communicate with the pharynx through the trachea, and are organs of respiration in air-breathing vertebrates. The lungs are formed by repeated subdivision of the branches of their bronchi which finally end in saccular dilatations called infundibula. The infundibula and air-passages immediately leading to them are beset with air-cells. These air-cells or alveoli are from 1-50 to 1-70 of an inch in diameter. They are furnished with a close capillary network in which the branches from the pulmonary artery terminate, and the blood is separated from the air only by the capillary wall and the thin alveolar epithelium of the air-cells. This assemblage of minute saccular organs and air-bearing tubes is bound up by connective tissue into comparatively compact lungs. The bronchial arteries and veins provide for the nutrition of the pulmonary structures. Lymphatics abound and there are numerous lymphatic glands. Each lung is pyramidal in form,

its base resting on the diaphragm and its apex rising about an inch above the clavicle. The right lung is divided into an upper, a middle and lower lobe; the left one simply into an upper and lower. At the inner side of each lung, a little above the middle, the bronchus and blood-vessels enter, forming the root of the lung; and except for this attachment the lung lies free in its pleural cavity, which it completely fills. The lung is elastic and always on the stretch. The blood, in passing through the lungs, gives off carbon dioxide to the air in the alveoli and receives oxygen. This absorption and elimination seems to be a simple mechanical process, and independent of any secreting or other activity of the epithelial cells.

15 Give nerve supply of the lung.

The nerves are supplied from the anterior and posterior pulmonary plexuses, formed chiefly from the sympathetic and pneumogastric.

Filaments from these plexuses accompany the bronchial tubes, upon which they are lost. Small ganglia are formed upon these nerves.

16 Give weight, capacity, color and specific gravity of the lungs.

The two weigh forty-two ounces, the right one two ounces heavier than the left.

Capacity, nearly seven and one-half pints. The entire respiratory surface is more than 870 square feet.

The color before birth is reddish-brown; on inflation it changes to a rose pink; in early adult life it is grayish-white; in early middle life it becomes brownish in spots and streaks; and in old age it is often bluish-black.

Its specific gravity varies from 0.345 to 0.746, water being 1000.

17 What is the pleura (Greek word side)?

It is the principal serous membrane of the thorax, the shut sac, having a serous surface, which lines the walls of the chest, and is reflected over the surface of each lung. There are two pleurae, right and left, completely shut off from each other. Each is divided into a parietal or costal layer and a visceral or pulmonary layer. Like the other serous membranes, the pleurae are moistened with a serous secretion, which serves to facilitate the movements of the lungs in the chest. Different portions of the parietal layer are distinguished by special names, which indicate their position.

The costal pleura is that which lines the ribs, costal cartilages, and intermediate muscles.

The diaphragmatic pleura is that which is attached to the diaphragm.

The mediastinal pleura is that which is attached to the adjacent structures in the mediastinum.

The cervical pleura is that which covers the dome of the lung.

18 Give arteries and nerves to the pleura.

Internal mammary, intercostal, musculo-phrenic, thymic, pericardiac and bronchial.

The veins correspond to the arteries.

The lymphatics are numerous.

The nerves are from the sympathetic and phrenic.

19 What is the broad ligament of the lung?

The visceral layer of the pleura after covering the root of the lung come together directly beneath it, and form a double-layered, triangular sheet, extending vertically from the root of the lung to the diaphragm, and laterally, from the lung to the mediastinal pleura. This fold is the broad ligament of the lung.

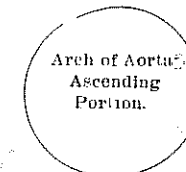
20 Give relations of ascending aorta.

In Front.

Pulmonary artery.
Right auricular appendix.
Pericardium.

Right Side.

Superior vena.
Right auricle.



Left Side.

Pulmonary artery.

Behind.

Right pulmonary artery.
Left auricle.
Pericardium.

21 Give branches of same.

The only branches of the ascending aorta are the two coronary arteries. They supply the heart, and are two in number, right and left, arising near the commencement of the aorta immediately above the free margin of the semilunar valves.

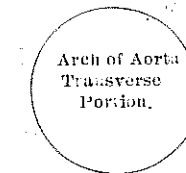
22 Give relations of the transverse portion.

ABOVE.

Left innominate vein.
Innominate artery.
Left carotid.
Left subclavian.

In Front.

Pleurae and lungs.
Remains of thymus gland.
Left pneumogastric nerve.
Left phrenic nerve.
Left superior cardiac nerve.
Left superior intercostal vein.



Behind.

Trachea.
Deep cardiac plexus.
Oesophagus.
Thoracic duct.
Left recurrent nerve.

BELOW.

Bifurcation of pulmonary artery.
Remains of ductus arteriosus.
Superficial cardiac plexus.
Left recurrent nerve.
Left bronchus.

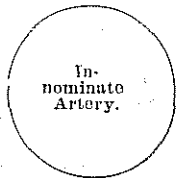
23 Give branches of the arch aorta.

The branches given off from the arch of the aorta are three in number: the innominate artery, the left common carotid, and the left subclavian.

24 Give relation of innominate artery.

In Front.

Sternum.
Sterno-hyoid and Sterno-thyroid muscles.
Remains of thymus gland.
Left innominate and right inferior thyroid veins.
Inferior cervical cardiac branch from right pneumogastric nerve.



Left Side.

Remains of thymus.
Left carotid.
Left inferior thyroid vein.
Trachea.

Right Side.

Right innominate vein.
Right pneumogastric nerve.

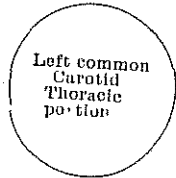
Pleura.

Behind.
Trachea.

25 Give relations of the left common carotid thoracic portion.

In front.

Sternum.
Sterno-hyoid and Sterno-thyroid muscles.
Left innominate vein.
Remains of thymus gland.



Externally.

Left pneumogastric nerve.
Left pleura and lung.
Left subclavian artery.

Internally.

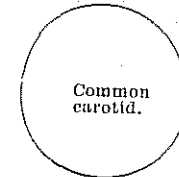
Innominate artery.
Inferior thyroid veins.
Remains of thymus gland.

Behind.
Trachea.
Oesophagus.
Thoracic duct.

26 Give relation of the common carotid artery.

Externally.

Integument and superficial fascia
Deep cervical fascia.
Platysma.
Sterno-mastoid.
Sterno-hyoid.
Sterno-thyroid.
Omo-hyoid.
Descendens and Communicans hypoglossi nerves.
Sterno-mastoid artery.
Superior and middle thyroid veins.
Anterior jugular vein.
Internal jugular vein.
Pneumogastric nerve.



Internally.

Trachea.
Thyroid gland.
Recurrent laryngeal nerve.
Inferior thyroid artery.
Larynx.
Pharynx.

Behind.

Longus colli.
Rectus capitis anticus major.
Sympathetic nerve.
Inferior thyroid artery.
Recurrent laryngeal nerve.

27 Give relations and branches of external carotid.

Branches—The external carotid artery gives off eight branches, which, for convenience of description, may be divided into four sets.

Anterior—	Posterior—
Superior Thyroid.	Occipital.
Lingual.	Posterior Auricular.
Facial.	
Ascending—	Terminal—
Ascending Pharyngeal.	Superficial Temporal.
	Internal Maxillary.

Externally.

Skin, superficial fascia.
Platysma and deep fascia.
Anterior border of Sterno-mastoid.
Hypoglossal nerve.
Lingual and facial veins.
Digastric and Stylo-hyoid muscles.
Parotid gland with facial nerve and temporo-maxillary vein in its substance.
Internal carotid artery.



In front.

Ramus of jaw.

Behind.

Parotid gland.

Internally.

Hyoid bone.
Pharynx.
Superior laryngeal nerve.
Stylo-glossus.
Stylo-pharyngeus.
Glosso-pharyngeal nerve.
Parotid gland.

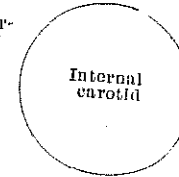
- 28 Give branches of superior thyroid.
Hyoid. Superior Laryngeal.
Superficial descending (Sterno-mastoid). Crico-thyroid.
- 29 Give branches of lingual artery.
Hyoid. Sublingual.
Dorsalis Linguae. Ranine.
- 30 Give branches of facial.
Cervical Branches— Facial Branches—
Inferior of Ascending Palatine. Muscular.
Tonsillar. Inferior Labial.
Submaxillary. Inferior Coronary.
Submental. Superior Coronary.
Muscular. Lateralis Nasi.
Angular.
- 31 Give branches of occipital.
Muscular. Auricular.
Sterno-mastoid. Meningeal.
Arteria Princeps Cervicis.
- 32 Give branches of posterior auricular.
Stylo-Mastoid. Auricular. Mastoid.
- 33 Give branches of ascending pharyngeal.
Prevertebral Pharyngeal. Meningeal.
- 34 Give branches of superficial temporal.
Transverse Facial Middle Temporal.
Anterior Auricular.
- 35 Give branches of internal maxillary.
Branches of the first or maxillary portion of the internal maxillary.
Tympanic (anterior). Small Meningeal.
Middle Meningeal. Inferior Dental.
Branches of the second or pterygoid portion of internal maxillary.
Deep Temporal. Masseteric.
Pterygoid. Buccal.

Branches of the third or spheno-maxillary portion of internal maxillary—

- Alveolar. Vidian.
Infra-orbital. Pterygo-palatine.
Posterior or Descending Palatine. Naso- or Spheno-palatine.
- 36 Give relations of internal carotid artery.

Externally.

Skin, superficial and deep fasciae
Platysma.
Sterno-mastoid.
External carotid and occipital arteries.
Hypoglossal nerve.
Parotid gland.
Stylo-glossus and Stylo-pharyngeus muscles.
Glosso-pharyngeal nerve.
Pharyngeal branch of the pneumogastric.
Internal jugular vein.
Pneumogastric nerve.



Internally.

Pharynx.
Superior laryngeal nerve.
Ascending pharyngeal artery.
Tonsil.

Behind.


Rectus capitis anticus major.
Sympathetic.
Superior laryngeal nerve.

- 37 Give branches of internal carotid.
The branches given off from the internal carotid are—
From the Petrous portion Tympanic (internal or deep).
From the Cavernous portion { Arteriae Receptaculi.
Anterior Meningeal.
Ophthalmic.
From the Cerebral portion { Anterior Cerebral.
Middle Cerebral.
Posterior Communicating.
Anterior Choroid.
- 38 Give branches of ophthalmic artery.
Orbital group— Ocular group—
Lachrymal. Muscular.
Supra-orbital. Anterior ciliary.
Posterior Ethmoidal. Short ciliary.
Anterior Ethmoidal. Long ciliary.
Palpebral. Arteria Centralis Retinae
Frontal.
Nasal.
- 39 Give branches of anterior cerebral.

- Antero-median and Ganglionic. Middle and Internal Frontal.
 Anterior and Internal Frontal. Posterior and Internal Frontal.
- 40 Give branches of middle cerebral.
 Antero-lateral Ganglionic. Ascending Frontal.
 External and Inferior Frontal. Ascending Parietal.
 Parieto-sphenoidal.
- 41 Give the relation of the first portion of the right subclavian artery.

In front.

Skin, superficial fascia.
 Platysma, deep fascia.
 Clavicular origin of Sterno-mastoid.
 Sterno-hyoid and Sterno-thyroid.
 Internal jugular and vertebral veins.
 Pneumogastric, cardiac, and phrenic nerves.



Beneath.
 Pleura.

Behind.

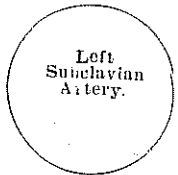Recurrent laryngeal nerve.
 Sympathetic.
 Longus colli.
 Neck of first rib.

- 42 Give the relations of the first portion of the left subclavian.

In front.

Pleura and left lung.
 Pneumogastric, cardiac, and phrenic nerves.
 Left carotid artery.
 Left internal jugular, vertebral, and innominate veins.
 Sterno-thyroid, Sterno-hyoid, and Sterno-mastoid muscles.

Inner side.
 Trachea
 Oesophagus.
 Thoracic duct.



Outer Side.
 Pleura

Behind.

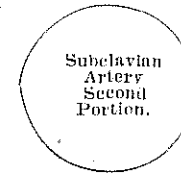Oesophagus and thoracic duct.
 Inferior cervical ganglion of sympathetic.
 Longus colli and vertebral column.

- 43 Give the relations of the second portion of the subclavian.

In front.

Skin and superficial fascia.
 Platysma and deep cervical fascia.
 Sterno-mastoid.
 Phrenic nerve.
 Scalenus anticus.
 Subclavian vein.

Above.
 Brachial plexus.



Below.
 Pleura.

Behind.

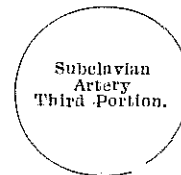
Pleura and Middle Scalenus.

- 44 Give the relations of the third portion.

In front.

Skin and superficial fascia.
 Platysma and deep cervical fascia.
 Descending branches of cervical plexus. Nerve to Subclavius muscle
 Subclavius muscle, suprascapular artery.
 The external jugular and transverse cervical veins.
 The clavicle.

Above.
 Brachial plexus.
 Omo-hyoid.



Below.
 First rib.

Behind.

Scalenus medius.

- 45 Give branches of the subclavian.

There are four branches—the vertebral, the internal mammary, the thyroid axis, and the superior intercostal, generally arise from the first portion of the vessel, on the left side, but on the right side the superior intercostal arises from the second portion of the vessel.

- 46 Give the branches of the vertebral.

Cervical—

Lateral Spinal.
 Muscular.

Cranial—

Posterior Meningeal.
 Anterior Spinal.
 Posterior Spinal.
 Posterior Inf'r Cerebellar

- 47 What do the vertebral form?

- They form the basilar artery.
- 48 Give branches of the basilar.
Transverse. Superior Cerebellar.
Anterior Inferior Cerebellar. Posterior Cerebral.
- 49 Give branches of posterior cerebral.
Postero-median Ganglionic. Postero-lateral Ganglionic.
Posterior Choroid. Three Terminal.
- 50 Give branches of thyroid axis.
Inferior thyroid.
Suprascapular.
Transversalis colli.
- 51 Give branches of the inferior thyroid.
Inferior Laryngeal. Oesophageal.
Tracheal. Ascending Cervical.
- Muscular
- 52 Give branches of the transversalis colli.
They are the superficial cervical and the posterior scapular.
- 53 Give the branches of internal mammary.
Comes Nervi Phrenici (Superior Phrenic). Anterior Intercostal.
Mediastinal. Perforating.
Pericardiac. Musculo-phrenic.
Sternal. Superior Epigastric.
- 54 What divides the subclavian artery into three portions?
The Scalenus anticus muscle.

THE VISCERA.—Continued.

SUB-DIVISION—URINARY SYSTEM.

- 1 What is the function of the urinary system?

The double function of appropriation and elimination belongs both to the alimentary and the respiratory systems, each being concerned in the supply of new material, and also in casting off of effete substances, but the urinary system is simply excretory; its only office is relieving the body of certain waste products, which, if allowed to remain in it, would injure the organs and ultimately destroy life.

- 2 What are the organs of the urinary system?

They are the two kidneys, which form the urine from the materials furnished by the blood; the ureters, ducts which convey the urine away from the kidneys; the bladder, a reservoir in which the urine is stored until circumstances are convenient for its discharge, and the urethra, a tube through which the urine passes from the bladder and is finally voided.

- 3 What is the kidney (kite, the belly; near, near)?

Thus from near we get the word nephritis.

It is a glandular structure whose function is the purification of the blood by the excretion of the urine.

- 4 Give position, color, dimensions and weight of the kidneys.

They are situated in the loins, opposite the upper lumbar vertebrae, behind the peritoneum, embedded in fat and capped by the adrenals or suprarenal capsules.

The left is somewhat (about half an inch) higher than the right, which leaves room for the liver. They are purplish-brown in color, about four inches long, $2\frac{1}{2}$ broad and $1\frac{1}{4}$ thick; they weigh about $4\frac{1}{2}$ ounces.

- 5 What holds the kidneys in position?

They are held in place by their vessels, the peritoneum and the abundant fatty tissue in which they are embedded and which constitutes the "adipose capsule."

- 6 Give the relations of the kidneys.

The upper end of each kidney is capped by a suprarenal body, which laps over upon the front surface and inner border. The hind surface of each is in relation to the last rib, the diaphragm and the quadratus lumborum, and Psoas magnus muscles. The anterior surface of the right kidney is related from above downward to the suprarenal body, liver, duodenum, ascending colon, and jejunum-ileum. The anterior surface of the left kidney to the suprarenal body; spleen, stomach, pancreas, splenic flexure, descending colon and jejunum-ileum.

- 7 Give the structure of the kidney.

A section of the kidney displays an outer cortical substance, darker and softer than the rest, consisting chiefly of uriniferous tubules and malpighian corpuscles; the inner or medullary substance is composed of numerous distinctly striated conical masses or malpighian pyramids, whose bases are directed peripherally, while their apices converge toward the anterior, ending in papillae, which project into the cavity of the pelvis. There are from 8 to 18 such pyramids, composed mainly of minute straight and looped uriniferous tubules, which proceed from the cortical substance to open on the papillae. One such papilla or a set of several papillae, pro-

trudes into a compartment of the general cavity called a calyx: the calyces unite in three infundibula, the beginning of the general cavity of the kidney, the pelvis, which is also the funnel-shaped beginning of the ureter, the tube by which the urine passes to the bladder.

8 What is the hilum?

The hilum of the kidney is the place on the median or concave side of the kidney, corresponding to the place of the scar on the bean, where the ureter goes out and the vessels and nerves enter.

9 What is the capsule of the kidney, floating kidney, a surgical kidney?

The capsule of the kidney is a smooth fibrous membrane closely investing the kidney and forming its outer coat.

Floating kidney is one which has become loose and displaced in the abdomen.

Surgical kidney is a term somewhat loosely applied to nephritic conditions, secondary conditions to mischief farther down in the urinary tract, but especially to suppurative pyelonephritis arising from cystitis.

10 What is the pelvis or sinus of the kidney?

It is the concavity or re-entrance at the hilum of the kidney.

11 What are the calyces of the kidney?

They are the cup-like or infundibuliform beginnings of the ureter in the pelvis of the kidney, surrounding the apices of the malpighian pyramids, each receiving usually more than one pyramid. There are from 7 to 13 such calyces, converging and uniting in the infundibula, which in turn combine to form the pelvis.

12 What are the infundibula of the kidney?

(a) The calyces; (b) the two or three main divisions of the pelvis of the kidney, formed by the confluence of the calyces.

13 What are the papillae of the kidney?

They are the apices of the malpighian pyramids, also called mammillae.

14 What are the malpighian pyramids?

They are pale-reddish conical masses forming the medullary part of the kidney, whose apices project into the calyces of the pelvis of the kidney, and are called papillae.

15 What are the malpighian corpuscles or bodies?

They are the glomeruli of the kidney surrounded by its capsule. These form the terminations of the branches of the uriniferous tubules, occur in the cortical substance of the kidney, and are about 1-100 of an inch in diameter. They are formed of the expanded end of the tube invaginated by the bunch of blood-vessels constituting the glomerulus which thus are

embraced in a double epithelial sac, and the blood is separated from the lumen of the tubule by the vascular wall and the epithelium of the inner layer of the capsule. There is reason to think that these bodies do most of the secretion of the water and less important salts of the urine, the remainder of the work of secreting the urine being done by the epithelial cells of the uriniferous tubules.

16 What is a malpighian tuft?

It is the glomerulus or vascular network or plexus in a malpighian body.

17 Who was Malpighi?

Marcello Malpighi (1628-94) was an Italian anatomist and physiologist.

18 What is the cortical substance of the kidney?

It is the outer part of the kidney-substance, which contains the glomeruli.

19 What are the columns of Bertin?

Named after E. J. Bertin, a French anatomist (1712-81). They are the prolongations inwards of the cortical substance of the kidney between the pyramids.

20 What are the tubes of Ferrin?

These tubes make the pyramids of Ferrin.

They are in the cortical substance and are convoluted.

21 What are the pyramids of Ferrin?

They are formed by a bundle of straight renal tubules which constitute the medullary rays, so named on account of their radiation from the medulla.

22 What are the tubes of Bellini?

They are the excretory tubes opening on the papilla. They are straight tubes.

23 What are the tubes of Henle?

The tubes of Henle connect those of Bellini and Ferrin. They are looped tubes.

24 What is the capsule of Muller?

It is the dilated extremity of a tube of Ferrin investing the Malpighian tuft probably by two layers, similar to the pleural investment of the lungs.

25 Give nerve supply of the kidney?

From the renal plexus, which is formed by filaments from the solar plexus and the lesser splanchnic nerve.

26 Give blood supply of the kidney.

It is from the renal artery and renal vein. (a) afferent (vessels carrying to), (b) efferent vessels (carrying from).

The kidney is very vascular. The larger arterial branches, if traced in section from the point at which they pierce the bottom of the sinus, will be found to run up between the pyramids of Malpighi to subdivide at their bases into cortico-medullary arches which lie between the cortex and medulla, giving off arterioles in both directions, the cortical branches supplying afferent twigs to the glomeruli within the capsules of Bowman.

The medullary branches running inwards to form plexuses around the straight and looped tubules of the Malpighian pyramids. The efferent vessels of the Malpighian glomeruli form a capillary plexus around the uriniferous tubules and terminate in renal veins.

The surface of the kidney receives small collateral arteries which pass through the fatty capsule from the suprarenal, spermatic and lumbar vessels. The superficial veins appear in the form of little stellate groups (stars of Verhayen) which communicate with the venous plexus in the adipose capsule and by means of this with the visceral and parietal veins in the neighborhood.

They are very distinct when the organ is congested.

27 Give lymphatics of kidney.

The renal lymphatics may be divided into two sets, capsular and parenchymatous. They terminate in a series of glands lying with the renal vessels in the subperitoneal tissue, and their contents are ultimately conveyed into the receptaculum chyli.

28 What is the ureter?

It is the excretory duct of the kidney; a tube conveying the urine to the bladder, where that structure exists, as in mammals or into the cloaca, in case no bladder exists. In man the ureter is a very slender tube, from 15 to 18 inches long, running from the pelvis of the kidney to the base of the bladder, at the posterior angle of the trigonum. It rests chiefly upon the Psoas muscles, behind the peritoneum. Its structure includes a fibrous coat, longitudinal and circular muscular fibres, and a lining of mucous membrane with vessels and nerves from various sources. The ureter pierces the wall of the bladder very obliquely, running for nearly an inch behind the muscular and mucous coats of that viscus.

29 Give arteries and nerves of the ureter.

The arteries are branches from the renal, spermatic, internal iliac, and inferior vesical.

The nerves are from the inferior mesenteric, spermatic and pelvic plexuses.

30 What is the bladder?

The bladder (*vesica urinaria*, "the urinary bladder," always being meant when the noun is not qualified) is the reservoir in which the urine is collected from the ureters.

31 How many coats has the bladder?

It has four: the mucous, which is nearest the cavity; and then, in order, the areolar, the muscular, and the serous.

32 What is the trigonum?

It is a triangular space or area at the base of the urinary bladder, whose apex is at the beginning of the urethra, and whose other two angles are at the points of entrance of the ureters into the bladder; more fully called trigonum vesical.

33 What is the form, size and position of the bladder?

When the bladder is collapsed, its mucous walls fall together in such a way that a sagittal section shows the line between them in the shape of a V with unequal and widely spread arms, the point of the V indicating the opening of the urethra.

It is 3x5 inches and holds about a pint.

In the child the bladder is almost an abdominal organ; but in the adult it is in the pelvis.

34 What is the urachus?

It is a fibrous cord extending from the fundus of the bladder to the umbilicus. It represents in the adult a part of the sac of the allantois and associate allantoic vessels of the fetus, whose cavities have been obliterated. It is that intra-abdominal section of the navel-string which is constituted by so much of the allantoic sac and the hypogastric arteries as becomes impervious, the section remaining pervious being the bladder and superior vesical arteries. It sometimes remains pervious, as a malformation, when the child may urinate by the navel.

35 What is the allantois?

A fetal appendage of most vertebrates, developing as a sac or diverticulum from the posterior portion of the intestinal cavity. It is one of the organs of the embryo of all amniotic vertebrates, or those which develop an amnion, but is wanting or is most rudimentary in amphibians and fishes.

In birds and reptiles it is large and performs a respiratory function, and in mammals contributes to form the umbilical cord and placenta. Its exterior primitively consists of mesoblast, its cavity receiving the secretion of the primordial kidneys (Wolffian bodies). So much of the sac as remains pervious within the body of the embryo becomes the urinary blad-

der, or, in some degree, a urinary passage.

The umbilical arteries and veins course along the elongated stalk of the sac, which becomes the umbilical cord, and that part of these allantoic vessels within the body which does not remain pervious becomes the urachus or round ligament of the liver.

The expanded extremity of the allantois, in most mammals, unites with the chorion, to form the placenta. In those vertebrates, as mammals, in which the umbilical vesicle has but a short period of activity, the allantois chiefly sustains the functions whereby the fetus is nourished by the blood of the mother, and has its own blood arterialized. In parturition, so much of the allantois as is outside of the body of the fetus is cast off, the separation taking place at the navel.

36 What is the uvula vesicæ?

It is a slight projection of mucous membrane from the bladder into the cystic orifice of the urethra.

37 Give blood supply of bladder.

The arteries of the bladder are the superior and inferior vesical, and, in the female, the uterine also; its veins are radicles of the internal iliac.

38 Give its lymphatics

They accompany the veins and terminate in the internal iliac gland.

39 Give nerve supply of the bladder.

The nerves are derived partly from the sympathetic system through the hypogastric plexuses, partly from the cerebro-spinal system through the third and fourth sacral nerves. The former supply the mucosa, the latter the muscularis.

40 Give ligaments of the bladder.

The bladder is held in place by ligaments, which are divided into true and false.

The true ligaments are five in number: two anterior, two lateral, and the urachus (superior).

The false ligaments, also five in number, are formed by folds of the peritoneum. The false are named the two posterior, two lateral, and superior.

40 What is the urethra?

It, like "ureter," is derived from the Greek word which means to 'urinate'. The male and female urethrae differ so materially that a separate description of each is necessary.

It is a modification of a part of a urogenital sinus into a tube or a groove for the discharge of the secretion of the genital or urinary organs or both; in most mammals, including man, a complete tube from the bladder

to the exterior, conveying urine and semen in the male sex; urine, only, in the female; in some birds, a penial groove for the conveyance of semen only. The urethra in the male is always a part of the penis, or a penial urethra, continuous usually with the ureteral part of the urogenital sinus; that of the female is only exceptionally a part of the clitoris. In man the urethra extends from the bladder to the end of the penis, usually a distance of 8 or 9 inches.

42 How many portions has the male urethra?

It has three portions—the prostatic, the membranous, the spongy—the structures and the relations of which are essentially different. Except during the passage of the urine or semen the urethra is a mere transverse cleft or slit, with its upper and under surfaces in contact. At the orifice of the urethra, at the end of the penis, the slit is vertical, and in the prostatic portion somewhat arched.

43 How long is each portion?

The prostatic is $1\frac{1}{4}$ inches long.

The membranous $\frac{3}{4}$ inch long.

The spongy $4\frac{1}{2}$ inches.

The first and second portions are not subject to any physiological changes such as characterize the third.

44 How many coats has the urethra?

It has three: mucous, muscular, and erectile.

45 What is the bulb of the urethra?

It is the posterior enlarged rounded extremity of the corpus spongiosum of the penis.

46 What is the crista urethrae?

It is the crest of the urethra; a longitudinal fold of mucous membrane and subadjacent tissue on the median line of the floor of the prostatic urethra, about three-fourths of an inch in length, and one-fourth of an inch in height where it is greatest. On the summit open the ejaculatory ducts, also called colliculus seminales, caput gallinaginis, and verumontanum.

47. What is the prostatic sinus?

It is a longitudinal groove in the floor of the urethra on each side of the crest, into which the prostatic ducts open.

48 What is the pocularis sinus?

A small cul-de-sac, from a quarter to half an inch in its greatest diameter, situated at the middle of the highest part of the crest of the urethra. It corresponds with the uterus of the female. Also called prostatic vesicle, utricle, uterus masculinus.

49 What are the semilunar ducts?

They open on the margins of the sinus pocularis.

50 What are Cowper's glands?

In various animals, a pair of accessory prostatic or urethral glands of lobulated or follicular structure, which pour a mucous secretion into the urethra. In man they are small, about the size of a pea, lying beneath the membranous portion of the urethra, close behind the bulb, and emptying into the bulbous portion of the tract. Their size, shape and position vary in different animals, in some of which they are much more highly developed than in man.

51 What is the fossa navicularis?

(a) It is a recess in the urethra, near the urinary meatus, where the calibre of the tube is enlarged.

(b) A depressed space between the posterior commissure of the vulva and the fourchette.

52 What is the lacuna magna?

It is the largest of several orifices of mucous follicles, situated on the roof of the fossa navicularis.

53 What are the glands of Littie?

They are the crypts along the spongy portion of the urethra.

54 What are the prostate glands?

The prostate ('standing in front') is a glandular body, situated around the initial portion of the urethra. It develops at puberty, atrophies after castration, and in certain animals increases in size during the breeding season.

55 What is the female urethra?

It is a tube beginning at the meatus urinarius internus in the bladder and ends at the meatus urinarius externus in the vulva. It is about $1\frac{1}{2}$ inches long, imbedded in the anterior wall of the vagina, perforating the triangular ligament, and surrounded by the fibres of the Compressor urethrae muscle. Its diameter is about $\frac{1}{4}$ inch, but it is capable of considerable dilatation, being surrounded by softer structures than those around the male urethra. When dilated far beyond its usual calibre, it does not lose its tone.

QUESTIONS AND ANSWERS ON VISCERA.—Continued.

SUB-DIVISION—SPINAL CORD AND BRAIN.

1 What is the spinal cord?

It is the terminal portion of the cerebro-spinal axis and extends from the foramen magnum, where it is continuous with the oblongata, to the first or second lumbar vertebra.

It gives off the spinal nerves and may be regarded as made up of a series of segments, from each of which springs a pair of nerves; it is divided into cervical, thoracic, lumbar, sacral and coccygeal regions, corresponding to the nerves and not to the adjacent vertebrae.

It is bilaterally symmetrical, like all other parts of the axis.

2 What enlargements has it?

(a) The cervical enlargement where the nerves from the arms come in.

(b) The lumbar enlargement where those from the legs come in.

3 What can be said of a cross section?

It exhibits a central H-shaped column of gray substance incased in white.

4 How is it developed?

It is developed from an involution of epiblast in connection with a notochord.

5 What is the neuron?

It is the cerebro-spinal axis in its entirety; the whole of the encephalon and myelon or brain and spinal cord, considered as one.

6 What is the myelon?

The spinal cord; the part of the cerebro-spinal axis which is not the brain.

7 What is the encephalon?

That part of the cerebro-spinal axis which is contained in the cranial cavity as a whole; the brain.

8 Give shape and weight of spinal cord.

It is cylindrical and is slightly flattened ventro-dorsally.

It weighs nearly an ounce.

9 What is the terminal cone?

The lumbar enlargement begins at the ninth thoracic vertebra, attains its greatest size at the twelfth thoracic, and thence rapidly dwindles in a 'terminal cone,' from the apex of which is a delicate prolongation, the 'filum terminale.'

10 What is the cauda equina?

From the tapering cone at the end of the cord proper, the nerve roots are very long and perpendicular in direction, and from their resemblance to a horse-tail, is called 'cauda equina.'

11 What are the membranes of the spinal cord?

They are the dura mater, arachnoid and pia mater.

12 What is the gray commissure of the spinal cord?

It is the connection of the two lateral crescentic masses of gray substance.

13 What is the central canal?

The gray commissure contains the central canal of the spinal cord, a minute channel, continuous with the fourth ventricle of the brain, from which it extends to the middle of the filum terminale. It is not patent in every part of its course.

14 What is the cerebro-spinal fluid?

It is a fluid between the arachnoid and pia mater membranes investing the brain and spinal cord.

15 How many columns and fissures has it?

The columns are the longitudinal masses of white matter of the spinal cord, and the fissures are the creases running from end to end.

The fissures are the ventro-median, which is deep; the dorso-median, which is shallow, and about a quarter of the way around to the front is a shallow dorso-lateral fissure, and between the dorso-lateral and dorso-median, but nearer the latter, is the dorso-intermediate fissure. The ventral roots of the spinal nerves come off on each side from a vertical strip of the surface which is about as far from the ventro-median fissure as the dorsal roots are from the dorso-median fissure. The dorsal roots come from the dorso-lateral fissure.

Each lateral half of the cord is divided into three parts: one between the ventro-median fissure and the ventral roots—the ventral (anterior) column; a second between the ventral roots and the dorsal roots—the lateral column; and a third between the dorsal roots (or dorso-lateral fissure) and the dorso-median fissure—the dorsal (posterior) column, which is subdivided by the dorso-intermediate fissure into the dorso-lateral column, and dorso-mesial column. All of the structures are composed of white nervous tissue.

Thus you see there are eight fissures and eight columns.

16 What are the columns or tracts of Goll?

The median portion of the posterior column of the spinal cord.

The Goll tract increases in size as it ascends.

17 What are the columns or tracts of Burdock?

The external portions of the posterior columns of the spinal cord. The Burdock tract varies but little from its average at different levels.

18 How long is the spinal cord?

About 17 inches in length, and its diameter one-half inch or less.

19 What are the columns of Clarke?

The columns of Clarke, vesicular columns of Clarke (after J. A. L. Clarke, an English anatomist, 1817-80), are two symmetrically placed tracts of medium-sized nerve cells of the spinal cord, laterodorsal of the central canal, confined chiefly to the thoracic region, but a little above and below it.

20 What is the brain and how many divisions has it?

It is the encephalon; the part of the cerebro-spinal axis which is contained in the cranium. Its divisions are the cerebrum or brain proper, the cerebellum or little brain, the pons Varolii, and the medulla oblongata.

21 What is the average weight of the brain?

In the male 49.5 ounces, in female 44 ounces.

Cavier's brain weighed more than 64 ounces. The human brain weighs more than that of any other animal, except the elephant and whale. The elephant's brain weighs about 10 lbs; that of the whale 5 lbs.

22 What are the coverings of the brain?

They are the same as those of the spinal cord—the dura mater, the arachnoid, and the pia mater.

23 What is the cortical layer of the brain?

Like the bark (cortex) of a tree the cortical layer covers the surfaces of the brain. It is composed of cellular nerve-material.

24 What are the fissures or sulci?

They are the infoldings of the cortex, and the more numerous and deeper they are the greater is the amount of the peripheral gray substance.

25 What kinds of matter are in the brain?

Gray matter and white matter. The gray matter, which invests the cerebellum and cerebrum, is also called the cortical substance, in distinction from the white or medullary substance of the interior. The brain is, in fact, a collection of gray ganglia united by white commissures.

26 Is there any gray matter besides the cortex?

There are several ganglia or collections of gray matter in the interior, as the corpora striata, the optic thalami, the optic lobes or corpora quadrigemina, the corpora dentata of the cerebellum, and the corpora olivaria of the medulla oblongata.

27 Are there any non-nervous structures connected with the brain?

There are two non-nervous structures, the coarctum or epiphysis cerebri and the pituitary body or hypophysis cerebri.

28 What are the convolutions or gyri (Anglicized into gyres)?

They are the prominences between the fissures or sulci.

29 Name the principal fissures of the cerebrum.

(a) The longitudinal fissure which separates the two hemispheres.

(b) The Sylvian fissure is the largest, deepest and most constant of the fissures of the brain. It has a short anterior and long posterior branch, the latter separating the temporal from the parietal lobes. It has the middle ^{cerebral} meningeal artery in it.

(c) The fissure of Rolando or central fissure is a deep sulcus separating the frontal and parietal lobes of the cerebrum on each side.

(d) Parieto-occipital fissure extends from the longitudinal fissure outwards for about one inch between the parietal and occipital lobes.

(e) The Transverse fissure is a crevice through which the invagination of the pia is effected, it starts from the porta (foramen of Monro) nearly to the distal end of the middle horn on each side. It is at the base of the brain. It is also called choroid fissure.

(f) Calloso-marginal fissure is nearly concentric with the callosal and also with that of the margin of the hemisphere until a point above the hind end of the callosum is reached, at which the fissure turns, and runs upward and ^{downward} to the upper border.

(g) Calcarine fissure, (from calcar, 'a spur') runs from near the rather pointed hind end of the hemisphere upward and forward, and just beyond the middle, at the point where it receives the parieto-occipital, bends downward and terminates beneath the rear end of the callosum. Encircling the callosum is a fissure, called the callosal.

(h) First temporo-sphenoidal fissure is below the fissure of Sylvius on the lateral surface of the brain.

30 What is the corpus callosum?

The corpus callosum (callous body) is the great white commissure of the hemispheres of the brain; the commissura magna or trabs cerebri. This structure is peculiar to the mammalia; it is first found in a rudimentary state in the implacentals, and increases in size and complexity to the highest mammals, coincidentally with a degree of other special cerebral commissures.

Also called callosum.

31 Name principal lobes of the cerebrum.

1. Frontal lobe is the anterior one of the cerebrum, separated from the parietal by the fissure of Rolando or central fissure.

2. Parietal lobe is the middle one of the vault of the cerebrum, separated from the frontal by the central fissure, or fissure of Rolando and marked off from the occipital by the parieto-occipital fissure. It is divided by an intra-parietal fissure into a superior and inferior parietal lobe. The frontal and parietal lobes which overlap the insula are known as the oper-

culum ("cover").

3. Occipital lobe is the posterior portion of the cerebrum marked off from the parietal lobe by the parieto-occipital fissure.

4. Temporo-sphenoidal lobe, also called temporal, is the lobe of the cerebrum which occupies the middle cerebral fossa of the skull, it is separated from the frontal and parietal lobes by the fissure of Sylvius.

5. The central lobe or Island of Reil is also called the lobule of the Sylvian fissure, lobule of the corpus striatum, is a portion of the cerebral cortex concealed in the Sylvian fissure, consisting of five or six radiations, convolutions, or the gyri operati ("covered gyrus").

31a What are the gyri or convolutions of the cerebrum?

Every gyri in man has its own name; but several different systems of naming them are in vogue, and the nomenclature is still shifting. The attempt to identify the human gyri and sulci with those of other animals encounters difficulties which have thus far been insurmountable except in cases of the most constant and best-marked folds and fissures. Again different human brains vary in details of the gyri, and the same brain may differ on its opposite sides. The gyri are best marked when the mental powers of the individual are at their height.

Gyrus is synonymous with convolution.

32 Name the principal gyri.

1. Angular gyrus is a short one, arching over the upper extremity of the superior temporal fissure, the hindmost one of the four parietal gyri, separated by a short vertical sulcus from the supra-marginal gyrus.

2. Annectent gyrus is a small fold which may connect large or primary convolutions; applied to several such gyri on the occipital lobe, as those forming the connections of the cuneus or occipital lobule.

3. Ascending frontal gyrus is the one bounding the fissure of Rolando in front.

4. Ascending parietal is the one bounding the fissure of Rolando behind.

5. Callosal gyrus is a convolution of the median surface of the cerebrum immediately over the corpus callosum and below the calloso-marginal fissure. It is continuous behind with the gyrus hippocampi, and ends in the gyrus uncinatus, also called gyrus fornicatus, convolution of the corpus callosum.

6. Cuneate gyrus is one of the occipital lobe appearing as a wedge-shaped figure on the median aspect of the cerebrum in the fork between the parieto-occipital sulcus and the calcarine sulcus, also called occipital lobule and cuneus.

7. External orbital gyrus is that part of the orbital surface which lies outside of the triradiate sulcus.

8. The frontal gyri, three gyri which compose the superior and lateral surface of the frontal lobe of the cerebrum, all lying in front of the ascending frontal gyrus. They are defined by the superior and inferior frontal sulci, and by the vertical fissure or precentral sulcus.

9. The hippocampal gyrus is the continuation of the gyrus fornicatus where it dips down behind and below the corpus callosum, and continues forward to the uncinate gyrus; so called from its relation to the hippocampus.

10. Marginal gyrus:—

That part of the first frontal convolution which appears on the median side of the hemisphere.

The gyrus which arches over the extremity of the fissure of Sylvius

11. Occipital gyri are the three principal convolutions of the occipital lobe of the cerebrum, separated by two small, transverse sulci, and distinguished as first, second and third; from above downward, superior, middle and inferior.

12. The orbital gyri are upon the under or orbital surface of the frontal lobe of the cerebrum, which rest upon the orbital plate of the frontal bone. They are three in number, directly continuous with and corresponding to the frontal gyri. The two which are best marked are sometimes called internal and external.

13. The parietal gyri are four well-marked convolutions upon the superior and lateral surface of the parietal lobe; and especially two of these distinguished as the ascending parietal (or posterior central) and the superior parietal, the other two being commonly known as the supramarginal and angular gyrus.

14. Quadrate, or quadratus gyrus, is a convolution of somewhat square figure appearing on the median surface of the cerebrum between the callosum marginal sulcus in front and the parieto-occipital sulcus behind, and continuous below with the gyrus fornicatus, also called precentral.

15. Sigmoid gyrus is the somewhat S-shaped fold which curves about the lateral end of the cruciate fissure, and whose surface includes several constant and well-marked "motor areas"

16. The temporal gyri, a general name of the temporal convolutions.

17. Uncinate gyrus is on the median surface of the cerebrum nearly opposite the gyrus fornicatus.

18. Gyri operati ("covered gyrus") is the insula.

19. The dentate gyrus is lodged in the hippocampi fissure, and is a long, slender roll of gray substance, notched upon its exposed surface.

33. What are the ganglia at the base of the brain?

Besides the gray matter of the cerebral hemispheres of the cerebellum and the medulla oblongata the—

(a) Olfactory bulb which is the anterior enlargement of the olfactory tract from which the olfactory nerves are sent off.

(b) Corpora-striata (striped bodies) are large ganglia of the brain, of mixed white and gray substance, situated beneath the anterior horn of each lateral ventricle of the cerebrum.

(c) Optic thalami is a large ganglion of the thalamencephalon, situated upon the crus and separated from the lenticular nucleus by the internal capsule; also called thalamus. It gives origin to some of the fibres of the optic nerve.

(d) Tubercula Quadrigemina are on the dorsal part of the midbrain. The lobes are paired, right and left, and hence called corpora bigemina in animals below mammals. In man they are marked by a cross-furrow, so they are called corpora quadrigemina, and constitute what are called the nates and testes of the brain. The optic nerve arises in part from the optic lobes.

(e) Tuber annulare is the annular tuber of the brain, the pons Varolii.

34. What is a commissure?

A joint, seam, suture or closure; the place where two bodies or parts of a body meet or unite.

35. Name the transverse commissures of the brain.

There are nine of these—

1. Anterior Commissure.

2. Middle Commissure.

3. Posterior Commissure.

4. Corpus Callosum.

5. Optic Commissure.

6. Pons Varolii.

7. Fornix, which is a longitudinal commissure also.

8. Posterior medullary velum.

9. Valve of Vieussens.

36. Name the longitudinal commissures of the brain.

There are ten of these—

1. Olfactory tracts.

2. Taenia Semicircularis.

- 3 Crura Cerebri.
 - 4 Processus-a-Cerebello ad Testes.
 - 5 Peduncles of the Pineal gland.
 - 6 Fornix.
 - 7 Infundibulum.
 - 8 Lamina Cinerea.
 - 9 Gyrus Fornicatus.
 - 10 Fasciculus unciniformis.
- 37 What is a ventricle?
Literally a belly, a stomach.
A small cavity.

Those of the brain are a series of connecting cavities, containing fluid, within the brain, continuous with the central cavity of the spinal cord. They are the remains of the original neural canal, formed by a folding over of the epiblast.

- 38 Bound the optic commissure.

The commissure or chiasma, somewhat quadrilateral in form, rests upon the optic groove of the sphenoid bone, being bounded, above, by the lamina cinerea; behind, by the tuber cinereum; on either side, by the anterior perforated space. Within the commissure the optic nerves of the two sides undergo a partial decussation. The fibres which form the inner margin (inferior commissure of Gudden) of each tract are continued across from one to the other side of the brain. These may be regarded as commissural fibres (intercerebral) between the internal geniculate bodies. Some fibres are continued across the anterior border of the chiasma, and connect the optic nerves of the two sides, having no relation with the optic tracts. They may be regarded as commissural fibres between the two retinae (inter-retinal fibres). The outer fibres of each tract are continued into the optic nerve of the same side. The central fibres of each tract are continued into the optic nerve of the opposite side, decussating in the commissure with similar fibres of the opposite tract.

- 39 What are the names of the ventricles?

Two lateral, third ventricle, fourth ventricle, fifth ventricle, and the ventricle of the corpus callosum.

- 40 Where are they found?

The lateral ventricles are found one in each hemisphere; they communicate with each other and with the third ventricle through the foramen of Monro. The third ventricle lies between the optic thalami. It communicates with the fourth ventricle through the aqueduct of Sylvius. The fourth ventricle lies between the cerebellum and the pons and medulla. The

so called fifth ventricle, or pseudocoel, has no connection with the other cerebral ventricles, being of a different nature and simply a small interval between the right and left layers of the septum lucidum

- 41 What is the septum lucidum?

It is the median partition of the lateral ventricles of the brain, inclosing the camera, pseudocoel or so-called fifth ventricle. Also called septum pellucidum, septum medium, septum ventriculorum, ventricular septum, septum medullare triangulare.

- 42 What is the fornix?

It is an arch. In the human brain it consists of two longitudinal bundles of fibres, one on each side, which rise from the corpora albicantia, pass up, as the anterior pillars of the fornix in front of the foramina of Monro and behind the anterior commissure, these, somewhat flattened and in apposition to each other, arch backward beneath the corpus callosum and above the velum interpositum, forming the body of the fornix and then diverge toward the back part of the corpus callosum, to turn down, as the posterior pillars of the fornix (crura fornicis), into the floor of the descending cornua of the lateral ventricles, where their free edges form the fimbriae.

- 42 What is the fimbria?

It is narrow band of white fibres running along the median concave side of the hippocampus major. It is a continuation of the pillars of the fornix. Also called taenia hippocampi and corpus fimbriatum.

- 43 What is the taenia semilunaris?

It consists of commissural fibres between the corpus striatum and the optic thalamus.

- 44 What is the cerebrum?

It is that portion of the brain which lies in front of the cerebellum and pons Varolii. It comprises about seven-eighths of the weight of the brain. It is the center of intelligence and thought.

- 45 What is the cerebellum?

It is called the arbor-vitae or tree of life. It is the center for the control of muscles. It is between the corpora quadrigemina in front and the medulla oblongata behind, and forming part of the roof of the fourth ventricle.

- 46 What is the pons?

Also called pons Varolii and pons cerebelli. It is a great transverse commissure seen at the base of the brain in front of the medulla. Its fibres connect the hemispheres of the cerebellum with each other and the medulla.

47 What is the medulla oblongata?

(a) Marrow; (b) the so-called spinal nervous system; the myelon; more fully called medulla spinalis; (c) the hind most segment of the brain, continuous with the spinal cord.

48 What is the penial gland?

Also called conarium and epiplysis.

It is a small reddish body developed from the hinder part of the roof of the first cerebral vesicle, and lying in front of and above the nates. Its substance consists mainly of epithelial follicles and connective tissue; there is no evidence that it is a nervous structure, and its function, if it passes any, is unknown. It was formerly supposed by some (as by the Cartesians) to be the seat of the soul.

49 What is a peduncle?

Literally a little foot. There are numerous peduncles of the brain.

50. Name those of the cerebellum.

They are three pairs in number and are stout bundles of nerve fibres which connect the cerebellum with other chief divisions of the brain. They are distinguished by their positions as superior, middle and inferior peduncles or crura. The superior pair emerge from the mesial part of the medullary substance of the hemispheres, and run forward upward to reach the nuclei tegmenti of the opposite sides, after decussation under the formatio reticularis. (also called crura ad corpora quadrigemina, crura ad cerebrum, processus cerebelli ad cerebrum, processus-e-cerebello ad testes, brachia conjunctiva, and brachia conjunctoria).

The middle pair from the ventral transverse fibres of the pons, emerging from the lateral part of the white substance of the hemispheres. (Also called crura or processus ad medullam).

51. Name the fissures of the cerebellum.

They are three in number—two vertical and one horizontal. The great horizontal fissure of the cerebellum is a continuous fissure which separates the cerebellum into upper and lower portions. It begins in front at the middle peduncles, and extends around the outer and posterior border of each hemisphere. The vertical ones are:

1. Incisura cerebelli anterior, the anterior median notch of the cerebellum, into which the corpora quadrigemina are received.

(2) The incisura cerebelli posterior, the median notch on the posterior outline of the cerebellum, formed by the projection of the cerebellar hemispheres beyond the vermis.

52 What is the vermis?

It is the median lobe of the cerebellum; the vermiform process of the cerebellum divided into the prevermis and postvermis.

53 What is the olivary body?

It is the ganglion of the oblongata lying on either side just lateral of the pyramid, and forming an oval projection on the surface just below the pons. It consists of the nucleus olivaris inferior with a covering and filling of white matter, also called inferior olivary body, or inferior olive, and corpus semiovale.

54 What is the corpus dentatum?

(a) A plicated capsule of gray matter, open anteriorly, situated within the white substance of each cerebellar hemisphere. Also called ganglion of the cerebellum and nucleus dentatus.

(b) A somewhat similar mass of gray matter in each olivary body. Also called corpus ciliare.

55 What is the lateral tract?

It continues with the lateral column of the spinal cord, lies behind the olivary body and in front of the restiform.

56 What is the restiform body?

It is the inferior peduncle of the cerebellum, by which it connects with the oblongata and parts below. It contains the direct cerebellar-tract fibres, crossed and uncrossed from the posterior columns of the cord, and fibres from the centra-lateral (lower) olive.

57 What is the fillet?

Some special bundle of nerve-fibers; especially, a band of longitudinal fibers lying in the ventral and outer parts of the tegmental region of the brain. Its distribution is not known, but it seems to connect below with the posterior columns of the spinal cord and above with the corpora quadrigemina, optic thalami, lenticular nucleus, and cortex cerebri.

Also called lemniscus.

58 What is a vesicle?

A small, bladder-like structure, cavity cell, or the like, in a body.

59 How many vesicles are there in the brain?

There are three: anterior, middle and posterior. They are embryonic and so transitory, and have other names when matured. They are called anterior, middle and posterior corresponding to the fore-brain, mid-brain and hind-brain.

They are primitive structures and become the ventricles of the brain. The three commonly become five by the subdivision of two of them.

A FEW MISCELLANEOUS QUESTIONS.

1 What is the perineum?

Origin uncertain.

(a) It is the region of the body between the thighs, extending from the anus to the fourchette in the female, or the scrotum in the male. In the surgical and obstetrical sense of the word the term may include, in the female, all the deeper parts between the posterior wall of the vagina and the anterior wall of the rectum, or it may be more particularly applied to the superficial parts, the deeper parts receiving the name of perineal body.

(b) The region included by the outlet of the pelvis extending from the apex of the subpubic arch in front to the tip of the coccyx behind, and bounded laterally by the conjoined pubic and ischiatic rami, the tuberosities of the ischia, and the great sacro-sciatic ligaments.

It is occupied by the termination of the rectum, the uretra, the root of the penis in the male, or the termination of the vagina, the vulva, and the clitoris in the female, together with their muscles, fasciae, vessels, and nerves. In this sense, the division in front of the anus is termed the urethral part or the true perineum, and the posterior division, including the anus, is termed the anal part, ischio-rectal region, or the false perineum.

2 What is the ischio-rectal fossa?

It is a deep pit in the perineum, on each side of the lower end of the rectum, between that and the tuberosity of the ischium, of triangular pyramidal form, its base directed to the integument of the parts, its apex corresponding to the divergence of the Levator ani from the Obturator muscle. It is founded internally by the Sphincter and Levator ani and Coccygeus muscles, behind by the edge of the Gluteus maximus and great sacro-sciatic ligament, and is filled with a mass of adipose connective tissue, the frequent site of abscesses.

3 What is the uterus?

It is that part of the female sexual passage to which a ripe ovum is conveyed from the ovary, and in which it is detained in gestation until the fetus is mature and expelled in parturition. The non-pregnant human uterus is a pear-shaped organ about 3 inches long; with a broad, flattened part above (the body), and a narrow, more cylindrical part below (the cervix). Within is a cavity which passes out into the Fallopian tube on each side above, and below opens into the vagina. The cavity narrows as it passes into the cervix at the internal os, and continues downward to the cervical canal, to terminate at the external os uteri or os tinae. The uter-

us is supported by the broad ligament, a transverse fold of peritoneum which embraces it on each side, and by accessory ligaments, such as the round, vesico-uterine, and recto-uterine ligaments. It consists of a serous or peritoneal coat, a middle coat of smooth muscular fibres, forming most of its thickness, and an epithelial lining.

4 What are the Fallopian tubes?

They are a pair of ducts extending from the ovary to the uterus, conveying ova. In the human female they are three or four inches long, and lie between the folds of the peritoneum which constitute the broad ligament of the uterus on each side, near the upper border of these folds, and consist of a serous, a muscular and a mucous coat.

The outer or ovarian end is fringed with processes, and called the fimbriated extremity, or morsus diaboli, which is more or less closely applied to the ovary. One of these oviducts, right or left, receives the ripened ovum on its escape from the ovary, and conducts it into the womb.

5 What is the ovary?

That part of the female animal in which ova eggs or germs are generated or matured, the essential female organ of reproduction, corresponding to the testes of the male; the female genital gland or germ gland; the ovarium. The ovary in woman is a flattened ovoid body about $1\frac{1}{2}$ inches long, $\frac{1}{4}$ inch wide, and $\frac{1}{8}$ inch thick, resting on the broad ligaments of the uterus and closely connected with the Fallopian tubes or oviduct.

6 What is the heart?

It is a hollow, muscular or otherwise contractile organ which receives blood in its interior and by contraction drives it out again, and thus keeps up the circulation of the blood

1. How many chambers has it?

It has four: right auricle, right ventricle, left auricle, left ventricle.

2. Where is the tricuspid valve?

It is between right auricle and right ventricle.

3. Where is the bicuspid or mitral valve?

It is between the left auricle and left ventricle.

4. Give dimensions.

About $5 \times 3\frac{1}{2} \times 2\frac{1}{2}$ inches, and weighs from 8 to 12 ounces.

Its apex is felt between 5th and 6th costal cartilages on left side.

7 What is the pericardium (around and heart)?

It is a somewhat conically shaped membranous sac, inclosing the heart and the origin of the great vessels. It is composed of two layers, an outer fibrous one, dense and unyielding in structure, and an inner serous one, re-

flected on the surface of the viscus. Its apex is above while the apex of the heart is below. The pericardium forms one of the coverings of the upper surface of the Diaphragm. Between the serous and fibrous coats there is a thin fluid for lubricating the surfaces. There is about one drachm in quantity normally.

8 What is the endocardium (within and heart)?

It is the lining of the heart, as distinguished from the pericardium, or investing membrane of that organ; the membranes forming the inner surface of the walls of the cardiac cavities, or the surface itself. It forms by its reduplications, the cardiac, aortic and pulmonary valves, and is continuous with the lining membrane of the greater vessels.

9 What is diastole?

It is the normal rhythmical dilatation or relaxation of the heart or other blood-vessels which alternates with a systole or contraction, the two movements together constituting pulsation or beating; as auricular diastole, ventricular diastole.

10 What is systole?

It is the contraction of the heart and arteries for propelling the blood and thus carrying on circulation.

11 What is the position of the heart?

It lies obliquely in the chest with its broad fixed base uppermost, a little backward and to the right; its free apex downward, forward and to the left, so that its beating may be seen or felt at a point an inch or less to the inner side of, and about an inch and a half below, the left nipple between fifth and sixth ribs.

12 What are the nerves of the heart?

They are derived from the cardiac plexuses, formed by the pneumogastric and sympathetic nerves. Its actions are involuntary.

13 The nerves of the heart are derived from how many sources?

From three sources:

- (1) From nerve cells buried in its own substance and known as the intrinsic ganglia.
- (2) From the tenth pair (pneumogastric) of cranial nerves
- (3) From the sympathetic nervous system.

The intrinsic ganglia keep the heart beating, and the other two sets of nerves control the rate and force of the beat.

14 What is a motor nerve?

Any nerve whose function is to excite muscular contraction, and thus effect movement in an animal body. Most nerves are of mixed character or sensorimotor, effecting both motion and sensation.

15 What is a sensory nerve?

A nerve conveying sensory impulses, or, more strictly, one composed exclusively of sensory fibers; nearly equivalent to afferent nerve.

16 What are vaso-motor nerves?

Those which supply the muscular coats of the blood-vessels

17 What is a nerve-center?

It is a group of ganglion-cells closely connected with one another and acting together in the performance of some function, as the cerebral centers, psychical centers; respiratory or vaso-motor centers.

18 What is the shape of the eye?

It is spheroidal in shape, but consists of the segments of two spheres, a portion of the smaller sphere forming its anterior transparent part, and being set on the front of the posterior segment, which is a part of the larger sphere.

19 How many and what coats has it?

It consists of three coats—sclerotic, choroid and retina

- (a) The sclerotic coat is an opaque, white, dense, fibrous, inelastic membrane, continuous with the cornea in front, the two forming the external coat of the eyeball.
- (b) The choroid is a delicate, highly vascular membrane, forming one of the coats or tunics of the eyeball, lining the sclerotic, and lying between it and the retina, with which it is in contact by its inner surface.
- (c) The retina is the innermost and chiefly nervous coat of posterior part of eyeball, between the choroid coat and vitreous humor. It may be divided into ten layers.

20 How many and what refracting media has the eyeball?

It has three—the aqueous humor, the crystalline lens, the vitreous humor.

- (a) The aqueous humor is a limpid, watery fluid which fills the space between the cornea and the crystalline lens of the eye.
- (b) The crystalline humor or lens is a lentiform pellucid body, composed of transparent firm substance, inclosed in a membranous capsule, and situated in front of the vitreous humor and behind the iris of the eye.
- (c) The vitreous humor is a pellucid gelatine substance which fills about four-fifths of the ball of the eye, behind the crystalline lens.

EXAMINATION QUESTIONS WHICH WERE USED JUNE 20, 1899,
FOR THE FIRST TERM STUDENTS IN THE AMERICAN
SCHOOL OF OSTEOPATHY.

I

1. Define Anatomy—Name its nine divisions.
2. Group muscles of forearm and give nerve supply.
3. Name muscles of hand and give nerve supply.
4. Name the structures which pass through the six openings of the posterior annular ligament.
5. Name the muscles attached to the external intermuscular septum and the structures which pass through it.
6. The same for internal intermuscular septum. Give relations of radial artery.
7. Name the structures which pierce the costo-coracoid membrane. Name bones of nasal fossa: of orbit.
8. Give anastomosis of elbow; name bones of the wrist.
9. Origin and insertion of Supinator longus.

II

1. Name muscles in gluteal region; give origin and insertion of Tibialis anticus.
2. Tell what structures pass through greater and lesser sacro-sciatic foramina.
3. Give relations of femoral artery.
4. Bound Scarpa's triangle. Give floor of same.
5. Bound popliteal space.

III

1. Name five triangles of neck, (draw) Give boundaries of the same.
2. Name the twelve cranial nerves—tell how each leaves the cranium.
3. Give rule for branches and roots of spinal nerves.
4. Draw the Brachial plexus.
5. Name the structures which pass through the three lacerated foramina.
6. Give blood supply and muscles of the temporal bone.